

# A case of porphyria cutanea tarda in the setting of hepatitis C infection and tobacco usage

M Lederhandler<sup>1,2</sup>, L Chen<sup>2</sup>, SA Meehan<sup>2</sup>, NK Brinster<sup>2</sup>, A Neimann<sup>2</sup>

Affiliations: <sup>1</sup>The Laser Skin & Surgery Center of New York, New York, New York, USA, <sup>2</sup>New York University Langone Medical Center, The Ronald O. Perelman Department of Dermatology, New York, New York, USA

Corresponding Author: Margo Lederhandler MD, The Laser Skin & Surgery Center of New York, 317 East 34<sup>th</sup> Street, Floor 11, New York, NY 10016, Email: [margo.lederhandler@gmail.com](mailto:margo.lederhandler@gmail.com)

## Abstract

Porphyria cutanea tarda (PCT) is the most common type of porphyria, presenting in middle-aged patients with a photodistributed vesiculobullous eruption, milia, and scars. Porphyria cutanea tarda occurs in relation to inhibition of uroporphyrinogen decarboxylase, a key enzyme in the heme biosynthesis pathway. A number of genetic and acquired factors increase susceptibility to PCT by reducing uroporphyrinogen decarboxylase activity. A handful of other vesiculobullous conditions may mimic PCT both clinically and histologically; therefore, both skin biopsy and laboratory evaluation are helpful in confirming the diagnosis. We report a case of PCT in the setting of cigarette usage and untreated hepatitis C infection.

*Keywords: porphyria cutanea tarda, hepatitis C, tobacco, treatment*

## Case Synopsis

A 69-year-old man, a smoker with a history of untreated hepatitis C and type II diabetes mellitus, presented to the emergency department at NYU Langone Tisch Hospital for a blistering eruption of several months' duration. The patient reported a long-time history of "marks" on his forearms and hands. However, he had never blistered until two months prior. He noted worsening of symptoms in the week leading up to presentation with increasing number of blisters on his dorsal hands and forearms, followed by progression to involve his left cheek, ear,

and neck (**Figure 1**). The eruption was associated with pruritus and a burning sensation. He noted frequent usage of his hands at work in printing for the police force and through hobbies, which included gardening and home-improvement. He denied a history of increased hair growth on the face.

New medications included varenicline, which he had started several weeks prior in the setting of smoking cessation and tramadol for joint pain. He admitted to "cheating" with smoking cessation and having several cigarettes daily. Out of concern that this might be a drug reaction, he stopped all medications a couple of weeks prior to presentation. He denied a family history of similar lesions. A review of systems revealed frequent dark urine (which at times resolved with hydration), chronic joint pain, and Raynaud phenomenon. He denied a history of alcohol use or human immunodeficiency virus.

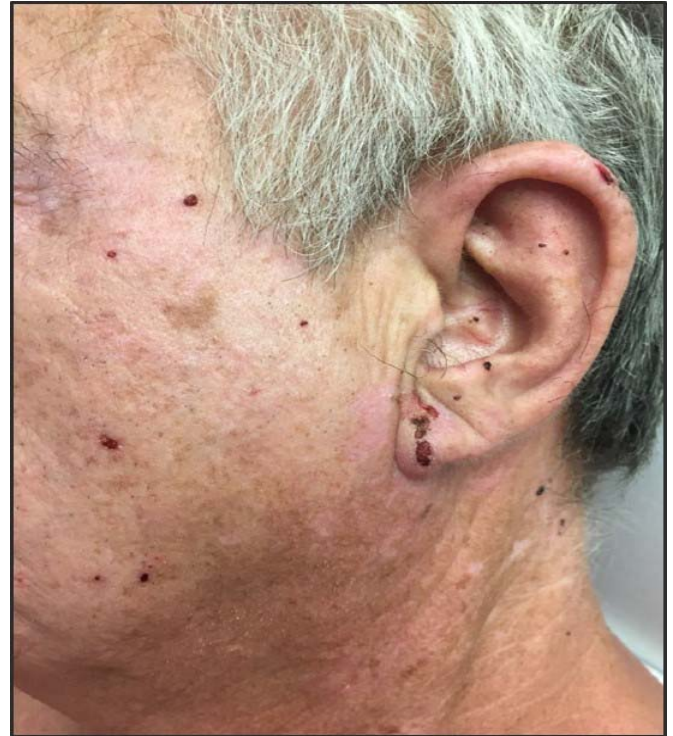On examination, the patient was well appearing and in no acute distress. His vital signs were within normal limits. On the forehead, lateral cheeks, left ear, and left posterolateral neck there were scattered superficial erosions, many with heme-crust. Scattered on the dorsal aspect of his forearms and hands were multiple hypopigmented, atrophic scars, scattered heme-crust ed erosions, and non-inflammatory, tense vesicles and bullae of varied sizes (**Figure 2**). There were a few firm, white, pearly papules consistent with milia. There was mild hypertrichosis overlying the lateral cheeks. The remainder of the full body skin examination was within normal limits.

A complete blood count demonstrated a hemoglobin of 13.0g/dL (ref 13.7-17.5g/dL), hematocrit of 38.5% (ref 40-51%), normal white blood count, platelet count, and normal differential. An erythrocyte sedimentation rate was 81mm/hr (ref 0-10mm/hr), and a C-reactive protein level was 20.9mg/L (1-5mg/L). A urine fractionated porphyrin test revealed elevated concentrations of urine uroporphyrin, heptacarboxylate porphyrin, and pentacarboxyl porphyrins. A total plasma/serum porphyrin level was elevated at 669nmol/L (ref 0-15nmol/L).

Two 4mm punch biopsies of the left dorsal hand were obtained. There was a pauci-inflammatory subepidermal blister with festooning and hyalinized papillary dermal vessels (**Figure 3**). Direct immunofluorescence showed perivascular C3 (**Figure 4**) and IgM deposition. IgA, IgG, and fibrinogen were negative.

## Case Discussion

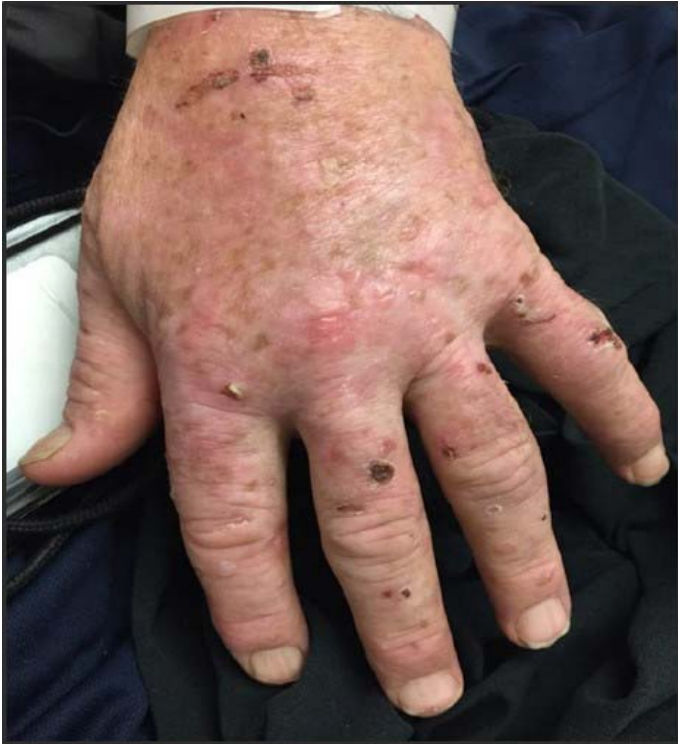Porphyria cutanea tarda (PCT) is the most common type of porphyria, a disorder of heme synthesis [1]. Enzyme defects along the heme synthesis pathway lead to the buildup of pathway precursors, causing two types of porphyrias: acute hepatic porphyrias and photocutaneous porphyrias [1]. The cutaneous porphyrias have skin involvement related to overproduction of photosensitizing porphyrins [1]. In the case of PCT, uroporphyrinogen decarboxylase is inhibited, leading to a buildup of photosensitizing porphyrins produced by the liver [1, 2]. In nearly all patients with clinical disease, at least two genetic or acquired factors that reduce uroporphyrinogen decarboxylase activity, and thus increase susceptibility to PCT, are present [3]. Genetic factors include hemochromatosis (prevalence 53%) and uroporphyrinogen decarboxylase mutation (17%), whereas acquired factors include hepatitis C virus (HCV) infection (69%), alcohol consumption (87%), tobacco use (81%), estrogen use in female patients (66%), and human immunodeficiency virus infection (13%) [3]. Our patient had active hepatitis C infection and was a smoker undergoing smoking cessation.



**Figure 1.** Forehead, lateral cheek, left ear, and left posterolateral neck with scattered superficial erosions, many with heme-crust. Lateral cheek with mild hypertrichosis.

Porphyria cutanea tarda is most often seen in the middle-aged population, classically with a photodistributed vesiculobullous eruption that heals with scars and milia [2]. Hypertrichosis may be seen and in advanced disease, sclerodermoid features may also be present [2]. In order to diagnose PCT, urine or plasma porphyrin profiles should be obtained, which will reveal a predominance of uroporphyrin and heptacarboxyl porphyrin [1].

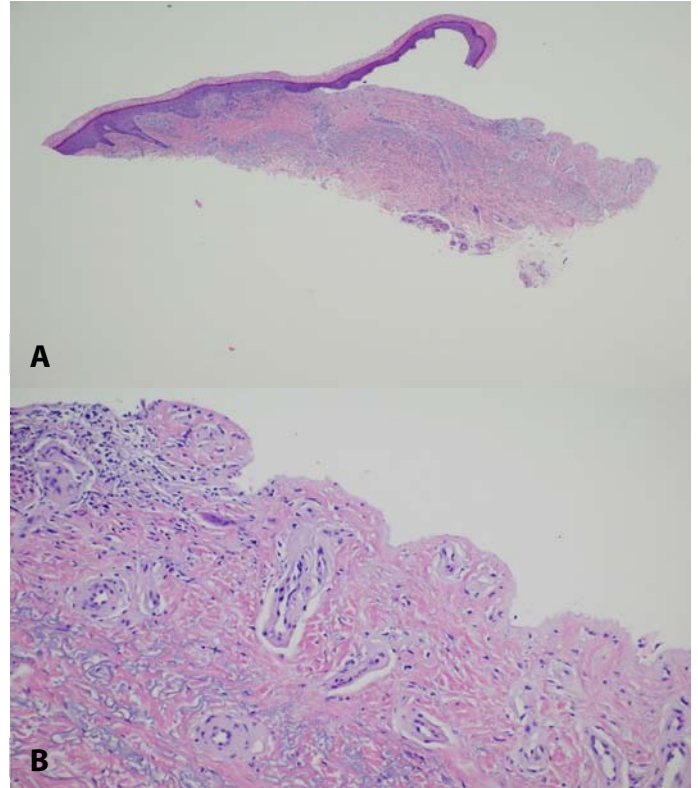
Skin biopsy for both hematoxylin and eosin as well as direct immunofluorescence is also helpful to distinguish PCT from other blistering disorders [2]. On histopathology, the subepidermal bulla is characteristically cell-poor and there is festooning of the dermal papillae, likely caused by the perivascular and vascular deposition of glycoproteins in the superficial dermis [2]. Direct immunofluorescence (DIF) microscopy reveals superficial and perivascular Immunoglobulin G (IgG) more often than IgM, complement, and fibrinogen [2]. Historically, the urine was examined by both natural light and Wood lamp — after several hours of exposure to natural light the urine turns red to brown, and on exposure



**Figure 2.** Dorsal aspect of hand with multiple hypopigmented, atrophic scars, scattered heme-crusted erosions, non-inflammatory, tense vesicles, and few firm white, pearly papules consistent with milia.

to UVA, the urine fluoresces pink to red [2]. This technique fell out of favor owing to lack of sensitivity and specificity for PCT [2].

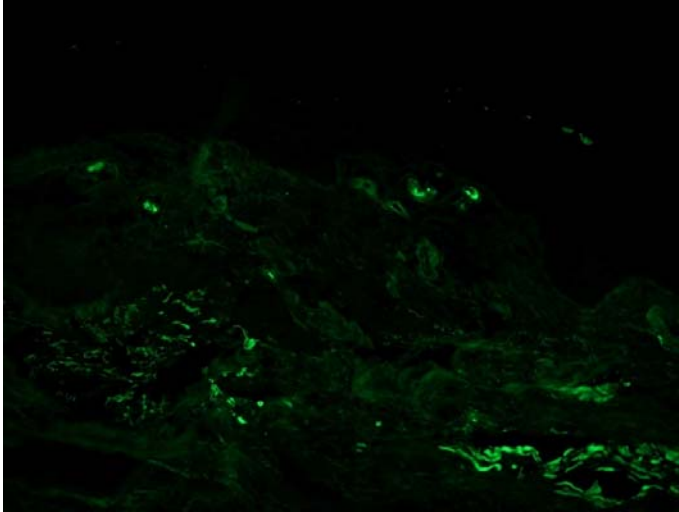
The differential diagnosis for PCT includes other vesiculobullous disorders, especially those with a predilection for photodistributed sites. Pseudoporphyria, which may be idiopathic or seen in the setting of certain medications (commonly nonsteroidal anti-inflammatory drugs), appears similarly clinically and is identical on histopathology; however, these patients will have normal porphyrin levels [1, 2, 4]. The non-inflammatory type of epidermolysis bullosa acquisita (EBA) commonly affects trauma-prone acral surfaces and may also heal with scars and milia [5, 6]. Histologically, EBA similarly is characterized by cell-poor subepidermal bullae and DIF demonstrates deposition of IgG at the basement membrane zone [6]. Bullous pemphigoid (BP) should be considered in the setting of tense bullae. However, classically bullae of BP may be seen on non-sun exposed sites and often there is an urticarial phase that precedes the formation of bullae [7]. Bullous systemic lupus erythematosus was



**Figure 3.** Biopsy of the left dorsal hand with H&E stain revealed a pauci-inflammatory subepidermal blister at **A)** 40x, with festooning and hyalinized papillary dermal vessels at 200x, **B).**

considered in this patient with a history of Raynaud phenomenon; however, he lacked other features of lupus erythematosus. The characteristic clinical features of bullous systemic lupus erythematosus include widespread bullae that heal without scars or milia and histologic features of the subepidermal bullae of systemic lupus are distinctive with a neutrophil-predominant infiltrate and distinctive immunoreactants on DIF [8]. Porphyrin studies may be helpful to differentiate PCT from the above when the diagnosis is otherwise unclear.

In distinguishing amongst the porphyrias with cutaneous phenotype, it may be helpful to first group those that are classically seen in children versus adults. Hepatoerythropoietic porphyria, congenital erythropoietic porphyria, and erythropoietic protoporphyria present in childhood. The cutaneous porphyrias that do not present in childhood include hereditary coproporphyria (HCP) and variegate porphyria (VP), in addition to PCT. Variegate porphyria has an onset in adolescence or adulthood with blisters and acute systemic attacks.



**Figure 4.** Direct immunofluorescence showed perivascular C3 deposition at 20x.

Characteristically, the plasma fluoresces pink at an emission peak of 626nm in symptomatic patients. HCP has similar clinical presentation to VP and the distinguishing feature is the high level of coproporphyrin in the stool.

Treatment of PCT includes treatment of the underlying triggering medical conditions, removal of precipitating factors, usage of oral anti-malarial medications, or hepatic iron depletion through phlebotomy [1, 9]. Antimalarials are effective owing

to their action within hepatocytes to free porphyrins, which are then renally excreted [1]. With the recent advent of direct-acting antivirals for HCV, the treatment of HCV has been revolutionized and the vast majority of patients with HCV have the ability to achieve cure. Several case studies have demonstrated the resolution of PCT clinical symptoms following treatment of HCV with direct-acting antivirals [10, 11, 12].

Once the diagnosis was made for our patient, he was referred to the hepatology clinic for the treatment of HCV. He was also referred to the hematology clinic for further evaluation and co-management. The possibility of treatment with hydroxychloroquine and phlebotomy was discussed. However, treatment was deferred until his hepatitis had been treated. The patient was extensively counseled on strict photo-protective behaviors, complete smoking cessation, and the avoidance of iron-rich foods, alcohol, and hepatotoxic medications. He demonstrated significant improvement at his three-week follow-up visit and sustained improvement 6 months later.

## Potential conflicts of interest

The authors declare no conflicts of interests.

## References

1. Bissell DM, Anderson KE, Bonkovsky HL. Porphyria. *N Engl J Med*. 2017;377:2101. [PMID: 29166231].
2. Frank J, Poblete Gutierrez, Pamela A. Porphyria. In: *Dermatology*. Bologna J, Jorizzo, Joseph L., Schaffer, Julie V., editor. 3 ed. Elsevier Saunders; 2012.
3. Jalil S, Grady JJ, Lee C, Anderson KE. Associations among behavior-related susceptibility factors in porphyria cutanea tarda. *Clin Gastroenterol Hepatol*. 2010;8:297-302, e1. [PMID: 19948245].
4. Harber LC, Bickers DR. Porphyria and pseudoporphyria. *J Invest Dermatol*. 1984;82:207-9. [PMID: 6699422].
5. Bernard P, Borradori, Luca. Pemphigoid Group. In: *Dermatology*. Bologna J, Jorizzo, Joseph L., Schaffer, Julie V., editor. 3rd ed. Elsevier Saunders; 2012.
6. Deen K, Wu J. Porphyria Cutanea Tarda Masquerading as Epidermolysis Bullosa Acquisita: A Report of Two Cases. *Case Rep Dermatol*. 2015;7:129-35. [PMID: 26269702].
7. Di Zenzo G, Marazza G, Borradori L. Bullous pemphigoid: physiopathology, clinical features and management. *Adv Dermatol*. 2007;23:257-88. [PMID: 18159905].
8. Chanprapaph K, Sawatwarakul S, Vachiramon V. A 12-year retrospective review of bullous systemic lupus erythematosus in cutaneous and systemic lupus erythematosus patients. *Lupus*. 2017;26:1278-84. [PMID: 28358242].
9. Tintle S, Alikhan A, Horner ME, et al. Cutaneous porphyrias part II: treatment strategies. *Int J Dermatol*. 2014;53:3-24. [PMID: 24134210].
10. Aguilera P, Laguno M, To-Figueras J. Treatment of chronic hepatitis with boceprevir leads to remission of porphyria cutanea tarda. *Br J Dermatol*. 2014;171:1595-6. [PMID: 25154788].
11. Hatch MM, Nawas Z, Kollipara R, Tyring SK. Can curative antivirals benefit porphyria cutanea tarda in hepatitis C patients? *J Eur Acad Dermatol Venereol*. 2017;31:e194. [PMID: 27550066].
12. Tong Y, Song YK, Tyring S. Resolution of Porphyria Cutanea Tarda in Patients With Hepatitis C Following Ledipasvir-Sofosbuvir Combination Therapy. *JAMA Dermatol*. 2016;152:1393-5. [PMID: 27732687].