

UC Davis

Dermatology Online Journal

Title

Multifocal epithelial hyperplasia: report of 3 cases

Permalink

<https://escholarship.org/uc/item/12p1s5xc>

Journal

Dermatology Online Journal, 20(8)

Authors

Tehranchinia, Zohreh
Mozafari, Nikoo
Barikbin, Behrooz
et al.

Publication Date

2014

DOI

10.5070/D3208023544

Copyright Information

Copyright 2014 by the author(s). This work is made available under the terms of a Creative Commons Attribution-NonCommercial-NoDerivatives License, available at <https://creativecommons.org/licenses/by-nc-nd/4.0/>

Peer reviewed

Photo Vignette

Multifocal epithelial hyperplasia: report of 3 cases

Zohreh Tehranchinia¹, Nikoo Mozafari¹, Behrooz Barikbin¹, Seyed Alireza Nadji²

¹Skin Research Center, Shahid Beheshti University of Medical Sciences, Tehran, Iran

²Virology Research Center, National Research Institute of Tuberculosis and Lung Diseases (NRITLD) Shahid Beheshti University of Medical Sciences, Tehran, Iran

Correspondence:

Nikoo Mozafari, MD
Shohada-e Tajrish Hospital
Tajrish Square
Tehran, Iran.
Tel: 98 2122741507
Fax: 98 2122744393
Email: Nikoo_MD@yahoo.com

Abstract

Multifocal epithelial hyperplasia (MEH) is a rare disorder characterized by multiple painless discrete and soft flattened papules on the oral mucosa. It is caused by human papilloma virus 13 and 32. The frequency of this disease varies widely from one geographic region to another. Generally it is very rare in Asia. Herein we report 3 Iranian cases with oral lesions, which showed clinical and histopathological characteristics of MEH disease. Two of them were siblings and HPV13 was detected in one of the patients.

Introduction

Multifocal epithelial hyperplasia (MEH) or Heck's disease is a rare contagious oral cavity disease caused by human papilloma virus [1]. It is characterized by multiple painless discrete and soft flattened papules with color similar to the adjacent mucosa [1]. It was first described in the Colombian Indian population by Estuarda in 1965 [2]. Thereafter, it was reported mostly among Native Americans, Eskimos, and South Africans; later it was also found in other ethnic groups [1, 2]. Generally multifocal epithelial hyperplasia is a very rare disease in Asia [3]. Herein we report 3 patients with multifocal epithelial hyperplasia; two of them were siblings. We detected HPV13 in one patient. The diagnosis of MEH can be made on the basis of clinical observation, but histological examination may show characteristics of viral infection, as reported here.

Case synopses

Cases 1 and 2

A 19-year-old girl presented to our dermatology department with a chief complaint of several elevated papules in her mouth for more than 10 years. Intraoral examination revealed several smooth-surfaced papules on her mucosal surfaces of the upper and lower lips and bilateral buccal mucosa.(Figure. 1) The lesions ranged in sizes from 2-10 mm in diameter. The lesions were firm, similar in color to the surrounding normal mucosa. The patient was otherwise healthy. Examination of other family members

revealed the presence of similar oral lesions on her 14-year-old brother. The lesions were located on the lateral border of tongue and inner aspect of his lower lip. (Figure. 2)

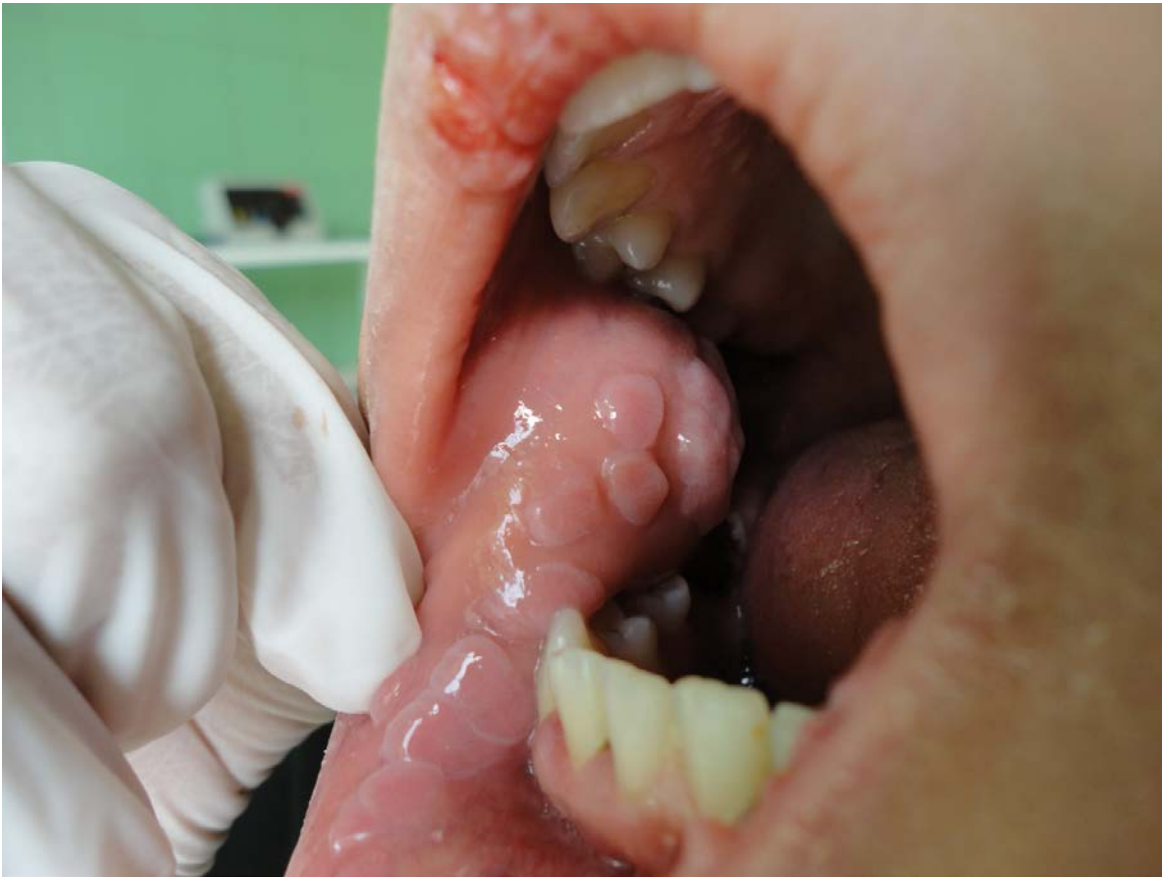

Figure 1. Several smooth-surfaced papules on the buccal mucosa

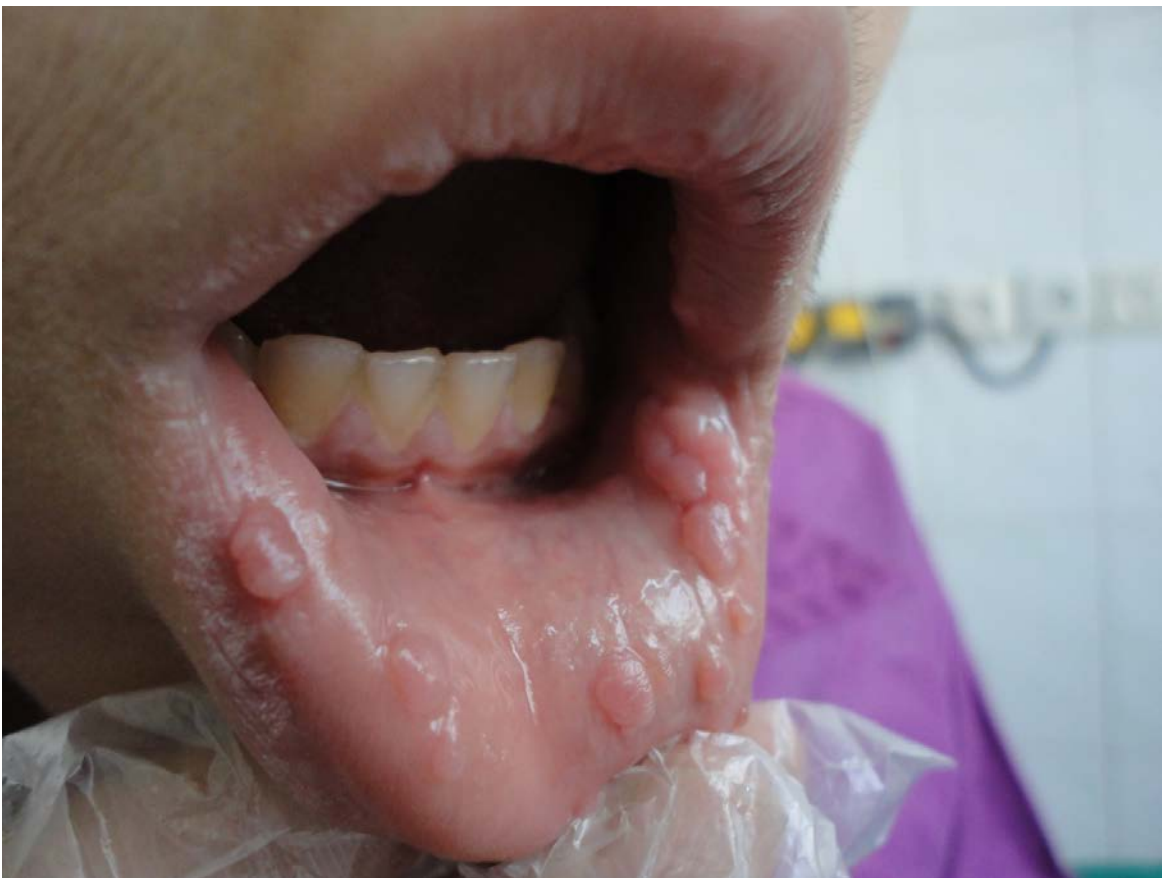

Figure 2. Multiple soft pink papules on the lower lip mucosa.

To confirm the diagnosis of multifocal epithelial hyperplasia, two punch biopsies were performed on case1 (19-year old girl). One specimen was fixed in 10 % formalin and submitted for histological examination. Another specimen was placed in normal saline and was sent to a virology lab for PCR studies.

Pathology: the hematoxylin and eosin (H&E)- stained section showed acanthosis with thickening and elongation of the rete ridges. Some of the club shaped rete ridges were confluent to each other. (Figure. 3)

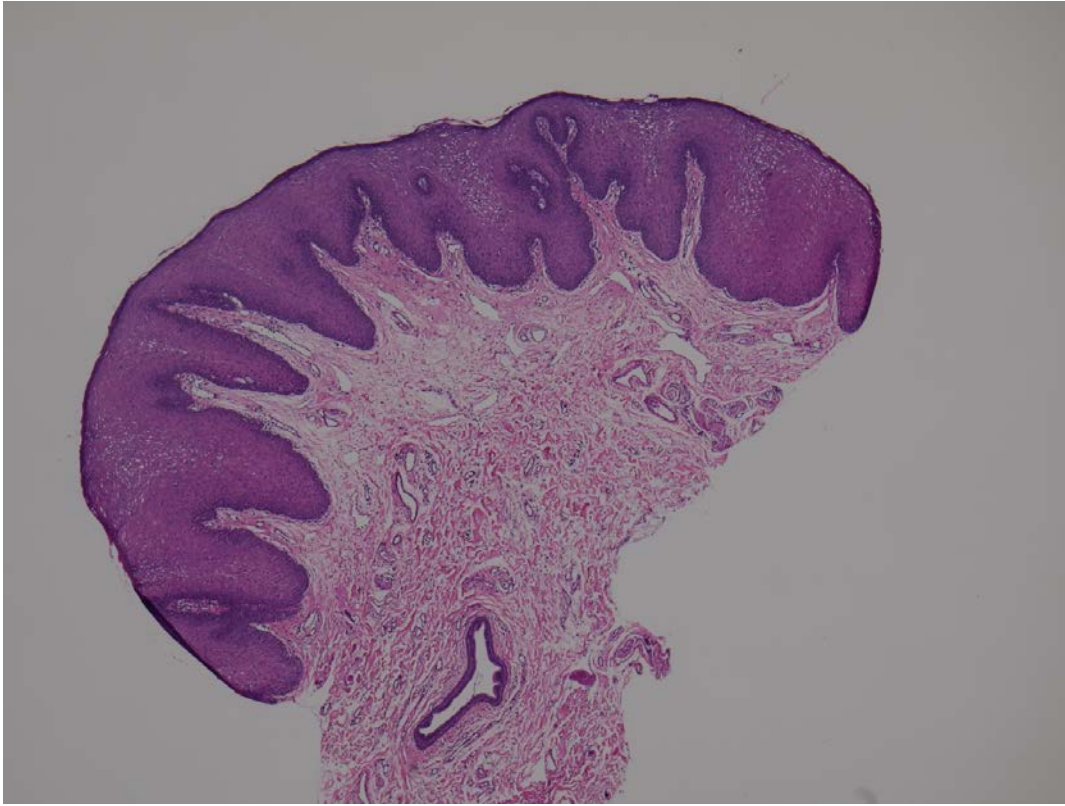

Figure 3. Hematoxylin and eosin (H&E)- stained section ($\times 4$) shows acanthotic epithelium with thickening and elongation of the rete ridges.

In the upper portion of the epithelium, the cells showed marked vacuolization (koilocytic changes), hyperchromatism, and enlargement of the nuclei, which were indicative of viral infection. (Figure. 4)

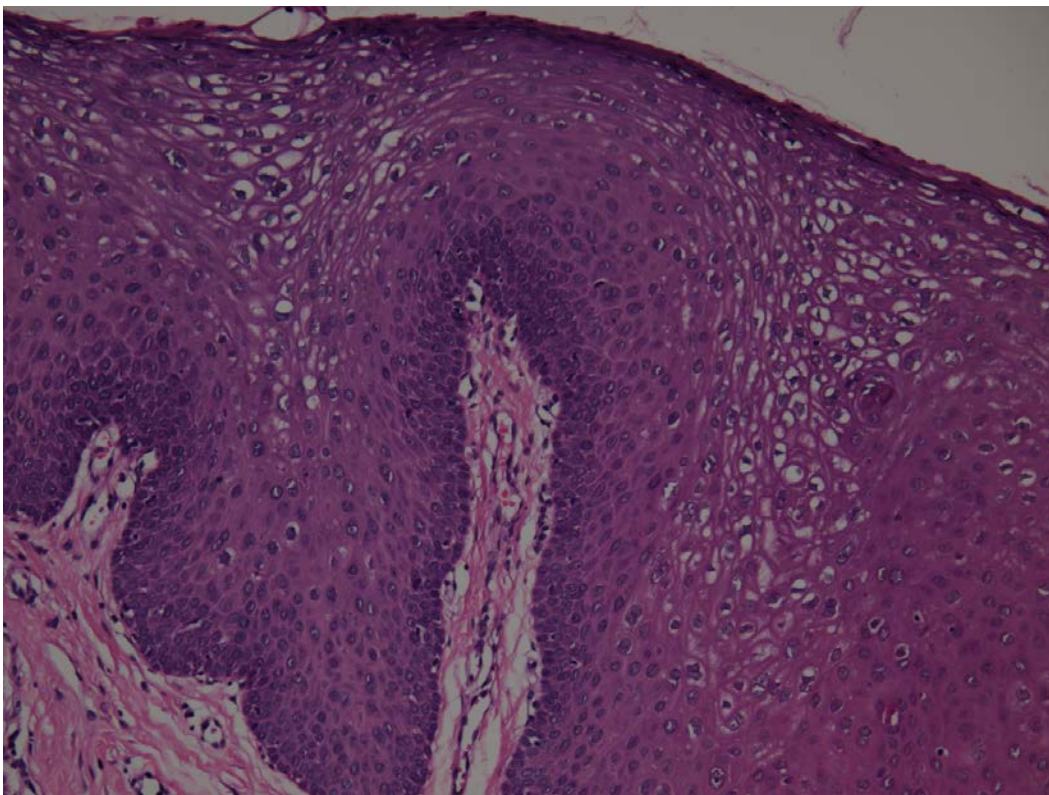


Figure 4. Hematoxylin and eosin (H&E)- stained section (×40) shows marked vacuolization (koilocytic changes), hyperchromatism, and enlargement of the nuclei.

In situ hybridization for HPV showed positive nuclear staining. Subsequently HPV genotype was determined by analysis of the MY09/11 primer set target sequence and it was confirmed the presence of HPV-13. The nucleotide sequence of HPV isolate that determined in this study has been deposited in GenBank data base under the accession number JN564005.Case 3

A 4-year-old-girl presented with a 1-year history of asymptomatic papules in her mouth. Physical examination revealed multiple, soft, discrete papulonodules measuring 2 to 7 mm. The lesions were mucosa-colored and located on the left buccal mucosa and inner surface of the lower lip. There was no family history of similar lesions. The parents did not give consent for a biopsy. The diagnosis of multifocal epithelial hyperplasia was established based on typical clinical features (Figure 5).

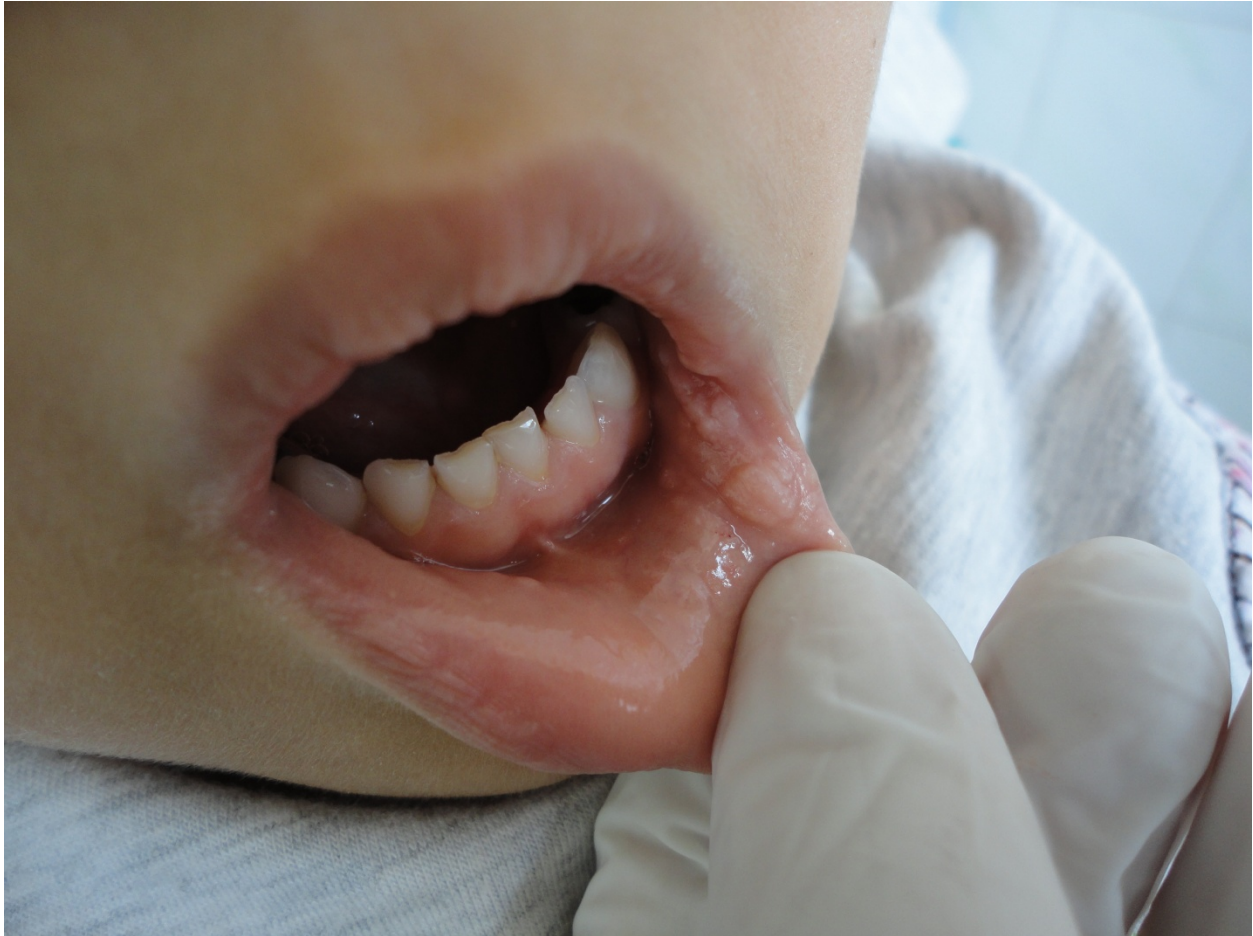

Figure 5. Multiple, soft, discrete papulonodules on the left buccal mucosa and inner surface of lower lip

Discussion

Multifocal epithelial hyperplasia is an uncommon mucosal proliferation, mostly found in specific ethnic and racial groups. It is observed in high frequency among native Americas and Eskimo populations [1]. It frequently affects children and adolescents, between 2 to 13 years of age [4, 5]. The majority of patients are female. The female to male ratio has been reported as high as 5:1 [5]. The exact cause of the higher incidence in females is not known.

Multifocal epithelial hyperplasia presents as multiple discrete exophytic papules or nodules on the oral mucosa, gingiva, tongue, and lips. They range in size from 1 to 10 mm in diameter and sometimes coalesce to form larger plaques in a cobblestoned pattern [1]. Lesions have the same color as the surrounding mucosa [1]. It is very important to differentiate multifocal epithelial hyperplasia from oral condyloma accuminata or oral florid papillomatosis, which may indicate sexual abuse. Other signs of physical abuse or signs of other sexually transmitted diseases as well as involvement of anogenital area are in favor of venereal warts, which can be confirmed by HPV subtyping. HPV 6 and 11 are the causative factors in the majority of these cases. Multifocal epithelial hyperplasia is specifically associated with HPV 13 and 32 [6] and usually has a benign course. Malignant transformation has been reported in one case of multifocal epithelial hyperplasia related to HPV 24. However, in this case, there is some doubt whether the diagnoses is verrucous carcinoma rather than multifocal epithelial hyperplasia [7].

The susceptibility factors that may be related to MEH have not been clearly determined, but as the familial involvement has been reported in most previous cases as in ours [8], several authors have suggested a possible relationship with an autosomal dominant gene [8]. Other suggested factors that may play a role in vulnerability of patients to HPV 13 or 32 include: poverty, dietary insufficiency, close living conditions, and the human leukocyte antigen (HLA-DR4) allele [4].

Treatment is not always indicated. The lesions are usually asymptomatic and may regress spontaneously within months to years. However, some patients may complain that the lesions interfere with occlusion or mastication or they may want to be treated because of aesthetic concerns [1].

Many ablative methods such as surgical excision, cryotherapy, electrocauterization, Co2 laser therapy, and trichloroacetic acid(TCA) application have been used with limited success because the lesions tend to recur [1]. Excision of the papules via 808 nm diode laser has also been reported [9]. Advantages of this method includes the hemoglobin target, which promotes optimal hemostatic effect, lesser scarring, and decreased infection [9].

Systemic interferon α and topical interferon β are other options that have been successfully applied in the treatment of multifocal epithelial hyperplasia [10]. Yaser et al. reported three patients with multifocal epithelial hyperplasia refractory to cryotherapy or TCA that successfully were treated with imiquimod 5% cream; no recurrence occurred during a one year follow-up period [11].

Topical imiquimod 5% cream was used for case 1 in the present report. After 4 months of treatment the lesions regressed completely, but partial recurrence was observed after 6 months [12].

Conclusion

Multifocal epithelial hyperplasia is a rare disease. It is important for dermatologists and stomatologists to be familiar with this disorder and differentiate it from sexually transmitted lesions.

References

1. Said AK, Leao JC, Fedele S, Porter SR. Focal epithelial hyperplasia - an update. *J Oral Pathol Med.* 2013 Jul;42(6):435-42.[PMID:23061874]
2. Ledesma-Montes C, Vega-Memije E, Garcés-Ortiz M, Cardiel-Nieves M, Juárez-Luna C. Multifocal epithelial hyperplasia. Report of nine cases. *Med Oral Patol Oral Cir Bucal.* 2005 Nov-Dec;10(5):394-401.[PMID:16264387]
3. Mosannen-Mozaffari P, Falaki F, Amirchaghmaghi M, Pakfetrat A, Dalirsani Z, Saghafi-Khadem S. Multifocal epithelial hyperplasia, a rare oral infection in Asia: report of twelve cases in Iran. *Med Oral Patol Oral Cir Bucal.* 2010 Jul;15(4):e591-5.[PMID:20038890]
4. Bennett LK, Hinshaw M. Heck's disease: diagnosis and susceptibility. *Pediatr Dermatol.* 2009 Jan-Feb;26(1):87-9.[PMID:19250415]
5. Gonzalez LV, Gaviria AM, Sanclemente G, Rady P, Tying SK, Carlos R, Correa LA, Sanchez GI. Clinical, histopathological and virological findings in patients with focal epithelial hyperplasia from Colombia. *Int J Dermatol.* 2005 Apr;44(4):274-9.[PMID:15811076]
6. Padayachee A, van Wyk CW. Human papillomavirus (HPV) DNA in focal epithelial hyperplasia by in situ hybridization. *J Oral Pathol Med.* 1991 May;20(5):210-4.[PMID:1648613]
7. Jablonska S. Demonstration of HPV 24 in long-standing Heck's disease with malignant transformation. *Eur J Dermatol.* 2000 Apr-May;10(3):235-6.[PMID:10725826]
8. Hall C, McCullough M, Angel C, Manton D. Multifocal epithelial hyperplasia: a case report of a family of Somalian descent living in Australia. *Oral Surg Oral Med Oral Pathol Oral Radiol Endod.* 2010 Jan;109(1):e20-4.[PMID:20123364]
9. Bombeccari GP, Pallotti F, Guzzi G, Spadari F. Diode Laser therapy for Heck's disease associated with HPV13 infection. *J Eur Acad Dermatol Venereol.* 2009 Feb;23(2):197-8.[PMID:18462295]
10. Steinhoff M, Metze D, Stockfleth E, Luger TA. Successful topical treatment of focal epithelial hyperplasia (Heck's disease) with interferon-beta. *Br J Dermatol.* 2001 May;144(5):1067-9.[PMID:11359400]
11. Yasar S, Mansur AT, Serdar ZA, Goktay F, Aslan C. Treatment of focal epithelial hyperplasia with topical imiquimod: report of three cases. *Pediatr Dermatol.* 2009 Jul-Aug;26(4):465-8.[PMID:19689526]
12. Barikbin B, Tehraninia Z, Mozafari N. Treatment of multifocal epithelial hyperplasia with imiquimod. *Indian J Dermatol Venereol Leprol.* 2014 Mar-Apr;80(2):175-7.[PMID:24685868]