

UC Davis

UC Davis Previously Published Works

Title

Developing a nanoparticle-delivered high-efficacy treatment for infantile hemangiomas using a mouse hemangioendothelioma model

Permalink

<https://escholarship.org/uc/item/1667t1kx>

Journal

Plastic and Reconstructive Surgery, 138(2)

ISSN

0032-1052

Authors

Orbay, H

Li, Y

Xiao, W

et al.

Publication Date

2016-08-01

DOI

10.1097/PRS.0000000000002403

Peer reviewed

Developing a Nanoparticle-Delivered High-Efficacy Treatment for Infantile Hemangiomas Using a Mouse Hemangioendothelioma Model

Hakan Orbay, M.D., Ph.D.
 Yuanpei Li, Ph.D.
 Wenwu Xiao, Ph.D.
 Simon R. Cherry, Ph.D.
 Kit Lam, M.D., Ph.D.
 David E. Sahar, M.D.
 Sacramento and Davis, Calif.



Background: Current treatments for infantile hemangiomas have unpredictable outcomes. The authors' aim was to develop a nanoporphyrin-delivered, high-efficacy treatment for infantile hemangiomas using a mouse hemangioendothelioma model.

Methods: The authors injected mouse hemangioendothelioma cells intradermally to axillary regions of 5-week-old, female, nude mice ($n = 19$) to induce hemangioendothelioma growth. They documented nanoporphyrin accumulation in hemangioendotheliomas using positron emission tomography. For the treatment study, the authors randomized hemangioendothelioma-bearing nude mice ($n = 9$) into three groups ($n = 3$ each). Group I received only saline injections. Group II received only laser treatment after saline injection, and group III received laser treatment after nanoporphyrin injection through the tail vein. The authors followed up the treatment response with digital caliper measurements.

Results: Hemangioendotheliomas started to grow approximately 1 week after inoculation and resembled infantile hemangiomas histologically. Nanoporphyrin uptake in hemangioendotheliomas was 19.7 ± 2.2 , 16.7 ± 2.02 , 8.4 ± 0.3 , and 4.9 ± 0.6 percent injected dose per gram of tissue at 3, 6, 24, and 48 hours after injection, respectively. Nanoporphyrin uptake was significantly higher than in blood at 24 and 48 hours after injection ($p < 0.05$). Results of ex vivo biodistribution study were consistent with positron emission tomographic imaging. Hemangioendotheliomas in group III started to regress 1 day after the treatment and disappeared totally by day 21. The difference between tumor volumes in group III and other groups was significant on days 17 and 21 ($p < 0.05$).

Conclusions: Nanoporphyrin accumulated in hemangioendotheliomas at high concentrations, enabling a high-efficacy photodynamic therapy. Given the similarities between hemangioendotheliomas and infantile hemangiomas, this treatment potentially can be a high-efficacy treatment for infantile hemangiomas. (*Plast. Reconstr. Surg.* 138: 410, 2016.)

Infantile hemangiomas are the most common tumors of childhood, with a reported incidence between 4 and 10 percent.¹⁻⁴ Tumors typically progress through two phases of growth: an initial “proliferative phase” during the first several months of life in which the tumor grows

rapidly, followed by an “involution phase,” with slow, spontaneous regression.^{3,5} Although most lesions proliferate and subsequently regress with

Disclosure: *The authors have no financial interest to declare in relation to the content of this article.*

From the Department of Surgery, Division of Plastic Surgery, and the Department of Biochemistry and Molecular Medicine, University of California-Davis Medical Center; and the Department of Biomedical Engineering, University of California-Davis.

Received for publication August 4, 2015; accepted March 28, 2016.

Copyright © 2016 by the American Society of Plastic Surgeons

DOI: 10.1097/PRS.0000000000002403

Supplemental digital content is available for this article. A direct URL citation appears in the text; simply type the URL address into any Web browser to access this content. A clickable link to the material is provided in the HTML text of this article on the *Journal's* Web site (www.PRSJournal.com).

minimal consequences, central facial lesions usually result in disfigurement. The residual fibrofatty masses force patients to live with unsightly scars for the remainder of their lives, causing lifelong psychological and physiologic problems. Preventing rapid growth of infantile hemangiomas early on can eliminate potential complications and dramatically improve quality of life for patients. Unfortunately, current treatment methods for infantile hemangiomas face multiple challenges, including poor overall efficacy and serious side effects.⁶⁻⁸ The goal of this study was to develop a novel, locally active, nontoxic treatment method for infantile hemangiomas using photodynamic therapy delivered by means of nanoparticles.

Photodynamic therapy uses a photosensitizing drug in combination with laser light to kill target cells. First, a photosensitizer is administered; then, the target region is irradiated with laser light at a wavelength that matches the absorption spectrum of the photosensitizer. The photosensitizer absorbs a photon of laser light and then transfers most of the absorbed energy to a molecule of oxygen. This converts the oxygen molecule into a relatively strong subtype of reactive oxygen species known as singlet oxygen.⁹⁻¹¹ As a consequence, in the tissues that have accumulated the sensitizer, light-induced reactive oxygen species exerts a cytotoxic effect by causing lethal oxidative damage to biologically important structures. Photodynamic therapy can eliminate tumors with minimal risk of fibrosis or scarring, and it is becoming an increasingly accepted therapeutic modality, either alone or in combination with other treatments for various malignant and nonmalignant conditions.^{11,12}

We used nanoporphyrim nanoparticle as a photosensitizer for photodynamic therapy in this study. Nanoporphyrim is a porphyrin-based nanocompound that has been recently developed and used as a photosensitizer for the photodynamic therapy treatment of ovarian and breast cancer xenografts in nude mice.¹³ Similar to other nanoparticles, nanoporphyrim selectively accumulates in tumors because of its small size (approximately 25 nm). This phenomenon is known as the “enhanced permeability and retention” effect. The general explanation for this phenomenon is that, for tumor cells to grow quickly, they must stimulate the production of blood vessels. These newly formed tumor vessels are usually abnormal in that they have poorly aligned defective endothelial cells with wide fenestrations, and lack a smooth muscle layer, or innervation. These vessels are also called leaky vessels.¹⁴⁻¹⁶ Infantile hemangiomas are also fast-growing vascular tumors;

therefore, we hypothesize that infantile hemangioma vasculature is leaky and that intravenously administered nanoporphyrim will preferentially accumulate at the infantile hemangioma lesion, which can then be destroyed through photodynamic therapy without affecting surrounding normal tissues.

MATERIALS AND METHODS

Animal Model for Infantile Hemangioma

All of the animal experiments were approved by the institutional animal care and use committee (protocol no. 17821). We used mouse hemangioendothelioma (EOMA) cells (American Type Culture Collection, Manassas, Va.) to establish an easily reproducible animal model for infantile hemangioma based on a previous article.¹⁷ We intradermally injected 1.5×10^6 EOMA cells to bilateral dorsal axillary regions of 5-week-old, female nude mice ($n = 7$) and followed up the tumor growth by digital caliper measurements every other day. We calculated the tumor volume based on these measurements using the following formula: Volume = (Width² × Length)/2. We killed the mice when the largest diameter of the tumor reached 1 cm. We also performed hematoxylin and eosin and immunofluorescence staining to demonstrate the highly vascular structure of hemangioendothelioma tumors. Briefly, hemangioendothelioma tumors were fixed with 4% paraformaldehyde, embedded in paraffin blocks, and cut into 5- μ m sections. The sections were incubated with a primary antibody for CD31 (Novus Biologicals, San Diego, Calif.) overnight at 4°C. Anti-rat Texas red (Invitrogen, Eugene, Ore.) was used as a secondary antibody. The nuclei were counterstained with 4',6-diamidino-2-phenylindole (Vector Laboratories, Burlingame, Calif.), and the images were captured under a fluorescence microscope.

Positron Emission Tomographic Imaging of Hemangioendotheliomas Using Nanoporphyrim

To obtain maximum efficacy from photodynamic therapy, high levels of photosensitizer accumulation in the target tissue are crucial. To demonstrate nanoporphyrim accumulation in hemangioendotheliomas, we performed positron emission tomographic imaging on hemangioendothelioma-bearing nude mice ($n = 3$). We induced hemangioendothelioma formation by means of intradermal injection of EOMA cells, and nanoporphyrim were synthesized as described previously.¹³

When hemangioendothelioma reached a volume of 500 mm³, we injected the mice with copper-64-labeled nanoporphyrin (800 µCi/2 mg) through the tail vein and obtained images using a positron emission tomography/computed tomography scanner (Inveon DPET; Siemens, Knoxville, Tenn.) at 3, 6, 24, and 48 hours after injection. A computed tomographic image was also acquired at 24 hours after injection for registration to the corresponding positron emission tomographic image. We performed an *ex vivo* biodistribution study at 48 hours after injection after the final positron emission tomographic scan. We killed the animals ($n = 3$) and excised the hemangioendotheliomas and major organs to measure the radioactivity level of the organs with a gamma counter (PerkinElmer, Waltham, Mass.). We quantified positron emission tomographic images by region-of-interest analysis and expressed the results as percentage injected dose per gram of tissue.

Treatment of Hemangioendotheliomas with Photodynamic Therapy

We randomized female nude mice bearing hemangioendotheliomas ($n = 9$) into three groups ($n = 3$ each) (Table 1). Animals in the control group (group I) received only phosphate-buffered saline injections through the tail vein. Animals in group II received only near-infrared laser treatment after phosphate-buffered saline injection through the tail vein, and animals in group III received near-infrared laser treatment after nanoporphyrin injection through the tail vein (nanoporphyrin-delivered photodynamic therapy) on day 11 after tumor inoculation. For photodynamic therapy, we illuminated hemangioendotheliomas with near-infrared laser for 2 minutes at 0.8-W power following injection of 200 µl nanoporphyrin solution at a concentration of 10 mg/ml. We followed up the treatment response by digital caliper measurements.

RESULTS

Animal Model for Infantile Hemangioma

We were able to induce reliable hemangioendothelioma growth by intradermal injection

of mouse hemangioendothelioma cells (Fig. 1, *above, left*). Hemangioendothelioma growth commenced 1 week subsequent to injection, and the tumors continued growth until day 21 after injection, when animals were humanely killed because of increased tumor size. Tumors showed accelerated growth rates after day 19 that may correlate with the “proliferative phase” noted in human infantile hemangiomas (Fig. 1, *above, right*). Hemangioendotheliomas were located superficially, and untreated tumors led to ulcer formation like human infantile hemangiomas. (See Figure, Supplemental Digital Content 1, which shows the ulceration on an untreated hemangioendothelioma suggesting the superficial location of the tumor and skin involvement, <http://links.lww.com/PRS/B782>.) We did not observe tumor invasion to the underlying tissue layers in any of the animals. CD31 immunofluorescence and hematoxylin and eosin staining demonstrated the highly vascular characteristic structure of the tumor resembling human infantile hemangiomas (Fig. 1, *below*).

Positron Emission Tomographic Imaging of Hemangioendotheliomas Using Nanoporphyrin

A significant fraction of the injected dose of copper-64-labeled nanoporphyrin accumulated in hemangioendotheliomas. Nanoporphyrin accumulation peaked as early as 3 hours after injection (19.8 ± 2.2 percent injected dose per gram of tissue), with levels remaining high until 6 hours after injection (16.7 ± 2.0 percent injected dose per gram of tissue). The uptake in hemangioendotheliomas decreased to 8.4 ± 0.3 percent injected dose per gram of tissue at 24 hours after injection and 4.9 ± 0.6 percent injected dose per gram of tissue at 48 hours after injection (Fig. 2, *above and below, left*). Nanoporphyrin uptake in liver was 14.8 ± 0.7 , 13.0 ± 1.0 , 5.5 ± 0.5 , and 1.4 ± 0.1 percent injected dose per gram of tissue at 3, 6, 24, and 48 hours after injection, respectively (Fig. 2, *above and below, left*). The accumulation in liver was expected because nanoporphyrin in blood circulation was carried to liver for metabolism. However, we believe that the uptake in heart (23.6 ± 1.2 , 17.4 ± 0.9 , 2.1 ± 0.2 , and 0.1 ± 0.03 percent injected dose per gram of tissue at 3, 6, 24, and 48 hours, respectively) was attributable to nanoporphyrin circulating in blood rather than myocardial uptake because a similar level of uptake was observed in aorta on positron emission tomographic images 3 hours after injection. The uptake in right hemangioendotheliomas

Table 1. Study Groups

Group	Description
I	No treatment
II	NIRL treatment
III	NP injection followed by NIRL treatment (PDT)

NIRL, near-infrared laser; NP, nanoporphyrin; PDT, photodynamic therapy.

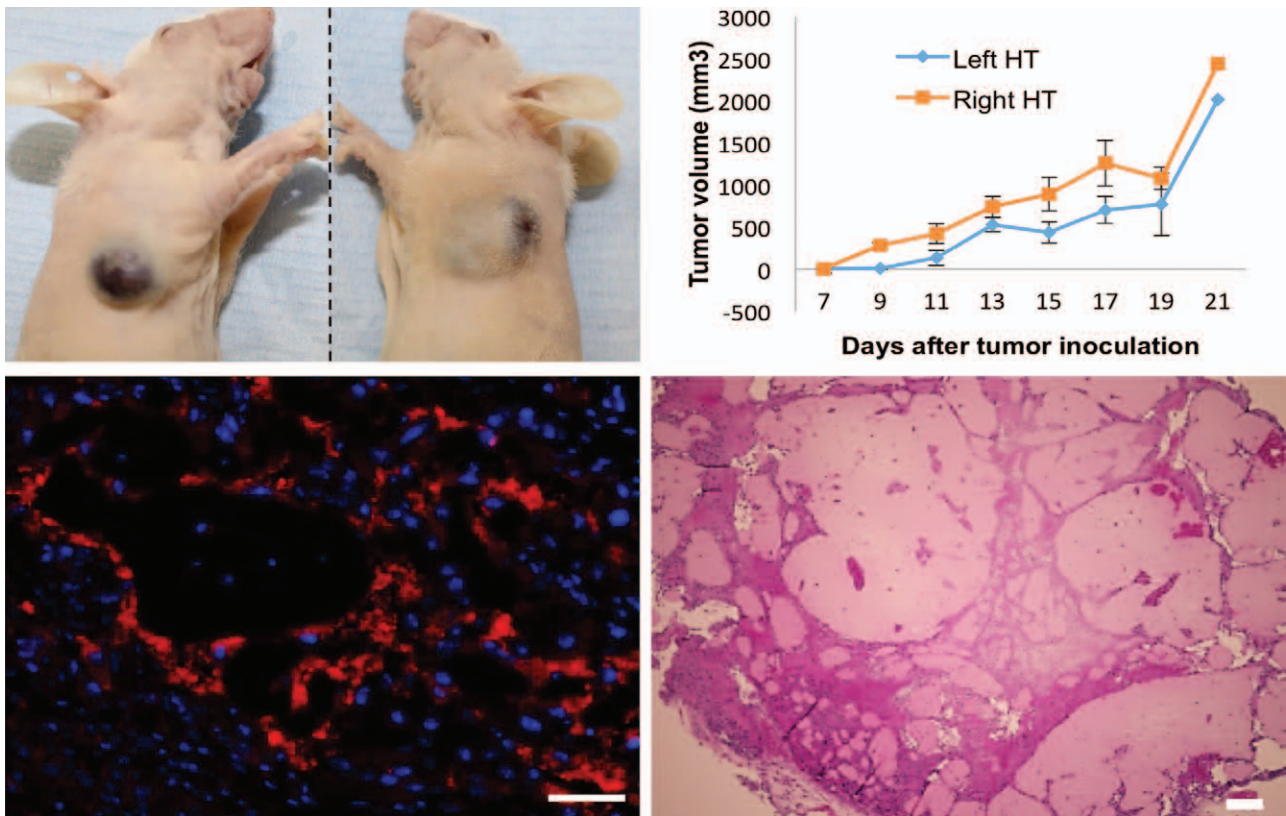


Fig. 1. (Above, left) The hemangioendotheliomas in the bilateral axillary region of nude mice 14 days after injection. (Above, right) The growth curve of the tumors in the axillary region. Errors bars = SD. HT, hemangioendothelioma. (Below) CD31 immunofluorescence and hematoxylin and eosin staining showing the vessels within the hemangioendothelioma. Microbars = 50 and 200 μ m, respectively.

was significantly higher than in blood at 24 and 48 hours after injection ($p < 0.05$ and $p < 0.01$, respectively), and higher than in liver at 48 hours after injection ($p < 0.05$). The uptake in left hemangioendotheliomas was significantly higher than in blood 24 and 48 hours after injection ($p < 0.05$). Nanoporphyrin uptake in other major organs was negligible. The uptake on positron emission tomographic imaging overlapped well with the location of hemangioendotheliomas on computed tomographic images (Fig. 2, below, right). Ex vivo biodistribution study revealed an average uptake of 0.3 ± 0.03 , 1.9 ± 2.28 , 0.8 ± 0.42 , 0.1 ± 0.01 , and 1.00 percent injected dose per gram of tissue in left hemangioendothelioma, right hemangioendothelioma, liver, heart, and spleen, respectively, 48 hours after injection (Fig. 3). The highest average uptake was in right hemangioendothelioma; however, the difference between the uptake in right hemangioendothelioma and other organs was not significant and most likely was caused by the wide range of values and resultant high standard deviation. In contrast, there was a significant difference between the uptake in spleen and other organs, including left hemangioendothelioma

($p < 0.01$ for brain, heart, lung, and muscle; and $p < 0.05$ for kidney, left hemangioendothelioma, and small intestine). There was also a significant difference between the uptake in liver and brain, heart, lung, and muscle ($p < 0.05$).

Treatment of Hemangioendotheliomas with Photodynamic Therapy

Hemangioendotheliomas in group III started to regress as early as the next day after treatment and totally disappeared on day 21 after inoculation (Fig. 4). Hemangioendotheliomas in group II showed variable response to treatment. Smaller tumors regressed the next day after treatment but started to regrow afterward, whereas the largest tumors showed limited response and kept growing (Fig. 4). In contrast, the hemangioendotheliomas in group I continued growth and the animals had to be killed on day 21 because of impairment of the vital functions by the growing hemangioendotheliomas. The tumor volumes in group III were significantly less than in groups I and II on day 21 ($p < 0.05$) and significantly less than in group I on day 17 ($p < 0.05$).

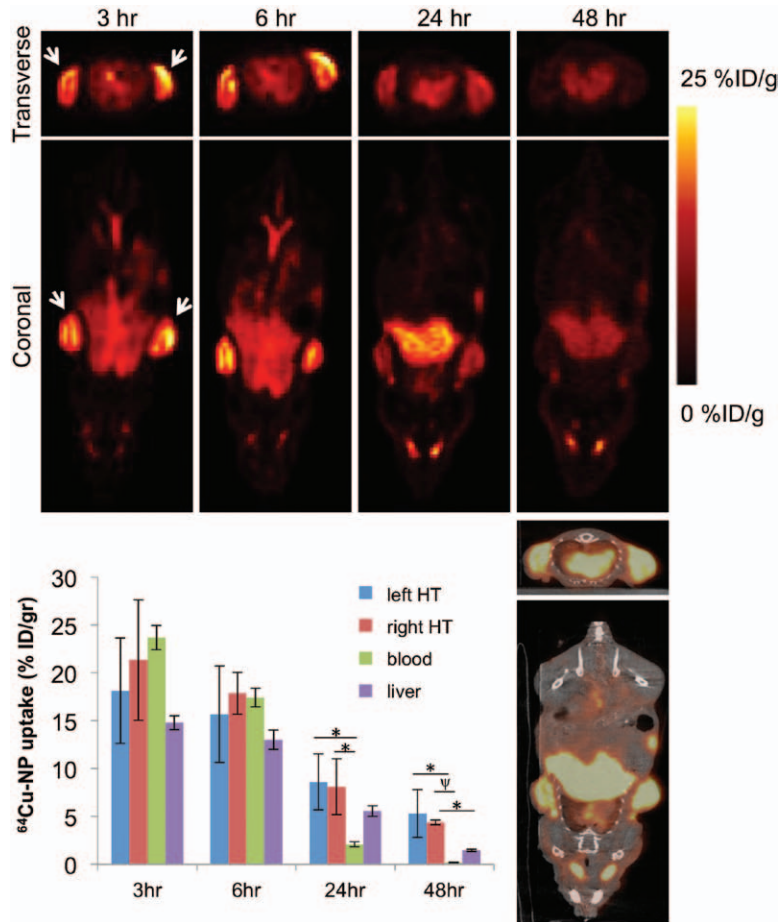


Fig. 2. (Above) Representative positron emission tomographic images at different time points after the injection of copper-64–labeled nanoporphyrin ($^{64}\text{Cu-NP}$). The uptake was highest at 3 and 6 hours after injection. White arrows point to the hemangioendotheliomas. (Below, left) Graph showing the average uptake of copper-64–labeled nanoporphyrin in hemangioendotheliomas, blood, and liver (percentage injected dose per gram of tissue) of all animals as determined by region-of-interest measurements on the positron emission tomographic images. Errors bars = SD. (Below, right) Positron emission tomographic signal overlapped perfectly with the hemangioendothelioma on positron emission tomographic/computed tomographic images obtained 24 hours after injection (* $p < 0.05$, $\psi p < 0.01$). HT, hemangioendothelioma; ID, injected dose.

DISCUSSION

The currently accepted approach to the treatment of infantile hemangiomas is to manage uncomplicated cases with expectant treatment. Treatment should be attempted if complications occur or if the infantile hemangioma grows substantially to block vital organs.^{18,19} Up to 38 percent of infantile hemangiomas referred to tertiary care specialists require systemic treatment because of complications.⁷ Systemic corticosteroids have been the historical mainstay of pharmacologic treatment of persistent infantile

hemangiomas. However, response to treatment is variable and adverse effects are common.^{1,7,8} Conventional laser treatment (e.g., pulsed dye laser) is a well-established treatment for other childhood vascular malformations. However, the use of pulsed dye laser to treat proliferating infantile hemangiomas remains controversial based on the likelihood of adverse outcomes (e.g., ulceration, scarring), and because of limited depth of penetration (<1 mm).^{3,7} Surgical excision remains the treatment of choice for smaller infantile hemangiomas, especially when there is threatened loss of

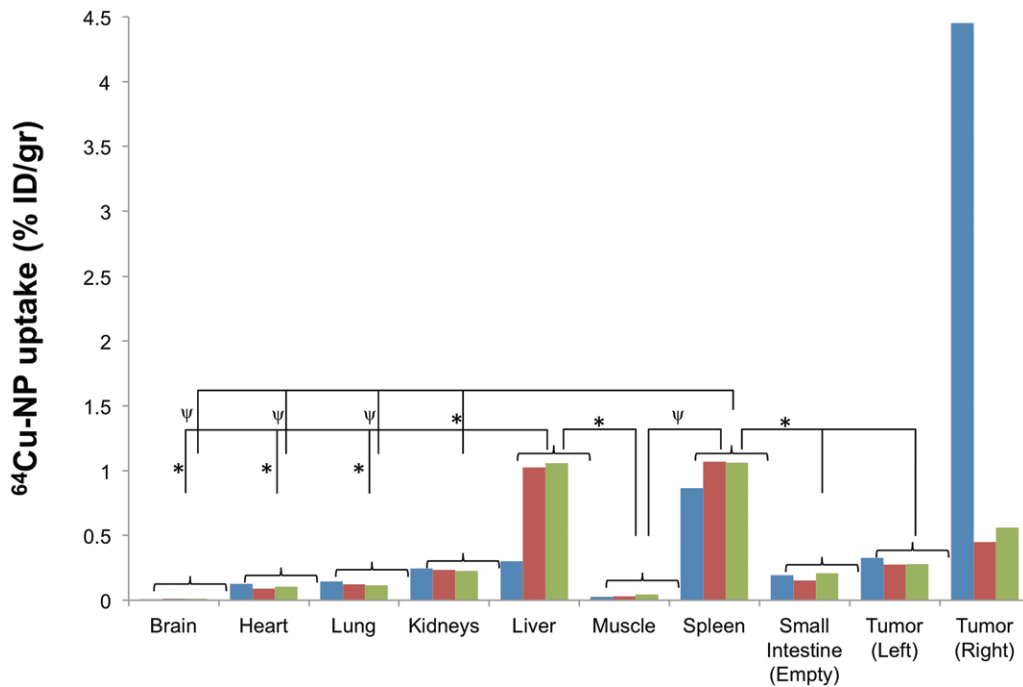


Fig. 3. Graph showing the result of an ex vivo biodistribution study performed 48 hours after copper-64-labeled nanoporphyrin (⁶⁴Cu-NP) injection. Animals were killed and major organs were collected. The radioactivity level in each organ was measured using a gamma counter. Colored bars in the graph represent the different animals (n = 3) from which the tissues were harvested. Errors bars = SD (*p < 0.05, ψp < 0.01).

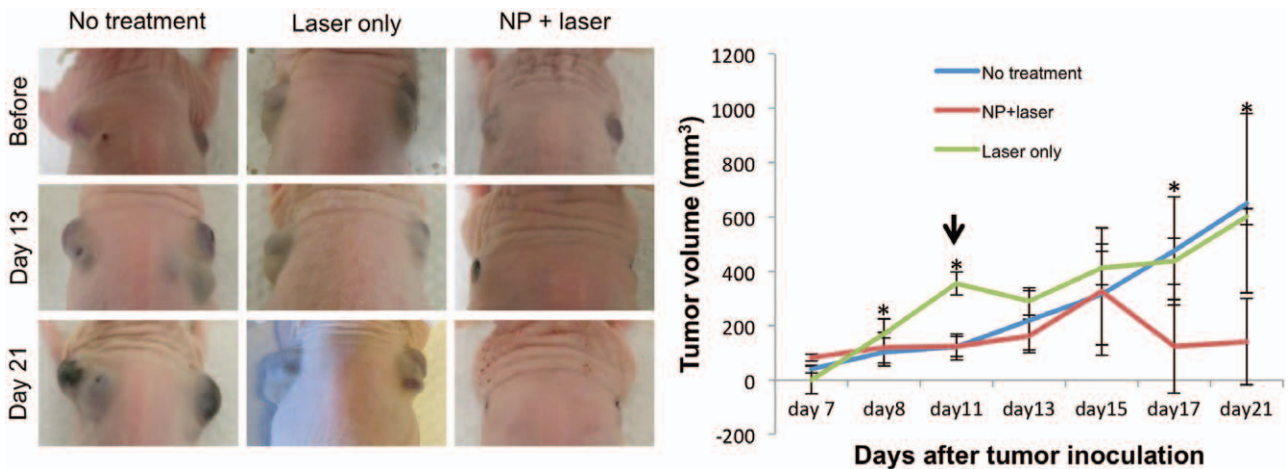


Fig. 4. (Left) Hemangioendotheliomas responded to treatment as early as day 1 after treatment in group III, whereas the hemangioendotheliomas in groups I and II continued to grow. (Right) Graph showing the volume changes of hemangioendotheliomas in the study groups after inoculation. Errors bars = SD (*p < 0.05, treatment). NP, nanoporphyrin.

function, life-threatening complications, or when drug therapy fails or is not tolerated.⁷

Propranolol, a beta-blocker typically used for cardiovascular disorders, has recently emerged as a useful therapeutic option for management of infantile hemangiomas as a first- and/or second-line treatment.^{20–22} A recent multicenter trial showed a success rate of 88 percent, with total cure in 60 percent of cases at doses of

3 mg/kg per day for 6 months.²⁰ However, only 55 patients were assigned to the placebo group (versus 405 patients enrolled in the propranolol treatment groups) and of 55, only 28 patients completed follow-up (versus 315 in the treatment groups). Therefore, there is a possibility that the striking difference between the sample sizes in this study might have created a bias toward the propranolol-treated groups. In addition, a

recent article reported a male infant who presented with infantile hemangioma even though his mother was receiving propranolol throughout pregnancy for the treatment of mild anxiety.²³ The boy presented with several episodes of symptomatic hypoglycemia (0.6 g/liter) at 3 days of age. Hypoglycemic episodes stopped after discontinuation of breastfeeding (at day 6 of age), and propranolol was considered to be responsible for the child's hypoglycemia in this case. It might have been hypothesized that treatment with propranolol, which crosses the placenta, in a pregnant woman could prevent the appearance of infantile hemangioma in her child, but this appears not to be the case in this patient. Furthermore, propranolol can cause a number of adverse effects, the most dangerous of which is symptomatic and potentially fatal hypoglycemia.^{24,25} Despite all the drawbacks and adverse effects of propranolol, Hemangeol (Pierre Fabre Pharmaceuticals, Inc., Parsippany, N.J.), a liquid preparation of propranolol, was approved by the U.S. Food and Drug Administration for the treatment of infantile hemangiomas and is the first drug to be approved for this indication.²⁶ Thus, it is now the gold standard in the treatment of infantile hemangiomas.

In this study, we addressed the limitations of propranolol treatment by using nanoporphyrin as a delivery vehicle for photodynamic therapy and potentially for propranolol. Nanoporphyrin is made of porphyrin that is naturally found in the human body (e.g., hemoglobin); therefore, it is significantly less toxic to normal cells and more biocompatible than the other inorganic nanoparticles such as gold and silica.¹³ As shown by positron emission tomographic imaging, nanoporphyrin selectively accumulated in hemangioendotheliomas at high levels by means of enhanced permeability and retention effect. This finding confirms that hemangioendothelioma vasculature is leaky, as we hypothesized. The high levels of nanoporphyrin in hemangioendotheliomas enabled a localized, high-efficacy treatment. Nanoporphyrin was activated only in hemangioendotheliomas with laser light illumination and remained inactive in other organs, limiting the systemic side effects of the treatment.²⁷ In addition, the near-infrared laser that we used in this study has an improved depth of penetration compared with conventional laser light (5 to 10 mm versus 1 mm).^{28,29} Increased depth of penetration combined with the superficial location of hemangioendotheliomas further increased the effectiveness of the treatment.

A limited number of clinical studies exist evaluating the use of photodynamic therapy as potential treatment for infantile hemangiomas and other vascular malformations. Photodynamic therapy was used for the treatment of port-wine stains with favorable results, and secondary scar formation was noted in only three of 238 patients, demonstrating the safety of the procedure.³⁰ In addition, a prospective evaluation of the outcomes following interstitial photodynamic therapy for patients with vascular anomalies, including infantile hemangiomas, provided evidence that photodynamic therapy is a successful modality in the management of these abnormalities that are resistant to conventional modalities, with minimal side effects.¹² However, both of these studies were clinical studies, and neither of them had a systematic, basic science approach focusing on the drug pharmacokinetics and biodistribution such as we are presenting here. Moreover, considering the favorable chemical properties of nanoporphyrin and the deeper penetration of near-infrared laser, we believe that the treatment we used in this study will be more effective in the clinical treatment of infantile hemangiomas.

The current study has several limitations. The hemangioendothelioma model in nude mice does not reflect exactly the same biological behavior that occurs in human infantile hemangiomas. For example, mouse hemangioendothelioma cell line–originated hemangioendotheliomas did not show the spontaneous regression that is frequently seen in human infantile hemangiomas. In contrast, histologic characteristics (most importantly, highly vascular nature, and hyperproliferation of the vessels) were similar to those of infantile hemangiomas. These histologic characteristics enabled the selective accumulation of nanoporphyrin in hemangioendotheliomas, and they are critical for the success of the proposed treatment and nanoporphyrin. Because infantile hemangiomas are also highly vascular tumors, there is a strong possibility that the biodistribution of nanoporphyrin will be similar in infantile hemangiomas.

CONCLUSIONS

Systemic injection of nanoporphyrin carrier leads to selective accumulation in our vascular cutaneous tumor model, predisposing the tumors to successful ablation by photodynamic therapy. These data strongly suggest that nanoporphyrin-mediated photodynamic therapy can be an effective treatment for infantile hemangiomas and will lay the groundwork for future studies using more clinically relevant animal models.

Hakan Orbay, M.D., Ph.D.

Division of Plastic Surgery
University of California, Davis Medical Center
4625 2nd Avenue, Room 3001
Sacramento, Calif. 95817
horbay@ucdavis.edu

ACKNOWLEDGMENTS

This work was supported by funds from the Department of Surgery, University of California–Davis Medical Center, and partly by the University of California–Davis Center for Molecular and Genomic Imaging Pilot Study Funds. The authors thank Jennifer Y. Fung and Charles M. Smith from the University of California, Davis Center for Molecular and Genomic Imaging for technical assistance.

REFERENCES

- Holland KE, Drolet BA. Approach to the patient with an infantile hemangioma. *Dermatol Clin*. 2013;31:289–301.
- Faustini K, Lam JM. Five things to know about infantile hemangiomas. *CMAJ* 2013;185:586.
- Chen TS, Eichenfield LF, Friedlander SF. Infantile hemangiomas: An update on pathogenesis and therapy. *Pediatrics* 2013;131:99–108.
- Kilcline C, Frieden IJ. Infantile hemangiomas: How common are they? A systematic review of the medical literature. *Pediatr Dermatol*. 2008;25:168–173.
- Itinteang T, Withers AH, Leadbitter P, Day DJ, Tan ST. Pharmacologic therapies for infantile hemangioma: Is there a rational basis? *Plast Reconstr Surg*. 2011;128:499–507.
- Neri I, Balestri R, Patrizi A. Hemangiomas: New insight and medical treatment. *Dermatol Ther*. 2012;25:322–334.
- Holland KE, Drolet BA. Infantile hemangioma. *Pediatr Clin North Am*. 2010;57:1069–1083.
- Greene AK. Management of hemangiomas and other vascular tumors. *Clin Plast Surg*. 2011;38:45–63.
- Castano AP, Mroz P, Hamblin MR. Photodynamic therapy and anti-tumour immunity. *Nat Rev Cancer* 2006;6:535–545.
- Darlenski R, Fluhr JW. Photodynamic therapy in dermatology: Past, present, and future. *J Biomed Opt*. 2013;18:061208.
- Green B, Cobb AR, Hopper C. Photodynamic therapy in the management of lesions of the head and neck. *Br J Oral Maxillofac Surg*. 2013;51:283–287.
- Jerjes W, Upile T, Hamdoon Z, et al. Interstitial PDT for vascular anomalies. *Lasers Surg Med*. 2011;43:357–365.
- Li Y, Lin TY, Luo Y, et al. A smart and versatile theranostic nanomedicine platform based on nanoporphyrin. *Nat Commun*. 2014;5:4712.
- Lee J, Lam KS. Perspectives on clinical translation of smart nanotherapeutics. *Ther Deliv*. 2012;3:1359–1362.
- Alexander-Bryant AA, Vanden Berg-Foels WS, Wen X. Bioengineering strategies for designing targeted cancer therapies. *Adv Cancer Res*. 2013;118:1–59.
- Aina OH, Sroka TC, Chen ML, Lam KS. Therapeutic cancer targeting peptides. *Biopolymers* 2002;66:184–199.
- Roomi MW, Kalinovsky T, Niedzwiecki A, Rath M. Antiangiogenic properties of a nutrient mixture in a model of hemangioma. *Exp Oncol*. 2009;31:214–219.
- Azzopardi S, Wright TC. Novel strategies for managing infantile hemangiomas: A review. *Ann Plast Surg*. 2012;68:226–228.
- Hochman M, Adams DM, Reeves TD. Current knowledge and management of vascular anomalies: I. Hemangiomas. *Arch Facial Plast Surg*. 2011;13:145–151.
- Léauté-Labrèze C, Hoeger P, Mazereeuw-Hautier J, et al. A randomized, controlled trial of oral propranolol in infantile hemangioma. *N Engl J Med*. 2015;372:735–746.
- Starkey E, Shahidullah H. Propranolol for infantile haemangiomas: A review. *Arch Dis Child*. 2011;96:890–893.
- Léauté-Labrèze C, Dumas de la Roque E, Hubiche T, Boralevi F, Thambo JB, Taïeb A. Propranolol for severe hemangiomas of infancy. *N Engl J Med*. 2008;358:2649–2651.
- Mechineaud M, Nicaise D, Martin L. Haemangioma in an infant whose mother was receiving long-term propranolol treatment during pregnancy. *Br J Dermatol*. 2015;174:464.
- Sans V, de la Roque ED, Berge J, et al. Propranolol for severe infantile hemangiomas: Follow-up report. *Pediatrics* 2009;124:e423–e431.
- Buckmiller L, Dyamenahalli U, Richter GT. Propranolol for airway hemangiomas: Case report of novel treatment. *Laryngoscope* 2009;119:2051–2054.
- Bayart CB, Brandling-Bennett HA. Beta-blockers for childhood vascular tumors. *Curr Opin Pediatr*. 2015;27:454–459.
- Sheng N, Zong S, Cao W, Jiang J, Wang Z, Cui Y. Water dispersible and biocompatible porphyrin-based nanospheres for biophotonics applications: A novel surfactant and polyelectrolyte-based fabrication strategy for modifying hydrophobic porphyrins. *ACS Appl Mater Interfaces* 2015;7:19718–19725.
- Yuan A, Wu J, Tang X, Zhao L, Xu F, Hu Y. Application of near-infrared dyes for tumor imaging, photothermal, and photodynamic therapies. *J Pharm Sci*. 2013;102:6–28.
- Sevick-Muraca EM. Translation of near-infrared fluorescence imaging technologies: Emerging clinical applications. *Annu Rev Med*. 2012;63:217–231.
- Qin ZP, Li KL, Ren L, Liu XJ. Photodynamic therapy of port wine stains: A report of 238 cases. *Photodiagnosis Photodyn Ther*. 2007;4:53–59.