

UC Irvine

UC Irvine Previously Published Works

Title

Unilateral absence of pulmonary artery and azygous continuation of interrupted inferior vena cava.

Permalink

<https://escholarship.org/uc/item/16c1h9st>

Journal

Radiology case reports, 15(6)

ISSN

1930-0433

Authors

Bista, Biraj
Ferris, Julie
Na, Nu
[et al.](#)

Publication Date

2020-06-01

DOI

10.1016/j.radcr.2020.02.021

Peer reviewed

Available online at www.sciencedirect.com

ScienceDirect

journal homepage: www.elsevier.com/locate/radcr

Case Report

Unilateral absence of pulmonary artery and azygous continuation of interrupted inferior vena cava

Biraj Bista, MD*, Julie Ferris, BS, BA, Nu Na, MD, Mayil Krishnam, MD, Deniz Urgan, MD

Division of Cardiovascular and Thoracic Imaging; Department of Radiology, University of California, 101 The City Drive South, Route 140, Irvine, CA 92868, USA

ARTICLE INFO

Article history:

Received 3 February 2020

Revised 18 February 2020

Accepted 20 February 2020

Keywords:

Unilateral absence of pulmonary artery (UAPA)

Azygous vein

Interrupted IVC

Deep vein thrombosis

ABSTRACT

Unilateral absence of pulmonary artery is a rare developmental anomaly. Infrahepatic inferior vena cava interruption is a well-recognized but uncommon developmental anomaly. Presence of both these anomalies in a single individual is extremely rare. A 58-year-old man with a history of recurrent lower extremity deep vein thrombosis and venous insufficiency presented to our emergency department with bilateral calf pain and swelling. Ultrasound demonstrated extensive deep vein thrombosis throughout bilateral lower extremities. Computed tomography angiography showed smooth tapering of the right pulmonary artery with absent distal most segment. To our knowledge, there is only 1 case report in the literature so far with both the abnormalities present in a single individual.

© 2020 The Authors. Published by Elsevier Inc. on behalf of University of Washington.

This is an open access article under the CC BY-NC-ND license.

(<http://creativecommons.org/licenses/by-nc-nd/4.0/>)

Introduction

Unilateral absence of pulmonary artery (UAPA) is a rare congenital abnormality caused by the failure of the sixth aortic arch to connect with the pulmonary trunk during the embryologic development [1–3]. Intrapulmonary vessels and the distal portion of the affected pulmonary artery trunk can develop normally, and blood supply is achieved by systemic collaterals from bronchial, major aortopulmonary collaterals and other systemic arteries [2,4]. In most patients, UAPA is associated with other cardiovascular congenital abnormalities such as tetralogy of Fallot, arterial septal defect, and truncus arteriosus [2]. It is usually diagnosed in infancy or childhood

due to symptoms related to other associated cardiovascular abnormalities. Few patients who remain asymptomatic until adulthood can present later with recurrent respiratory infections, dyspnea on exertion, high-altitude pulmonary edema, pulmonary hypertension in the contralateral lung, or hemoptysis [1].

Interruption of the inferior vena cava (IVC) results from agenesis of a segment of the IVC or a fusion defect between the prerenal and hepatic segment of the IVC. Its prevalence is 0.6–2.0% in patients with congenital heart disease [4,5]. It results in termination of the IVC below the hepatic vein. The infrahepatic IVC may continue as the azygos vein or may continue as the hemiazygos vein to the left SVC, intrathoracic veins, or anomalous intrahepatic veins [2,3]. The hepatic seg-

* Corresponding author.

E-mail addresses: bbista@hs.uci.edu (B. Bista), jferris1@hs.uci.edu (J. Ferris), nanr@uci.edu (N. Na), mkrishn@uci.edu (M. Krishnam), hakayurg@hs.uci.edu (D. Urgan).<https://doi.org/10.1016/j.radcr.2020.02.021>1930-0433/© 2020 The Authors. Published by Elsevier Inc. on behalf of University of Washington. This is an open access article under the CC BY-NC-ND license. (<http://creativecommons.org/licenses/by-nc-nd/4.0/>)

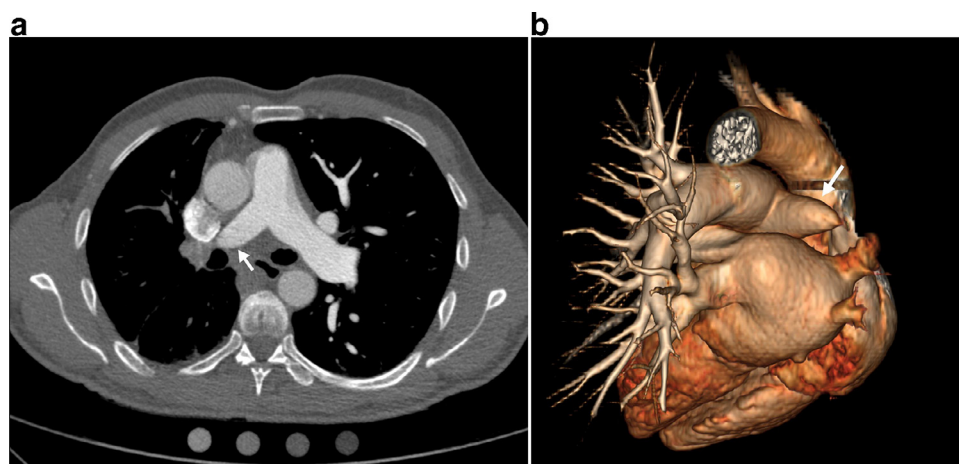


Fig. 1 – (A) Smooth tapering of the right main pulmonary artery with absent distal segment. (B) 3D volume rendered image (posterior view) showing smooth tapering of the right main pulmonary artery with absent distal segment.

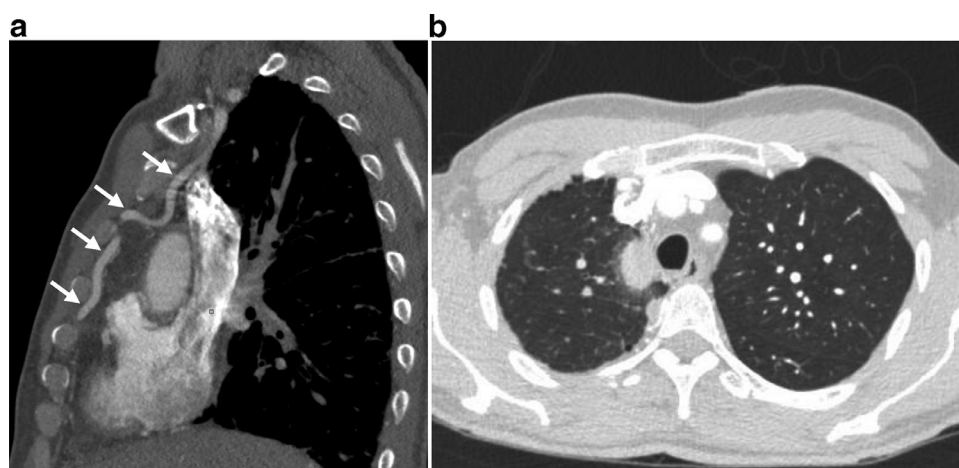


Fig. 2 – (A) Enlarged right internal mammary artery as a major collateral supply for right lung. (B) Thickened right pleura as evidence of additional systemic to pulmonary shunt.

ment of the IVC drains directly into the right atrium. In small percentage of people, interrupted IVC with azygous continuation is known to cause recurrent deep venous thrombosis of the lower limbs, sick sinus syndrome and atrial flutter [1,4].

Case report

A 58-year-old man with a history of recurrent lower extremity deep vein thrombosis (DVT) and venous insufficiency presented to the emergency department with bilateral calf pain and swelling. Ultrasound demonstrated extensive DVTs throughout bilateral lower extremities. Computed tomography angiography showed no pulmonary emboli, but demonstrated smooth tapering of the right main pulmonary artery and paucity of right intrapulmonary arteries. (Fig. 1A, and B). The left pulmonary artery was dilated while the pulmonary trunk measured within normal limits. The left lung showed compensatory hyperinflation. Dilated right internal mam-

mary and right bronchial arteries were present as main aortopulmonary collaterals (Fig. 2A). Thickened right pleura showed evidence of additional systemic to pulmonary shunt (Fig. 2B). Incidental note was made of dilated azygos vein draining an interrupted IVC to the superior vena cava (Fig. 3A and b). Aortic arch was left sided and no other cardiovascular abnormality was seen.

Discussion

UAPA and azygos continuation of the IVC are rare congenital anomalies [1,2,4]. To our knowledge, this is the second case reported where both the anomalies are present in a single individual. Our patient did not have any other congenital cardiovascular anomalies like tetralogy of Fallot, arterial septal defect, and truncus arteriosus which are usually associated with unilateral pulmonary artery agenesis [2,3]. Patient did not endorse any common symptoms of UAPA such

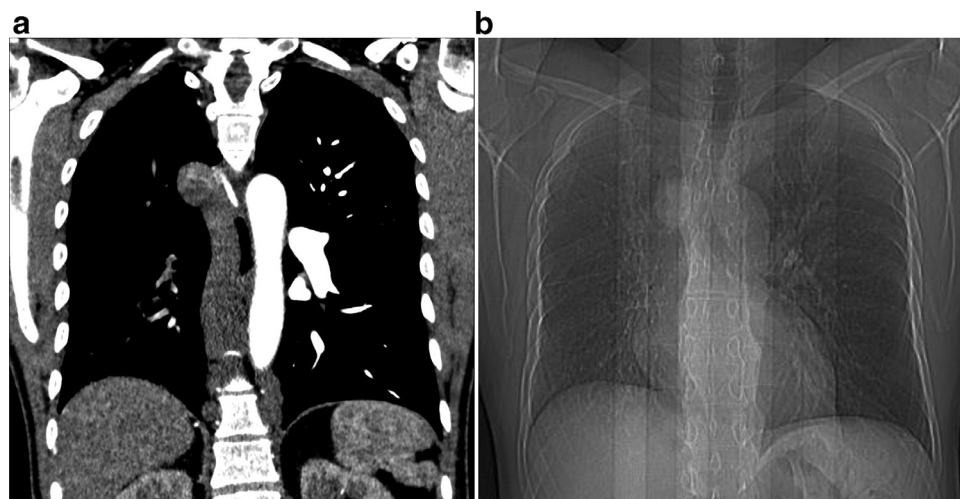


Fig. 3 – (A) Enlarged azygous vein as a continuation of interrupted infrahepatic IVC draining into SVC. (B) CT scanogram demonstrates enlarged azygous vein seen to the right of trachea, smaller right lung and right hilum.

as respiratory infections, dyspnea on exertion, high-altitude pulmonary edema, or hemoptysis. Rather patient presented with bilateral calf pain and swelling with a history of recurrent lower extremity DVTs and venous insufficiency. CT findings of both UAPA and interrupted IVC with azygous continuation were incidental. Interrupted IVC with azygous continuation is known to cause recurrent, unprovoked DVTs and venous insufficiency, possibly because the dilated vena azygos system cannot drain the lower limbs adequately [4]. This anomaly may be present in 5% of cases of idiopathic DVT in patients under 30 years [4,5]. Our patient had no other risk factors for DVT or venous insufficiency and interrupted IVC may be the potential cause. No known association of UAPA and azygous continuation of an interrupted IVC was found in literature. Awareness of the systemic collaterals in UAPA patients is important for ensuring the accurate selective embolization of bleeding vessels. Presence of interrupted IVC poses more problem in patients with UAPA during invasive procedures, such as right heart catheterization procedures, electrophysiological procedures, IVC filter placement, temporary pacing through the transfemoral route, and abdominal or thoracic surgery if need arises.

Knowledge of interrupted IVC with azygous continuation in a patient with UAPA is important before interventional or

surgical procedures. In conclusion, we describe a unique case of 2 rare congenital anomalies occurring in a single individual, their radiological findings and potential management challenges.

REFERENCES

- [1] Avcı BK, Karadağ B, Tüzün H, Öngen Z. Unilateral absence of the left pulmonary artery with patent ductus arteriosus and interrupted inferior vena cava. *Turk Kardiyol Dern Ars* 2014;42(4):399–402.
- [2] Wang P, et al. Isolated unilateral absence of pulmonary artery in adulthood: a clinical analysis of 65 cases from a case series and systematic review. *J Thorac Dis* 2017;9(12):4988–96.
- [3] Pfefferkorn JR, Loser H, Pech G, et al. Absent pulmonary artery: a hint to its embryogenesis. *Pediatr Cardiol* 1982;3:283–6.
- [4] Ruggeri M, et al. Congenital absence of the inferior vena cava: a rare risk factor for idiopathic deep-vein thrombosis. *The Lancet* 2001;357(9254):441–441.
- [5] Timmers GJ, Falke TH, Rauwerda JA, Huijgens PC. Deep vein thrombosis as a presenting symptom of congenital interruption of the inferior vena cava. *Int J Clin Pract* 1999;53:75–6.