

# UC Irvine

## UC Irvine Previously Published Works

### Title

Sinonasal Undifferentiated Carcinoma: A 15-Year Single Institution Experience.

### Permalink

<https://escholarship.org/uc/item/16g9f65z>

### Journal

Seminars in Neurosurgery, 80(1)

### ISSN

2193-6331

### Authors

Workman, Alan

Brody, Robert

Baranov, Esther

et al.

### Publication Date

2019-02-01

### DOI

10.1055/s-0038-1668537

Peer reviewed

# Sinonasal Undifferentiated Carcinoma: A 15-Year Single Institution Experience

Alan D. Workman<sup>1</sup> Robert M. Brody<sup>1</sup> Edward C. Kuan<sup>1</sup> Esther Baranov<sup>2</sup> Steven G. Brooks<sup>1</sup>  
Michelle Alonso-Basanta<sup>3</sup> Jason G. Newman<sup>1</sup> Christopher H. Rassekh<sup>1</sup> Ara A. Chalian<sup>1</sup>  
Alexander G. Chiu<sup>1,4</sup> Gregory S. Weinstein<sup>1</sup> Michael D. Feldman<sup>2</sup> Nithin D. Adappa<sup>1</sup>  
Bert W. O'Malley Jr.<sup>1</sup> James N. Palmer<sup>1</sup>

<sup>1</sup>Department of Otorhinolaryngology – Head and Neck Surgery, University of Pennsylvania, Philadelphia, Pennsylvania, United States

<sup>2</sup>Department of Pathology, University of Pennsylvania, Philadelphia, Pennsylvania, United States

<sup>3</sup>Department of Radiation Oncology, University of Pennsylvania, Philadelphia, Pennsylvania, United States

<sup>4</sup>Department of Otolaryngology – Head and Neck Surgery, University of Kansas, Kansas City, Kansas, United States

Address for correspondence Alan D. Workman, MD, MTR, Department of Otorhinolaryngology – Head and Neck Surgery, Hospital of the University of Pennsylvania, Philadelphia, PA 19103, United States (e-mail: WorkmanA@pennmedicine.upenn.edu).

J Neurol Surg B 2019;80:88–95.

## Abstract

**Objective** Sinonasal undifferentiated carcinoma (SNUC) is an aggressive neoplasm, with conflicting existing literature regarding prognosis and treatment due to the rarity of disease. Characterization of optimal SNUC management is necessary for improved outcomes.

**Study Design** Case series with planned data collection and analysis.

**Setting** Hospital of the University of Pennsylvania and Pennsylvania Hospital.

**Participants** Patients with pathologically confirmed SNUC treated within a 15-year period were identified, and records were obtained and evaluated for several demographic characteristics.

**Main Outcomes Measures** Disease-specific survival from diagnosis was the primary endpoint, while disease recurrence was a secondary endpoint of the study.

**Results** Twenty-seven patients with established SNUC were included in this cohort, with a median age of 55 years. Eighty-five percent of patients were surgically treated, and 85% of patients presented with stage IV disease. Two-year disease-specific survival was 66% and 5-year disease-specific survival was 46%. Ninety-six percent of patients received both chemotherapy and radiation as adjuvant treatment. Nodal disease at presentation and disease recurrence both significantly decreased patient survival ( $p < 0.05$ ).

**Conclusions** The majority of patients at this institution presented with clinically advanced disease, and most were managed with a multimodal approach of surgical resection, chemotherapy, and radiation. Extent of disease at presentation and progression of disease following treatment are poor prognostic signs and may merit a more aggressive approach, while early detection and treatment may improve survival and decrease patient morbidity.

## Keywords

- ▶ SNUC
- ▶ sinonasal undifferentiated carcinoma
- ▶ survival
- ▶ treatment paradigms
- ▶ prognosis

received  
February 12, 2018  
accepted after revision  
July 12, 2018  
published online  
August 16, 2018

© 2019 Georg Thieme Verlag KG  
Stuttgart · New York

DOI <https://doi.org/10.1055/s-0038-1668537>.  
ISSN 2193-6331.

## Introduction

Sinonasal undifferentiated carcinoma (SNUC) is a rare, highly aggressive malignancy that lacks clearly defined treatment protocols and concrete stage-based survival data. Overall SNUC mortality rates are high, with 5-year survival ranging from 20 to 63% in the literature.<sup>1–8</sup> SNUC is extremely locally destructive,<sup>9</sup> frequently invading and eroding adjacent structures early on in the disease course.<sup>10</sup> Additionally, it most often presents at American Joint Committee on Cancer (AJCC) stage IV.<sup>1,3–6,8,11,12</sup> The reasons for advanced disease at presentation are multifactorial, but delay in diagnosis is a principal feature, as symptoms of SNUC are more readily attributed to benign causes early on.<sup>13–15</sup> Often, a patient with a locally advanced SNUC will present at evaluation for nasal congestion, sinusitis, or symptoms of facial pressure. The large potential space of the sinuses also offers an opportunity for unimpeded initial growth, further contributing to high preliminary T stage of the tumor.<sup>16</sup>

SNUC is a unique neoplasm, distinguished from esthesioneuroblastoma (ENB) by a lack of periodic Homer-Wright rosettes and intercellular fibrils commonly associated with ENB. It also differs from Epstein-Barr virus-related nasopharyngeal-type undifferentiated carcinoma, which is a distinct entity with superior outcomes.<sup>17</sup> There is also an overexpression of p16 in SNUC, related to human papillomavirus (HPV) infection in many, but not all, cases.<sup>18</sup> SNUC was previously described as an anaplastic malignancy, and it can be epithelial or nonepithelial in origin.<sup>11,19</sup> Treatment for SNUC is generally surgery, radiation, chemotherapy, or some combination of these modalities; a consensus on timing and sequence of treatment has not yet been established. Some studies have argued superiority of surgery alone, chemoradiation alone, or the use of neoadjuvant or adjuvant chemoradiation.<sup>5,17</sup> However, no uniform agreement on survival advantage with any particular treatment modality has been established.<sup>13</sup>

Several case series have been published since SNUC was first identified as an independent entity in 1986,<sup>11</sup> but the number of patients in each series is quite limited due to the infrequency of SNUC occurrence. This study, conducted at the University of Pennsylvania hospitals, is one of the largest single-institution case series to date, comprised of 27 patients over a 15-year period. It is our hope that this contribution to the literature will provide useful additional data for discerning optimal management and prognostication of this disease.

## Methods

### Patient Selection

Approval was obtained from the University of Pennsylvania Institutional Review Board for a retrospective cohort study of SNUC patients from January 1992 to December 2017 treated at the Hospital of the University of Pennsylvania or Pennsylvania Hospital. All patients were identified using pathology criteria from our internal pathology report database, and all available inpatient and outpatient records were obtained for

each patient. Records contained treatment reports from a multidisciplinary team at the University of Pennsylvania with an otolaryngologist, medical oncologist, radiation oncologist, and pathologist. In some cases, a neurosurgeon was also consulted. All patients that did not undergo surgical or medical management for SNUC with posttreatment follow-up at the University of Pennsylvania were excluded.

### Data Collection

Patient demographic characteristics, including age at diagnosis, gender, smoking and alcohol histories, and prior radiation treatment, were recorded. If tumor stage was provided in the clinical record in a radiology, radiation oncology, or otorhinolaryngology note then this was noted, otherwise tumors were staged using the guidelines provided by the AJCC based on available radiographic and clinical information. Orbital involvement and presence of neck metastasis at diagnosis were two additional factors obtained. When obtainable, tumor size was reported in centimeters in largest dimension.

Each patient in the data set underwent surgical, radiation, and/or chemotherapy treatment and was followed at the University of Pennsylvania as an outpatient for at least 2 years or until time of death. Surgical factors, including extent of resection, type of surgical approach, neurosurgical involvement, and intraoperative or postoperative complications, were recorded. Specific type of chemotherapy and/or radiation dose (in units Gray) was also recorded. Death was the primary examined outcome, but tumor recurrence, as assessed by imaging or endoscopy, was a secondary outcome.

### Statistical Analysis

Size of the data set precluded the use of robust statistical techniques to examine all independent variables on primary and secondary outcome measures, but patient- and disease-specific characteristics were examined to assess their effect on the primary outcome of disease-specific survival. Patients were censored from the Kaplan-Meier survival curve if lost to follow-up after 2 years. Statistical comparisons were performed using Cox proportional hazards modeling for assessing the effect of patient variables on survival. For outcome variables, statistical comparisons were performed using the log-rank Mantel-Cox test as appropriate. A value of  $p < 0.05$  was considered statistically significant. Statistical analyses were conducted using STATA 13 (Stata Corp, College Station, Texas, United States).

## Results

A total of 27 patients with SNUC were treated and followed at the Hospital of the University of Pennsylvania or Pennsylvania Hospital between 1992 and 2017. Demographic data for these patients, as well as tumor characteristics, are listed in ► **Table 1**. Examples of SNUC histopathology in this case series, including a positive cytokeratin stain and negative S100 protein and synaptophysin stains, can be seen in ► **Fig. 1**. A majority of patients (63%) were male, and a majority also had a history of smoking or regular alcohol

**Table 1** Patient and tumor characteristics

Patient characteristics	
Number of patients	27
Age at diagnosis (mean)	54.6 ± 12.2
Male gender	17 (63%)
Smoking history	17 (63%)
Alcohol history	16 (59%)
Prior radiation treatment	1 (4%)
Tumor characteristics	
TNM staging	
Stage I	0 (0%)
Stage II	1 (4%)
Stage III	3 (11%)
Stage IVA	9 (33%)
Stage IVB	11 (41%)
Stage IVC	3 (11%)
Orbital involvement	13 (48%)
Neck metastasis	9 (33%)

Abbreviation: TNM, tumor/node/metastasis.

consumption. The average age at diagnosis was 55 years, with an age range of 29 to 80 years. Notably, a preponderance of patients presented at stage IVA or greater, representing 85% of the cohort, while no patients presented with stage I disease. Approximately half of patients had orbital involvement at the time of diagnosis, and a third had documented nodal neck disease. The most common presenting symptoms were nasal obstruction and sinusitis, followed by epistaxis. Tumor size data was heterogeneous in nature and not reported in several cases, but in those with available information, the tumors were an average of 3.9 cm in greatest dimension.

Eighty-five percent of patients underwent primary surgical management (►Table 2), and half of the nonoperative patients had unresectable stage IVC disease. ►Fig. 2 shows a schematic diagram of patient treatment, from primary management to adjuvant therapies. A large majority of patients had an initial biopsy at an outside hospital, and were then referred to the University of Pennsylvania for further treatment. Cisplatin and carboplatin were by far the most commonly used chemotherapy agents. For radiation therapy, patients received a median dose of 63 Gy to the tumor site, with a range of 50 to 70 Gy for those completing the full course of radiation.

Within the surgical cohort, slightly over half of all patients had a gross total resection (GTR), and a similar proportion also had an exclusively endoscopic approach (►Table 2). Neurosurgery was involved in 43% of cases, most often due to dural involvement of the tumor. Surgical or postsurgical complications were present in four patients, comprised of two cerebrospinal fluid leaks, a necrotic free flap, and severe epistaxis. Four patients in the overall cohort

required orbital exenteration either during or after the primary surgery.

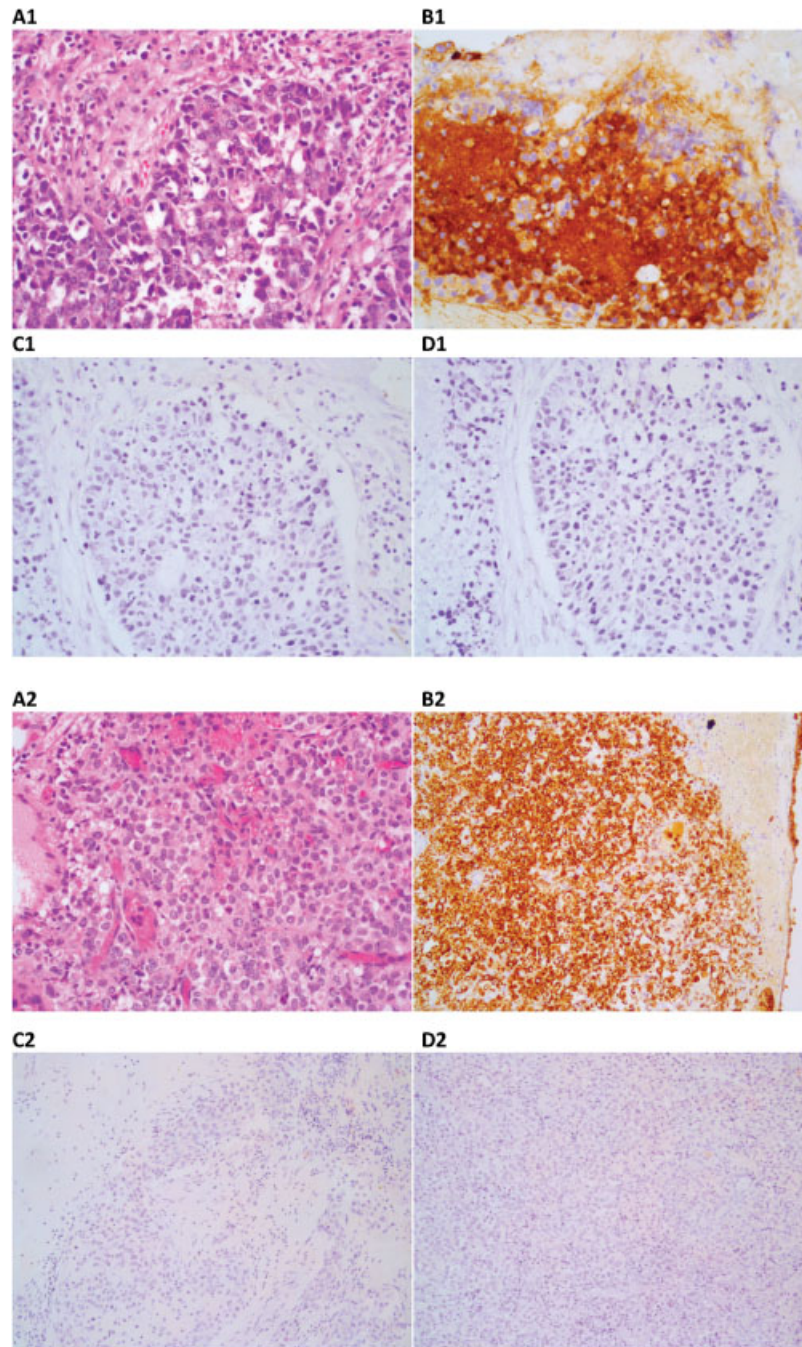
Disease-specific survival of both surgical and nonsurgical patients was 66% at 2 years and 46% at 5 years (►Fig. 3). Notably, disease-specific survival and overall survival were equivalent in our cohort. When examining seven patient and tumor characteristics for effects on survival (►Table 3), neck disease at presentation was associated with increased mortality ( $p < 0.05$ , hazard ratio, 4.5, 95% confidence interval, 1.04–19.2, ►Fig. 4); median survival of patients with neck disease was 20 months, compared with 126 months for individuals without initially positive neck nodes. The secondary outcome of disease recurrence was also independently associated with decreased survival ( $p < 0.01$ , log-rank Mantel–Cox test). Metastasis before or following treatment was associated with an especially poor median survival, with mortality in half of these patients in the 13 months following presentation.

## Discussion

This study is an overview and analysis of a 27-patient SNUC cohort, and is one of the largest single-institution case series published to date. SNUC is a highly aggressive and uncommon neoplasm, with incompletely defined prognostic indicators and treatment strategies. Most patients in this cohort presented with clinically advanced disease, and almost all were managed with a multimodality approach of surgical resection, chemotherapy, and radiation. Five-year overall and disease-specific survival was 46%, and neck disease at presentation and disease recurrence following treatment were associated with increased mortality.

To understand the data in our patient population, it is best presented in the context of other similar case series that have been published in the past 15 years. ►Table 4 presents a list of all United States SNUC case series in the literature that are comprised of greater than 10 patients, with data extracted and compared with this study. Several notable trends are apparent. Patient age is very similar among all cohorts, with presentation in the 5th decade of life. Percentage of patients presenting with T4 disease varies from two-thirds to almost all patients, corroborating what is known about the SNUC disease course.<sup>1,3–6,8,11,12</sup> Interestingly, our cohort had significantly higher levels of nodal disease at presentation than those reported at other United States institutions. The reasons for this discrepancy are unclear, but may partially account for the relatively high proportion of patients undergoing multimodality therapy with surgery, chemotherapy, and radiation at our institution. Furthermore, both our study and previous reports have identified nodal disease at presentation as a very poor prognostic indicator,<sup>24</sup> which has important implications for survival.<sup>1,3,5,6,10</sup> Despite this, 2- and 5-year survival in our subjects is comparable to the average of what has previously been reported.

Two meta-analyses and two national database reports have been published for SNUC in the past 5 years, and these provide important information that affects the evaluation



**Fig. 1** SNUC histopathology of two patients in the case series. (A1/2) Hematoxylin and eosin stain. (B1/2) Positive cytokeratin stain. (C1/2) Negative S100 stain. (D1/2) Negative synaptophysin stain.

and treatment of SNUC.<sup>1,25-27</sup> A meta-analysis by Reiersen et al in 2012 found that while only 20% of all patients treated for SNUC received surgery, radiation, and chemotherapy, a combination of any of these therapies was strictly superior in offering improved survival when compared with any single modality. Among the treatment modalities, surgery had the largest effect, while adjuvant therapy was most beneficial in patients with advanced local or neck disease. In the context of our current case series, 81% of our patients received all three therapies, and the available evidence points to aggressive multimodal management as the recommended

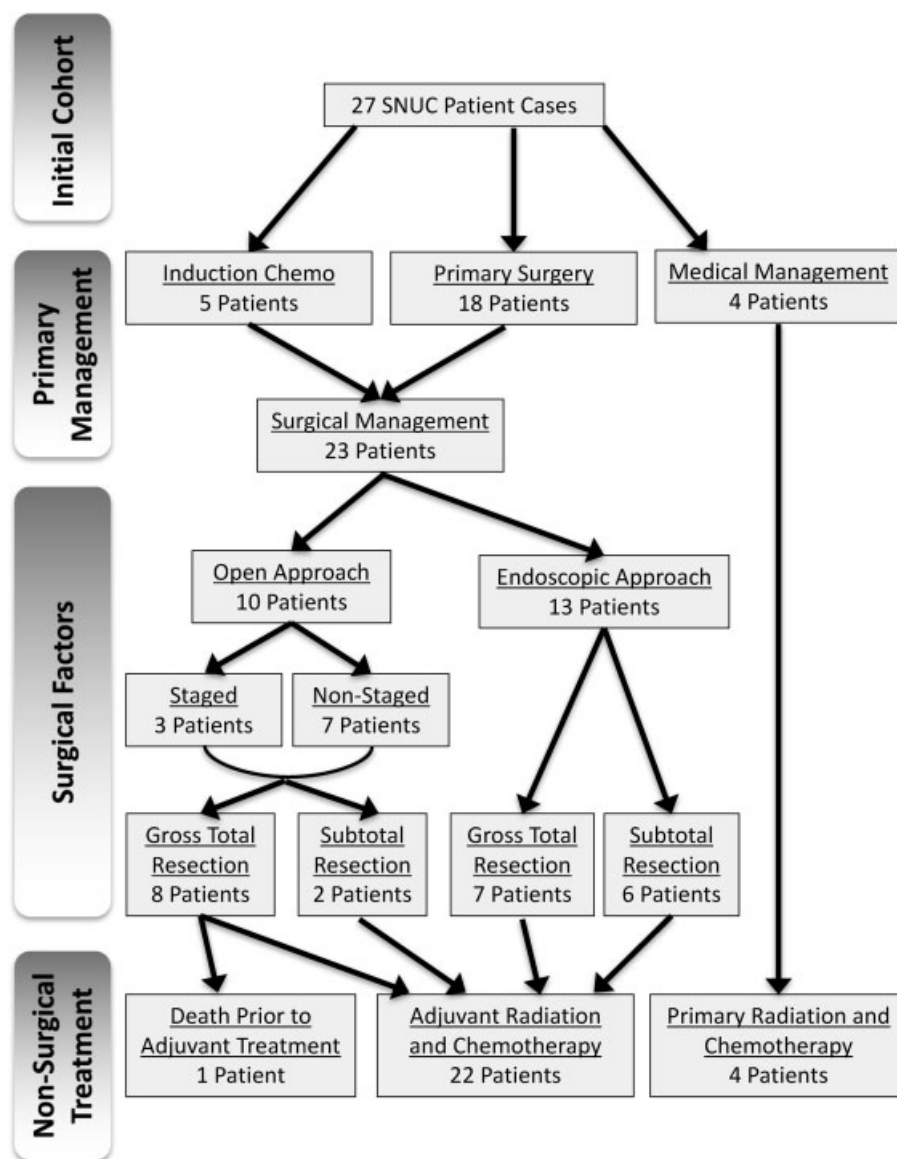
approach. Surgery, especially when GTR is achieved, is highly predictive of local disease control.<sup>28,29</sup> This is further corroborated by reports showing that 70% of patients with SNUC will still have viable tumor at surgical resection following chemoradiation, highlighting the insufficiency of nonsurgical management.<sup>4</sup>

While surgery is clearly a critical component of SNUC treatment, adjuvant therapy plays a demonstrable role. SNUC neoplasms tend to be microscopically invasive, and even negative margins should be further treated with radiation and chemotherapy. Cisplatin, 5-fluorouracil, and

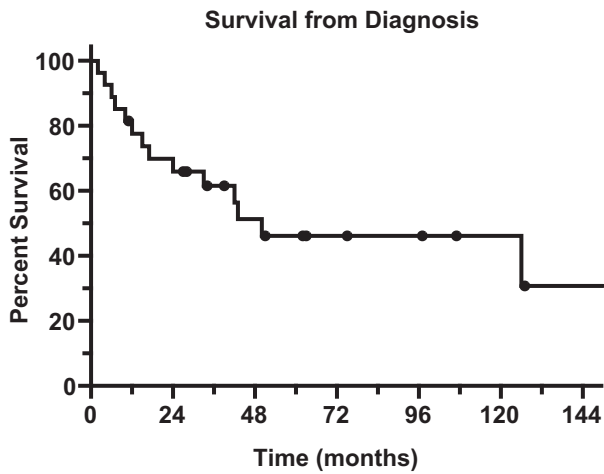
**Table 2** Treatment and outcomes

Treatment	
Surgery	23 (85%)
Gross total resection	13 (57%)
Endoscopic	13 (57%)
Comb. neurosurgical	10 (43%)
Complications	4 (17%)
Radiation	26 (96%)
Chemotherapy	26 (96%)
Outcomes	
Recurrence	14 (52%)
Distant metastasis	8 (30%)

paclitaxel have an overall response rate of 80% in SNUC,<sup>30</sup> and these are the most frequently used therapies in practice.<sup>16</sup> At our institution, cisplatin or carboplatin were the first line agents of choice. Mean radiation dose across the majority of studies is 63.9 Gy, comparable to the median value of 63 Gy in our cohort. Most radiation treatments given in our series were postsurgical, and radiation's role in downstaging patients prior to surgical treatment is still unclear. However, even in patients without demonstrated nodal disease at presentation, prophylactic neck irradiation has proven effective for preventing development of regional disease.<sup>12</sup> Once cervical lymphadenopathy is present on physical exam, greater than 90% of patients will have regional or distant metastases.<sup>1</sup> In considering SNUC management, clinicians must assess the need for elective prophylactic surgical or radiation treatment of the neck to improve prognosis.



**Fig. 2** Flow diagram of treatment for the SNUC patients in the overall cohort.



**Fig. 3** Kaplan-Meier overall survival analysis.

**Table 3** Survival by patient and tumor characteristics

Variable	Hazard ratio (95% CI)	p-Value
Gender	1.80 (0.47–6.88)	0.39
Age	1.01 (0.95–1.07)	0.84
Smoking history	0.83 (0.24–2.86)	0.77
Alcohol history	0.68 (0.20–2.28)	0.53
Neck metastasis	4.47 (1.04–19.20)	0.04 <sup>a</sup>
Distant metastasis	3.82 (0.76–19.06)	0.10

Abbreviation: CI, confidence interval.

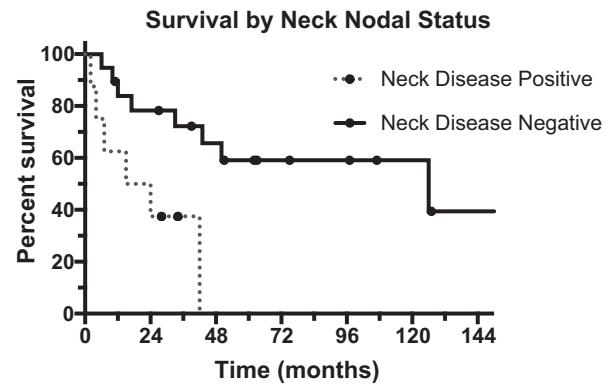
<sup>a</sup> $p < 0.05$ .

A meta-analysis by Chambers et al, a study in the Surveillance, Epidemiology, and End Results database, and a study in the National Cancer Database provide other important demographic and survival considerations for SNUC.<sup>25–27</sup>

**Table 4** Published SNUC case series in the United States

Study	Penn	Mayo	UCSF	UVA	UM	Harvard	Einstein	UCD	MD And.	UF	UC
Author	Workman et al	Gamez et al	Chen et al	Musy et al	Lin et al	Gray et al	Mourad et al	Yoshida et al	Rosenthal	Tanzler et al	Miyamoto et al
Year	Current	2017	2008	2002	2010	2015	2013	2013	2004	2008	2000
Patients (#)	27	40	21	20	19	19	18	16	16	15	14
Age	55	57	47	58	51	52	52	50	48	57	54
F/u (mo)	47	83	58	80	21		26		81	30	
T4 (%)	85	80	81	73	84	100	67	94	69	100	63
Node + (%)	33	8	10	13	21	16	22	25	0	13	
Surgery (%)	85	83	90	55	53	63	83	63	63	66	64
XRT (%)	96	100	100	95	100	100	83	63	100	93	86
Chemo (%)	96	68	62	80	84	100	83	63		47	43
2 y OS (%)	66			47	61		75				45
5 y OS (%)	46	44	43	20	22	45	48	33	63	67	36

Abbreviations: Einstein, Yeshiva University and Albert Einstein College of Medicine; f/u, median follow-up; Mayo, Mayo Clinic in Rochester, MN; MD And, MD Anderson Cancer Center; OS, overall survival; Penn, University of Pennsylvania; SNUC, sinonasal undifferentiated carcinoma; UC, University of Cincinnati;<sup>3,4,6–8,12,20–23</sup> UCD, University of California, Davis; UCSF, University of California, San Francisco; UF, University of Florida; UM, University of Michigan; UVA, University of Virginia; XRT, radiation therapy.



**Fig. 4** Kaplan-Meier survival analysis for all patients, broken into two groups by nodal neck disease at presentation.

There is a 2:1 predilection to SNUC in males, which is also borne out in our cohort (63%). Older age, advanced stage, metastatic disease, and Asian race were all significantly associated with decreased survival, while combination surgery with adjuvant therapy was again more effective than single-modality treatment. Notably, a large majority of patients who died of their disease did so within 20 months of treatment,<sup>25</sup> suggesting that there is a time during which surveillance is most critical.<sup>31,32</sup> Like many other sinonasal cancers, a proportion of SNUC is related to HPV infection, although p16 is often overexpressed in SNUC even in the absence of HPV.<sup>18</sup> Both HPV positive and p16 positive SNUC patients showed improved survival in a preliminary study.<sup>20</sup>

The long timespan covered by this case series makes for a diagnostic challenge. The updated 2017 World Health Organization criteria for histopathological diagnosis of head and neck tumors describes SNUC as a diagnosis of exclusion, without squamous or glandular differentiation present.<sup>33</sup>

Furthermore, distinction of SNUC from large cell neuroendocrine carcinoma is difficult. Diagnoses of exclusion can be susceptible to sampling error and a definitive classification cannot always be ensured; our case series is not immune to this potential pitfall. Specific stains, such as the integrase interactor 1 protein stain and the nuclear protein in testis stain were not performed on some patients in the case series, as these stains have only recently been commonly utilized by pathologists for SNUC diagnosis. Other limitations of our study are related to sample size; a total of 27 patients precludes robust regression analyses or power to detect differences in all variables examined in our cohort. However, the rarity of SNUC ensures that no single institution will have a large enough group for adequate statistical considerations, and it is unlikely that a randomized controlled trial evaluating SNUC therapies would be possible even with a multi-institutional effort. The infrequency of SNUC cases makes case series valuable, both for future meta-analyses and appraisal of homogenous, single-institution data.

Overall, this study assesses demographics, tumor characteristics, and clinical management of a relatively large cohort of SNUC patients over a 15-year period. Long-term survival of SNUC patients is universally poor, as almost all patients present with very advanced disease. Neck metastases were present in a high proportion of our patient population, and were associated with decreased survival time. There was a heavy emphasis on a multimodal approach of surgical resection with adjuvant chemoradiotherapy in almost all patients, regardless of disease extent, and the literature is largely supportive of this methodology. Persistence of disease following treatment was a very poor prognostic sign and highly predictive of mortality. Identification of optimal strategies to prevent disease progression is a high priority for developing improved treatments for SNUC.

## References

- Reiersen DA, Pahilan ME, Devaiah AK. Meta-analysis of treatment outcomes for sinonasal undifferentiated carcinoma. *Otolaryngol Head Neck Surg* 2012;147(01):7-14
- Mendenhall WM, Mendenhall CM, Riggs CE Jr, Villaret DB, Mendenhall NP. Sinonasal undifferentiated carcinoma. *Am J Clin Oncol* 2006;29(01):27-31
- Lin EM, Sparano A, Spalding A, et al. Sinonasal undifferentiated carcinoma: a 13-year experience at a single institution. *Skull Base* 2010;20(02):61-67
- Musy PY, Reibel JF, Levine PA. Sinonasal undifferentiated carcinoma: the search for a better outcome. *Laryngoscope* 2002;112(8 Pt 1):1450-1455
- Rischin D, Porceddu S, Peters L, Martin J, Corry J, Weih L. Promising results with chemoradiation in patients with sinonasal undifferentiated carcinoma. *Head Neck* 2004;26(05):435-441
- Miyamoto RC, Gleich LL, Biddinger PW, Gluckman JL. Esthesioneuroblastoma and sinonasal undifferentiated carcinoma: impact of histological grading and clinical staging on survival and prognosis. *Laryngoscope* 2000;110(08):1262-1265
- Raja V, Campbell GA. Unusual cases involving the CNS and nasal sinuses: case 2. Sinonasal undifferentiated carcinoma. *J Clin Oncol* 2003;21(20):3877-3880
- Chen AM, Daly ME, El-Sayed I, et al. Patterns of failure after combined-modality approaches incorporating radiotherapy for sinonasal undifferentiated carcinoma of the head and neck. *Int J Radiat Oncol Biol Phys* 2008;70(02):338-343
- Ejaz A, Wenig BM. Sinonasal undifferentiated carcinoma: clinical and pathologic features and a discussion on classification, cellular differentiation, and differential diagnosis. *Adv Anat Pathol* 2005;12(03):134-143
- Smith SR, Som P, Fahmy A, Lawson W, Sacks S, Brandwein M. A clinicopathological study of sinonasal neuroendocrine carcinoma and sinonasal undifferentiated carcinoma. *Laryngoscope* 2000;110(10 Pt 1):1617-1622
- Frierson HF Jr, Mills SE, Fechner RE, Taxy JB, Levine PA. Sinonasal undifferentiated carcinoma. An aggressive neoplasm derived from Schneiderian epithelium and distinct from olfactory neuroblastoma. *Am J Surg Pathol* 1986;10(11):771-779
- Tanzler ED, Morris CG, Orlando CA, Werning JW, Mendenhall WM. Management of sinonasal undifferentiated carcinoma. *Head Neck* 2008;30(05):595-599
- Xu CC, Dziegielewski PT, McGaw WT, Seikaly H. Sinonasal undifferentiated carcinoma (SNUC): the Alberta experience and literature review. *J Otolaryngol Head Neck Surg* 2013;42:2
- Kramer D, Durham JS, Sheehan F, Thomson T. Sinonasal undifferentiated carcinoma: case series and systematic review of the literature. *J Otolaryngol* 2004;33(01):32-36
- Righi PD, Francis F, Aron BS, Weitzner S, Wilson KM, Gluckman J. Sinonasal undifferentiated carcinoma: a 10-year experience. *Am J Otolaryngol* 1996;17(03):167-171
- Deutsch BD, Levine PA, Stewart FM, Frierson HF Jr, Cantrell RW. Sinonasal undifferentiated carcinoma: a ray of hope. *Otolaryngol Head Neck Surg* 1993;108(06):697-700
- Jeng YM, Sung MT, Fang CL, et al. Sinonasal undifferentiated carcinoma and nasopharyngeal-type undifferentiated carcinoma: two clinically, biologically, and histopathologically distinct entities. *Am J Surg Pathol* 2002;26(03):371-376
- Wadsworth B, Bumpous JM, Martin AW, Nowacki MR, Jenson AB, Farghaly H. Expression of p16 in sinonasal undifferentiated carcinoma (SNUC) without associated human papillomavirus (HPV). *Head Neck Pathol* 2011;5(04):349-354
- Wenig BM. Undifferentiated malignant neoplasms of the sinonasal tract. *Arch Pathol Lab Med* 2009;133(05):699-712
- Gray ST, Herr MW, Sethi RK, et al. Treatment outcomes and prognostic factors, including human papillomavirus, for sinonasal undifferentiated carcinoma: a retrospective review. *Head Neck* 2015;37(03):366-374
- Mourad WF, Hauerstock D, Shourbaji RA, et al. Trimodality management of sinonasal undifferentiated carcinoma and review of the literature. *Am J Clin Oncol* 2013;36(06):584-588
- Yoshida E, Aouad R, Fragoso R, et al. Improved clinical outcomes with multi-modality therapy for sinonasal undifferentiated carcinoma of the head and neck. *Am J Otolaryngol* 2013;34(06):658-663
- Gamez ME, Lal D, Halyard MY, et al. Outcomes and patterns of failure for sinonasal undifferentiated carcinoma (SNUC): the Mayo Clinic experience. *Head Neck* 2017;39(09):1819-1824
- Ahn PH, Mitra N, Alonso-Basanta M, et al. Nodal metastasis and elective nodal level treatment in sinonasal small-cell and sinonasal undifferentiated carcinoma: a surveillance, epidemiology and end results analysis. *Br J Radiol* 2016;89(1058):20150488
- Chambers KJ, Lehmann AE, Remenschneider A, et al. Incidence and survival patterns of sinonasal undifferentiated carcinoma in the United States. *J Neurol Surg B Skull Base* 2015;76(02):94-100
- Kuan EC, Arshi A, Mallen-St Clair J, Tajudeen BA, Abemayor E, St John MA. Significance of tumor stage in sinonasal undifferentiated carcinoma survival: a population-based analysis. *Otolaryngol Head Neck Surg* 2016;154(04):667-673
- Khan MN, Konuthula N, Parasher A, et al. Treatment modalities in sinonasal undifferentiated carcinoma: an analysis from the National Cancer Database. *Int Forum Allergy Rhinol* 2017;7(02):205-210



- 28 Al-Mamgani A, van Rooij P, Mehilal R, Tans L, Levendag PC. Combined-modality treatment improved outcome in sinonasal undifferentiated carcinoma: single-institutional experience of 21 patients and review of the literature. *Eur Arch Otorhinolaryngol* 2013;270(01):293–299
- 29 Kim BS, Vongtama R, Juillard G. Sinonasal undifferentiated carcinoma: case series and literature review. *Am J Otolaryngol* 2004; 25(03):162–166
- 30 Hitt R, López-Pousa A, Martínez-Trufero J, et al. Phase III study comparing cisplatin plus fluorouracil to paclitaxel, cisplatin, and fluorouracil induction chemotherapy followed by chemoradiotherapy in locally advanced head and neck cancer. *J Clin Oncol* 2005;23(34):8636–8645
- 31 Khalili S, Worrall DM, Brooks S, et al. Endoscopy versus imaging: analysis of surveillance methods in sinonasal malignancy. *Head Neck* 2016;38(08):1229–1233
- 32 Workman AD, Palmer JN, Adappa ND. Posttreatment surveillance for sinonasal malignancy. *Curr Opin Otolaryngol Head Neck Surg* 2017;25(01):86–92
- 33 Stelow EB, Bishop JA. Update from the 4th Edition of the World Health Organization Classification of Head and Neck Tumours: Tumors of the Nasal Cavity, Paranasal Sinuses and Skull Base. *Head Neck Pathol* 2017;11:3–15
- 34 Rosenthal DI, Barker JL Jr, El-Naggar AK. Sinonasal malignancies with neuroendocrine differentiation: patterns of failure according to histologic phenotype. *Cancer* 2004;101(11):2567–2573