

# UCSF

## UC San Francisco Previously Published Works

### Title

Minimally Invasive Hysterectomy for Uteri Greater Than One Kilogram

### Permalink

<https://escholarship.org/uc/item/16h888p2>

### Journal

JSLs Journal of the Society of Laparoscopic & Robotic Surgeons, 21(1)

### ISSN

1086-8089

### Authors

Ito, Traci E  
Vargas, Maria V  
Moawad, Gaby N  
[et al.](#)

### Publication Date

2017

### DOI

10.4293/jsls.2016.00098

Peer reviewed

# Minimally Invasive Hysterectomy for Uteri Greater Than One Kilogram

Traci E. Ito, MD, Maria V. Vargas, MD, Gaby N. Moawad, MD, Jessica Opoku-Anane, MD, Michael K. M. Shu, BA, Cherie Q. Marfori, MD, James K. Robinson, III, MD

## ABSTRACT

**Background and Objectives:** To assess the feasibility and safety of minimally invasive hysterectomy for uteri >1 kg.

**Methods:** Clinical and surgical characteristics were collected for patients in an academic tertiary care hospital. Included were patients who underwent minimally invasive hysterectomy by 1 of 3 fellowship-trained gynecologists from January 1, 2009, to July 1, 2015 and subsequently had confirmed uterine weights of 1 kg or greater on pathology report. Both robotic and conventional laparoscopic procedures were included.

**Results:** During the study period, 95 patients underwent minimally invasive hysterectomy with confirmed uterine weight over 1 kg. Eighty-eight percent were performed with conventional laparoscopy and 12.6% with robot-assisted laparoscopy. The median weight (range) was 1326 g (range, 1000–4800). The median estimated blood loss was 200 mL (range, 50–2000), and median operating time was 191 minutes (range, 75–478). Five cases were converted to laparotomy (5.2%). Four cases were converted secondary to hemorrhage and one secondary to extensive adhesions. There were no conversions after 2011. Intraoperative transfusion was given in 6.3% of cases and postoperative transfusion in 6.3% of cases. However, after 2013, the rate of intraoperative transfusion decreased to 1.0% and postoperative transfusion to 2.1%. Of the 95 cases, there were no cases with malignancy.

**Conclusions:** This provides the largest case series of hysterectomy over 1 kg completed by a minimally invasive approach. Our complication rate improved with ex-

perience and was comparable to other studies of minimally invasive hysterectomy for large uteri. When performed by experienced surgeons, minimally invasive hysterectomy for uteri >1 kg can be considered feasible and safe.

**Key Words:** Fibroids, Laparoscopic hysterectomy.

## INTRODUCTION

Large pathology increases the technical challenge of hysterectomy by any mode. It has thus been recommended that uterine size greater than 15 weeks' gestation, or a specimen weight >500 g serves as the upper limit for the safe performance of a minimally invasive surgical (MIS) approach.<sup>1,2</sup> As more surgeons have developed the skills to perform technically advanced laparoscopic hysterectomy, the practice of using uterine size as a contraindication to laparoscopy has come into question.<sup>3</sup> There are clear benefits to a minimally invasive approach for hysterectomy, but there is limited evidence regarding perioperative outcomes in cases of large areas of pathology.<sup>3–8</sup> Yet, hysterectomy is the most commonly performed gynecologic surgery, and the most frequent indication for hysterectomy in the United States is uterine fibroids, a condition that is known to enlarge the uterus. It is therefore imperative to develop an understanding of the feasibility and safety of a laparoscopic approach for hysterectomy in cases with large pathologic areas.

The goal of this study was to describe our technique for performing laparoscopic hysterectomy in women with uterine weights  $\geq 1$  kg and to report the associated perioperative outcomes.

## MATERIALS AND METHODS

After obtaining George Washington University Institutional Review Board approval, a retrospective chart review was initiated. Patients who underwent minimally invasive hysterectomy by 1 of 3 fellowship-trained minimally invasive gynecologic surgeons (JKR, CQM, and GNM) from January 1, 2009, to July 1, 2015, were identified through surgical schedules and data were collected

Department of Obstetrics and Gynecology (Drs Ito, Vargas, Moawad, Opoku-Anane, Marfori, and Robinson) The George Washington University Hospital, and the George Washington University Medical School (Mr. Shu), The George Washington University Hospital, Washington, DC, USA.

Disclosures: Dr. Moawad receives an honorarium from Intuitive and Applied Medical.

Address correspondence to: Traci E. Ito, MD, 1500 River Shore Drive. Apt 303 Louisville, KY 40206. Telephone: 217-377-1412, E-mail: traciemiito@gmail.com

DOI: 10.4293/JSLS.2016.00098

© 2017 by JSLS, *Journal of the Society of Laparoendoscopic Surgeons*. Published by the Society of Laparoendoscopic Surgeons, Inc.

for all patients with final specimen weights of >1 kg. Clinical characteristics collected included age, race, body mass index (BMI), parity, and history of prior surgeries. Surgical characteristics collected included surgical approach, operative time from incision to closure, estimated blood loss, conversion to laparotomy, and intraoperative complications. Intraoperative complications were defined as hemorrhage (estimated blood loss > 1000 mL), blood transfusion, and visceral injury. Perioperative characteristics collected included pathologic diagnosis, specimen weights from pathology reports, length of hospital stay, readmission, and postoperative complications. Postoperative complications included surgical site infection, reoperation, unanticipated intensive care unit admission, deep vein thrombosis or pulmonary embolism, blood transfusion, ileus or bowel obstruction, and sepsis.

### Operative technique

The technique to achieve traditional laparoscopic hysterectomy for large uteri varied slightly among the 3 surgeons, but the main steps were similar. A urinary catheter was placed for gravity drainage, and a V-Care uterine manipulator (ConMed Endosurgery, Utica, New York, USA) was inserted. Pneumoperitoneum was achieved by everting the umbilicus and introducing a Veress needle into the abdomen. Occasionally the Veress needle was introduced at Palmer's point in the left upper quadrant. However, this decision was not dependent on uterine size, but on previous vertical incision or hernia repair that may have resulted in adhesions at that level of the umbilicus. Once intraperitoneal placement was confirmed by an initial pressure reading <5 mm Hg, we used a high-pressure trocar insertion technique.<sup>9</sup> The abdomen was insufflated to a pressure of 25 mm Hg, and a 5-mm optical trocar was introduced at the umbilicus under direct visualization. The pressure was then reduced to 15 mm Hg for the remainder of the case.

The patient was then placed in the Trendelenburg position and 2 ancillary ports were placed. Ancillary ports included left and right lower quadrant ports. In conventional laparoscopic cases, a 12-mm suprapubic port was placed. The 2 lateral ports were 5 mm in size. All ancillary ports were placed under direct visualization after preinjection with 0.25% bupivacaine with epinephrine.

The round ligaments were transected bilaterally with a Harmonic scalpel (Ethicon, Endosurgery, Cincinnati, Ohio, USA), and the anterior leaf of the broad ligament was opened over the anterior fornix delineator, creating a bladder flap. The retroperitoneal spaces were developed

to identify the ureters when anatomy was distorted by the size of the uterus. This was not performed if ureteral location was obvious upon inspection. A window in the posterior leaf of the broad ligament was made to isolate the utero-ovarian ligaments and further lateralize the ureters. The utero-ovarian pedicle was then desiccated and transected from the suprapubic port to allow 90° access after releasing the fallopian tubes from the mesosalpinx to the level of the uterine cornua. The posterior leaf of both broad ligaments was further opened in the direction of the uterosacral ligaments bilaterally to skeletonize the uterine arteries at the level of the lateral fornix delineator. The uterine pedicles were desiccated with a reusable bipolar instrument and transected with the Harmonic scalpel at the level of the lateral vaginal fornices. The uterine arteries were approached from the low lateral ports to allow 90° access. A culdotomy incision was made with the ultrasonic scalpel. In some cases, it was appropriate to access the uterine artery at its origin. This method was pursued in cases with large posterior fibroids or when the lateral margins, where the uterine pedicles are typically accessed, were obstructed by aberrant anatomy or large fibroids.

At the time of specimen removal, the surgeon made a clinical decision based on the size of the uterus, location of fibroids, and patient's pelvic structure as to what mode of tissue extraction would be used. In some cases, transvaginal tissue extraction was appropriate and was achieved by using a cold-scalpel "paper roll" or coring technique.<sup>10</sup> Before the U.S. Food and Drug Administration (FDA) safety warning on power morcellation, when the pathologic specimen could not be placed into the pelvis, either a minilaparotomy or power morcellation technique was used. In the case of a minilaparotomy technique, the suprapubic port site was extended to 2.5 cm.

This technique was modified after the FDA safety warning on power morcellation. The umbilical port was changed to 12 mm and a 5-mm suprapubic port was placed. At the time of tissue extraction, an umbilical minilaparotomy incision was made, measuring about 2.5 cm. A containment bag was used whenever possible. The pneumoperitoneum was re-established with the use of an Alexis retractor and cap (Applied Medical, Brecksville, Ohio, USA). The large isolation bag was positioned deep in the pelvis. The edges of the bag were pulled around the large specimen until the drawstrings were appreciated. These drawstrings were elevated to the port site and pulled through the minilaparotomy. The cap was removed, and the bag exteriorized with the uterus completely contained.

At this point, the Alexis retractor was removed and replaced within the bag. A cold-scalpel and paper roll method was used for tissue extraction.<sup>10</sup> After the specimen was removed, the bag was examined to assess whether it remained intact. The vaginal cuff was closed laparoscopically with a V-loc (Covidien; Medtronic, Minneapolis, Minnesota, USA) in a running fashion. Care was taken to dissect the bladder to allow incorporation of tissue ~1 cm from the incisional edge. In addition, the posterior peritoneal layer and uterosacral ligaments were incorporated in the closure whenever feasible.

For robotic hysterectomy, the Veress needle was used to achieve pneumoperitoneum and a 12-mm midline optical port was placed under direct visualization through the base of the umbilicus. Two 8-mm robotic ports were used and placed lateral to the umbilicus for robotic arms 1 and 2. The third robotic arm was not used. When needed, a 5-mm assistant port was added in the left upper quadrant. A side-docking technique was used exclusively. When the robotic technique was employed, the surgical steps were identical to those used for laparoscopic hysterectomy. Monopolar and fenestrated bipolar instruments were used. Tissue extraction was also completed by using a similar technique.

One surgeon performed 4 robotic hysterectomies and the remainder of the cases by a conventional laparoscopic approach, another performed all cases using conventional laparoscopy, and the last surgeon transitioned to performing robotic hysterectomies routinely and contributed 8 robotic hysterectomies to the cohort.

## RESULTS

A total of 95 women who underwent minimally invasive hysterectomy from 2009 to 2014 had a final uterine weight of >1 kg on final pathologic evaluation. Patient characteristics are shown in **Table 1**. Most women were black (75.8%). The median (range) age was 45 (27–64) years, and BMI was 32 (19.8–49.9). Twenty-three percent had a prior laparoscopic procedure, and 33.7% had at least one prior laparotomy.

**Table 2** summarizes surgical characteristics and perioperative outcomes. Robotic hysterectomy was completed in 12.6% of cases and the remaining 87.4% were completed with conventional laparoscopy. In terms of tissue extraction technique, 9.5% of cases were performed from a transvaginal approach, 22.1% underwent power morcellation, and 56.8% underwent an umbilical or suprapubic minilaparotomy extraction approach. The median (range) uterine weight was 1326 g (1000–4800). The median (range) operating time was

**Table 1.**  
Patient Demographic and Clinical Characteristics

Characteristic	Laparoscopic Hysterectomy with Specimen Weight >1 kg (N = 95)
Age median (min-max)	45 (27–64)
Race/ethnicity n (%)*	
Caucasian	15 (15.8)
Black	72 (75.8)
Hispanic	0 (0)
Asian or Pacific islander	0 (0)
Other	1 (1.1)
BMI, median (min-max)	32 (19.8–49.9)
Nulliparity, n (%)	42 (44.2)
Previous laparoscopic surgery, n (%)	22 (23.2)
Previous open abdominal surgery, n (%)	32 (33.7)

Data were missing for some patients. Total missing for each variable: race, n = 7; BMI, n = 2; parity, n = 2.

191 minutes (75–478) and estimated blood loss was 200 mL (20–2000). Eleven patients (11.6%) underwent uterine artery desiccation at the origin.

The intraoperative complication rate was 7.3%. All of these patients (n = 7) had an intraoperative blood loss >1000 mL and 6 (6.3%) received a blood transfusion. One patient received a transfusion for vital sign changes in the setting of a low starting hemoglobin. She had an estimated blood loss of 200 mL. Five operations were converted to laparotomy (5.3%): 4 secondary to hemorrhage and 1 conversion secondary to extensive adhesive disease that precluded safe lateralization of the ureter and isolation of the uterine artery. There was 1 repair of a serosal defect of the sigmoid colon after inherent injury during adhesiolysis. This was repaired laparoscopically. Eight patients (8.4%) experienced a postoperative complication. Transfusion was the most common postoperative complication (6.3%) followed by cellulitis (2.1%). Three of the 6 women who received a postoperative transfusion had also received an intraoperative transfusion, for a total transfusion rate of 9.5%. One of these women had a low starting hemoglobin and an estimated blood loss of 300 mL, but she had symptoms of anemia after surgery and thus required blood transfusion.

In evaluating the proportion of conversions, hemorrhage, and transfusion by year, we found a decline starting in 2012 (**Figure 1**). There were no conversions after 2011.

**Table 2.**  
Operative Characteristics and Outcomes

Characteristic	Laparoscopic Hysterectomy with Specimen Weight >1 kg (N = 95)
Surgical technique, n (%)	
Laparoscopic	83 (87.4)
Robotic	12 (12.6)
Tissue extraction technique, n (%)*	
Transvaginal	9 (9.5)
Power morcellator	21 (22.1)
Minilaparotomy	54 (56.8)
Uterine artery desiccation at the origin, n (%)	11 (11.6)
Specimen weight (g), median (min-max)	1326 (1000–4800)
Operative time (min), median (min-max)	191 (75–478)
EBL (mL), median (min-max)	200 (20–2000)
Conversion to laparotomy, n (%)	5 (5.3)
Intraoperative complication, n (%)	7 (7.3)
Hemorrhage	7 (7.3)
Transfusion	6 (6.3)
Visceral injury	1 (1.1)
Postoperative complication, n (%)	8 (8.4)
Urinary tract infection	0
Surgical site infection	2 (2.1)
Re operation	0
ICU admission	0
DVT/PE	0
Blood transfusion	6 (6.3)
Ileus/bowel obstruction	0
Sepsis	0
Length of stay, median (min-max)	1 (0–6)
Readmission, n (5)	1 (1.1)

EBL, estimated blood loss; DVT/PE, deep vein thrombosis and/or pulmonary embolism. \*Data were missing for some patients. Total missing for each variable: tissue extraction technique, n = 6; length of stay, n = 3; and readmission, n = 1.

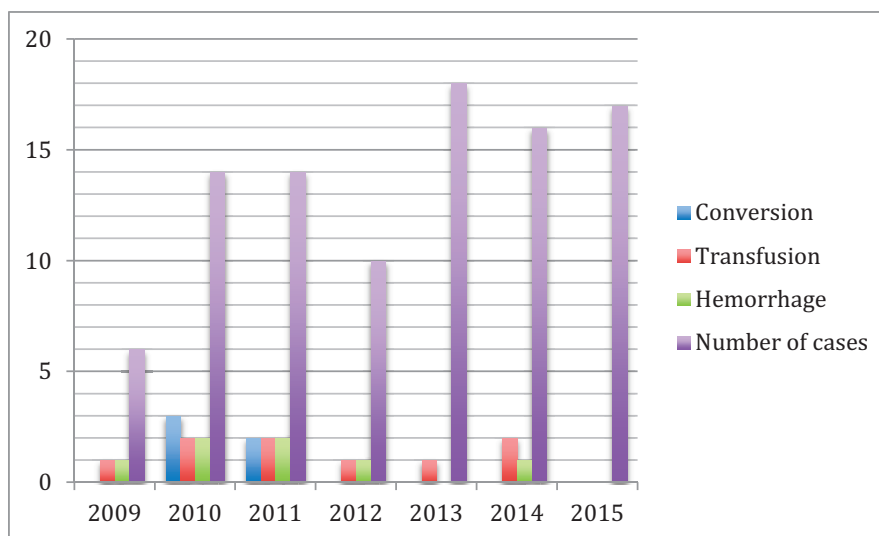
From 2013 through 2015 the rate of hemorrhage was 3.3%, intraoperative transfusion was 1.0%, and postoperative transfusion was 2.1%.

Cases were stratified by specimen weights to assess for differences in surgical outcomes. Women with uterine weights greater than or equal to 1500 g had longer median (range) operative time: 228 minutes (75–478) versus 180 minutes (75–391) ( $P = .012$ ), but no difference in estimated blood loss, length of stay, rate of conversion, or rate of complications (**Table 3**).

## DISCUSSION

This case series is among the largest reporting experience with minimally invasive hysterectomy for uteri >1 kg. We included cases achieved by both the conventional and robotic approaches, as outcomes are clinically comparable.<sup>3,11</sup> The results support the conclusions of prior reports that showed that laparoscopic hysterectomy for women with large uterine pathology is a safe option and that outcomes are improved over similar cases with the open abdominal approach.<sup>4,8,12,13</sup> The most common complications in our cohort were hemorrhage and transfusion, especially in the first 3 years of performance of the procedure. Complications declined substantially thereafter and were comparable to other reports of similar procedures after the learning curve.<sup>12</sup> Notably, transfusion protocols in our hospital also changed in 2012, increasing the threshold for transfusion and decreasing the number of transfusions in the hospital overall.

In comparison to Uccella et al,<sup>12</sup> who had a large case series of uteri greater than 1 kg, our data included a slightly larger median weight of uteri (1326 g vs 1120 g) with a larger range (1000–4800 g). Our median operative times were longer overall (190 vs 120 min). Operating time may have been increased in our series after the inclusion of the learning curve period in our data, the participation of residents and/or fellows at 100% of our cases,<sup>14</sup> and the change in approach to tissue extraction to include bagging in early 2014. Concomitant procedures like appendectomy and hernia repair were also performed, and many cases required adhesiolysis and enterolysis. Cystoscopy was performed in all cases. Our increased operating time may have also been in part due to larger uterine size overall which potentially increased case complexity and required more time for tissue extraction. Both the present study and Uccella and colleagues<sup>12</sup> report comparable complication rates (after the learning curve) to laparoscopic procedures for smaller uteri. Our patients had a median length of hospital stay of 1 day, and almost 50% of



**Figure 1.** Conversions, hemorrhage, and transfusion by year.

patients were discharged on the day of surgery. Most of our patients returned to work 2 weeks after surgery. These findings thus support that a laparoscopic approach for hysterectomy with a large area of pathology confers the benefits of shorter hospital stays and faster recovery period when compared to laparotomy, despite the higher surgical complexity.<sup>2,16</sup>

Our data demonstrate a learning curve as exhibited by our higher initial rate of hemorrhage and transfusion.<sup>12</sup> The overall intraoperative transfusion rate was 6.3% and a postoperative transfusion rate was 6.3%. The rate of transfusion declined from 2013 onward and became 1.0% for intraoperative transfusion and 2.1% for postoperative transfusion. There were no conversions to laparotomy after 2011. This decline in complications may be attributable to refinement of operative technique, improvements in perioperative management, and changes in our hospital's transfusion protocol.

Despite the learning curve period, our outcomes were improved over hysterectomy for large uteri performed using the abdominal approach. Uccella et al<sup>12</sup> reported outcomes in women with uteri >1.5 kg undergoing both abdominal and conventional laparoscopic hysterectomy. Compared to the abdominal cohort, our minimally invasive cohort >1.5 kg had a similar overall intraoperative complication rate (7.2% vs 9.1%), despite the fact that hemorrhage and transfusion were not considered complications in the abdominal cohort but were in our cohort. The abdominal cohort had slightly lower rate of intraoperative transfusion (7.4% vs 12.1%), but a

higher rate of hemorrhage (18.5% vs 12.1%). In considering only cases after our learning curve, the abdominal cohort had significantly higher transfusion (7.4% vs 1.0%) and hemorrhage (18.5% vs 3.3%) rates. The abdominal cohort also had a significantly higher rate of postoperative complications (37.0% vs 12.1%).<sup>13</sup>

Refinements in operative technique that potentially improved outcomes after the learning curve include surgeons becoming more comfortable entering the retroperitoneal space to gain access to uterine vessels at the origin. Optimization of techniques for retraction including enhanced comfort with instrumentation to manipulate fibroids—for example, use of the active blade of the Harmonic scalpel to stab posterior fibroids and elevate them up and out of the pelvis allowing better visualization of the anatomy and access to the uterine vessels at their origin.

With regard to preoperative planning, after 2011, preoperative uterine artery embolization (UAE) was implemented in patients with large pedunculated fibroids who were deemed to have a high potential risk of large pelvic varicosities and parasitic blood supply. This technique, which has been previously described, was used in 5 cases.<sup>17</sup> In addition, the use of preoperative leuprolide acetate and evaluation for iron infusion for women with hemoglobin under 10 became routine. Finally, in 2013, a change in transfusion guidelines occurred that increased the transfusion threshold, especially in postoperative patients.

As with all retrospective studies, there are inherent weaknesses in this study. In some cases, operative

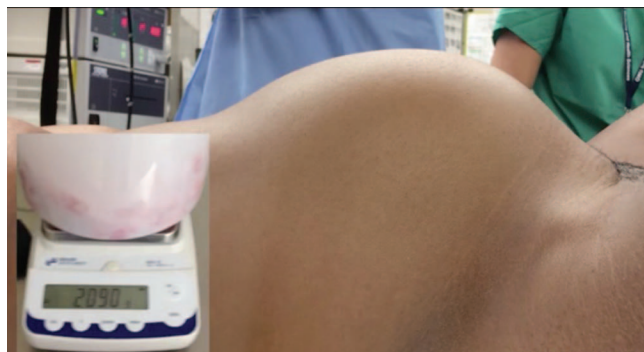**Table 3.**  
Outcomes by Specimen Weight

Characteristic	Laparoscopic Hysterectomy With Specimen Weight 1 to <1.5 kg (N = 62)	Laparoscopic Hysterectomy With Specimen Weight ≥1.5 kg (N = 33)	P
Surgical technique, n (%)			.533
Laparoscopic	53 (85.5)	30 (90.9)	
Robotic	9 (14.5)	3 (9.1)	
Tissue extraction technique, n (%)*			.089
Transvaginal	7 (11.2)	2 (6.6)	
Power morcellator	15 (24.2)	6 (18.2)	
Minilaparotomy	31 (50.0)	24 (72.7)	
Specimen weight (g), median (min–max)	1199 (1000–1498)	2133 (1500–4800)	<.001
Operative time (min), * median (min–max)	180 (75–391)	228 (75–478)	.012
EBL, (mL) median (min–max)	200 (20–1500)	200 (50–2000)	.088
Conversion to laparotomy, n (%)	4 (6.5)	1 (3.0)	.655
Intraoperative complication, any, n (%)	4 (6.5)	3 (9.1)	.690
Hemorrhage	3 (4.8)	4 (12.1)	.232
Transfusion	2 (3.2)	4 (12.1)	.178
Visceral injury	1 (1.6)	0 (0)	—
Postoperative complication, any, n (%)	4 (6.2)	4 (12.1)	.443
Urinary tract infection	0	0 (0)	—
Surgical site infection	1 (1.6)	1 (3.0)	—
Reoperation	0 (0)	0 (0)	—
ICU admission	0 (0)	0 (0)	—
DVT/PE	0 (0)	0 (0)	–1
Blood transfusion	3 (4.8)	3 (9.1)	.415
Ileus/bowel obstruction	0	0 (0)	—
Sepsis	0	0 (0)	—
Length of stay (days),* median (min–max)	1 (0–6)	1 (0–3)	.956
Readmission,* n (%)	1 (1.6%)	0 (0%)	—

EBL, estimated blood loss; ICU, intensive care unit; DVT/PE, deep venous thrombosis/pulmonary embolism. \*Data were missing for some patients. Total missing for each variable: operating time, n = 11; length of stay, n = 3; and readmission, n = 1.

times were incomplete or missing. In addition, other studies report pre- and postoperative hemoglobin and hematocrit. However, at our institution, unless clinically indicated, postoperative blood work is not routinely collected. Finally, although to our knowledge, this series is among the largest of cases of uterine weights greater than 1 kg, the size of the series is small. Ultimately, randomized controlled trials are necessary to assess outcomes by approach for cases with larger pathologic specimens.

The strengths of our study include standardization of technique among all 3 surgeons. Cases always have a resident and/or fellow present, the same manipulator is used by all 3 surgeons, and the staff in the operating room is specific for gynecology in most of the cases. In addition, because of the relative rarity of such large specimen weights, the present study contributes to the available early literature needed to set a precedent for further study of outcomes by surgical approach in cases with higher complexity.



**Figure 2.** Photograph of patient before hysterectomy for a 2-kg uterus.

## CONCLUSION

The minimally invasive approach to hysterectomy for uteri >1 kg is both feasible and safe in the hands of experienced surgeons. Although operating times increase, the previously documented benefits of laparoscopy over laparotomy persist. (**Figure 2**).

## References:

1. Kjerulff KH, Langenberg P, Seidman JD, Stolley PD, Guzinski GM. Uterine leiomyomas: racial differences in severity, symptoms and age at diagnosis. *J. Reprod Med.* 1996;41:483–490.
2. Kluivers KB, Hendriks JC, Mol BW, et al. Quality of life and surgical outcome after total laparoscopic hysterectomy versus total abdominal hysterectomy for benign disease: a randomized, controlled trial. *J Minim Invas Gynecol.* 2007;14:145–152.
3. O'Hanlan KA, McCutcheon SP, McCutcheon JG. Laparoscopic hysterectomy: impact of uterine size. *J Minim Invas Gynecol.* 2011;18:85–91.
4. Kondo W, Bourdel N, Marengo F, et al. Is laparoscopic hysterectomy feasible for uteri larger than 1000 g? *Eur J Obstetr Gynecol Reprod Biol.* 2011;158:76–81.
5. Perron-Burdick M, Yamamoto M, Zaritsky E. Same-day discharge after laparoscopic hysterectomy. *Obstetr Gynecol.* 2011;117:1136–1141.
6. Rolla M, Gagliardi ML, Giacomantonio L, Cecaroni M, Bruni F, Minelli L. Total laparoscopic hysterectomy of an uterus of 1840 grams: a case report. *Acta Biomed.* 2009;80:282–285.
7. Uccella S, Cromi A, Bogani G, Casarin J, Formenti G, Ghezzi F. Systematic implementation of laparoscopic hysterectomy independent of uterus size: clinical effect. *J Minim Invas Gynecol.* 2013;20:505–516.
8. Walid MS, Heaton RL. Total laparoscopic hysterectomy for uteri over one kilogram. *JLSLS.* 2010;14:178–182.
9. Reich H, Conti Ribeiro S, Rasmussen C, Rosenberg J, Vidali A. High-pressure trocar insertion technique. *JLSLS* 1999;3:45–48.
10. Wong WS, Lee TC, Lim CE. Novel vaginal “paper roll” uterine morcellation technique for removal of large (>500 g) uterus. *J Minim Invas Gynecol.* 2010;17:374–378.
11. Wright JD, Ananth CV, Lewin SN, et al. Robotically assisted vs laparoscopic hysterectomy among women with benign gynecologic disease. *JAMA.* 2013;309:689–698.
12. Uccella S, Cromi A, Serati M, Casarin J, Sturla D, Ghezzi F. Laparoscopic hysterectomy in case of uteri weighing  $\geq 1$  kilogram: a series of 71 cases and review of the literature. *J Minim Invas Gynecol.* 2014;21:460–465.
13. Uccella S, Casarin J, Marconi N, et al. Laparoscopic versus open hysterectomy for benign disease in women with giant uteri ( $\geq 1500$  g): feasibility and outcomes. *J Minim Invas Gynecol.* 2016;23:922–927.
14. Allen RW, Pruitt M, Taaffe KM. Effect of resident involvement on operative time and operating room staffing costs. *J Surg Educ.* 2016;0.1016/j.jsurg.2016.05.014.
15. Wattiez A, Soriano D, Fiaccavento A, et al. Total laparoscopic hysterectomy for very enlarged uteri. *J Am Assoc Gynecol Laparosc.* 2002;9:125–130.
16. Seracchioli R, Venturoli S, Vianello F, et al. Total laparoscopic hysterectomy compared with abdominal hysterectomy in the presence of a large uterus. *J Am Assoc Gynecol Laparosc.* 2002;9:333–338.
17. Hawa N, Robinson J 3rd, Chahine BE. Combined preoperative angiography with transient uterine artery embolization makes laparoscopic surgery for massive myomatous uteri a reasonable option: case reports. *J Minim Invas Gynecol.* 2012;19:386–390.