

# UC Davis

## Dermatology Online Journal

### Title

Calciphylaxis treated with sodium thiosulfate: report of two cases

### Permalink

<https://escholarship.org/uc/item/17f4k9tt>

### Journal

Dermatology Online Journal, 19(9)

### Authors

Garcia, Celia Posada  
Roson, Elena  
Peon, Gonzalo  
[et al.](#)

### Publication Date

2013

### DOI

10.5070/D3199019616

### Copyright Information

Copyright 2013 by the author(s). This work is made available under the terms of a Creative Commons Attribution-NonCommercial-NoDerivatives License, available at <https://creativecommons.org/licenses/by-nc-nd/4.0/>

Peer reviewed

## Case Presentation

### Calciphylaxis treated with sodium thiosulfate: report of two cases

Celia Posada Garcia MD, Elena Roson PhD, Gonzalo Peon MD, Maria Teresa Abalde MD, Carlos De La Torre PhD

Dermatology Online Journal 19 (9): 7

Complejo Hospitalario de Pontevedra, Pontevedra, Spain

#### Correspondence:

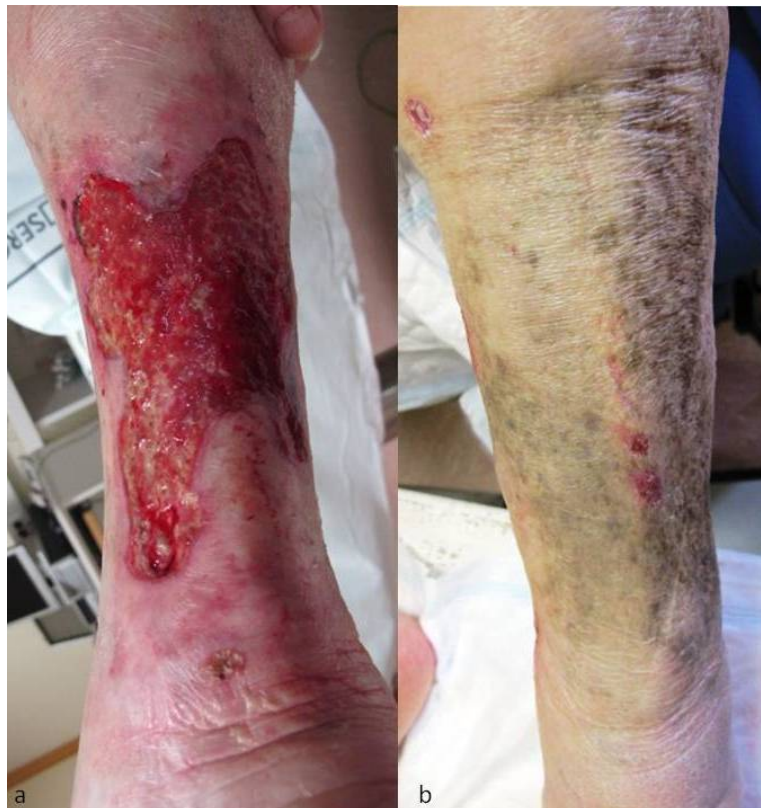Celia Posada Garcia MD  
Complejo Hospitalario de Pontevedra  
Pontevedra, Spain

## Abstract

Although traditionally observed in patients with end-stage renal disease and secondary hyperparathyroidism, calciphylaxis has been reported in patients with normal renal and parathyroid function. There is no evidence-based therapy available. The use of sodium thiosulfate (STS) has been increasingly described. Herein we describe two patients who responded well to this treatment.

**Keywords:** calciphylaxis, calcific uremic arteriolopathy, sodium thiosulfate

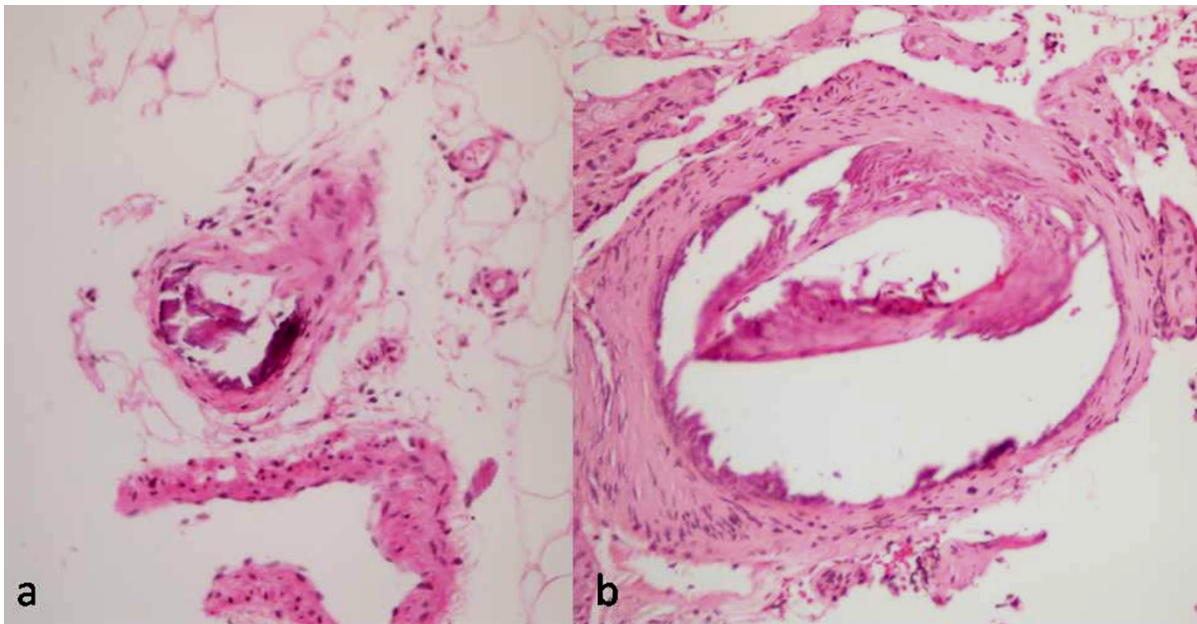
## Case synopsis



**Figure 1.** (a) Large ulcers on lower legs surrounded by erythema and purpura (b) Ulcerations almost healed following therapy with intravenous sodium thiosulfate.

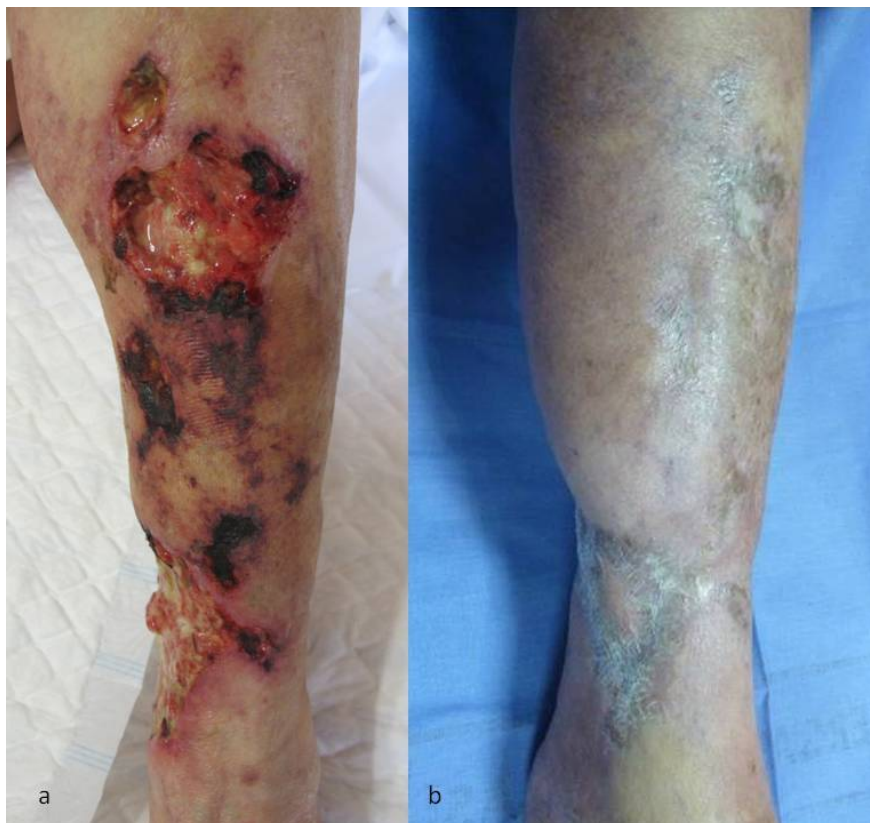**Patient 1:** a 73-year-old woman presented with a 2-month history of painful and necrotic ulcers surrounded by retiform purpura on her lower legs (Figure 1a). Her medical history included diabetes mellitus type II, hypertension, obesity, lupus erythematosus (treated with antimalarial drugs and systemic corticosteroids), HCV infection, chronic kidney disease, atrial fibrillation (treated with acenocoumarol), and cardiac valve disease. Plain radiographs of her legs identified vascular

calcification along the vessels under the cutaneous lesions. Cutaneous biopsy showed necrotic epidermis and dermal lymphohistiocytic infiltrate. Calcium deposition within blood vessels was observed in the deep dermis (Figure 2a). Peripheral arteriopathy was diagnosed. Laboratory tests were within normal ranges except for low levels of vitamin D with secondary hyperparathyroidism (PTH 86 pg/ml [9-70]). Creatinine clearance was 35ml/min/m<sup>2</sup> and phosphate and calcium levels were not elevated. Despite supplementary vitamin D therapy and initiation of low molecular weight heparin instead of acenocoumarol, the patient continued to worsen. Treatment with intravenous STS was initiated at a dose of 12.5g three times per week together with wound care. The treatment continued for four months with almost complete healing of the lesions and no adverse effects (Figure 1b). However, the patient died owing to septic shock from urinary infection.



**Figure 2.** (a) and (b) [H-Ex20] Calcium deposition in the vessel walls was observed in the deep dermis of cutaneous biopsy performed in patients 1 and 2 respectively.

**Patient 2:** an 80-year old woman presented with a several month history of extremely painful ulcers covered by necrotic eschars and surrounded by racemous livedo on her lower left extremity (Figure 3a). Her medical history included obesity, diabetes mellitus, and atrial fibrillation treated with acenocoumarol. Cutaneous biopsy (Figure 2b) and radiographs confirmed calciphylaxis. Laboratory tests were within normal ranges, including renal function. Management included discontinuation of acenocoumarol and commencement of low molecular weight heparin, wound care, and intravenous STS at standard dose (25mg 3 times per week). Pain improved within several weeks and the ulcers healed within nine months (Figure 3b).



**Figure 3.** (a) Necrotic ulcers on her lower left leg covered by eschar and surrounded by retiform purpura (b) The ulcers improved progressively and the lesions resolved after nine months of therapy with sodium thiosulfate.

## Discussion

Although traditionally observed in patients with end-stage renal disease and secondary hyperparathyroidism, calciphylaxis has been reported in patients with normal renal and parathyroid function [1]. Calciphylaxis is a small vessel vasculopathy characterized by soft tissue ischemia and necrosis owing to calcium deposition in the medial layer of subcutaneous arterioles [2]. It is associated with high mortality rates (45-80%) [3]; sepsis is the main cause of death [3,4].

The pathogenesis is poorly understood and it is thought to be multifactorial [5]. It is speculated that metabolic abnormalities and therapies that are associated with uremia are precipitating factors in calciphylaxis. In the case of non-uremic calciphylaxis, deficiencies in vascular calcification inhibitors have been postulated [6].

Currently, an overview of risk factors for development of calciphylaxis is not more than just a descriptive list of a statistical phenomenon. These include female sex, white race, obesity, diabetes, liver disease, systemic corticosteroid use, elevated calcium-phosphate product, increased erythrocyte sedimentation rate, decreased albumin level, elevated alkaline phosphatase levels, elevated phosphorus level, warfarin use, vitamin D administration, protein C and S deficiency, and calcium supplementation [1,2,5,6].

Our patients do not fit traditional patients. The first patient suffered from mild chronic kidney disease and she had slightly high levels of PTH owing to vitamin D deficiency. There was no disturbance of calcium and phosphorus metabolism and these findings did not seem to cause her calciphylaxis. The second patient did not have chronic kidney disease or hyperparathyroidism. However, both of them presented with multiple risk factors related to calciphylaxis.

The diagnosis is essentially clinical. Cutaneous biopsy shows extensive calcification of the tunica media of small-medium sized dermal and subcutaneous arterioles. Laboratory tests do not make the diagnosis of calciphylaxis in patients suffering from renal disease and calcium metabolism impairment [3,5].

Management of calciphylaxis involves a multidisciplinary approach. Supportive management such as wound care, pain control, and frequent debridement are essential [3]. Therapy of calciphylaxis in traditional patients has been to promote normalization of calcium, phosphorus, and parathyroid hormone metabolism [5]. Parathyroidectomy should only be considered for patients with severe hyperparathyroidism who have failed medical management [2-4]. Novel medical therapies described for calciphylaxis secondary to hyperparathyroidism include cinacalcet and bisphosphonates. Cinacalcet may be an alternative to surgical management. The role of bisphosphonates in treating calciphylaxis is unclear [3-5,7].

Currently, the first-line treatment of calciphylaxis without hyperparathyroidism is STS [3]. It is approved by the Food and Drug Administration (FDA) for the prophylaxis of cisplatin-induced nephrotoxicity and as an antidote for cyanide poisoning. It has also been used for the management of disorders of calcium homeostasis, such as recurrent calcium stones or tumoral calcinosis [4]. The mechanism of action is thought to be a result of its ability to dissolve calcium deposits into soluble calcium thiosulfate complexes and potentially act as an antioxidant [4,7]. Since 2004, case reports of 3 or fewer subjects have described the use of STS for calciphylaxis in end-stage kidney disease, with the majority reporting dramatic improvement [8]. STS was used intraperitoneally in a patient intolerant to intravenous administration with good outcome [8]. STS has been reported for the treatment of calciphylaxis in a patient with normal renal and parathyroid function [9,10]. However, a recent retrospective study showed that, although STS is an effective treatment for the pain and skin lesions, it has little impact on overall mortality compared to historical published cohorts [8]. Adverse reactions to STS are usually mild and include nausea, vomiting, headache, rhinorrhea, and anion gap metabolic acidosis. There are no specific contraindications [3,4,7].

We decided to commence treatment with STS for our patients because chronic kidney disease or hyperparathyroidism did not seem to play a causal role in their calciphylaxis. We achieved good results with improvement of pain and slow healing of ulcerations over a period of months, as described in the literature. The drug was well tolerated. The death of the first patient was not related to this treatment.

In conclusion, we report two new “non-traditional” patients with calciphylaxis who had excellent responses to sodium thiosulfate. We should keep in mind the diagnosis of calciphylaxis if there is a suggestive clinical picture even if kidney disease and hyperparathyroidism are not present. Given the mortality associated with calciphylaxis, sodium thiosulfate appears to be a reasonable therapeutic strategy for most patients.

## References

1. Kalajian AH, Malhotra PS, Callen JP, [Parker LP](#). 1. Calciphylaxis with normal renal and parathyroid function: not as rare as previously believed. *Arch Dermatol*. 2009 Apr;145(4):451-8. [PMID: 19380668]
2. Weenig RH, Sewell LD, Davis MD, [McCarthy JT](#), [Pittelkow MR](#). Calciphylaxis: natural history, risk factor analysis, and outcome. *J Am Acad Dermatol*. 2007 Apr;56(4):569-79. [PMID: 17141359]
3. Ng AT, Peng DH. Calciphylaxis. *Dermatol Ther*. 2011 Mar-Apr;24(2):256-62. [PMID: 21410615]
4. Raymond CB, Wazny LD, Sood AR. Sodium thiosulfate, bisphosphonates, and cinacalcet for calciphylaxis. *CANNT J*. 2009 Oct-Dec;19(4):25-7. [PMID: 20136032]
5. Brandenburg VM, Cozzolino M, Ketteler M. Calciphylaxis: a still unmet challenge. *J Nephrol*. 2011 Mar-Apr;24(2):142-8. [PMID: 21337312]
6. Nigwekar SU, Wolf M, Sterns RH, [Hix JK](#). Calciphylaxis from nonuremic causes: a systematic review. *Clin J Am Soc Nephrol*. 2008 Jul;3(4):1139-43. [PMID: 18417747]
7. Ross EA. Evolution of treatment strategies for calciphylaxis. *Am J Nephrol*. 2011;34(5):460-7. [PMID: 21986387]
8. Nouredine L, Landis M, Patel N, [Moe SM](#). Efficacy of sodium thiosulfate for the treatment for calciphylaxis. *Clin Nephrol*. 2011 Jun;75(6):485-90. [PMID: 21612750]
9. Hackett BC, McAleer MA, Sheehan G, [Powell FC](#), [O'Donnell BF](#). Calciphylaxis in a patient with normal renal function: response to treatment with sodium thiosulfate. *Clin Exp Dermatol*. 2009 Jan;34(1):39-42. [PMID: 18627391]
10. Ong S, Coulson IH. Normo-renal calciphylaxis: response to sodium thiosulfate. *J Am Acad Dermatol*. 2011 May;64(5):e82-4. [PMID: 21496692]