

UC Irvine

UC Irvine Previously Published Works

Title

Transcutaneous retrobulbar amphotericin B for rhino-orbital-cerebral mucormycosis: a multi-center retrospective comparative study

Permalink

<https://escholarship.org/uc/item/17t1d1cf>

Journal

Orbit, 43(1)

ISSN

0167-6830

Authors

Dallalzadeh, Liane O
Ediriwickrema, Lilangi S
Fung, Sammie E
[et al.](#)

Publication Date

2024-01-02

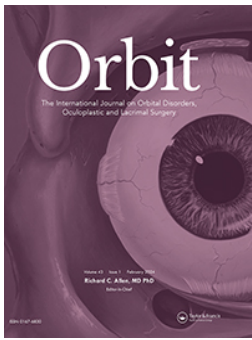
DOI

10.1080/01676830.2023.2186435

Copyright Information

This work is made available under the terms of a Creative Commons Attribution License, available at <https://creativecommons.org/licenses/by/4.0/>

Peer reviewed



Orbit

The International Journal on Orbital Disorders, Oculoplastic and
Lacrimal Surgery

ISSN: (Print) (Online) Journal homepage: www.tandfonline.com/journals/iorb20

Transcutaneous retrobulbar amphotericin B for rhino-orbital-cerebral mucormycosis: a multi- center retrospective comparative study

Liane O. Dallalzadeh, Lilangi S. Ediriwickrema, Sammie E. Fung, Clara J. Men,
Andrea L. Kossler, Anna C. Kupcha, Louise A. Mawn, Cat N. Burkat, Suzanne
W. van Landingham, Jordan R. Conger, Brittany Simmons, Chau Pham, Sruti
S. Akella, Pete Setabutr, Tiffany Ho, Steven M. Couch, Jane S. Kim, Hakan
Demirci, Bobby S. Korn, Don O. Kikkawa & Catherine Y. Liu

To cite this article: Liane O. Dallalzadeh, Lilangi S. Ediriwickrema, Sammie E. Fung, Clara J. Men, Andrea L. Kossler, Anna C. Kupcha, Louise A. Mawn, Cat N. Burkat, Suzanne W. van Landingham, Jordan R. Conger, Brittany Simmons, Chau Pham, Sruti S. Akella, Pete Setabutr, Tiffany Ho, Steven M. Couch, Jane S. Kim, Hakan Demirci, Bobby S. Korn, Don O. Kikkawa & Catherine Y. Liu (2024) Transcutaneous retrobulbar amphotericin B for rhino-orbital-cerebral mucormycosis: a multi-center retrospective comparative study, *Orbit*, 43:1, 41-48, DOI: [10.1080/01676830.2023.2186435](https://doi.org/10.1080/01676830.2023.2186435)

To link to this article: <https://doi.org/10.1080/01676830.2023.2186435>



Published online: 07 Mar 2023.



Submit your article to this journal [↗](#)



Article views: 213



View related articles [↗](#)

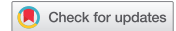

View Crossmark data [↗](#)



Citing articles: 1 View citing articles [↗](#)

RESEARCH ARTICLE



Transcutaneous retrobulbar amphotericin B for rhino-orbital-cerebral mucormycosis: a multi-center retrospective comparative study

Liane O. Dallalzadeh^a, Lilangi S. Ediriwickrema^b, Sammie E. Fung^a, Clara J. Men^c, Andrea L. Kossler^c, Anna C. Kupcha^d, Louise A. Mawn^d, Cat N. Burkat^e, Suzanne W. van Landingham^e, Jordan R. Conger^b, Brittany Simmons^f, Chau Pham^f, Sruti S. Akella^g, Pete Setabutr^g, Tiffany Ho^h, Steven M. Couch^h, Jane S. Kimⁱ, Hakan Demirciⁱ, Bobby S. Korn^{aj}, Don O. Kikkawa^{aj}, and Catherine Y. Liu^a

^aDivision of Oculofacial Plastic and Reconstructive Surgery, Viterbi Family Department of Ophthalmology, Shiley Eye Institute, UC San Diego, La Jolla, California, USA; ^bDivision of Ophthalmic Plastic and Reconstructive Surgery, Gavin Herbert Eye Institute, UC Irvine, Irvine, California, USA; ^cDivision of Oculoplastic and Orbital Surgery, Byers Eye Institute, Stanford University, Palo Alto, California, USA; ^dDivision of Oculoplastics and Orbital Disease, Vanderbilt Eye Institute, Vanderbilt University, Nashville, Tennessee, USA; ^eOculoplastic, Orbital, & Cosmetic Facial Surgery, Department of Ophthalmology and Visual Sciences, University of Wisconsin Madison, Madison, Wisconsin, USA; ^fDivision of Oculoplastic, Orbit, and Reconstructive Surgery, Department of Ophthalmology and Visual Sciences, University of Iowa, Iowa City, Iowa, USA; ^gOculoplastic and Reconstructive Surgery Service, Illinois Eye and Ear Infirmary, University of Illinois, Chicago, Illinois, USA; ^hDivision of Oculofacial Plastic and Reconstructive Surgery, Department of Ophthalmology and Visual Sciences, Washington University in St. Louis, St. Louis, Missouri, USA; ⁱDivision of Eye Plastic, Orbital and Facial Cosmetic Surgery, Kellogg Eye Center, University of Michigan, Ann Arbor, Michigan, USA; ^jDivision of Plastic and Reconstructive Surgery, UC San Diego Department of Surgery, La Jolla, California, USA

ABSTRACT

Purpose: To assess whether transcutaneous retrobulbar amphotericin B injections (TRAMB) reduce exenteration rate without increasing mortality in rhino-orbital-cerebral mucormycosis (ROCM).

Methods: In this retrospective case–control study, 46 patients (51 eyes) with biopsy-proven ROCM were evaluated at 9 tertiary care institutions from 1998 to 2021. Patients were stratified by radiographic evidence of local orbital versus extensive involvement at presentation. Extensive involvement was defined by MRI or CT evidence of abnormal or loss of contrast enhancement of the orbital apex with or without cavernous sinus, bilateral orbital, or intracranial extension. Cases (+TRAMB) received TRAMB as adjunctive therapy while controls (–TRAMB) did not. Patient survival, globe survival, and vision/motility loss were compared between +TRAMB and –TRAMB groups. A generalized linear mixed effects model including demographic and clinical covariates was used to evaluate the impact of TRAMB on orbital exenteration and disease-specific mortality.

Results: Among eyes with local orbital involvement, exenteration was significantly lower in the +TRAMB group (1/8) versus –TRAMB (8/14) ($p = 0.04$). No significant difference in mortality was observed between the ±TRAMB groups. Among eyes with extensive involvement, there was no significant difference in exenteration or mortality rates between the ±TRAMB groups. Across all eyes, the number of TRAMB injections correlated with a statistically significant decreased rate of exenteration ($p = 0.048$); there was no correlation with mortality.

Conclusions: Patients with ROCM with local orbital involvement treated with adjunctive TRAMB demonstrated a lower exenteration rate and no increased risk of mortality. For extensive involvement, adjunctive TRAMB does not improve or worsen these outcomes.

ARTICLE HISTORY

Received 14 October 2022
Accepted 25 February 2023

KEYWORDS

Orbit; mucormycosis; retrobulbar; amphotericin B; injection

Introduction

Rhino-orbital-cerebral mucormycosis (ROCM) is a rare, highly morbid, and often fatal opportunistic infection. Presence of fungal colonization of the paranasal sinuses is common due to the inhalation of fungal spores. In the setting of an immunocompromised host, this colonization may evolve into invasive infection and spread from the paranasal sinuses to the intraorbital and intracranial spaces via ischemic vasculitis resulting in tissue infarction and necrosis.¹ Susceptible patients are most often those immunosuppressed due to diabetes mellitus, hematologic

malignancy, or solid organ transplantation.² The global rise in COVID-19 has also resulted in an unprecedented increase in mucormycosis infections, termed COVID-19 associated mucormycosis.^{3–9} This is commonly seen in diabetic patients infected with COVID-19, though it has also been described in immunocompetent and non-diabetic patients.^{10,11}

Current standard of care for ROCM involves reversal of immunocompromising conditions where possible, systemic antifungal therapy, and debridement of devitalized tissue. Due to the angioinvasive nature of the disease with

resultant tissue destruction, systemic antifungal therapy alone is insufficient secondary to limited tissue penetration.¹² Debridement of necrotic tissue is thus key as it reduces fungal load, provides specimen for biopsy/culture, and improves penetration of both systemic antifungal therapy and host immune response.^{13,14} Further, functional endoscopic sinus surgery with debridement of affected tissues has been demonstrated to improve survival.^{15,16} Adjunctive systemic therapies include additional antifungal agents and hyperbaric oxygen (HBO). Additional agents may include triazoles, specifically posaconazole and isavuconazole, used for de-escalation or for patients intolerant to amphotericin B.¹⁷ Echinocandins such as micafungin and caspofungin are also used as salvage therapy, and while they are not inherently active against mucormycosis, there is some evidence they may augment amphotericin B.¹⁷ Hyperbaric oxygen is thought to allow direct delivery of oxygen to ischemic tissue, enhance the oxygen-dependent mechanisms of host leukocytes, and inhibit fungal growth. However, outcomes regarding HBO for invasive fungal sinusitis are mixed and animal models have demonstrated no improved survival.^{18–20}

Debate remains regarding management of ROCM within the orbit. Traditionally, exenteration can be employed; however, this is disfiguring, and a survival benefit has yet to be demonstrated.^{15,21–23} Further, orbital disease is associated with a poorer prognosis, given the direct access to the intracranial space via the orbital apex.¹⁴ Several prior studies have proposed adjunctive orbital therapy. These have included conservative debridement of necrotic orbital tissue in conjunction with intraoperative irrigation of amphotericin B, placement of indwelling orbital catheters for local administration of amphotericin B, and transcutaneous retrobulbar injections of amphotericin B (TRAMB).^{24–33} The purpose of this study is to describe a multi-institutional experience with TRAMB as adjunctive therapy for ROCM in cases of both local orbital and extensive involvement.

Methods

Cohort assembly

This is a multi-institution retrospective comparative study of adult patients with ROCM treated with transcutaneous retrobulbar amphotericin B injections (+TRAMB) or without injections (–TRAMB) as an adjunct to traditional management. Approval was obtained by the Institutional Review Boards at the University of California San Diego, Stanford University, Vanderbilt University, University of Wisconsin Madison, University of California Irvine, University of Iowa, University of Illinois Chicago,

Washington University in St. Louis, and University of Michigan. This report adheres to the ethical principles outlined in the Declaration of Helsinki as amended in 2013 and is HIPAA compliant. This manuscript describes an off-label use of amphotericin B.

Patients were identified via electronic medical record review of those presenting to the ophthalmology or oculoplastic consult services from 1998 to 2021 with assigned ICD-9 and ICD-10 codes corresponding with a diagnosis of rhino-orbital-cerebral mucormycosis. Demographics, medications, clinical examinations, laboratory reports, operative reports, pathology reports, and radiographic reports were extracted from electronic medical records. Inclusion criteria included age ≥ 18 years and sinus culture and/or biopsy confirming fungi of the phylum *Mucormycota* (including *Rhizopus* and *Mucor*). Exclusion criteria included patients presenting with invasive fungal sinusitis caused by organisms of other phyla or that which did not involve the orbit. Records were subsequently reviewed individually by investigators to divide participants into two groups: extensive or local orbital involvement at presentation. Extensive orbital involvement was defined by MRI or CT evidence of abnormal or loss of contrast enhancement of the orbital apex with or without cavernous sinus, bilateral orbital, or intracranial extension. Local involvement was defined by MRI or CT evidence of abnormal or loss of contrast enhancement within the orbit without apical involvement. All patients received functional endoscopic sinus surgery with debridement and intravenous amphotericin B with reversal of immunocompromising comorbidities where possible.

Study design

Demographic factors, predisposing comorbidities (including diabetes mellitus, solid-organ transplantation, and hematologic malignancy), adjunctive systemic antifungals (azoles or echinocandins), and adjunctive HBO were extracted from the medical record of +TRAMB and -TRAMB patients.

Presenting visual acuity (measured at the hospital bedside using a Rosenbaum near vision acuity card at 14 inches with corrective lenses when available) was obtained except for patients presenting with altered mental status. Final visual acuity was assessed either similarly or with a Snellen chart at distance, subject to whether a patient's final exam took place in the hospital or clinic. Visual acuity was converted to the logarithm of minimum angle of resolution (logMAR) for statistical analysis, with count fingers, hand motion, light perception represented as 1.86, 2.30, 2.78, respectively.³⁴ For patients exenterated, final visual acuity was defined as no light perception represented as 2.78.

Presenting and final ophthalmoplegia were graded as 1 point for every duction affected irrespective of the degree of impacted motility yielding a score of 0 (full ductions) to 4 (supra-, infra-, add-, and abduction affected). This was to account for difference in motility grading schemes across multiple participating centers. Presenting and final signs of orbital congestion were also graded as 1 point for the presence of proptosis, eyelid edema, eyelid erythema, conjunctival chemosis, or conjunctival injection yielding a score of 0 to 5. For patients who were exenterated, final ophthalmoplegia and orbital congestion were defined as the scores at the last exam prior to exenteration.

For the +TRAMB group, the total number of TRAMB injections was extracted along with any reported adverse events. Injections consisted of compounded amphotericin B in a prefilled syringe. Patients were anesthetized with 2 mg intravenous morphine or the equivalent dose of intravenous hydromorphone or fentanyl. One patient received a peribulbar block of 2% lidocaine mixed 1:1 with 0.5% bupivacaine per preference. A 23 or 25-gauge retrobulbar needle was used to deliver 1 mL of liposomal amphotericin B transcutaneously to the retrobulbar space. Patients were observed after each injection for signs of orbital compartment syndrome. At time of study, all participating centers adopted TRAMB into their ROCM management protocol, however due to the retrospective and multi-institutional nature of this study, the exact injection protocol varied across participating centers. The liposomal formulation was preferred given it has been shown to induce less inflammation, with one eye receiving the deoxycholate formulation.³³ All patients except one received 1 mL of 3.5 mg/mL amphotericin B; the remaining patient instead received a single injection of 1 mL of 1.5 mg/mL. Frequency of injection was subject to the institution's practice at the time with the most common protocols being an initial loading of three daily injections; thereafter, injections were continued daily or every other day. Among cases with extensive involvement, injections were continued until either exenteration, death, or transition to comfort care. Among cases with local orbital involvement, injections were continued until clinical examination (visual acuity, ophthalmoplegia, and orbital congestion) was considered to have stabilized, exenteration, or death.

Primary outcome measures included rate of orbital exenteration and disease-specific mortality.

Statistical analysis

Demographic and clinical characteristics of cases and controls were compared via two-sided t-tests or Fisher's

exact tests. Eyes were then stratified into local orbital and extensive involvement. For patients with bilateral orbital involvement, each eye was analyzed as a separate unit. Visual acuity at presentation and final exam was compared between +TRAMB and -TRAMB groups via two-sided t-tests for each stratum. Ophthalmoplegia and orbital congestion at presentation and final exam were compared between +TRAMB and -TRAMB groups via Wilcoxon rank-sum tests for each stratum. Patients unable to participate in visual acuity or extraocular motility assessments due to altered mental status and those with missing data were excluded from these analyses. Generalized linear mixed effects models (GLMM) were used to evaluate the effect of these demographic and clinical features on exenteration and mortality. The use of GLMM allowed control for the within-subject variability and random intercept associated with correlated eyes of the same subject, due to our cohort including some patients with two effected eyes. Variables that had a statistically significant relationship ($p \leq 0.05$) or a nearly significant relationship ($p < 0.20$) to exenteration or disease-specific mortality in univariate models were included in subsequent multivariate models. Analyses were conducted with R (R Core Team; Vienna, Austria) and figures were made with GraphPad Prism 9.0.0 (GraphPad Software LLC; San Diego, California).

Results

Forty-six patients met inclusion criteria. Of these, four patients presented with bilateral orbital involvement and one patient was admitted twice for sequential unilateral infections, for a total of 51 eyes. Twenty-three eyes received TRAMB (+TRAMB), 15 with extensive and 8 with local orbital involvement at presentation. Twenty-eight eyes served as controls (-TRAMB), 14 with extensive and 14 with local orbital involvement at presentation.

Table 1 presents demographic and clinical features of both -TRAMB and +TRAMB eyes. Notably, there was no statistically significant difference in age, sex, or use of adjunctive therapies such as azoles, echinocandins, or hyperbaric oxygen therapy. When further stratified by extent of involvement, there was no statistically significant difference in use of adjunctive azoles ($p = 0.38, 0.35$) or echinocandins ($p = 0.25, 0.70$) for local orbital or extensive disease, respectively. Both \pm TRAMB groups demonstrated no significant difference in prevalence of diabetes mellitus or solid organ transplantation. However, hematologic malignancy as a predisposing immunocompromising comorbidity was significantly more prevalent in -TRAMB controls.

Table 1. Demographic and clinical characteristics of patients with ROCM.

	-TRAMB N = 28	+TRAMB N = 23	p-value*
Age (years, mean ± SD)	58.6 ± 12.5	54.5 ± 12.1	.25
Sex (male, %)	85.7	69.6	.19
Immunocompromising comorbidities (%)			
Diabetes mellitus	82.1	91.3	.44
Solid organ transplant	10.7	17.4	.69
Hematologic malignancy	35.7	8.7	.04
Other	3.6	21.7	.08
Adjunct systemic antifungal (%)			
Azoles	71.4	47.8	.15
Echinocandins	35.7	21.7	.36
Hyperbaric oxygen therapy (%)	17.9	34.8	.22

*Continuous variables compared by two-sided t-test. Categorical variables compared by two-tailed Fisher's exact test.

In the local orbital involvement group, visual acuity, ophthalmoplegia, and orbital congestion were evaluated at presentation and final exam (Table 2). There was no statistically significant difference in visual acuity, ophthalmoplegia, or orbital congestion at presentation between -TRAMB and +TRAMB eyes. Visual acuity improved in +TRAMB eyes at final exam relative to -TRAMB, with borderline statistical significance ($p = 0.051$). Ophthalmoplegia improved in +TRAMB eyes as well, though this finding was not significant ($p = 0.074$). There was no significant difference in orbital congestion between -TRAMB and +TRAMB eyes at final exam.

In the extensive involvement group, visual acuity, ophthalmoplegia, and orbital congestion at presentation and final exam were also evaluated (Table 3). There was no statistically significant difference in visual acuity, ophthalmoplegia, or orbital congestion at presentation between -TRAMB and +TRAMB eyes. Visual acuity at final exam worsened in both groups, and there was no

improvement in ophthalmoplegia for either group. Notably, orbital congestion was significantly worse in +TRAMB eyes at final exam relative to -TRAMB.

Regarding exenteration, there was a significantly decreased rate of exenteration for eyes with local orbital involvement that received TRAMB (1/8) versus those that did not (8/14) ($p = 0.04$) (Figure 1). However, among eyes with extensive involvement, there was no significant difference in rate of exenteration between +TRAMB (4/15) and -TRAMB (6/14) ($p = 0.38$) (Figure 2). Table 4 summarizes demographic and clinical correlates of exenteration amongst all eyes determined by univariate and multivariate generalized linear mixed effects models (GLMM). Of these, males and those who received adjunctive intravenous echinocandins had a nearly significant increased rate of exenteration ($p < 0.20$). The number of TRAMB injections correlated with a statistically significant decreased rate of exenteration ($p = 0.03$). This correlation remained significant in a multivariate GLMM model controlling for sex and adjunctive echinocandins

Table 2. Visual acuity, ophthalmoplegia, and orbital congestion at presentation and final exam for local orbital involvement.

	-TRAMB N = 10	+TRAMB N = 5	p-value*
Visual Acuity (logMAR median [IQR])			
Presentation	0.54 [0.13, 2.42]	0.18 [0.05, 0.24]	.095
Final	1.54 [0.00, 2.78]	0.10 [0.00, 0.14]	.051
Ophthalmoplegia[#] (median [IQR])			
Presentation	4.00 [0.75, 4.00]	1.00 [0.50, 4.00]	.574
Final	4.00 [0.50, 4.00]	0.00 [0.00, 2.00]	.074
Orbital Congestion^Δ (median [IQR])			
Presentation	3.00 [1.50, 4.00]	1.00 [0.50, 2.50]	.117
Final	1.00 [0.00, 3.50]	1.00 [0.00, 2.50]	.582

*Continuous variables (logMAR) compared with two-sided t-test. Ranked numeric variables (ophthalmoplegia, orbital congestion) compared with Wilcoxon rank-sum test.

[#]Graded as 1 point for every duction affected 0 (full ductions) to 4 (complete ophthalmoplegia).

^ΔGraded as 1 point for proptosis, chemosis, conjunctival injection, eyelid edema, eyelid erythema, 0 (none) to 5 (all).

Table 3. Visual acuity, ophthalmoplegia, and orbital congestion at presentation and final exam for extensive involvement.

	-TRAMB N = 12	+TRAMB N = 7	p-value*
Visual Acuity (logMAR median [IQR])			
Presentation	1.20 [0.33, 2.78]	0.54 [0.30, 2.78]	.598
Final	2.78 [0.30, 2.78]	2.78 [1.30, 2.78]	.773
Ophthalmoplegia (median [IQR])			
Presentation	4.00 [1.50, 4.00]	4.00 [1.00, 4.00]	.883
Final	3.00 [0.50, 4.00]	4.00 [1.00, 4.00]	.713
Orbital Congestion (median [IQR])			
Presentation	0.00 [0.00, 2.00]	2.00 [0.25, 3.00]	.074
Final	1.00 [0.00, 2.75]	2.00 [1.00, 4.00]	.047

*Continuous variables (logMAR) compared with two-sided t-test. Ranked numeric variables (ophthalmoplegia, orbital congestion) compared with Wilcoxon rank-sum test.

[#]Graded as 1 point for every duction affected 0 (full ductions) to 4 (complete ophthalmoplegia).

^ΔGraded as 1 point for proptosis, chemosis, conjunctival injection, eyelid edema, eyelid erythema, 0 (none) to 5 (all).

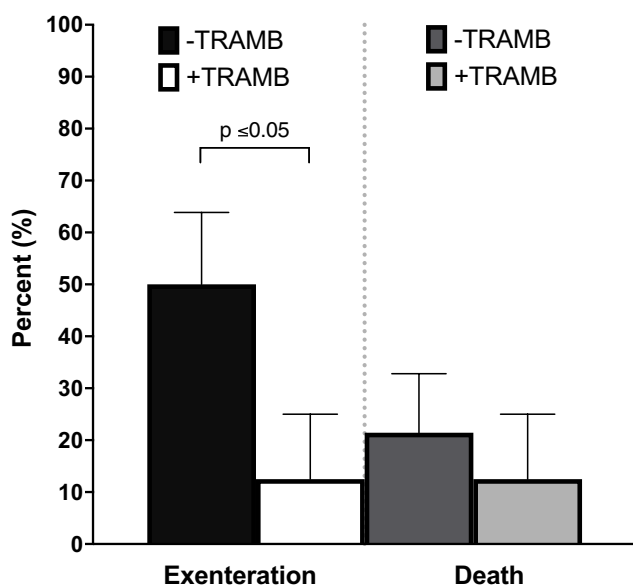


Figure 1. Exenteration and death for ROCM with local orbital involvement (mean \pm SEM).

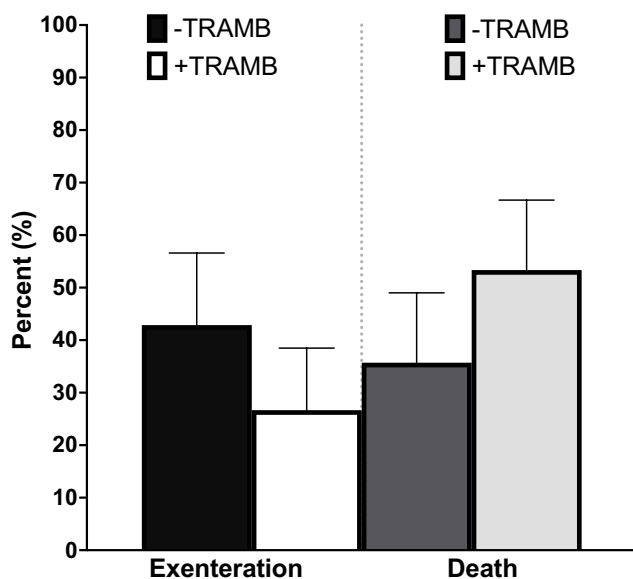


Figure 2. Exenteration and death for ROCM with extensive involvement (mean \pm SEM).

($p = 0.048$). Notably, extensive involvement was not associated with significantly increased rate of exenteration ($p = 0.43$).

There was no significant difference in disease-specific mortality among eyes with local orbital involvement that received TRAMB (1/8) versus those that did not (3/14) ($p = 0.62$) (Figure 1). Similarly, there was no significant difference in death among eyes with extensive involvement that received TRAMB (8/15) and those that did not (5/14) ($p = 0.36$) (Figure 2). Table 5 summarizes demographic and clinical correlates of mortality amongst all eyes determined by GLMM. No variable conferred statistical significance. However, extensive involvement yielded an odds ratio of 16.92. Notably, the number of injections was not correlated with mortality.

The median [interquartile range] number of TRAMB injections was 3 [2,6] with a range of 1 to 20. Frequency of injections varied by institution either as a daily or every other day, with only one case receiving an injection every 2 days. Of the 23 cases, 16 began TRAMB within 1 day of presentation. The remaining seven initiated injections based on declining visual acuity. Five of the 23 eyes (21.7%) suffered adverse effects. All five demonstrated interval increase in orbital congestion with worsened chemosis. Of these, one patient also developed an interval 1.5cc admixture of amphotericin B and debris within the extraconal inferior orbit that required drainage by orbitotomy. This was thought to have resulted from precipitation of amphotericin B in the setting of ten consecutive TRAMB injections.

Discussion

Orbital involvement of mucormycosis is associated with poor prognosis and unfortunately there is no consensus on management of orbital disease.¹⁴ Exenteration has traditionally been employed to decrease risk of direct intracranial extension via the orbital apex. However, a prior meta-analysis and two retrospective series found lack of survival benefit, while a second meta-analysis found a survival benefit only in patients presenting with fever.^{15,21–23} It remains unclear whether

Table 4. Univariate and multivariate correlates of exenteration.

N = 51	Regression coefficient	Univariate p-value	Multivariate p-value	Odds Ratio
Age (years)	0.01	0.53		1.01
Sex (male)	1.30	0.12	0.297	2.56
Extensive involvement	-0.46	0.43		0.84
Adjunctive systemic antifungal				
Azoles	-0.05	0.93		0.50
Echinocandins	0.83	0.19	0.376	2.75
Number of TRAMB injections	-0.47	0.03	0.048	0.54

Table 5. Univariate correlates of disease-specific mortality.

N = 51	Regression coefficient	p-value	Odds Ratio
Age (years)	0.01	.91	1.06
Sex (male)	-0.42	.90	0.68
Extensive involvement	1.32	.68	16.92
Adjunctive systemic antifungal			
Azoles	-0.40	.89	1.76
Echinocandins	-0.16	.96	0.96
Number of TRAMB injections	-0.07	.88	0.75

exenteration benefits patients with mild orbital disease at the expense of vision loss and disfigurement.

Given the unclear survival benefits of exenteration, alternative strategies such as conservative orbital debridement with or without intraoperative irrigation of amphotericin B and indwelling orbital catheters or drains have been reported.^{24–28,33} These methods, while less invasive than exenteration, require either surgical removal of necrotic orbital contents or placement of a catheter or drain potentially introducing an additional nidus for infection. Compared to these methods, TRAMB injections are minimally invasive and conveniently can be performed at bedside.^{13,21,33}

The overall rate of exenteration for the controls (-TRAMB) in our study was 57% (local orbital involvement) and 43% (extensive involvement), which is similar to prior studies that reported rates of 21–57%.^{14,15,21} With TRAMB, the rate of exenteration was significantly lower in the local involvement group (12.5%), while disease-specific mortality was comparable (21% +TRAMB vs 13% -TRAMB). For extensive involvement, the rate of exenteration with TRAMB (27%) was not significantly different from that of controls. This may reflect patients with severe disease adopting comfort care measures or being unfit for general anesthesia. Mortality rates for this group were similar with or without retrobulbar injections, 36% +TRAMB vs 53% -TRAMB. No demographic or clinical variables, including number of TRAMB injections, correlated with a survival benefit. In our multivariate analyses, extensive involvement by itself yielded a nearly 17-fold greater odds of disease-specific mortality, following that extent of disease is the strongest predictor of mortality.³⁵

For local orbital involvement, visual acuity improved at final exam in the +TRAMB group, possibly due to the number of eyes saved from exenteration, conferring with borderline statistical significance. Improvement in ophthalmoplegia with TRAMB trended towards significance at final exam. Orbital congestion at final exam was not significantly different between \pm TRAMB for local orbital involvement. Notably, there was a significant worsening of orbital congestion by final exam for +TRAMB eyes with extensive involvement. Amphotericin B is known to incite edema and

inflammation when administered locally, as it induces the expression of pro-inflammatory cytokines including TNF- α , IL-6, and IL-1.^{36,37} When injected into the orbit, this inflammatory reaction manifests as increased orbital congestion. Further, frequent injections add volume to an already confined space. Additional studies evaluating long-term effects post amphotericin injections are needed.

This study has several limitations. First, it was retrospective and therefore patients were not randomized to the intervention. Second, variation exists in the injection protocol adopted by each institution. Given the rarity of ROCM and resulting limitations in sample size, there has been no prospective study to date evaluating TRAMB, and thus the optimal injection protocol including frequency of injections and endpoint to cease therapy remains to be determined.³⁸ Third, we did not stratify patients further by radiographic features of contrast enhancement, as has been previously suggested.^{13,33,39–42} Further, our cohort of extensive involvement includes patients with apical disease with and without intracranial spread. Disease-specific mortality expectedly is increased with central nervous system involvement, with the expectation that TRAMB would not be curative once disease has reached the CNS. Our findings are consistent with this expectation.

Determining the effect of TRAMB on exenteration and disease-specific mortality in patients with apical enhancement alone is an important area of continued study.³³

In this multi-institutional retrospective comparative study, patients with ROCM with local orbital involvement treated with adjunctive TRAMB demonstrated clinically improved visual acuity, a decreased rate of exenteration, and no increased rate of mortality compared to those treated with standard therapy. Clinicians may consider TRAMB injections a useful minimally invasive and globe-sparing adjuvant therapy in these patients.

Acknowledgements

Evan Walker, MS UCSD Health research data analyst - statistical support; Sasan Moghimi, MD UCSD Shiley Eye Institute - statistical support, Sherya A. Shah, BA Stanford School of Medicine - data collection.

Disclosure statement

None of the following disclosures are relevant to the subject of this manuscript.

Andrea L. Kossler – consultant for Horizon Therapeutics and Immunovant.

Suzanne W. van Landingham – former consultant for Horizon Therapeutics.

Don O. Kikkawa – former consultant with Horizon Therapeutics, royalties from Elsevier, Ltd.

Bobby S. Korn – former consultant with Horizon Therapeutics, royalties from Elsevier, Ltd.

Catherine Y. Liu – site principal investigator for a Horizon Therapeutics-sponsored clinical trial, royalties from Wolter Kluwers Health.

Remaining authors – no disclosures.

Funding

This report was supported by an unrestricted grant from Research to Prevent Blindness (New York, NY).

Meeting presentation

This material in part was presented at the American Society of Ophthalmic Plastic and Reconstructive Surgery virtual fall scientific symposium in November 2020 as an oral presentation.

References

1. Colon-Acevedo B, Kumar J, Richard MJ, Woodward JA. The role of adjunctive therapies in the management of invasive sino-orbital infection. *Ophthalmic Plast Reconstr Surg.* 2015;31(5):401–405. doi:10.1097/IOP.0000000000000488.
2. Prabhu RM, Patel R. Mucormycosis and entomophthoromycosis: a review of the clinical manifestations, diagnosis and treatment. *Clin Microbiol Infect.* 2004;10(Suppl 1):31–47. doi:10.1111/j.1470-9465.2004.00843.x.
3. Riad A, Shabaan AA, Issa J, Ibrahim S, Amer H, Mansy Y, et al. COVID-19-associated mucormycosis (CAM): case-series and global analysis of mortality risk factors. *J Fungi (Basel).* 2021;7(10):837. doi:10.3390/jof7100837.
4. Chao CM, Lai CC, Yu WL. COVID-19 associated mucormycosis - an emerging threat. *J Microbiol Immunol Infect.* 2022;55(2):183–190.
5. Dallalzadeh LO, Ozzello DJ, Liu CY, Kikkawa DO, Korn BS. Secondary infection with rhino-orbital cerebral mucormycosis associated with COVID-19. *Orbit.* 2021;1–4. doi:10.1080/01676830.2021.1903044.
6. Sen M, Honavar SG, Bansal R, Sengupta S, Rao R, Kim U, et al. Epidemiology, clinical profile, management, and outcome of COVID-19-associated rhino-orbital-cerebral mucormycosis in 2826 patients in India - Collaborative OPAI-IJO Study on Mucormycosis in COVID-19 (COSMIC), Report 1.

Indian J Ophthalmol. 2021;69(7):1670–1692. doi:10.4103/ijo.IJO_1565_21.

7. Dave TV, Gopinathan Nair A, Hegde R, Vithalani N, Desai S, Adulkar N, et al. Clinical presentations, management and outcomes of rhino-orbital-cerebral mucormycosis (ROCM) following COVID-19: a multi-centric study. *Ophthalmic Plast Reconstr Surg.* 2021;37(5):488–495. doi:10.1097/IOP.0000000000002030.
8. Fakhar M, Sharifpour A, Zakariaei Z, Banimostafavi ES, Soleymani M, Davoodi L. Rhino-orbital-cerebral mucormycosis in a post-COVID-19 diabetic patient: rare case from Iran. *Clin Case Rep.* 2022;10(2):e05506. doi:10.1002/ccr3.5506.
9. Patel R, Jethva J, Bhagat PR, Prajapati V, Thakkar H, Prajapati K. Rhino-orbital-cerebral mucormycosis: an epidemiological study from a tertiary care referral center in Western India. *Indian J Ophthalmol.* 2022;70(4):1371–1375. doi:10.4103/ijo.IJO_2943_21.
10. Mohammadi F, Badri M, Safari S, Hemmat N. A case report of rhino-facial mucormycosis in a non-diabetic patient with COVID-19: a systematic review of literature and current update. *BMC Infect Dis.* 2021;21(1):906. doi:10.1186/s12879-021-06625-3.
11. Nair AG, Adulkar AG, D'Cunha L, Rao PR, Bradoo RA, Bapaye M, et al. Rhino-orbital mucormycosis following COVID-19 in previously non-diabetic patients. *Orbit.* 2021;40(6):499–504. doi:10.1080/01676830.2021.1960382.
12. Ibrahim AS, Spellberg B, Avanesian V, Fu Y, Edwards JE. Rhizopus oryzae adheres to, is phagocytosed by, and damages endothelial cells in vitro. *Infect Immun.* 2005;73(2):778–783. doi:10.1128/IAI.73.2.778-783.2005.
13. Kalin-Hajdu E, Hirabayashi KE, Vagefi MR, Kersten RC. Invasive fungal sinusitis: treatment of the orbit. *Curr Opin Ophthalmol.* 2017;28(5):522–533. doi:10.1097/ICU.0000000000000394.
14. Trief D, Gray ST, Jakobiec FA, Durand ML, Fay A, Freitag SK, et al. Invasive fungal disease of the sinus and orbit: a comparison between mucormycosis and Aspergillus. *Br J Ophthalmol.* 2016;100(2):184–188. doi:10.1136/bjophthalmol-2015-306945.
15. Turner JH, Soudry E, Nayak JV, Hwang PH. Survival outcomes in acute invasive fungal sinusitis: a systematic review and quantitative synthesis of published evidence. *Laryngoscope.* 2013;123(5):1112–1118. doi:10.1002/lary.23912.
16. Yohai RA, Bullock JD, Aziz AA, Markert RJ. Survival factors in rhino-orbital-cerebral mucormycosis. *Surv Ophthalmol.* 1994;39(1):3–22. doi:10.1016/S0039-6257(05)80041-4.
17. Riley TT, Muzny CA, Swiatlo E, Legendre DP. Breaking the mold: a review of mucormycosis and current pharmacological treatment options. *Ann Pharmacother.* 2016;50(9):747–757. doi:10.1177/1060028016655425.
18. Couch L, Theilen F, Mader JT. Rhinocerebral mucormycosis with cerebral extension successfully treated with adjunctive hyperbaric oxygen therapy. *Arch Otolaryngol Head Neck Surg.* 1988;114:791–794. doi:10.1001/archotol.1988.01860190095032.
19. Ferguson BJ, Mitchell TG, Moon R, Camporesi EM, Farmer J. Adjunctive hyperbaric oxygen for treatment

- of rhinocerebral mucormycosis. *Rev Infect Dis.* 1988;10:551–559. doi:10.1093/clinids/10.3.551.
20. Barratt DM, Van Meter K, Asmar P, Nolan T, Trahan C, Garcia-Covarrubias L, et al. Hyperbaric oxygen as an adjunct in zygomycosis: randomized controlled trial in a murine model. *Antimicrob Agents Chemother.* 2001;45:3601–3602. doi:10.1128/AAC.45.12.3601-3602.2001.
 21. Kashkouli MB, Abdolalilzadeh P, Oghazian M, Hadi Y, Karimi N, Ghazizadeh M. Outcomes and factors affecting them in patients with rhino-orbito-cerebral mucormycosis. *Br J Ophthalmol.* 2019;103(10):1460–1465. doi:10.1136/bjophthalmol-2018-312688.
 22. Hirabayashi KE, Idowu OO, Kalin-Hajdu E, Oldenburg CE, Brodie FL, Kersten RC, et al. Invasive fungal sinusitis: risk factors for visual acuity outcomes and mortality. *Ophthalmic Plast Reconstr Surg.* 2019;35(6):535–542. doi:10.1097/IOP.0000000000001357.
 23. Hargrove RN, Wesley RE, Klippenstein KA, Fleming JC, Haik BG. Indications for orbital exenteration in mucormycosis. *Ophthalm Plast Reconstr Surg.* 2006;22:286–291. doi:10.1097/01.iop.0000225418.50441.ee.
 24. Luna JD, Ponssa XS, Rodríguez SD, Luna NC, Jaurez CP. Intraconal amphotericin B for the treatment of rhino-orbital mucormycosis. *Ophthalmic Surg Lasers.* 1996;27:706–708. doi:10.3928/1542-8877-19960801-10.
 25. Athavale DD, Jones R, O'Donnell BA, Forer M, Biggs N. Non-exenteration management of sino-orbital fungal disease. *Ophthalmic Plast Reconstr Surg.* 2017;33(6):426–429. doi:10.1097/IOP.0000000000000812.
 26. Pelton RW, Peterson EA, Patel BC, Davis K. Successful treatment of rhino-orbital mucormycosis without exenteration: the use of multiple treatment modalities. *Ophthalm Plast Reconstr Surg.* 2001;17:62–66. doi:10.1097/00002341-200101000-00012.
 27. Seiff SR, Choo PH, Carter SR. Role of local amphotericin B therapy for sino-orbital fungal infections. *Ophthalm Plast Reconstr Surg.* 1999;15:28–31. doi:10.1097/00002341-199901000-00007.
 28. Kahana A, Lucarelli MJ. Use of radiopaque intraorbital catheter in the treatment of sino-orbito-cranial mucormycosis. *Arch Ophthalmol.* 2007;125:1714–1715. doi:10.1001/archophth.125.12.1714.
 29. Joos ZP, Patel BC. Intraorbital irrigation of amphotericin B in the treatment of rhino-orbital mucormycosis. *Ophthalm Plast Reconstr Surg.* 2017;33:e13–16. doi:10.1097/IOP.0000000000000377.
 30. Saedi B, Sadeghi M, Seilani P. Endoscopic management of rhinocerebral mucormycosis with topical and intravenous amphotericin B. *J Laryngol Otol.* 2011;125:807–810. doi:10.1017/S0022215111001289.
 31. Hirabayashi KE, Kalin-Hajdu E, Brodie FL, Kersten RC, Russell MS, Vagefi MR. Retrobulbar injection of amphotericin B for orbital mucormycosis. *Ophthalmic Plast Reconstr Surg.* 2017;33(4):e94–97. doi:10.1097/IOP.0000000000000806.
 32. Safi M, Ang MJ, Patel P, Silkiss RZ. Rhino-orbital-cerebral mucormycosis (ROCM) and associated cerebritis treated with adjuvant retrobulbar amphotericin B. *Am J Ophthalmol Case Rep.* 2020;19:100771. doi:10.1016/j.ajoc.2020.100771.
 33. Ashraf DC, Idowu OO, Hirabayashi KE, Kalin-Hajdu E, Grob SR, Winn BJ, et al. Outcomes of a modified treatment ladder algorithm using retrobulbar amphotericin b for invasive fungal rhino-orbital sinusitis. *Am J Ophthalmol.* 2021. doi:10.1016/j.ajo.2021.05.025.
 34. Schulze-Bonsel K, Feltgen N, Burau H, Hansen L, Bach M. Visual acuities “hand motion” and “counting fingers” can be quantified with the Freiburg visual acuity test. *Invest Ophthalmol Vis Sci.* 2006;47(3):1236–1240. doi:10.1167/iovs.05-0981.
 35. Kupcha AC, Simmons BA, Law JJ, Liu Y, Chen Q, Shriver EM, et al. Association of age-adjusted Charlson comorbidity index with orbital fungal disease outcomes. *Ophthalmic Plast Reconstr Surg.* 2022;38(1):53–58. doi:10.1097/IOP.0000000000001987.
 36. Hamill RJ. Amphotericin B formulations: a comparative review of efficacy and toxicity. *Drugs.* 2013;73:919–934. doi:10.1007/s40265-013-0069-4.
 37. Sau K, Mambula SS, Latz E, Henneke P, Golenbock DT, Levitz SM. The antifungal drug amphotericin B promotes inflammatory cytokine release by a Toll-like receptor- and CD14-dependent mechanism. *J Biol Chem.* 2003;278(39):37561–37568. doi:10.1074/jbc.M306137200.
 38. Nair AG, Dave TV. Transcutaneous retrobulbar injection of amphotericin B in rhino-orbital-cerebral mucormycosis: a review. *Orbit.* October, 2021;31:1–12. doi:10.1080/01676830.2021.1990351.
 39. Gorovoy IR, Vagefi MR, Russell MS, Gorovoy M, Bloomer MM, Glastonbury CM. Loss of contrast enhancement of the inferior rectus muscle on magnetic resonance imaging in acute fulminant invasive fungal sinusitis. *Clin Exp Ophthalmol.* 2014;42(9):885–887. doi:10.1111/ceo.12337.
 40. Gorovoy IR, Kazanjian M, Kersten RC, Kim HJ, Vagefi MR. Fungal rhinosinusitis and imaging modalities. *Saudi J Ophthalmol.* 2012;26(4):419–426. doi:10.1016/j.sjopt.2012.08.009.
 41. Horger M, Hebart H, Schimmel H, Vogel M, Brodoefel H, Oechsle K, et al. Disseminated mucormycosis in haematological patients: CT and MRI findings with pathological correlation. *Br J Radiol.* 2006;79(945):e88–95. doi:10.1259/bjr/16038097.
 42. Kim JH, Kang BC, Lee JH. The prognostic value of gadolinium-enhanced magnetic resonance imaging in acute invasive fungal rhinosinusitis. *J Infect.* 2015;70(1):88–95. doi:10.1016/j.jinf.2014.07.027.