

# UCSF

## UC San Francisco Previously Published Works

### Title

Comparison between C1-2 Fixation with and without Supplemental Posterior Wiring.

### Permalink

<https://escholarship.org/uc/item/1835g6rr>

### Journal

Global Spine Journal, 5(1)

### ISSN

1663-7976

### Authors

Tran, Mai

Wadhwa, Rishi

Ziewacz, John

et al.

### Publication Date

2014-04-01

### DOI

10.1055/s-0034-1371972

Peer reviewed

# Comparison between C1–2 Fixation with and without Supplemental Posterior Wiring

Mai Tran<sup>1</sup> Rishi Wadhwa<sup>2</sup> John Ziewacz<sup>2</sup> Praveen Mummaneni<sup>2</sup> Dean Chou<sup>2</sup>

<sup>1</sup>Miller School of Medicine, University of Miami, Miami, Florida, United States

Address for correspondence Mai Tran, BS, 12520 SW 94th Lane, Miami, FL 33186, United States (e-mail: mttran@med.miami.edu).

<sup>2</sup>Department of Neurological Surgery, University of California San Francisco, San Francisco, California, United States

Evid Based Spine Care J 2014;5:12–15.

## Abstract

**Study Design** Retrospective analysis.

**Clinical Question** Is there a difference between the screw–rod construct (SRC) procedure without wiring and the SRC procedure with wiring with respect to fusion, implant failure, reoperation, donor-site morbidity, and complication rates?

**Patients and Methods** We performed a retrospective analysis of 26 patients who underwent C1–2 fixation between 2004 and 2012 (SRC with wiring and structural bone graft, 13 patients; SRC with autograft but without wiring, 13 patients). Fusion was assessed using dynamic X-rays in all patients and computed tomographic scans in selected cases. Pseudoarthrosis was confirmed during reoperation.

**Results** The mean follow-up time was 2 years and 5 months for the SRC without wiring group and 2 years and 1 month for the SRC with wiring group. Patients with less than 1-year follow-up time were excluded. The fusion rate, implant failure rate, and reoperation rates for the SRC without wiring group were 92, 8, and 8%, respectively. The fusion, implant failure, and reoperation rates for the SRC with wiring group were 100, 0, and 0%, respectively. There were no donor-site morbidities or complications in either group (both 0%). There were no differences in parameters we examined between the two groups ( $p > 0.05$  for each rate, Fisher exact test).

**Conclusions** The results suggest that supplementing the SRC procedure with wiring may increase fusion rate, but this difference is not statistically significant. Although the sample size was small, there was not a significant discrepancy in outcomes between the two groups at an average follow-up of 2 years.

## Keywords

- ▶ SRC
- ▶ posterior wiring
- ▶ Harms technique
- ▶ atlantoaxial instability
- ▶ C1
- ▶ C2
- ▶ fusion
- ▶ screw rod construct

## Study Rationale and Context

When treating atlantoaxial stability, the posterior C1 lateral mass screw and C2 pars or pedicle screw construct (screw–rod construct [SRC]) with onlay autograft have yielded high-fusion rates.<sup>1</sup> Some surgeons supplement the SRC procedure with posterior wiring using structural

bone graft (Brooks, Gallie, Sonntag), which increases operative time and expense.

## Clinical Question

Is there a difference between the SRC procedure without wiring and the SRC procedure with supplemental wiring with

received  
July 8, 2013  
accepted after revision  
February 10, 2014

© 2014 Georg Thieme Verlag KG  
Stuttgart · New York

DOI <http://dx.doi.org/10.1055/s-0034-1371972>.  
ISSN 1663-7976.

| Final class of evidence (CoE)—treatment           | Yes |
|---|-----|
| Study Design                                      |     |
| RCT   |     |
| Cohort  | X   |
| Case-control                                      |     |
| Case series                                       |     |
| Methods   |     |
| Concealed allocation (RCT)                        |     |
| Intention to treat (RCT)                          |     |
| Blinded/independent evaluation of primary outcome |     |
| F/U $\geq$ 85%                                    |     |
| Adequate sample size                              |     |
| Control for confounding                           |     |
| Overall class of evidence                         | III |

respect to fusion, implant failure, reoperation, donor-site morbidity, and complication rates?

## Patients and Methods

### Study Design

Retrospective analysis.

### Inclusion Criteria

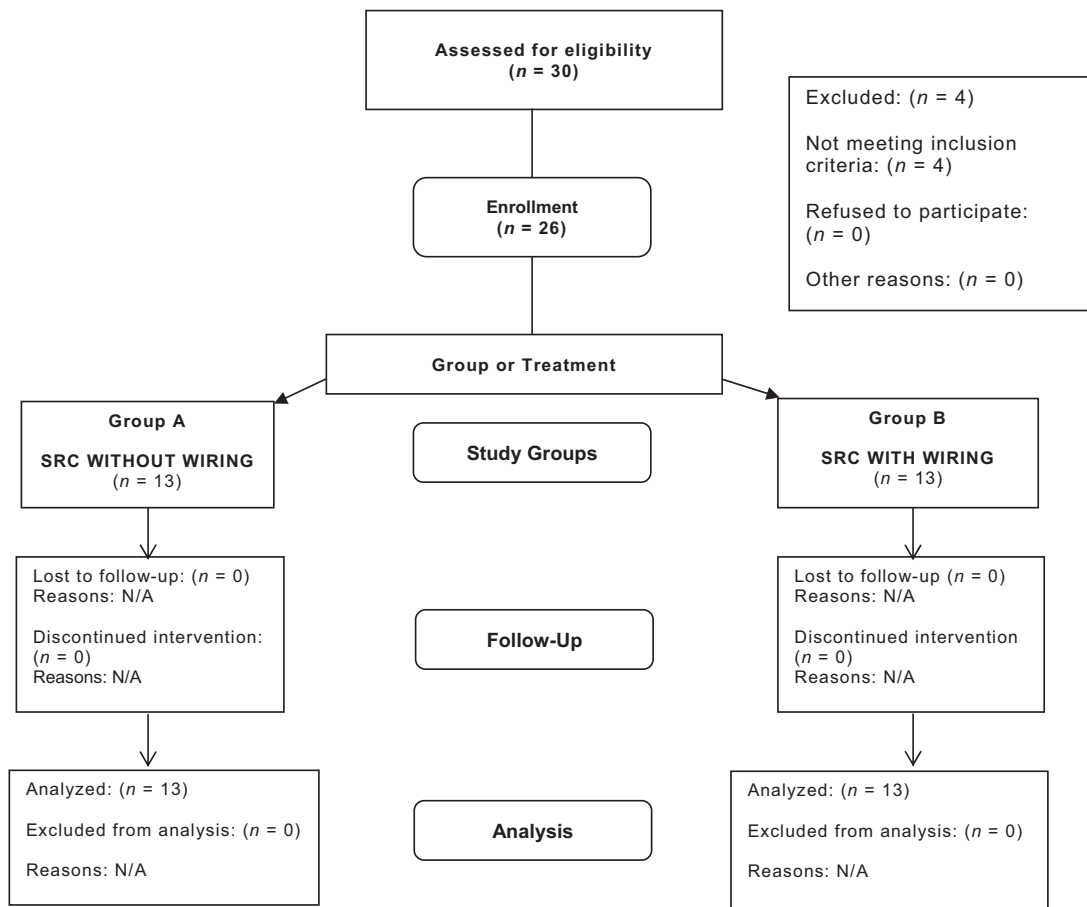
Patients who underwent the SRC procedure without or with wiring for C1–2 fixation and had a minimum of 1-year follow-up.

### Exclusion Criteria

Patients who underwent other procedures than the SRC procedure without or with wiring for C1–2 fixation or did not have a minimum of 1-year follow-up (►Fig. 1).

### Patient Population and Interventions Compared

- Thirteen patients underwent the SRC procedure without wiring (five females, eight males) (►Fig. 1, ►Table 1).



**Fig. 1** After eligibility assessment, 26 patients were enrolled in the SRC without wiring vs. SRC with wiring study: 13 in each group; 0 lost to follow-up. SRC, screw-rod construct.

**Table 1** Demographic and baseline characteristics of intervention groups

|  | Treatment A:<br>SRC without wiring, <i>n</i> = 13 | Treatment B:<br>SRC with wiring, <i>n</i> = 13 |
|--|---|--|
| Age (y, mean ± SD)                                 | (65 ± 22.2)                                       | (65 ± 18.7)                                    |
| Female ( <i>n</i> , %)                             | 5 (38)  | 6 (46)   |
| Male ( <i>n</i> , %)                               | 8 (62)  | 7 (54)   |
| Osteoporosis ( <i>n</i> , %)                       | 2 (15)  | 1 (8)  |
| Acute ( <i>n</i> , %)                              | 1 (8)   | 2 (15)   |
| Chronic ( <i>n</i> , %)                            | 12 (92)   | 11 (85)  |
| Pathology  |   |  |
| RA pannus ( <i>n</i> , %)                          | 4 (31)  | 3 (23)   |
| Fracture ( <i>n</i> , %)                           | 6 (46)  | 9 (69)   |
| C1–2 transverse ligamentous injury ( <i>n</i> , %) | 3 (23)  | 1 (8)  |
| Loss to follow-up ( <i>n</i> , %)                  | 0 (0)   | 0 (0)  |

Abbreviations: RA, rheumatoid arthritis; SD, standard deviation; SRC, screw-rod construct.

Note: *p* values for between group differences as determined by the Fisher exact test for categorical measures.

- Thirteen patients underwent the SRC procedure with wiring (six females, seven males) (►Fig. 1, ►Table 1).
- In the SRC procedure, a screw is inserted bilaterally into the C1 lateral masses and the C2 pars interarticularis or trans-laminar<sup>2</sup>; the C1 and C2 screws are then connected via a rod.<sup>3</sup>
- In Sonntag wiring technique, a wire is passed under the posterior C1 arch from inferior to superior<sup>4</sup>; a notched graft is then placed over the C2 spinous process and wedged underneath the posterior C1 arch<sup>4</sup>; the wire is looped over the graft, placed around the C2 spinous process, and seated in notches that were created on the inferior aspect of both sides of the spinous process.<sup>4</sup>
- Grafts used were iliac crest grafts (21 patients), fibular allograft (1 patient), laminectomy bone (3 patients), and combined C2 spinous process and C1 laminectomy bones (1 patient).
- To control for confounders, osteoporosis rate, acute/chronic condition rate, and pathology (RA pannus, fracture, and C1–2 transverse ligamentous injury) rates were investigated.

### Outcomes

- Fusion: Absence of motion on flex-ex films and the presence of bridging bone on computed tomographic or plain films.
- Implant failure: Implant pull-out, loosening, or separation.
- Reoperation: Having to undergo another operation because of pseudoarthrosis or implant failure.
- Donor-site morbidity: Complications at the site in which the bone graft was removed.
- Complication: Problems that arise as a result of the surgery such as vertebral artery, neurological injury, infection, etc.

### Analysis

- Fisher exact test.

Additional methodological and technical details are provided in the online supplementary material.

## Results

- Total patients analyzed, average age (age range) in years, mean follow-up time: SRC without wiring group = 13 patients, 65 (17–91), 2 years and 5 months, respectively; SRC with wiring group = 13 patients, 65 (30–92), 2 years and 1 month, respectively.
- Osteoporosis rate: SRC without wiring group = 15%; SRC with wiring group = 8%.
- Acute/chronic condition rate: SRC without wiring group = 8/92%; SRC with wiring group = 15/85%.
- Pathology (RA pannus, fracture, and C1–2 transverse ligamentous injury) rates: SRC without wiring group = 31, 46, 23%, respectively; SRC with wiring group = 23, 69, and 8%, respectively.
- Fusion, implant failure, reoperation rate: SRC without wiring group = 92, 8, and 8% respectively; SRC with wiring group = 100, 0, and 0%, respectively.
- No donor-site morbidities or complications in either group (0%).
- No differences in any of the parameters examined between the two groups even when controlling for confounders (*p* > 0.05, Fisher exact test) (►Table 2).

## Discussion

### Strengths

- One of the only comparisons between SRC without wiring and SRC with wiring.
- Minimum of 1-year follow-up time.
- Patients were operated at a major academic center.
- Even numbers of patients in both the groups.
- Statistical significance = *p* < 0.05: minimizes the likelihood that the results were due to chance.

**Table 2** Results

|                              | SRC without wiring group | SRC with wiring group | Fisher exact test |
|------------------------------|--------------------------|-----------------------|-------------------|
| Number of patients analyzed  | 13                       | 13                    | N/A               |
| Average follow-up time       | 2 y 5 mo                 | 2 y 1 mo              |                   |
| Fusion rate, %               | 92                       | 100                   | $p > 0.05$        |
| Implant failure rate, %      | 8                        | 0                     | $p > 0.05$        |
| Reoperation rate, %          | 8                        | 0                     | $p > 0.05$        |
| Donor-site morbidity rate, % | 0                        | 0                     | $p > 0.05$        |
| Complication rate, %         | 0                        | 0                     | $p > 0.05$        |

Abbreviations: N/A, not applicable; SRC, screw-rod construct.

Note: No one was lost to follow-up.

- Control for the following potential confounders: osteoporosis, acute/chronic condition, and pathology (RA pannus, fracture, and C1–2 transverse ligamentous injury).

### Limitations

- Retrospectively collected data
- Small sample size
- Not randomized
- Not blinded

### Clinical Relevance and Impact

- Supplemental wiring may not provide significant benefit to the patients with respect to the parameters examined.
- The screws and rods themselves may provide sufficient support.
- Because performing the posterior wiring technique increases operative time and expense, the addition of posterior wiring should ultimately be at the surgeon's discretion, taking into account bone quality, fusion potential, and overall confidence in the initial C1–2 construct obtained with only the SRC procedure.

### Summary and Conclusions: Key Points

- Osteoporosis, acute/chronic condition, and pathology (RA pannus, fracture, and C1–2 transverse ligamentous injury)

rates were not confounders nor associated with higher reoperation rates.

- There were no significant differences in the fusion, implant failure, reoperation, donor-site morbidity, and complication rates between the SRC without wiring and with wiring groups.

### Acknowledgement

This study was approved by the institutional Committee on Human Research (CHR) at the University of California San Francisco (UCSF).

### Conflict of Interest

- Mai Tran, Rishi Wadhwa, and John Ziewacz: None.
- Praveen Mummaneni: Depuy, Globus, 2N LLC.
- Dean Chou: Depuy, Globus, Stryker.

### References

- 1 Elliott RE, Tanweer O, Boah A, et al. Atlantoaxial Fusion with Screw-Rod Constructs: Meta-Analysis and Review of Literature. *World Neurosurg* 2012;8750(12):412–417
- 2 Harms J, Melcher RP. Posterior C1–C2 fusion with polyaxial screw and rod fixation. *Spine (Phila Pa 1976)* 2001;26(22):2467–2471
- 3 Sonntag VK. Atlantoaxial stabilization: a minimally invasive alternative. *World Neurosurg* 2013;80(3–4):315–316
- 4 Mummaneni PV, Haid RW. Atlantoaxial fixation: overview of all techniques. *Neurol India* 2005;53(4):408–415

## Editorial Perspective

The publication of this article was controversial among the reviewers. The main concerns were obviously centered around the relatively low sample-size, the recruitment methodology used (were all consecutive C1–2 fusion patients included?) and possible heterogeneity of the compared populations.

That said, after reiterative deliberations, *EBSJ* has decided in favor of publication as the authors pose an important question: In the age of potential unprecedented quality segmental fixation of a deficient atlantoaxial complex, is the addition of supplemental wiring and posterior onlay or interposition graft still needed, or can other techniques, such as a facet arthrodesis, provide adequate substitution?

While it is obviously desirable to have larger cohorts, especially for comparison studies, more specific or rare conditions with difficult patient recruitments may prompt us to make exceptions as was done here, in order to raise awareness in our surgeon community of other treatment options. That said, this article shows us at-best equivalency of segmental rod constructs alone with the previous posterior arch grafting, but it is clearly premature to use the presented data as a foundation to declare a new standard of care. We hope that the presented study will prompt investigations into more formal determinants of atlantoaxial fusion and efforts at larger scale patient safety and outcomes reporting of these patients.