

## UC Davis

### UC Davis Previously Published Works

**Title**

Granulomas associated with renal neoplasms: A multi-institutional clinicopathological study of 111 cases

**Permalink**

<https://escholarship.org/uc/item/1858q2mf>

**Journal**

Histopathology, 80(6)

**ISSN**

0309-0167

**Authors**

Sangoi, Ankur R  
Maclean, Fiona  
Mohanty, Sambit  
et al.

**Publication Date**








2022-05-01

**DOI**

10.1111/his.14633

Peer reviewed

## Granulomas associated with renal neoplasms: A multi-institutional clinicopathological study of 111 cases

Ankur R Sangoi,<sup>1</sup>  Fiona Maclean,<sup>2</sup> Sambit Mohanty,<sup>3</sup> Ondrej Hes,<sup>4</sup>  Reba Daniel,<sup>5</sup> Priti Lal,<sup>5</sup> Sofia Canete-Portillo,<sup>6</sup> Cristina Magi-Galluzzi,<sup>6</sup> Kristine M Cornejo,<sup>7</sup> Katrina Collins,<sup>8</sup> Michael Hwang,<sup>8</sup> Sara M Falzarano,<sup>9</sup> Mike M Feely,<sup>9</sup> Melad Dababneh,<sup>10</sup> Lara Harik,<sup>10</sup> Maria Tretiakova,<sup>11</sup>  Mahmut Akgul,<sup>12</sup> Varsha Manucha,<sup>13</sup> Emily Chan,<sup>14</sup>  Chia-Sui Kao,<sup>15</sup> Farshid Siadat,<sup>16</sup> Kanika Arora,<sup>17</sup> Guliz Barkan,<sup>18</sup> Liang Cheng,<sup>8</sup>  Michelle Hirsch,<sup>19</sup> Li Lei,<sup>20</sup> Matthew Wasco,<sup>21</sup> Sean R Williamson<sup>22</sup>  & Andres M Acosta<sup>19</sup> 

<sup>1</sup>El Camino Hospital, Pathology, Mountain View, CA, USA, <sup>2</sup>Department of Anatomic Pathology, Douglass Hanly Moir Pathology, Sonic Healthcare, Macquarie Park, Australia, <sup>3</sup>Department of Pathology and Laboratory Medicine, Advanced Medical Research Institute, Bhubaneswar, India, <sup>4</sup>Department of Pathology, Charles University Hospital and Medical Facility Plzen, Plzen, Czech Republic, <sup>5</sup>Department of Pathology, University of Pennsylvania, Philadelphia, PA, USA, <sup>6</sup>Department of Pathology, University of Alabama at Birmingham, Birmingham, AL, USA, <sup>7</sup>Department of Pathology, Massachusetts General Hospital and Harvard Medical School, Boston, MA, USA, <sup>8</sup>Indiana University, Pathology, Indianapolis, IN, USA, <sup>9</sup>Department of Pathology, Immunology and Laboratory Medicine, University of Florida, Gainesville, FL, USA, <sup>10</sup>Department of Pathology and Laboratory Medicine, Emory University, Atlanta, GA, USA, <sup>11</sup>University of Washington, Department of Laboratory Medicine and Pathology, Seattle, WA, USA, <sup>12</sup>Department of Pathology and Laboratory Medicine, Albany Medical Center, Albany, NY, USA, <sup>13</sup>Department of Pathology, University of Mississippi Medical Center, Jackson, MS, USA, <sup>14</sup>Department of Pathology, University of California San Francisco, San Francisco, CA, USA, <sup>15</sup>Stanford Medical Center, Stanford, CA, USA, <sup>16</sup>Department of Pathology and Laboratory Medicine, Cumming School of Medicine, University of Calgary, Calgary, AL, Canada, <sup>17</sup>Department of Pathology, Henry Ford Hospital, Detroit, MI, USA, <sup>18</sup>Loyola University Healthcare Center, Department of Pathology, Maywood, IL, USA, <sup>19</sup>Department of Pathology, Brigham and Women's Hospital, Harvard Medical School, Boston, MA, USA, <sup>20</sup>Department of Pathology and Laboratory Medicine, University of California Davis Health System, Sacramento, CA, USA, <sup>21</sup>St Joseph Mercy Hospital, Ann Arbor, MI, USA, and <sup>22</sup>Department of Pathology, Cleveland Clinic, Cleveland, OH, USA

Date of submission 13 January 2022

Accepted for publication 23 February 2022

Published online Article Accepted 29 March 2022

Sangoi A R, Maclean F, Mohanty S, Hes O, Daniel R, Lal P, Canete-Portillo S, Magi-Galluzzi C, Cornejo K M, Collins K, Hwang M, Falzarano S M, Feely M M, Dababneh M, Harik L, Tretiakova M, Akgul M, Manucha V, Chan E, Kao C-S, Siadat F, Arora K, Barkan G, Cheng L, Hirsch M, Lei L, Wasco M, Williamson S R & Acosta A M (2022) *Histopathology* 80, 922–927. <https://doi.org/10.1111/his.14633>

### Granulomas associated with renal neoplasms: A multi-institutional clinicopathological study of 111 cases

**Aims:** Formal depiction of granulomatous inflammation associated with renal neoplasms has mainly consisted of case reports. Herein, we investigate the clinicopathological features and potential significance of granulomas associated with renal tumours from a large multi-institutional cohort.

**Methods and results:** One hundred and eleven study cases were collected from 22 institutions, including 57 partial nephrectomies and 54 radical nephrectomies. Patient ages ranged from 27 to 85 years (average = 60.1 years; male = 61%). Renal neoplasms included clear cell renal cell carcinoma (RCC; 86%),

Address for correspondence: Ankur R. Sangoi, El Camino Hospital, Department of Pathology, 2500 Grant Road GC33, Mountain View, California 94040, USA. e-mail: asangoi2@yahoo.com

papillary RCC (8%), chromophobe RCC (3%), clear cell papillary RCC (1%), mixed epithelial stromal tumour (1%) and oncocytoma (1%). Granulomas were peritumoral in 36%, intratumoral in 24% and both in 40% of cases. Total granuloma count per case ranged from one to 300 (median = 15) with sizes ranging from 0.15 to 15 mm (mean = 1.9 mm). Necrotising granulomas were seen in 14% of cases. Histochemical stains for organisms were performed on 45% of cases (all negative). Sixteen cases (14%) had a prior biopsy/procedure performed, and eight patients had neoadjuvant immunotherapy or chemotherapy. Eleven patients

(10%) had a confirmed diagnosis of sarcoidosis, including five in whom sarcoidosis was diagnosed after nephrectomy.

*Conclusion:* Based on this largest case-series to date, peri-/intratumoral granulomas associated with renal neoplasms may be more common than initially perceived. The extent of granulomatous inflammation can vary widely and may or may not have necrosis with possible aetiologies, including prior procedure or immunotherapy/chemotherapy. Although a clinical association with sarcoidosis is infrequent it can still occur, and the presence of granulomas warrants mention in pathology reports.

Keywords: carcinoma, granulomas, intratumoral, kidney, neoplasm, peritumoral, renal, sarcoid, sarcoid-like

## Introduction

Granulomatous reactions to malignancies, probably as an immunological response to an antigenic trigger, can occur in a variety of cancers, but have been well-described in lymphomas.<sup>1</sup> In some tumours (e.g. seminoma), admixed granulomas are also histologically characteristic. Other tumours, such as urothelial carcinoma, often demonstrate a granulomatous reaction after bacillus Calmette–Guerin (BCG) therapy. Sarcoidosis is a multisystem granulomatous disorder, usually characterized by non-necrotising granulomas, and is typically a diagnosis of exclusion. Pulmonary involvement by sarcoidosis is the prototypical organ site (95%), with infrequent incidence of renal involvement (<1%).<sup>2</sup> Thus far, formal depiction of granulomatous inflammation in association with renal neoplasms has mainly consisted of case reports and small series (cumulative case count of 28<sup>3–15</sup>), with limited follow-up and narrow description of other putative aetiologies beyond sarcoidosis (e.g. prior biopsy or immunotherapy). Herein, we investigate detailed clinicopathological features and the potential significance of granulomas associated with renal tumours from a large multi-institutional cohort.

## Methods and Materials

A database search was performed from 22 different institutions for cases of renal neoplasms containing granulomas from nephrectomy specimens. The distribution of granulomas was classified as peritumoral if they were located within 2 mm of the tumour border

or intratumoral if they were embedded within the neoplastic parenchyma. Biopsy cases of renal masses containing granulomas were excluded. Clinical information relevant for the study was obtained from review of electronic medical records and pathology reports. Moreover, all available slides were re-reviewed for documentation of histopathological features, including glass slide quantification of total granuloma count per entire case, size of the largest granuloma and the presence/absence of associated necrosis. The information obtained from review of pathology reports and medical records included: surgical procedure (partial versus radical nephrectomy), patient age, tumour laterality, tumour stage, diagnosis, World Health Organization/International Society of Urological Pathology (WHO/ISUP) nuclear grade, utility of histochemical stains for organisms, prior procedure (e.g. prior renal biopsy or stent), prior pharmacotherapy (e.g. immunomodulators, checkpoint inhibitors, chemotherapy) or the presence of nephroliths at the time of nephrectomy. Importantly, cases with a known prior history of autoimmune conditions (namely sarcoidosis) were noted, as well as clinical follow-up performed for potential subsequent development of sarcoidosis. Data are available on request from the authors.

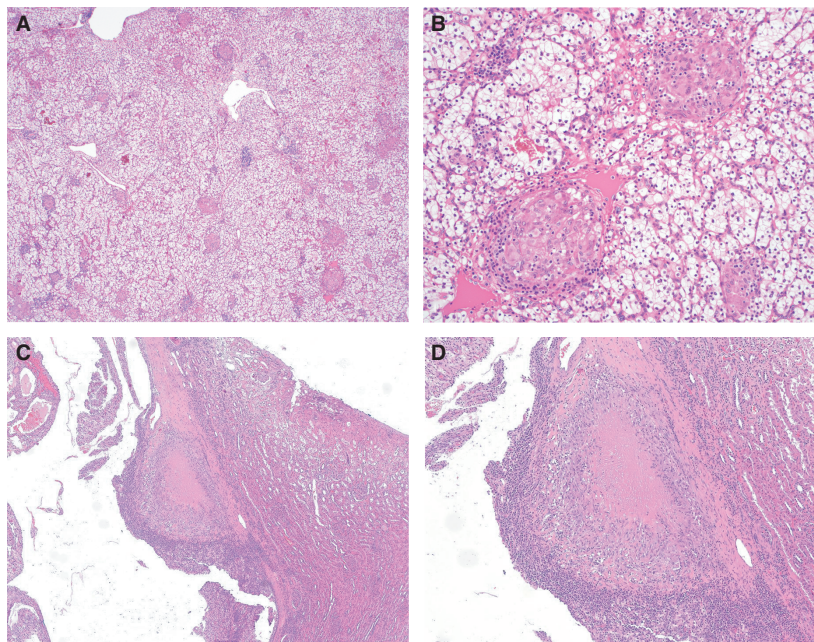
## Results

A total of 111 study cases were obtained from 22 different institutions, including 57 partial nephrectomies and 54 radical nephrectomies, with slight left-sided predominance (55%). Four nephrectomies for

urothelial carcinoma that contained tumoral granulomas were excluded from the study due to a history of prior BCG therapy. Patient ages ranged from 27 to 85 years (average = 60.1 years; male = 61%). Renal neoplasms included several histological subtypes of RCC: clear cell renal cell carcinoma (RCC; 86%), papillary RCC (8%), chromophobe RCC (3%) and clear cell papillary RCC (1%). Other renal neoplasms included mixed epithelial stromal tumour (1%) and oncocytoma (1%). WHO/ISUP RCC nuclear grades (chromophobe RCC excluded) were as follows: grades 2 (50%), 3 (36%), 1 (9%) and 4 (5%). Most RCC cases were pathological stage pT1a (49%) followed by pT3a (23%), pT1b (21%) and pT2 (7%). The distribution of granulomas was peritumoral in 36% of cases, intratumoral in 24% of cases and both peri- and intratumoral in 40% cases (Figure 1). Total granuloma count per case varied widely, ranging from one to 300 (median = 15) with size of the largest granuloma ranging from 0.15 to 15 mm (mean = 1.9 mm). Necrotising granulomas were seen in 14% of cases. There was no association noted between size or number of granulomas and presence of necrosis (median = 16 granulomas in cases with necrosis versus median = 15 in those without; mean granuloma size 3.2 mm in cases with necrosis versus mean

granuloma size 1.8 mm in cases without). Similarly, there was no association between renal tumour type and presence of necrotising granulomas (tumour types in cases with granulomas included 11 clear cell RCC, three papillary RCC and one clear cell papillary RCC). Among the 11 cases with a diagnosis of sarcoidosis, the median granuloma count was 43, with size of the largest granuloma ranging from 0.4 to 5 mm (mean = 2.4 mm); only two of these 11 cases had granulomas with necrosis. Histochemical stains [acid-fast bacteria (AFB) and Grocott's methenamine silver (GMS)] were performed on 45% of overall cases (all negative for micro-organisms), and were performed on 67% (10 of 15) cases with necrotising granulomas. In two cases with necrotising granulomas, polymerase chain reaction (PCR) testing for mycobacteria was performed (negative in both cases). None of the cases contained admixed refractile material within or adjacent to the granulomas.

Sixteen cases (14%) had pre-operative procedures performed, including 11 cases with core biopsy, two cases with embolisation, two cases with stent placement and one case with nephrolithotomy. Only two cases (2%) had a nephrolith present at time of nephrectomy. Eight patients had a history of pre-operative neoadjuvant immunotherapy or



**Figure 1.** A,B, Intratumoral granulomas. Numerous granulomas are present within the tumour parenchyma of this clear cell renal cell carcinoma (RCC) [A, haematoxylin and eosin (H&E)]. In this case, the granulomas are non-caseating (B, H&E). C,D, Peritumoral granulomas. Granulomas with necrosis are present at the border between this clear cell papillary RCC and the adjacent renal parenchyma (C,D, H&E). AFB and GMS histochemical stains were performed on this case (negative for micro-organisms). Neither of these study cases had a prior history of sarcoidosis, prior procedure or prior immunotherapy/chemotherapy.

chemotherapy, including three targeted for renal cell carcinoma, one for melanoma, one for lymphoma, one for renal transplant, one for mixed connective tissue disease and one for rheumatoid arthritis. A total of 11 patients (10%) had a confirmed diagnosis of sarcoidosis, consisting of six patients with a known pre-operative diagnosis and five patients in whom sarcoidosis was diagnosed only after nephrectomy. One patient had a known pre-operative diagnosis of mixed connective tissue disease and another of rheumatoid arthritis. None of the patients had a known history of vasculitis, pyelonephritis or tuberculosis. Clinical follow-up was available in 94% of cases, with the time interval from nephrectomy to latest clinical inquiry of putative diagnosis of sarcoidosis ranging from one to 212 months (mean = 34 months). One patient presented with concurrent lung nodules at the time of nephrectomy (thought to represent pulmonary metastasis from RCC), with histological documentation of nephrectomy granulomas leading to timely clinical diagnosis of sarcoidosis.

## Discussion

The initial depiction of a renal neoplasm with admixed granulomas was from a 1993 case report of a RCC with intratumoral granulomas, without a confirmed diagnosis of sarcoidosis.<sup>6</sup> A review of previously published studies (mainly individual case reports or small series) of granulomas in renal neoplasms also highlights this association (Table 1), with some allusion to a sarcoidosis link but with limited discussion of other putative aetiologies. Based on our study, to our knowledge the largest case-series to date, several important points emerge.

First, granulomas associated with renal neoplasms are more often peri- than intratumoral alone (36 versus 24%) but usually show both patterns (40%), and may be more common than initially perceived. While the multi-institutional collaborative nature of our study allowed for a large capture of study cases, most individual contributors notably submitted several cases each. Moreover, during study design several contributors noted that they had encountered additional cases of granulomas in neoplastic RCC nephrectomies, but because of limited pathology report documentation these were difficult to retrieve by electronic database review. Therefore, because granulomas are an incidental finding in the context of surgery performed for a renal neoplasm, they are probably under-reported in most institutions.

Secondly, while the majority of study cases involved malignant tumours (98%), our study and two others<sup>10, 15</sup> demonstrate that benign renal neoplasms can also be associated with granulomas. While the exact aetiology of this granulomatous response remains unclear, one study proposed that the high content of glycogen present in clear cell RCC (similar to that seen in seminoma) might be an eliciting factor.<sup>3</sup> As 86% (95 of 111) of our study cases were clear RCC and 86% (24 of 28) of other cumulative cases were also clear cell RCC, a response to glycogenated tumour cells may indeed be at least responsible, in part, for the formation of the associated granulomas. Biochemically, the release of angiotensin I-converting enzyme from multinucleated giant cells in sarcoidosis<sup>16</sup> may also play a role in tumoral granulomatous response, although infection, vasculitis and drug reactions may also be considered among potential aetiologies.

While we observed more granulomas in study cases with a diagnosis of sarcoidosis than those without (median granuloma count = 43 versus 15), the total granuloma count per case varied widely (range = 1–300). As such, careful scrutiny may be needed to identify peri- or intratumoral granulomas, which are often small in size (mean = 1.9 mm). Care should also be taken to avoid misclassifying a multinucleated tumour cell, megakaryocyte or Langerhans cell (uncommon but reported in RCC<sup>17–19</sup>) as a multinucleated giant cell. In keeping with the histology of typical sarcoidosis, necrotising granulomas were only present in 18% (two of 11) of study cases with a known diagnosis of sarcoidosis (overall rate of necrotising granulomas was 14%). Histochemical stains (AFB and GMS) were performed more often on study cases with necrotising granulomas (67 versus 45% of overall cases), as might be expected for those found at any other organ site. Despite all cases being negative for micro-organisms in our study, given that sarcoidosis is a diagnosis of exclusion, the use of histochemical stains may be prudent in routine practice when encountering peri- or intratumoral renal granulomas, especially if the granulomas are of a necrotising nature.

Drug-induced sarcoid-like reactions have been well-recognized as a tissue reaction to systemic therapy,<sup>20</sup> with tumour-associated local T cell-mediated granulomatous reactions receiving more recognition with the utility of novel immunotherapeutic agents.<sup>21</sup> In our series, eight patients (7%) had a history of pre-operative neoadjuvant immunotherapy or chemotherapy. Of the 16 study cases (14%) with pre-operative procedures performed (well known to elicit a tissue

**Table 1.** Previously published studies of granulomas associated with renal neoplasms

Study	No. of cases	Renal tumour(s)	Renal tumour subtype(s)	Distribution of granulomas	Sarcoidosis*
Campbell <i>et al.</i>	1	RCC	Clear cell RCC	Intratumoral	None
Bottone <i>et al.</i>	1	RCC	Clear cell RCC	Peritumoral	1/1 (100%)
Marinides <i>et al.</i>	1	RCC	Papillary RCC	Peritumoral	None
Hes <i>et al.</i>	3	RCC	Clear cell RCC	Intratumoral	None
Kovacs <i>et al.</i>	1	RCC	Clear cell RCC	Intratumoral/peritumoral	None
Piscioli <i>et al.</i>	1	RCC	Clear cell RCC	Peritumoral	None
Narasimhaiah <i>et al.</i>	3	RCC	Clear cell RCC	Intratumoral	None
Ouellet <i>et al.</i>	1	RCC	Clear cell RCC	Peritumoral	None
Burhan <i>et al.</i>	1	RCC	Clear cell RCC	Intratumoral	None
Khatua <i>et al.</i>	1	RCC	Clear cell RCC	Peritumoral	None
Arora <i>et al.</i>	11	RCC	Clear cell RCC ( $n = 10$ ), Clear cell papillary RCC ( $n = 1$ )	Intratumoral/peritumoral	1/11 (11%)
Majeed <i>et al.</i>	2	RCC	Clear cell RCC ( $n = 1$ ), MCNLMP MCNLMP ( $n = 1$ )	Intratumoral/peritumoral	2/2 (100%)
Tarjan <i>et al.</i>	1	AML	AML	Unknown <sup>†</sup>	None
Current study	111	RCC, MEST, oncocytoma	Clear cell RCC ( $n = 95$ ), papillary RCC ( $n = 9$ ), Chromophobe RCC ( $n = 3$ ), clear cell papillary RCC ( $n = 2$ ), MEST ( $n = 1$ ), oncocytoma ( $n = 1$ )	Intratumoral/peritumoral	11/111 (10%) <sup>‡</sup>

AML, angiomyolipoma; MCNLMP, multilocular cystic neoplasm of low malignant potential; MEST, mixed epithelial stromal tumour; RCC, renal cell carcinoma.

\*Cases with either known history of or subsequent diagnosis of sarcoidosis;

<sup>†</sup>Diagnosed on a core needle biopsy;

<sup>‡</sup>Five cases were diagnosed with sarcoidosis only after nephrectomy identified granulomas.

response regardless of organ site), none (0%) were from patients with a diagnosis of sarcoidosis. As such, when encountering a renal neoplasm with associated granulomas, chart review for possible prior pharmacotherapy or prior renal procedure may offer a useful clinicopathological correlation. With nephroliths at the time of nephrectomy identified in only 2% of study cases, nephrolithiasis seems an unlikely contributing factor.

While only six patients had a known pre-operative diagnosis of sarcoidosis, five cases were subsequently diagnosed with sarcoidosis after tumoral granulomatous inflammation was identified on histological review of the nephrectomy specimen. In these five cases, more thorough clinical and radiographic exploration for extrarenal granulomas ultimately

confirmed a diagnosis of sarcoidosis. Our study tally of 10% (11 of 111 patients) is in keeping with the overall reported incidence 14% (four of 28 patients) of sarcoidosis from previously published studies of granulomas associated with renal neoplasms (Table 1). Therefore, in order to alert clinicians that additional work-up is advised for a putative diagnosis of sarcoidosis, formal documentation of tumoral granulomas in the pathology report is crucial. This is particularly relevant in light of the finding that, in a small subset of patients, granulomas found in the nephrectomy specimen might be the first indication of sarcoidosis.

Although not the focus of our study, it is worth noting that the presence of tumoral sarcoid-like granulomas (designated an immune-mediated antitumour

response of macrophages by activated T cell lymphocytes<sup>22</sup>) in cancer patients has been associated with reduced metastasis and increased survival;<sup>23</sup> however, there are limited data involving RCC patients. Pertaining to cancer risk and sarcoidosis, it is interesting to note that from one study, the relative risk for development of RCC by a diagnosis of sarcoidosis is small but statistically significant (relative risk of 1.55<sup>24</sup>), making early recognition of potential sarcoidosis relevant for possible early screening. Also, it is reasonable to speculate that, in the absence of sarcoidosis, RCCs with a granulomatous reaction might have shared molecular features. Further genomic and epigenomic studies including RCC with granulomas not associated with sarcoidosis are required to explore this hypothesis.

Based on this largest case series to date, peri- and intratumoral granulomas associated with renal neoplasms may be more common than initially perceived, and can be seen in both benign and malignant tumours. The extent of granulomatous inflammation can vary widely and may or may not have necrosis, with possible aetiology from a prior procedure or immunotherapy/chemotherapy. Although a clinical association with sarcoidosis is infrequent, it can occur and warrants reporting of the granulomas to ensure patients receive diagnostic evaluation of suspected sarcoidosis.

## Conflicts of Interest

All authors have no financial or other conflicts of interest.

## Data availability statement

The data that support the findings of this study are available from the corresponding author upon reasonable request.

## References

1. Brincker H. Sarcoid reactions in malignant tumours. *Cancer Treat. Rev.* 1986; **13**: 147–156.
2. Baughman RP, Teirstein AS, Judson MA *et al.* Clinical characteristics of patients in a case control study of sarcoidosis. *Am. J. Respir. Crit. Care Med.* 2001; **164**: 1885–1889.
3. Arora K, Divatia MK, Truong L, Shen SS, Ayala AG, Ro JY. Sarcoid-like granulomas in renal cell carcinoma: The Houston Methodist hospital experience. *Ann. Diagn. Pathol.* 2017; **31**: 62–65.
4. Bottone AC, Labarbera M, Asadourian A, Barman A, Richie C. Renal sarcoidosis coexisting with hypernephroma. *Urology.* 1993; **41**: 157–159.
5. Burhan W, Al Rowaie Z, Rajih E, Akhtar M. Sarcoid-like granulomatous reaction in renal cell carcinoma: Report of a case with review of the published reports. *Ann. Saudi Med.* 2013; **33**: 614–618.
6. Campbell F, Douglas-Jones AG. Sarcoid-like granulomas in primary renal cell carcinoma. *Sarcoidosis.* 1993; **10**: 128–131.
7. Hes O, Hora M, Vanecek T *et al.* Conventional renal cell carcinoma with granulomatous reaction: a report of three cases. *Virchows Arch.* 2003; **443**: 220–221.
8. Khatua S, Bose K, Bandyopadhyay A, Banerjee A. A rare association of sarcoid-like granuloma with renal cell carcinoma. *J. Cancer Res. Ther.* 2015; **11**: 1033.
9. Kovacs J, Varga A, Bessenyei M, Gomba S. Renal cell cancer associated with sarcoid-like reaction. *Pathol. Oncol. Res.* 2004; **10**: 169–171.
10. Majeed NK, Acosta AM, Kajdacsy-Balla A, Setty S, Aardsma NA. Granulomas within renal epithelial neoplasms in patients with sarcoidosis: a causal association? *Pathol. Res. Pract.* 2017; **213**: 1431–1434.
11. Marinides GN, Hajdu I, Gans RO. A unique association of renal carcinoma with sarcoid reaction in the kidney. *Nephron.* 1994; **67**: 477–480.
12. Narasimhaiah DA, Manipadam MT, Aswathaman K, Krishnamoorthy S. Renal cell carcinoma associated with granulomatous reaction. *Saudi J. Kidney Dis. Transpl.* 2011; **22**: 1211–1214.
13. Ouellet S, Albadine R, Sabbagh R. Renal cell carcinoma associated with peritumoral sarcoid-like reaction without intratumoral granuloma. *Diagn. Pathol.* 2012; **7**: 28.
14. Pisciole I, Donato S, Morelli L, Del Nonno F, Licci S. Renal cell carcinoma with sarcomatoid features and peritumoral sarcoid-like granulomatous reaction: report of a case and review of the literature. *Int. J. Surg. Pathol.* 2008; **16**: 345–348.
15. Tarjan G, Kim GJ, Al H, Rasheed MR. Renal angiomyolipoma with sarcoid granulomas: report of a unique case. *Int. J. Surg. Pathol.* 2016; **24**: 253–256.
16. Kurata A, Terado Y, Schulz A, Fujioka Y, Franke FE. Inflammatory cells in the formation of tumor-related sarcoid reactions. *Hum. Pathol.* 2005; **36**: 546–554.
17. Agaimy A, Bonert M, Naqvi A *et al.* Langerhans cell histiocytosis associated with renal cell carcinoma is a neoplastic process: clinicopathologic and molecular study of 7 cases. *Am. J. Surg. Pathol.* 2020; **44**: 1658–1665.
18. Williamson SR, Kum JB, Goheen MP, Cheng L, Grignon DJ, Idrees MT. Clear cell renal cell carcinoma with a syncytial-type multinucleated giant tumor cell component: implications for differential diagnosis. *Hum. Pathol.* 2014; **45**: 735–744.
19. Williamson SR, Mast KJ, Cheng L, Idrees MT. Clear cell renal cell carcinoma with intratumoral and nodal extramedullary megakaryopoiesis: a potential diagnostic pitfall. *Hum. Pathol.* 2014; **45**: 1306–12309.
20. Chopra A, Nautiyal A, Kalkanis A, Judson MA. Drug-induced sarcoidosis-like reactions. *Chest.* 2018; **154**: 664–677.
21. Paydas S. Sarcoid-like reaction in cases treated by checkpoint inhibitors. *Med. Oncol.* 2021; **38**: 29.
22. Meyer EM, Grundmann E. Lymph node reactions to cancer. *Klin. Wochenschr.* 1982; **60**: 1329–1338.
23. Murthi M, Yoshioka K, Cho JH *et al.* Presence of concurrent sarcoid-like granulomas indicates better survival in cancer patients: a retrospective cohort study. *ERJ Open Res.* 2020; **6**: 00061-2020. <https://doi.org/10.1183/23120541.00061-2020>.
24. Bonifazi M, Bravi F, Gasparini S *et al.* Sarcoidosis and cancer risk: systematic review and meta-analysis of observational studies. *Chest.* 2015; **147**: 778–791.