

UC Davis

Dermatology Online Journal

Title

A patient with acute-type adult T-cell leukemia/lymphoma that rapidly progressed after Helicobacter pylori eradication therapy

Permalink

<https://escholarship.org/uc/item/1906k01h>

Journal

Dermatology Online Journal, 30(2)

Authors

Matsudate, Yoshihiro
Saeki, Kyosuke

Publication Date

2024

DOI

10.5070/D330263595

Copyright Information

Copyright 2024 by the author(s). This work is made available under the terms of a Creative Commons Attribution-NonCommercial-NoDerivatives License, available at

<https://creativecommons.org/licenses/by-nc-nd/4.0/>

Peer reviewed

A patient with acute-type adult T-cell leukemia/lymphoma that rapidly progressed after *Helicobacter pylori* eradication therapy

Yoshihiro Matsudate¹ MD PhD, Kyosuke Saeki² MD

Affiliations: ¹Division of Dermatology, Ehime Prefectural Central Hospital, Matsuyama, Japan, ²Division of Hematology, Ehime Prefectural Central Hospital, Matsuyama, Japan

Corresponding Author: Yoshihiro Matsudate MD PhD, Division of Dermatology, Ehime Prefectural Central Hospital, 83 Kasuga-cho, Matsuyama City, Ehime 790-0024, Japan., Tel: 81-899-47-1111, Fax: 81-899-43-4136, Email: yoshihiro_matsudate@yahoo.co.jp

Keywords: cutaneous, *Helicobacter pylori*, drug hypersensitivity, HTLV1 infections, T-cell lymphoma

To the Editor:

Adult T-cell leukemia/lymphoma (ATLL) causes polymorphous skin lesions and several cases of ATLL involving clinically suspected drug eruptions have been reported [1]. However, no cases in which drug treatment triggered the rapid progression of ATLL have ever been reported to our knowledge. Herein, we describe a case of ATLL that rapidly progressed after *Helicobacter pylori* (HP) eradication therapy.

A 76-year-old man was diagnosed with HP infection and received HP eradication therapy (amoxicillin/clarithromycin/vonoprazan: VONOSAP®). Ten days after the therapy was started (3 days after it was completed), he presented with a generalized erythematous eruption. Fifteen mg/day oral prednisolone for three days was ineffective. The eruptions gradually progressed and systemic symptoms, including fever, fatigue, and nausea, also developed. There was no medical or family history of leukemia/lymphoma.

A physical examination revealed diffuse infiltrating erythema and plaques over the entire body (**Figure 1**). A histopathological examination of an erythematous plaque on his right upper arm revealed a dense dermal infiltrate of atypical lymphocytes with epidermotropism (**Figure 2A**). Immunohistochemically, the infiltrating atypical cells were positive for CD4 and CD25 (**Figure 2B, C**). Laboratory tests produced the following: white blood cell count 15760/ μ l (flower-shaped abnormal

lymphocytes, 13.5%), aspartate aminotransferase, 148U/l (normal, 13-30U/l), alanine aminotransferase 230U/l (normal, 10-42U/l), lactate dehydrogenase 418U/l (normal, 124-222U/l), γ -glutamyl transpeptidase 171U/l (normal, 13-64U/l), albumin 3.4g/dl (normal, 4.1-5.1g/dl), blood urea nitrogen 27.7mg/dl (normal, 8.0-20.0mg/dl), blood creatinine 1.07mg/dl (normal, 0.65-1.07mg/dl), serum calcium 13.2mg/dl (normal, 8.8-10.1mg/dl), soluble interleukin-2 receptor 54641U/ml (normal, 121-613U/ml). Anti-human T-cell lymphotropic virus type 1 (HTLV1) antibody testing was positive. The

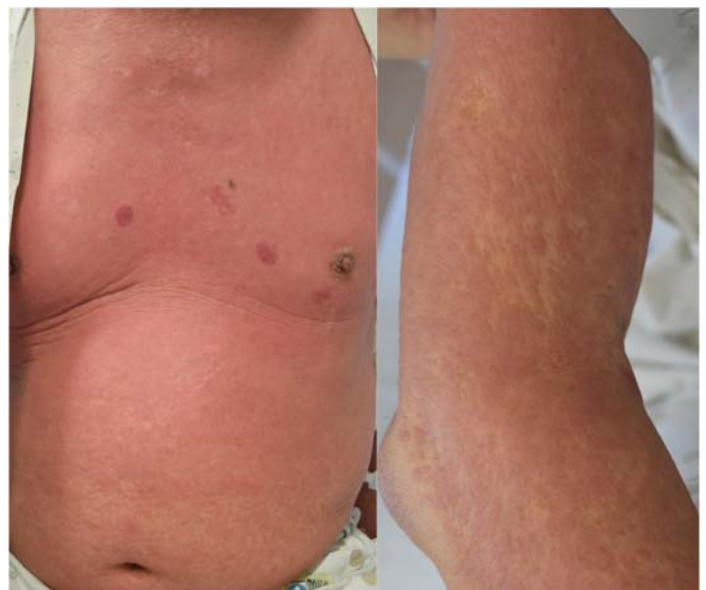

Figure 1. Diffuse infiltrating erythema and plaques were observed over the patient's entire body.

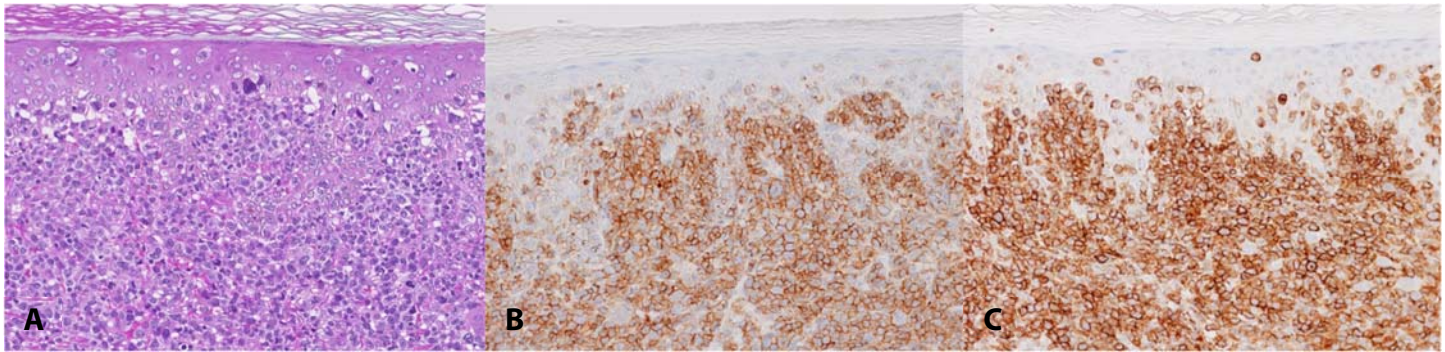


Figure 2. A) Histopathological examination revealed a dense dermal infiltrate of atypical lymphocytes with epidermotropism. H&E, 200x. Immunohistochemically, the infiltrating atypical cells were positive for B) CD4, and C) CD25. 200x.

monoclonal integration of HTLV1 proviral DNA in the peripheral blood was confirmed by Southern blot analysis. Thus, a diagnosis of acute-type ATLL was made. After treatment for hypercalcemia, CHOP chemotherapy (cyclophosphamide, doxorubicin, vincristine, and prednisolone) was initiated, but was ineffective. The patient died of multi-organ failure 9 days after admission.

Helicobacter pylori is causally related to gastritis/gastric cancer and HP eradication reduces the incidence of gastric cancer [2]. *Helicobacter pylori* eradication therapy usually consists of a proton-pump inhibitor with amoxicillin and clarithromycin for 7 days. The skin eruptions associated with HP eradication therapy include both drug eruptions and allergic reactions to HP [3]. Allergic reactions to HP tend to occur after the completion of HP eradication therapy [3]. The degradation products of HP eradication therapy are absorbed by the small intestine and some of them are taken up into

extracellular vesicles [3]. Ito et al. showed that antigen-specific reactions occurred through HP components in the serum extracellular vesicles of patients that experienced skin reactions after the completion of HP eradication therapy [3]. In these cases, cytokine (IL2, IL4, IL6, IFN γ , and TNF) upregulation was detected in vitro [3].

In ATLL, inflammation mediated by IFN γ promotes lymphomagenesis [4]. Although the incidental onset of ATLL cannot be excluded, we suspected that IFN γ -mediated inflammation caused by an allergic reaction to HP may be involved in the rapid progression of ATLL in the present case. Further reports of similar cases are needed to clarify the association between HP eradication therapy and the rapid progression of ATLL.

Potential conflicts of interest

The authors declare no conflicts of interest.

References

1. AbdullGaffar B, Abdulrahman S. Adult T-cell leukemia/lymphoma clinically confused with viral/drug skin eruptions and pathologically misinterpreted as mycosis fungoides/Sézary syndrome. *J Cutan Pathol*. 2021;48:1103-1108. [PMID: 33354782].
2. Franceschi F, Zuccala G, Roccarina D, Gasbarrini A. Clinical effects of *Helicobacter pylori* outside the stomach. *Nat Rev Gastroenterol Hepatol*. 2014;11:234-242. [PMID: 24345888].
3. Ito T, Shiromizu T, Ohnishi S, et al. Potential role of extracellular vesicle-mediated antigen presentation in *Helicobacter pylori* hypersensitivity during eradication therapy. *J Allergy Clin Immunol*. 2018;142:672-676. [PMID: 29653117].
4. Mitagami Y, Yasunaga J, Kinoshita H, Ohshima K, Matsuoka M. Interferon- γ promotes inflammation and development of T-cell lymphoma in HTLV-1 bZIP factor transgenic mice. *PLoS Pathog*. 2015;11:e1005120. [PMID: 26296091].