

UC San Diego

UC San Diego Previously Published Works

Title

Transcarotid artery stenting for carotid artery pseudoaneurysm using flow reversal technique

Permalink

<https://escholarship.org/uc/item/19b1b7vw>

Journal

Journal of Vascular Surgery Cases and Innovative Techniques, 4(2)

ISSN

2468-4287

Authors

Rizwan, Muhammad
Smith, Carlton
Faro, Scott
et al.

Publication Date

2018-06-01

DOI

10.1016/j.jvscit.2018.01.005

Peer reviewed

Transcarotid artery stenting for carotid artery pseudoaneurysm using flow reversal technique

Muhammad Rizwan, MD, Carlton Smith, MD, Scott Faro, MD, and Mahmoud B. Malas, MD, MHS, FACS, Baltimore, Md

ABSTRACT

Carotid artery pseudoaneurysm results mostly from direct trauma, prior endarterectomy, prior dissection, radiation, and infections. There are many different surgical and endovascular treatment options for repair, and the choice of treatment depends on patient-, surgeon-, and institute-related factors. Studies have reported the efficacy of various endovascular techniques for aneurysm repair, including stent graft placement and coil embolization, with promising short- and long-term outcomes. In this report, we describe two cases of carotid artery pseudoaneurysm (after trauma and after carotid endarterectomy) treated successfully through transcarotid artery stenting using the flow reversal technique to minimize the risk of embolization and stroke. (*J Vasc Surg Cases and Innovative Techniques* 2018;4:115-8.)

Carotid artery pseudoaneurysm (CAP), an uncommon condition, is due to localized disruption of the arterial wall, resulting mostly from direct trauma, prior endarterectomy, prior dissection, radiation, and infection-related vasculopathy (human immunodeficiency virus infection and tuberculosis).¹⁻³ Overall, extracranial carotid artery aneurysms account for <1% of all arterial aneurysms. In carotid arteries, the proportion of true aneurysm to pseudoaneurysm varies widely in the literature, with pseudoaneurysms being the most common (36%-82%) and traumatic aneurysms next most common (12%-13%) of all the carotid artery aneurysms.^{1,4,5} The incidence of CAP after carotid endarterectomy (CEA) is <1% of all CEAs performed.⁶ Depending on the size and etiology, the common presentation of CAP includes pulsatile neck mass followed by neurologic symptoms, mass effects, or bleeding due to rupture. In case of traumatic CAP, the internal carotid artery (ICA) is most commonly involved. There are many different surgical and endovascular treatment options for repair, and the choice of treatment depends on patient factors (anatomy, comorbidities) and surgeon- and institute-related factors (eg, experience, imaging, and devices). Studies have reported the safety and efficacy of various newer endovascular techniques for aneurysm repair, including stent

graft placement and coil embolization, with promising short- and long-term outcomes.⁷⁻⁹ In this report, we describe two cases of CAP, after trauma and after CEA, that were treated successfully through transcarotid artery stenting (TCAR) using the flow reversal technique to minimize the risk of embolization and stroke. Both patients consented for the information in this report and its publication.

CASE REPORTS

Case 1. A 26-year-old man presented to the emergency department with complete paralysis of his left upper and lower extremities. Magnetic resonance imaging showed ischemic stroke of the right middle cerebral artery and right anterior cerebral artery territory. The patient had a history of being involved in a road traffic accident 10 months before this visit, when he had multiple upper and lower extremity bone fractures that were treated without known complications. Six months later, the patient presented to another hospital with weakness in the left upper and lower extremities, which was completely resolved; head computed tomography performed at that time did not show any signs of stroke, and the patient was discharged home.

On this admission, carotid duplex ultrasound (DUS) showed a pseudoaneurysm of the distal right ICA measuring 2 cm in diameter with significant intramural thrombus. Three-dimensional computed tomography showed the aneurysm measuring 3.8 × 1.8 cm (*Fig 1*).

Case 2. A 60-year-old man presented with left hemispheric stroke and was found to have bilateral cerebral artery aneurysms. The patient was referred to neurosurgery for embolization of his aneurysms. Carotid DUS showed 90% right carotid artery stenosis, and CEA was performed by the neurosurgery service with a plan for aneurysm repair. Carotid DUS at 2 weeks of follow-up showed a right 5-cm CAP at the distal part of the patch with intramural thrombus. The pseudoaneurysm was approximately 1.3 cm distal to the origin of the right ICA and was a significant dilation of the posterior wall of the vessel. It measured 17 mm in greatest dimension with a 9.5-mm neck. A DUS image of the aneurysm is shown in *Fig 2*.

From the Johns Hopkins Bayview Vascular and Endovascular Clinical Research Center.

Author conflict of interest: none.

Correspondence: Mahmoud B. Malas, MD, MHS, FACS, Professor of Surgery, Johns Hopkins University, Director of the Center of Research Excellence and Surgical trial, Johns Hopkins Medical Institutes, Director of Endovascular Surgery, Johns Hopkins Bayview Medical Center, 4940 Eastern Ave, Bldg A/5, Ste 547, Baltimore, MD 21401 (e-mail: bmalas1@jhmi.edu).

The editors and reviewers of this article have no relevant financial relationships to disclose per the Journal policy that requires reviewers to decline review of any manuscript for which they may have a conflict of interest.

2468-4287

© 2018 The Authors. Published by Elsevier Inc. on behalf of Society for Vascular Surgery. This is an open access article under the CC BY-NC-ND license (<http://creativecommons.org/licenses/by-nc-nd/4.0/>).

<https://doi.org/10.1016/j.jvscit.2018.01.005>

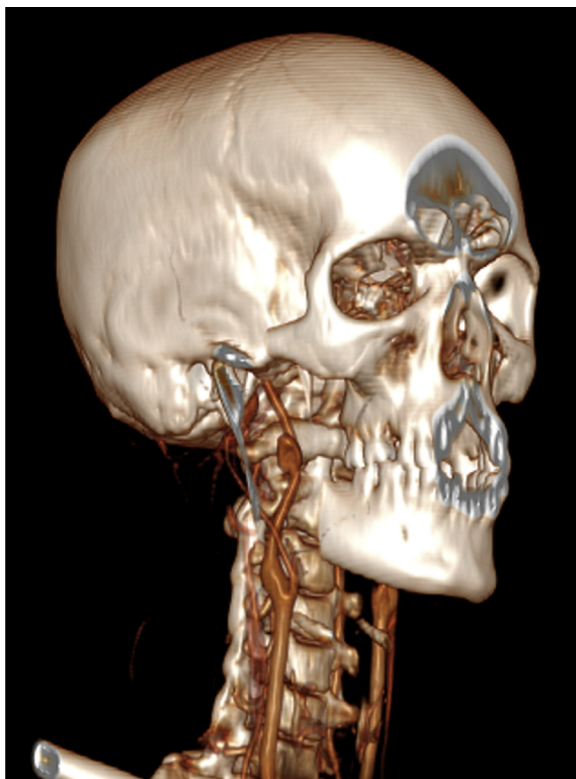


Fig 1. Computed tomography three-dimensional image of right distal carotid artery aneurysm.

Repair. Both patients were premedicated with dual anti-platelet agents including aspirin 300 mg and clopidogrel 300 mg. In both patients, a cutdown technique was performed under local anesthesia at the base of the neck through a 3-cm vertical incision between the two heads of the sternocleidomastoid muscle. The dissection was performed proximal to the omohyoid muscle, and the internal jugular vein was retracted laterally. A 3-cm segment of the common carotid artery (CCA) was dissected, and a vessel loop was placed proximally at the level of the clavicle. Both patients were given 80 units/kg of heparin intravenously. A 5.0 Prolene purse-string suture was placed at the anterior wall of the CCA. A micropuncture needle was used to access the CCA at the purse-string suture. A 0.018-inch microwire was advanced through the needle 4 cm only into the CCA. The microneedle was exchanged to a 5F soft MicroSheath (Bard Peripheral Vascular, Tempe, Ariz) that was advanced only 2 cm into the CCA. Angiography was performed in anterior and oblique views to confirm access of the true lumen of the CCA and to open the carotid bifurcation. Fade technique was used to guide the 0.018-inch wire into the external carotid artery. The MicroSheath was advanced with the dilator over the microwire into the external carotid artery. The microwire was exchanged to the 0.035-inch stiff wire. The MicroSheath was exchanged to the Silk Road 8F arterial sheath (Silk Road Medical, Sunnyvale, Calif) over the stiff wire. This sheath can be advanced only 2 cm into the CCA. During the cutdown, the second team established access to the contralateral common femoral vein with standard ultrasound puncture.

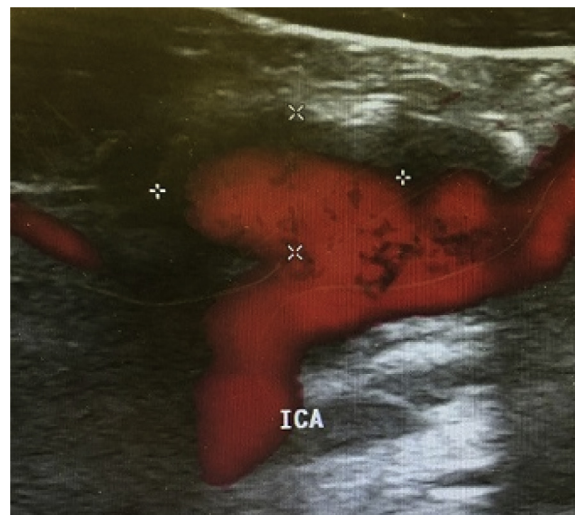


Fig 2. Duplex ultrasound (DUS) image of post-carotid endarterectomy (CEA) right carotid artery pseudoaneurysm (CAP). ICA, Internal carotid artery.

The Silk Road 8F venous sheath was inserted into the common femoral vein. The arterial line was connected to the venous sheath through the flow reversal connecting tubing. After a therapeutic level of activated clotting time was ensured, the CCA was clamped with an atraumatic vascular clamp proximal to the arterial sheath at the level of the clavicle. This established active cerebral reversal flow neuroprotection. Angiography was performed through the arterial sheath while holding the flow stopper button on the flow modular regulator. This angiogram showed the anatomy of the distal ICA and the aneurysm (Fig 3). This imaging helped confirm the diameter of the ICA proximal and distal to the aneurysm as well as the length needed to cover the entire length of the aneurysm. Next, we advanced a 0.018-inch (190-cm) wire under reversal flow into the distal ICA using fade fluoroscopy technique. Next, we advanced and deployed a Viabahn endoprosthesis (W. L. Gore & Associates, Flagstaff, Ariz) through the arterial sheath. The size of the stent was 5/50 mm for the first patient and 6/50 mm for the second patient, ensuring complete coverage of the entire aneurysm and at least an additional 1 cm proximal and distal to healthy carotid artery. We repeated angiography, which showed complete exclusion of the aneurysm and preservation of the external carotid. Aneurysm repair was accomplished using the Viabahn endoprosthesis through TCAR with the ENROUTE Transcarotid Neuroprotection System (Silk Road Medical) for stroke prevention. More technical details of TCAR have been described before.¹⁰ Both patients remained neurologically stable during and after the procedure. Carotid DUS confirmed stent patency with thrombosis of the CAP 2 weeks after the procedure. Patients were free of neurologic complications at 30 days, 3 months, and 12 months of follow-up. Carotid DUS confirmed stent graft patency and resolution of the aneurysms.

DISCUSSION

The selection of a surgical vs an endovascular treatment approach depends on multiple etiologic, anatomic, and

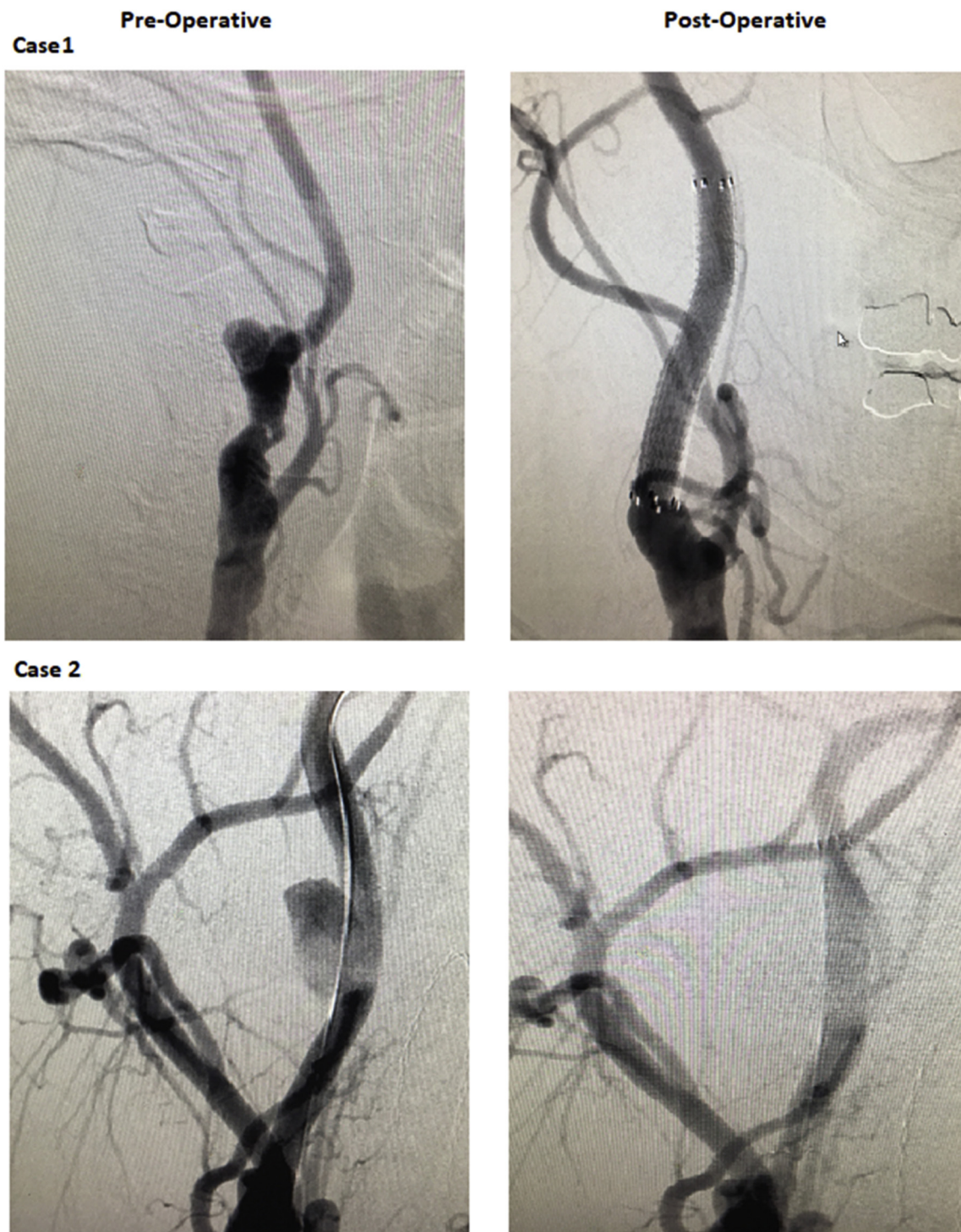


Fig 3. Preoperative and postoperative digital subtraction arteriograms of carotid artery pseudoaneurysm (CAP).

patient-related factors. Open surgical repair is preferred for most infected and ruptured aneurysms. The endovascular approach is preferred in pseudoaneurysms related to trauma, in true aneurysms of the distal ICA, and in patients with hostile neck anatomy (prior neck surgery or irradiation).¹¹ Options for endovascular repair include

bare-metal stent placement with trans-stent coil embolization of the aneurysm, sac exclusion of the aneurysm using a stent graft, and endovascular occlusion of the ICA.^{4,9,11-14}

We chose the endovascular approach because the aneurysm was too distal to be accessed surgically in

the first case and because of prior CEA in the second patient. There are numerous distal and proximal embolic protection devices available today.^{10,15,16} Operators can select the device of choice according to lesion characteristics to reduce the risk of embolism and stroke. For the distal protection filter device to be used, the filter has to be passed through or next to the aneurysm, and sometimes predilation with a balloon is necessary if there is an associated restenosis (prior CEA), which increases the risk of distal embolization, especially when there is an intramural thrombus. Another important aspect is the distal location of many of these aneurysms, leaving no room for safe placement of a distal embolic protection device. In both of our patients, there was significant thrombus within the CAP, and in the first case, the aneurysm was located in the distal ICA. We chose the TCAR approach with the neuroprotection system while placing the stent graft for neuroprotection. The direct access to the CCA has another technical advantage of easy delivery of stent grafts, which are often less flexible, as opposed to navigating the aortic arch with a transfemoral approach. This is especially useful in older patients with tortuous anatomy and severe arch atherosclerosis. Establishing cerebral protection before any lesion manipulation offers another advantage to use of angled catheters to support access to the distal ICA in case of difficult angulated carotid bifurcations without the need for a "buddy wire" as in the transfemoral approach.

TCAR with the ENROUTE Transcarotid Neuroprotection System for stroke prevention is a relatively newer technique for treatment of high-risk patients with carotid artery stenosis. It combines surgical principles of neuroprotection and endovascular techniques to treat high-grade stenosis in the carotid artery. It allows direct access of the CCA to initiate a high rate of temporary cerebral blood flow reversal to prevent embolization from the carotids to the brain while carotid artery stenting is being performed. Thus, it avoids the unprotected catheterization of the arch and lesion. To date, as shown by the Safety and Efficacy Study for Reverse Flow Used During Carotid Artery Stenting Procedure (ROADSTER) study, this technique has the lowest reported hazards of 30-day stroke and death compared with any other carotid artery stenting techniques.¹⁷

CONCLUSIONS

TCAR under cerebral flow reversal may have several advantages in treating carotid artery aneurysms in selected patients and should be considered another option, when appropriate, to minimize the risk of embolization and stroke.

REFERENCES

1. Nordanstig J, Gelin J, Jensen N, Osterberg K, Stromberg S. National experience with extracranial carotid artery

- aneurysms: epidemiology, surgical treatment strategy, and treatment outcome. *Ann Vasc Surg* 2014;28:882-6.
2. Padayachy V, Robbs JV. Carotid artery aneurysms in patients with human immunodeficiency virus. *J Vasc Surg* 2012;55:331-7.
 3. Garg K, Rockman CB, Lee V, Maldonado TS, Jacobowitz GR, Adelman MA, et al. Presentation and management of carotid artery aneurysms and pseudoaneurysms. *J Vasc Surg* 2012;55:1618-22.
 4. Zhou W, Lin PH, Bush RL, Peden E, Guerrero MA, Terramani T, et al. Carotid artery aneurysm: evolution of management over two decades. *J Vasc Surg* 2006;43:493-6; discussion: 497.
 5. Fankhauser GT, Stone WM, Fowl RJ, O'Donnell ME, Bower TC, Meyer FB, et al. Surgical and medical management of extracranial carotid artery aneurysms. *J Vasc Surg* 2015;61:389-93.
 6. Branch CL Jr, Davis CH Jr. False aneurysm complicating carotid endarterectomy. *Neurosurgery* 1986;19:421-5.
 7. Saatci I, Cekirge HS, Ozturk MH, Arat A, Ergungor F, Sekerci Z, et al. Treatment of internal carotid artery aneurysms with a covered stent: experience in 24 patients with mid-term follow-up results. *AJNR Am J Neuroradiol* 2004;25:1742-9.
 8. Bush RL, Lin PH, Dodson TF, Dion JE, Lumsden AB. Endoluminal stent placement and coil embolization for the management of carotid artery pseudoaneurysms. *J Endovasc Ther* 2001;8:53-61.
 9. Coldwell DM, Novak Z, Ryu RK, Brega KE, Biffi WL, Offner PJ, et al. Treatment of posttraumatic internal carotid arterial pseudoaneurysms with endovascular stents. *J Trauma* 2000;48:470-2.
 10. Malas MB, Leal J, Kashyap V, Cambria RP, Kwolek CJ, Criado E. Technical aspects of transcarotid artery revascularization using the ENROUTE transcarotid neuroprotection and stent system. *J Vasc Surg* 2017;65:916-20.
 11. Li Z, Chang C, Yao C, Guo L, Liu Y, Wang M, et al. Endovascular stenting of extracranial carotid artery aneurysm: a systematic review. *Eur J Vasc Endovasc Surg* 2011;42:419-26.
 12. McCready RA, Divilbiss JL, Bryant MA, Denardo AJ, Scott JA. Endoluminal repair of carotid artery pseudoaneurysms: a word of caution. *J Vasc Surg* 2004;40:1020-3.
 13. Szopinski P, Ciostek P, Kielar M, Myrcha P, Pleban E, Noszczyk W. A series of 15 patients with extracranial carotid artery aneurysms: surgical and endovascular treatment. *Eur J Vasc Endovasc Surg* 2005;29:256-61.
 14. Martin ND, Carabasi RA, Bonn J, Lombardi J, DiMuzio P. Endovascular repair of carotid artery aneurysms following carotid endarterectomy. *Ann Vasc Surg* 2005;19:913-6.
 15. Mousa AY, Campbell JE, Aburahma AF, Bates MC. Current update of cerebral embolic protection devices. *J Vasc Surg* 2012;56:1429-37.
 16. Bijuklic K, Wandler A, Hazizi F, Schofer J. The PROFI study (prevention of cerebral embolization by proximal balloon occlusion compared to filter protection during carotid artery stenting): a prospective randomized trial. *J Am Coll Cardiol* 2012;59:1383-9.
 17. Kwolek CJ, Jaff MR, Leal JI, Hopkins LN, Shah RM, Hanover TM, et al. Results of the ROADSTER multicenter trial of transcarotid stenting with dynamic flow reversal. *J Vasc Surg* 2015;62:1227-34.

Submitted Sep 18, 2017; accepted Jan 22, 2018.