

UC San Diego

UC San Diego Previously Published Works

Title

Hooverball: Case Study, Literature Review and Clinical Recommendations

Permalink

<https://escholarship.org/uc/item/19p4d7j0>

Journal

Journal of Rehabilitation Medicine – Clinical Communications, 3(1)

ISSN

2003-0711

Authors

Anders, Alpha
Vitale, Kenneth

Publication Date

2020

DOI

10.2340/20030711-1000038

Peer reviewed

CASE REPORT

HOOVERBALL: CASE STUDY, LITERATURE REVIEW AND CLINICAL RECOMMENDATIONS

Alpha ANDERS, MD¹ and Kenneth VITALE, MD, FACSM, FAAPMR, CAQSM²

¹Department of Internal Medicine, Section of Physical Medicine and Rehabilitation, LSU Health New Orleans School of Medicine, New Orleans, Louisiana,

²Department of Orthopedic Surgery, University of California San Diego School of Medicine, La Jolla, CA 92037, USA

With the increasing popularity of extreme conditioning programmes, athletes and patients are searching for new, engaging, high-intensity, total-body workouts. The sport of Hooverball is increasingly used as a workout. First devised in the USA in 1929 to keep President Hoover physically fit, Hooverball has experienced increasing popularity in the past 15 years. The game is scored like tennis and played like volleyball, with players throwing and catching a heavy medicine ball over a volleyball net. Players use complex, multi-joint, explosive movements, featuring torsion, flexion and extension to absorb the forces involved. This paper reports a case of a Hooverball player who presented with a knee injury. The paper also reviews the origins of the sport, and its increase in popularity related to the increasing prominence of extreme conditioning programmes. A literature review, and common Hooverball-related injuries, are presented. Clinical recommendations are set out for patient safety, injury prevention and game coverage, including a prehabilitation strategy for players prior to engaging in this revived and growing sport.

Key words: Hooverball; extreme conditioning programme; medicine ball; prehabilitation; meniscus; knee injury; athlete; physical fitness; patient safety.

Accepted Jul 28, 2020; published Sep 30, 2020

JRM-CC 2020; 3: jrmcc00040

Correspondence address: Kenneth Vitale, Department of Orthopedic Surgery, University of California San Diego, 9300 Campus Point Drive, #7894, La Jolla, CA 92037, USA. E-mail: kvitale@ucsd.edu

Devised in the USA by physician Joel T. Boone in 1929 to keep President Hoover physically fit, Hooverball is a combination of tennis and volleyball, played with a weighted medicine ball (1, 2). The game is scored like

LAY ABSTRACT

With the increasing popularity of “extreme conditioning” exercise programmes, players and patients are searching for new and engaging high-intensity, total-body workouts. This report examines the case of Hooverball, a revived workout. First invented in the USA in 1929 to keep President Hoover physically fit, Hooverball has experienced an increase in popularity over the past 15 years. The game is scored like tennis and played like volleyball, but instead of striking a lightweight ball, players throw and catch a heavy medicine ball over a volleyball net. In order to absorb the impact and return a medicine ball over the net, players use complex, multi-joint, explosive movements. This paper reviews the origins of the sport and its increase in popularity related to the increasing prominence of extreme conditioning programmes. Clinical recommendations are set out for patient safety, injury prevention and game coverage, including a prehabilitation strategy for players prior to engaging in this revived and growing sport.

tennis and is classically played on a 20 × 9 m (66 × 30 foot) sand or hardwood court, with a medicine ball weighing 2.72 kg (6 pounds) or more and an 2.43 m (8 foot) high volleyball net. With 2–4 players on each team, the game starts with 1 player throwing the medicine ball over the net. The opposing team attempts to catch the weighted ball mid-air and return it over the net in rapid succession to initiate a volley. Both teams strive to make the ball land inbounds on their opponent’s side. Players use complex, explosive movements, featuring dynamic torsion, flexion and extension, in multi-joint patterns to absorb the impact and return the throw of the heavy ball at high speed. Today, the game is played with medicine balls weighing 9 kg (20 pounds) or

more. With the increase in popularity of extreme conditioning programmes (ECP) in the past 20 years, Hooverball has emerged as a popular sport, played on military bases and in CrossFit gyms across the country; some National Football League athletes play to keep fit and mimic game intensity (3, 4). However, there is a lack of research regarding Hooverball. A search of PubMed and expanded NCBI All database catalogue, using the key words “Hooverball,” “Hoover-ball,” and “Hoover ball” on 23 June 2020 yielded no results. Additional searches of CINAHL and Embase also generated zero results, and a search of Google Scholar yielded no medical journals.

This paper reports a case of a Hooverball player who developed a knee injury. In addition, the paper reviews the available literature on Hooverball and provides clinical commentary on the sport, its potential injuries and injury prevention, and describes a prehabilitation strategy. Musculoskeletal and sports medicine providers treating athletes should be aware of this growing sport and the potential risk of injury.

CASE REPORT

An active 68-year-old man presented to an academic sports medicine clinic with right lateral knee pain, initially in 2016. His medical history was unremarkable for any chronic diseases. In 1964 he had developed right knee pain from playing Hooverball and was told that he had a “torn ligament”, but did not recall details. Since then, he had remained highly active, regularly exercising vigorously. At home he used parallel bars and gymnastics rings, engaged in regular callisthenic and plyometric exercises, and routinely performed 2-m jumps across small ravines. He also continued to play Hooverball.

Six months previously he had twisted his right leg playing Hooverball and felt a sharp lateral knee pain. Since then, he had experienced intermittent exacerbations of swelling and sharp lateral knee pain with twisting and pivoting during Hooverball, occasional catching/clicking, but no instability of the knee joint. He did not report any radiating pain, paraesthesia, or weakness.

Physical examination was notable for tenderness along the lateral joint line and mild joint effusion. Range of motion was 0–130° with pain at end range flexion and a positive McMurray’s test for pain and clicking. He had mild increased tibial translation, with Lachman test (2B).

Knee X-rays showed mild degenerative changes and a possible effusion. Magnetic resonance imaging (MRI)

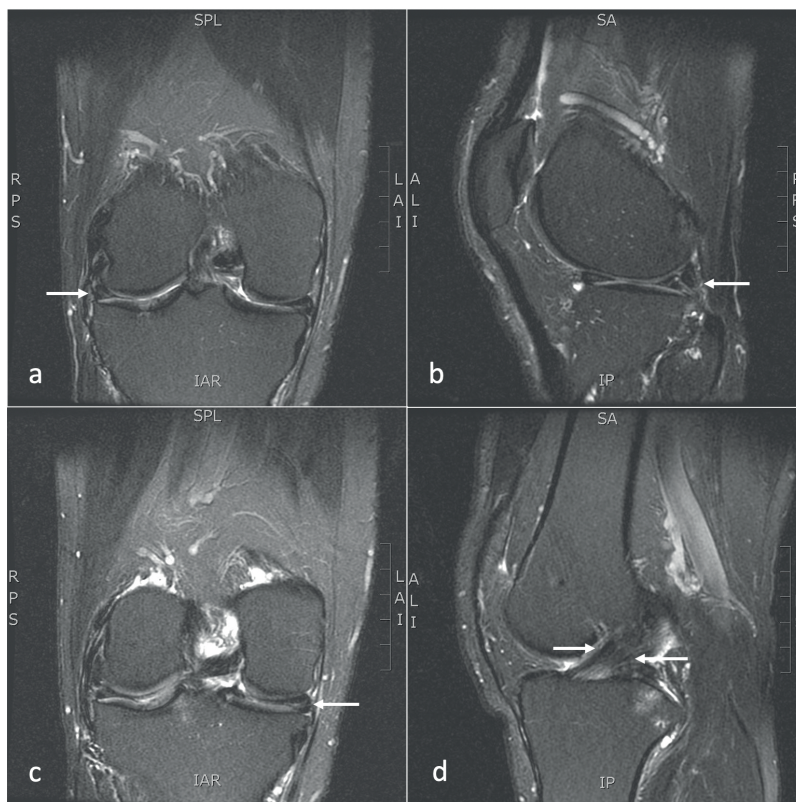


Fig. 1. (a) Sagittal and (b) coronal T2-weighted magnetic resonance imaging (MRI). Arrows indicate longitudinal horizontal oblique tear of the lateral meniscus (linear white signal within black meniscus). (c) Coronal T2-weighted MRI. Arrows indicate horizontal longitudinal medial meniscal tear with similar white signal intensity. (d) Sagittal T2-weighted MRI. Arrows indicate thickened anterior cruciate ligament (ACL) compatible with chronic low-grade injury/sprain

revealed a longitudinal horizontal oblique tear of the entire lateral meniscus, a longitudinal horizontal tear of the body and posterior horn of the medial meniscus, and thickening of the anterior cruciate ligament consistent with chronic low-grade injury/sprain (Fig. 1).

The patient was counselled on diagnoses and treatment options and proceeded with conservative management, including physical therapy and a modified home exercise programme. He declined bracing, injections, or surgery. Given his history, it is likely that he had an acute on chronic injury. The suspected mechanism of injury was combined torsion on a flexed knee and planted foot with deceleration/eccentric absorption of energy from the medicine ball, followed by a strong acceleration force in the lateral medicine ball throw/lateral scoop toss technique of Hooverball. This fast transition from absorbing kinetic energy, followed by summing sufficient force to propel the weighted ball in the opposite direction, is similar to high-velocity techniques of plyometric and ballistic exercise (“load and explode”), which carry increased risk of injury similar to other weight-training programmes if performed incorrectly (5).

Two months after the current presentation, the patient reported an overall improvement in symptoms and decreased swelling. He was eventually able to return to Hooverball and other plyometric exercise, but presented

again in 2019 with recurrent knee pain after performing plyometric ravine jumps. He was still playing Hooverball and exercising regularly; he was counselled on proper form and activity modification.

CASE DISCUSSION AND LITERATURE REVIEW

This case study presents a number of interesting points. A highly active, athletic, older patient presented with an acute on chronic meniscal tear secondary to playing a sport that entails complex full-body multidirectional movements, including torsion, flexion, extension, and acceleration/deceleration. The mechanism of injury and management of chronic degenerative and acute traumatic meniscal injuries has been described in the literature (6–8). However, there is little published research regarding Hooverball injuries. Due to its dynamic total-body and high-intensity movements, Hooverball has been incorporated into ECPs, such as CrossFit.

ECPs are aggressive training workouts that feature a variety of high-intensity exercises performed at a high volume of repetitions in sets, with limited rest periods between sets (9). Medicine balls are used in ECP training, thrown in a similar way as in Hooverball regarding height, distance, speed, and power. Unlike CrossFit and other ECPs, catching a medicine ball is relatively unique to Hooverball.

In order to help President Hoover to lose weight and improve his cardiovascular health, his personal physician devised “Hoover Rules Medicine Ball (1, 10).” Hoover routinely played the game with members of his Cabinet and Supreme Court, using a 1.8 kg (4-pound) medicine ball (10). Players are typically recommended to assume a wide, solid stance, similar to the athletic position or stance (e.g. shortstop or running back in the ready position) “before receiving the ball due to its weight (10).” President Hoover’s personal physicians explained to him that 30 min of Hooverball could provide “as much total body exercise as three hours of golf or one hour of tennis (10).” Thus, the sport could be considered as an early high-intensity cross-training programme or ECP.

The injury rate in CrossFit and ECPs is controversial. The rates have been shown to be either comparable to, or more than twice as likely as in traditional weightlifting or other recreational activities (5, 11). However, another study concluded that injury risk is comparable to *or lower than* common forms of exercise or strength training (12). One study determined that the intensity of exercise, rather than the exercise itself, is what causes the higher observed rate of injury in CrossFit (11). Given the complex, full-body motions and inherent intensity, athletes who want to embark on Hooverball have been recommended to be “physiologically prepared to enjoy the sport without undue risk of injury (10).”

There are no published studies in PubMed, PubMed-Central or other NCBI databases, Embase or CINAHL that document the incidence or types of injuries in

Hooverball, and no medical studies specifically document medicine ball injuries. There is only one partially related study that assessed workout-related emergency department (ED) visits in 2016 that were reported to the US National Electronic Injury Surveillance System (13, 14). Specifically, medicine ball injuries (although not the sport of Hooverball) accounted for 6.2% of equipment-related workout injuries resulting in a visit to an ED. Most of these injuries were at the gym using a medicine ball. However, the most common injury was a potentially serious one: head trauma from the medicine ball slipping or falling onto the exerciser’s head. Based on the senior author’s clinical experience, common injuries seen with Hooverball include knee meniscal and cruciate ligament injuries, as in the case reported here, low-back pain exacerbations, shoulder labral and rotator cuff injuries, neck strain and head trauma/concussions. Routine ankle and wrist sprains may also occur.

Injury prevention

Prehabilitation is recommended to reduce the potential of injury (15, 16). Prehabilitation promotes the restoration of healthy patterns and neuromuscular recruitment that may be absent or altered after a prior injury (15) and emphasizes interventions, such as gait retraining, to encourage healthy movement (15). Some believe that poor training habits and/or biomechanical asymmetries may predispose to a non-contact injury, especially in young athletes who are still growing (16). Throwing a medicine ball at high speed requires plyometric and ballistic movements at high intensities and odd body angles; therefore prehabilitation may be appropriate for Hooverball.

The authors advocate a basic level of fitness before commencing such a demanding exercise. The American College of Sports Medicine recommendations may be an appropriate starting point, as it incorporates aspects of both cardiovascular fitness (150 min of moderate-intensity exercise per week) and strength and neuromotor exercise (2–3 days a week) (17); if athletes meet these guidelines, they are likely to tolerate the more vigorous intensity of Hooverball.

Correct warm-up is highly recommended and commonly used prior to any high-intensity exercise. Pre-game warm-up should include sport-specific movements that mimic the neuromuscular patterns of the sport, initially at lower intensities followed-by higher intensities. This may improve biomechanics (18), help improve performance, and reduce risk of injury (18, 19).

The authors also suggest that anyone engaging in ECPs should have some prior agility experience, preferably in an organized sport (team or individual) that has regular practice and competition. Although agility experience is not a requirement of commencing high-intensity exercise, the authors have observed several injuries in ECPs in patients who may not be accustomed to the combination of intensity plus agility, strength plus power, with limited

rest periods. Untrained individuals who then combine multiple facets of an exercise regimen simultaneously, at high intensity and with heavy weights, may be at risk.

Event coverage

For musculoskeletal and sports medicine physicians providing medical event coverage, there are a few recommendations. The tent set-up and sideline medical bag should include similar equipment to that used in other sport event coverage (20), with a few additional suggestions. Head trauma and whiplash-associated injuries may occur with medicine ball collisions to the head; orbital trauma assessment tools and cervical collars may be appropriate. In the era of increased concussion awareness, providers should be well-versed in concussion assessment, have appropriate concussion screening assessment and tools, and know the chain-of-command for transport to medical facilities for further workup. For simpler injuries, Hooverball players may present to the tent requesting wrist, ankle and knee taping; hence, there should be adequate supplies and clinicians need to be familiar with taping techniques. Rules in North America for obtaining radiographs following injury have evolved over the years; familiarity with, for example, the current versions of the Ottawa Foot and Ankle rules, Pittsburgh and Ottawa Knee rules, and Quebec shoulder rules may help guide the provider in decision making (21).

In the USA, there are regional and national tournaments in Hooverball, which may represent an outreach opportunity for sports medicine physicians to provide medical services to the community and this growing sport, which has injury risk and may not yet have formal medical coverage.

Conclusion

This case report and literature review regarding Hooverball enables clinical recommendations, prehabilitation options, and advice to be set out to help individuals who want to play Hooverball to be adequately prepared for the sport. Further research is needed to assess the kinesiology of the sport's athletic movements, determine proper technique, evaluate safety and injury incidence, and help determine injury prevention strategies for Hooverball players.

ACKNOWLEDGEMENTS

The authors received no funding, grants or equipment for this research. There are no financial benefits to either author.

The authors have no conflicts of interest to declare.

REFERENCES

1. History of Hoover-ball. The Herbert Hoover Presidential Library and Museum. 2017 [cited 2020 Jun 23]. Available from: <https://hoover.archives.gov/hoovers/history-hoover-ball>.
2. Hooverball | game. Encyclopedia Britannica. [Cited 2020 Jun 23]. Available from: <https://www.britannica.com/sports/Hooverball>.
3. Hoover-ball: a president's game becomes a CrossFit sensation. [Cited 2020 Jun 23]. Available from: <https://www.wbur.org/onlyagame/2016/03/05/hoover-ball-crossfit-president-politics>.
4. Rollins K. Watch: James Harrison plays volleyball with medicine ball. Sports Illustrated. [Cited 2020 Jun 23]. Available from: <https://www.si.com/extra-mustard/2017/06/27/james-harrison-pittsburgh-steelers-plays-volleyball-medicine-ball-video>.
5. Aune KT, Powers JM. Injuries in an extreme conditioning program. Sports Health 2017; 9: 52–58.
6. Brukner P, Khan K. Clinical sports medicine. 3rd edition. Sydney: McGraw-Hill Book Co. Australia; 2006, p. 1084.
7. Beaufils P, Pujol N. Management of traumatic meniscal tear and degenerative meniscal lesions. Save the meniscus. Orthop Traumatol Surg Res 2017; 103: S237–244.
8. Brelin AM, Rue J-PH. Return to play following meniscus surgery. Clin Sports Med 2016; 35: 669–678.
9. Bergeron MF, Nindl BC, Deuster PA, Baumgartner N, Kane SF, Kraemer WJ, et al. Consortium for Health and Military Performance and American College of Sports Medicine consensus paper on extreme conditioning programs in military personnel. Curr Sports Med Rep 2011; 10: 383–389.
10. Sailor S. Heave ho: re-introducing Hooverball. Strategies 1992; 5: 20.
11. Elkin JL, Kammerman JS, Kunselman AR, Gallo RA. Likelihood of injury and medical care between crossfit and traditional weightlifting participants. [Cited 2020 Jun 23] Orthop J Sports Med 2019; 7 (5) 2325967119843348.
12. Klimek C, Ashbeck C, Brook AJ, Durall C. Are injuries more common with CrossFit training than other forms of exercise? J Sport Rehabil 2018; 27: 295–299.
13. National Electronic Injury Surveillance System (NEISS). CPSC.gov. 2018 [cited 2020 Jun 23]. Available from: <https://www.cpsc.gov/Research--Statistics/NEISS-Injury-Data>.
14. Workouts gone wrong. EllipticalReviews.com. [Cited 2020 Jun 23]. Available from: <https://www.ellipticalreviews.com/workouts-gone-wrong/>.
15. Tenforde AS, Shull PB, Fredericson M. Neuromuscular prehabilitation to prevent osteoarthritis after a traumatic joint injury. PM R 2012; 4: S141–S144.
16. Pearce PZ. Prehabilitation: preparing young athletes for sports. Curr Sports Med Rep 2006; 5: 155–160.
17. American College of Sports Medicine. ACSM's guidelines for exercise testing and prescription. 10th edition. Philadelphia, PA: Wolters Kluwer Health; 2016, p. 472.
18. Hewett TE, Ford KR, Xu YY, Khoury J, Myer GD. Effectiveness of neuromuscular training based on the neuromuscular risk profile. Am J Sports Med 2017; 45: 2142–2147.
19. Zemková E, Hamar D. Sport-specific assessment of the effectiveness of neuromuscular training in young athletes. Front Physiol 2018; 9: 264.
20. Daniels JM, Kary J, Lane JA. Optimizing the sideline medical bag preparing for school and community sports events. Phys Sportsmed 2005; 33: 9–16.
21. Gould SJ, Cardone DA, Munyak J, Underwood PJ, Gould SA. Sideline coverage: when to get radiographs? A review of clinical decision tools. Sports Health 2014; 6: 274–278.