

UCSF

UC San Francisco Previously Published Works

Title

GABAA receptor autoimmunity: A multicenter experience

Permalink

<https://escholarship.org/uc/item/1bq3n4s8>

Journal

Neurology Neuroimmunology & Neuroinflammation, 6(3)

ISSN

2332-7812

Authors

O'Connor, Kevin
Waters, Patrick
Komorowski, Lars
et al.

Publication Date

2019-05-01

DOI

10.1212/nxi.0000000000000552

Peer reviewed

GABA_A receptor autoimmunity

A multicenter experience

Kevin O'Connor, MD, Patrick Waters, PhD, Lars Komorowski, PhD, Anastasia Zekeridou, MD, Chu-Yueh Guo, MD, Victor C. Mgbachi, BSc, Christian Probst, PhD, Swantje Mindorf, MS, Bianca Teeegen, PhD, Jeffrey M. Gelfand, MD, Michael D. Geschwind, MD, PhD, Vanda Lennon, MD, PhD, Sean J. Pittock, MD, and Andrew McKeon, MD

Correspondence

Dr. McKeon
mckeon.andrew@mayo.edu

Neurol Neuroimmunol Neuroinflamm 2019;6:e552. doi:10.1212/NXI.0000000000000552

Abstract

Objective

We sought to validate methods for detection and confirmation of GABA_A receptor (R)-IgG and clinically characterize seropositive cases.

Methods

Archived serum and CSF specimens (185 total) suspected to harbor GABA_AR-IgG were evaluated by indirect immunofluorescence assay (IFA). Twenty-six specimens from 19 patients appeared suspicious for GABA_AR-IgG positivity by IFA, based on prior reports and comparison with commercial GABA_AR antibody staining. Aliquots of those specimens were tested at the University of Oxford, United Kingdom, and Euroimmun, Lubeck, Germany, for GABA_AR-IgG by cell-based assays (CBAs) using HEK293-indicator cells transfected with plasmids encoding different GABA_AR subunits.

Results

Eight specimens (of 26 tested; 4 serums, 4 CSFs) from 5 patients were confirmed by CBA to be GABA_AR-IgG positive. Patient IgGs were always reactive with $\alpha 1\beta 3$ GABA_AR subunits. One more patient was identified clinically after this validation study. Median age for the 6 patients at serologic diagnosis was 44 years (range, 1–71 years), and 4 of them were male. Among the 4 for whom clinical information was available (2 treated by the authors), all had encephalitis and antiepileptic drug refractory seizures. Three out of 4 patients treated with a combination of immunotherapies had good outcomes. The fourth, recognized to have an autoimmune cause late in the clinical course, had severe permanent neurologic sequelae and brain atrophy.

Conclusions

Though not as common as NMDA-R encephalitis, GABA_AR encephalitis generally has a characteristic clinical-radiologic presentation and is treatable, making accurate laboratory diagnosis critical.

RELATED ARTICLE

Editorial

Encephalitis, severe seizures, and multifocal brain lesions: Recognizing autoimmunity to the GABA_A receptor

Page e554

From the Department of Laboratory Medicine and Pathology (K.O.C., A.Z., V.L., S.J.P., A.M.), Department of Neurology (A.Z., V.L., S.J.P., A.M.), and Department of Immunology (V.L.), Mayo Clinic, Rochester, MN; Oxford Autoimmune Neurology Group (P.J.W., V.C.M.), Nuffield Department of Clinical Neurosciences, UK; Institute for Experimental Immunology (L.K., C.P., S.M., B.T.), Affiliated to Euroimmun AG, Luebeck, Germany; and the Department of Neurology (C.Y.G., J.M.G., M.D.G.), University California, San Francisco.

Funding information and disclosures are provided at the end of the article. Full disclosure form information provided by the authors is available with the full text of this article at Neurology.org/NN.

The Article Processing Charge was funded by the authors.

This is an open access article distributed under the terms of the Creative Commons Attribution-NonCommercial-NoDerivatives License 4.0 (CC BY-NC-ND), which permits downloading and sharing the work provided it is properly cited. The work cannot be changed in any way or used commercially without permission from the journal.

Glossary

CBA = cell-based assay; **GABA_A** = γ aminobutyric acid; **GAD** = glutamic acid decarboxylase; **IFA** = immunofluorescence assay; **IVIg** = intravenous immune globulin; **WBC** = white blood cell.

Diagnostic certainty is often lacking in neural-IgG antibody seronegative autoimmune encephalitis.¹ Novel disease-specific IgG biomarker characterization enhances diagnostic sensitivity. γ -aminobutyric acid (GABA_A) receptor (R) encephalitis is an immunotherapy responsive, presumably IgG-mediated, disorder. Patient IgGs target the $\alpha 1$ and $\beta 3$ subunits of the pentameric GABA_AR (nicotinic acetylcholine receptor superfamily of ligand-gated ion channels, arranged as γ - β - α - β - α).^{2,3} This disorder appears to be less common than NMDA-R encephalitis (the largest reported series of GABA_AR encephalitis comprised 26 patients, with 11 children).^{3,4} Typically, GABA_AR encephalitis presented with refractory status epilepticus, or *epilepsia partialis continua*, with multifocal MRI lesions in the cerebral cortex and subcortex. We sought archival cases in the Mayo Clinic Neuroimmunology Laboratory database, based on recorded patterns observed by tissue-based indirect immunofluorescence assay (IFA), and characterized those patterns in detail. Findings were confirmed by cell-based assays (CBAs) in 2 international research and diagnostic laboratories (the University of Oxford, UK, and Euroimmun, Lubeck, Germany).

Methods

Standard protocol approvals, registrations, and patient consents

The Mayo Clinic institutional review board approved this study (IRB # 08–006647).

Laboratory methods

Archived specimens were sera (116) and CSF specimens (CSFs, 69) from 154 patients referred to the Mayo Clinic Neuroimmunology Laboratory for service evaluation (2011–2018). Those specimens had stained murine brain synapses, by IFA, in a pattern potentially compatible with GABA_AR-IgG (appendix e-1, links.lww.com/NXI/A103).³ On retesting by IFA, 26 of those specimens, from 19 patients, were scored as having moderate (18) or high (8) likelihood of GABA_AR-IgG positivity. Aliquots (serum only, 6; CSF only, 6; both serum and CSF, 7) were tested at the University of Oxford, United Kingdom, and Euroimmun, Lubeck, Germany, for GABA_AR-IgG by CBAs, appendix e-1.

Data availability

All data pertaining to this article are contained within or published as online supplement.

Results

Eight of 26 specimens from 5 patients were confirmed by CBA to be GABA_AR-IgG positive. Four of those 5 patients'

specimens had been scored as high likelihood by IFA. IgG staining was most prominent in synapses of the hippocampus, dentate gyrus, thalamus, and cerebellar granular layer (figure 1). Purkinje cells (figure 1) and myenteric plexus (not shown) did not stain.

For one patient, serum only was positive (CSF unavailable); for another, CSF only was positive (serum unavailable), and for 3 patients both serum and CSF were positive (100%). Inter-CBA testing was concordant for all specimens except for one CSF (negative in the Euroimmun Lab and positive in the Oxford Lab); the paired serum was positive in both laboratories. All positive specimens were reactive with $\alpha 1\beta 3$ GABA_AR subunits. None were reactive with $\gamma 2$ subunit only.

One more patient (number 6, table) was evaluated for encephalitis at Mayo Clinic after the serologic study was completed, and was confirmed to be GABA_AR-IgG-positive at the University of Barcelona. Among the 6 patients, the median age at serologic diagnosis was 44 years (range, 1–71 years), and 4 of them were male (table). Medical histories were available for 4. All had encephalitis with antiepileptic drug refractory seizures. One had neoplasia (thymoma). Three patients treated with immunotherapies had good outcomes.

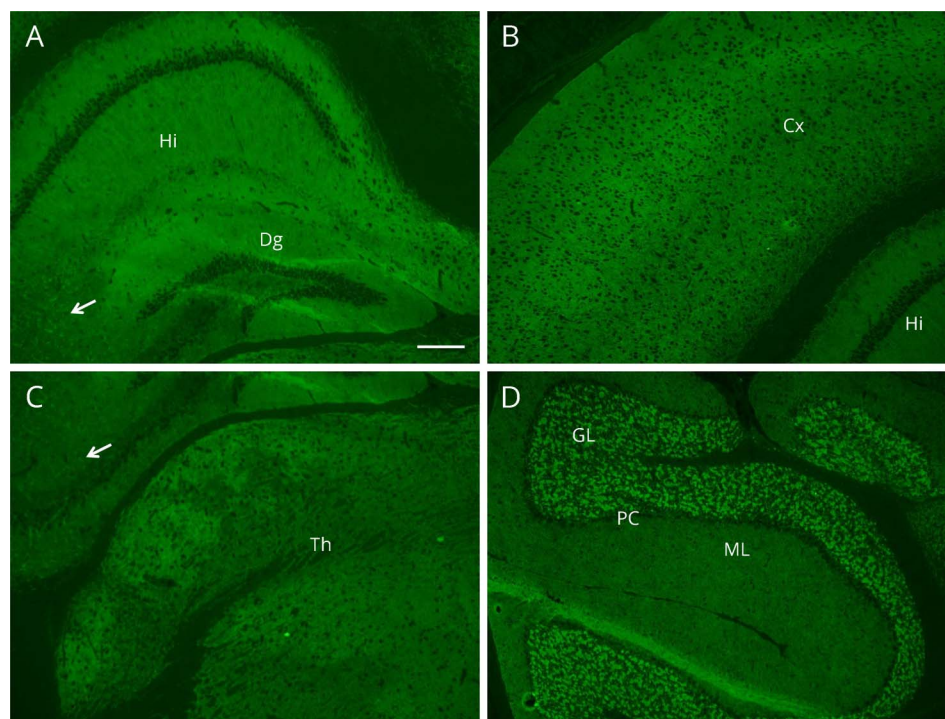
A fourth patient, a one-year-old child, was recognized late to have an autoimmune cause for seizures and had severe permanent neurologic sequelae.

Illustrative cases

Case 3

A 59-year-old man, previously healthy, had seizures consisting of acidic-metallic taste and lip-smacking. Over the next week, the seizure frequency increased, and he developed amnesic symptoms and dysphasia. He had a seizure characterized by right arm and leg tonic-clonic movements. MRI brain showed nonenhancing, confluent T2 hyperintense left medial temporal lobe lesions, and 2 smaller juxtacortical lesions (figure 2A). CSF was initially bland, but 3 weeks into the illness contained 7 white blood cells (WBCs) per μ L (normal value, ≤ 5 ; 86% lymphocytes) and elevated total protein (59 mg/dL; normal, < 35 mg/dL). CT chest revealed an anterior mediastinal mass; thymoma was confirmed at surgical removal. Intravenous immune globulin (IVIg) (2 g/kg divided over 3 days), then IV methylprednisolone (1,000 mg daily for 5 days), was followed by substantial but incomplete cognitive improvements. Improvement continued after thymectomy. Confusion, seizures, and paranoia developed 3 months after initial presentation. CSF examination revealed only elevated total protein (69 mg/dL). Head MRI demonstrated

Figure 1 GABA_A receptor (R)-IgG staining characteristics by tissue-based IFA



GABA_AR-IgG produces intense synaptic staining of the hippocampus (Hi) and dentate gyrus (Dg), (A) cortex (Cx), (B) and thalamus (Th), (C) which relatively spares the CA3 hippocampal region (arrows). Cerebellar synapses more robustly stain in the granular layer (GL) than molecular layer (ML), D. Purkinje cell (PC) staining is absent. Scale bar = 100 μ m.

improvement in some T2 lesions, complete resolution of others, and new lesions in bilateral temporal and frontal lobes (nonenhancing, figure 2B). No further improvement followed IVIg (2 g/kg). However, substantial clinical improvement and long-term seizure cessation accompanied IV methylprednisolone treatment (1,000 mg/d for 5 days) followed by plasma exchange. After treatment, neuropsychological testing demonstrated below average performance in immediate verbal recall and mild problems with confrontation naming, verbal agility, and semantic fluency. Brain MRI showed significant improvement of some lesions, but persistence of others, with temporal lobe atrophy (figure 2C). After 6 months of symptoms, he received rituximab 1,000 mg IV, 2 doses, 2 weeks apart, while continuing a prednisone taper. At 8 months, he was independent in activities of daily living but was not working and needed help managing finances.

Case 4

A 55-year-old woman with a history of Hashimoto thyroiditis, rheumatoid arthritis, Sjogren syndrome, and type 1 diabetes, developed new onset seizures with focal neurologic signs (left-sided weakness). CSF contained 23 WBCs/ μ L (lymphocyte predominant) and normal protein. MRI demonstrated multifocal juxtacortical and subcortical T2 hyperintense lesions, without gadolinium enhancement. For the next 5 years, episodic cognitive impairment continued with recurrence of antiepileptic drug-refractory seizures. Worsening seizures were accompanied by waxing and waning T2-hyperintense MRI lesions, nonenhancing. Symptoms and radiologic abnormalities resolved following treatment with IV methylprednisolone and

plasma exchange. Left frontal lobe biopsy was nondiagnostic. The patient had coexisting glutamic acid decarboxylase (GAD) 65 autoimmunity (serum GAD65-IgG, 280 nmol/L; CSF, 0.08 nmol/L; normal value, \leq 0.02). No neoplasm was identified despite repeated whole-body CT scans over the course of 5 years. PET-CT scan of brain revealed hypermetabolic lesions, some co-localizing with T2-hyperintense lesions in the MRI, and others not (figure 2D). Neurologic examination 2 months after her most recent relapse demonstrated mild difficulties with construction and calculation. Rituximab was recommended for relapse prevention.

Discussion

We identified GABA_AR encephalitis cases by IFA and required CBA to confirm. Consistent with prior reports, this approach did not yield isolated γ 2 subunit-specific positivity.³ GABA_AR encephalitis occurred across the age range and in both sexes.³ Antiepileptic drug-refractory seizures, other encephalitic symptoms, and abnormalities on brain MRI (multifocal, non-diffusion-restricting, nonenhancing, medium-to-large sized cortical, juxtacortical and subcortical lesions) or PET should prompt testing for GABA_AR encephalitis.² Brain MRI may occasionally be normal.³

Search for thymoma should be undertaken in adults, and others (diverse carcinomas and myeloma) should be considered.³ Patients with thymoma, with and without encephalitis, usually have multiple autoantibodies detectable in characteristic profiles

Table Characteristics of 4 GABA_AR encephalitis patients

Patient number/age/sex	Neurologic syndrome	MRI head findings	Other findings	GABA _A R-IgG, serum, CBA-E titer, and CBA-O titer	GABA _A R-IgG, CSF CBA-E titer, and CBA-O titer	Treatment	Outcome	Follow-up (mo)
1/1/F ^a	Encephalitis with refractory status epilepticus; coma for 3 mo	Generalized atrophy	CSF, noninflammatory	NA	32, 4	IVIg, IVMP	Status epilepticus stopped after 3 mo; residual severe cognitive impairment, seizures	24
2/16/M ^b	Encephalitis with seizures	Multifocal bilateral cerebral lesions, nonenhancing (frontal, temporal, occipital)	Nausea, vomiting, weight loss	32, 3.5	NA	IVIg IVMP PLEX Rituximab	Complete recovery	—
3/59/M ^c	EPC (facial twitching) and encephalopathy	Multifocal bilateral cerebral lesions, nonenhancing (frontal, temporal, parietal)	CSF: 7 WBCs; protein, 59 mg/dL (normal, < 35 mg/dL) Thymoma	100, 3.5	10, 4	IVIg IVMP PLEX Rituximab	After IVMP and PLEX, seizures stopped, mild residual cognitive impairment. No relapse since rituximab	8
4/55/F ^d	EPC and pyrexia, with inflammatory brain lesions, recurrent, immune therapy responsive	Multifocal bilateral cerebral lesions, nonenhancing, (frontal, temporal, occipital)	History of RA, Hashimoto thyroiditis, Sjogren syndrome CSF: 23 WBCs, normal protein	NA	NA	IVIg, IVMP, PLEX	After IVMP and PLEX seizures stopped, and brain lesions resolved.	18

Abbreviations: CBA-E = cell-based assay from Euroimmun; CBA-O = Cell-based assay from Oxford. EPC = epilepsy partialis continua; F = female; IVIg = IV immune globulin; IVMP = IV methylprednisolone; M = male; NA = specimen not available; PLEX = plasma exchange; RA = rheumatoid arthritis; WBC = white blood cell.

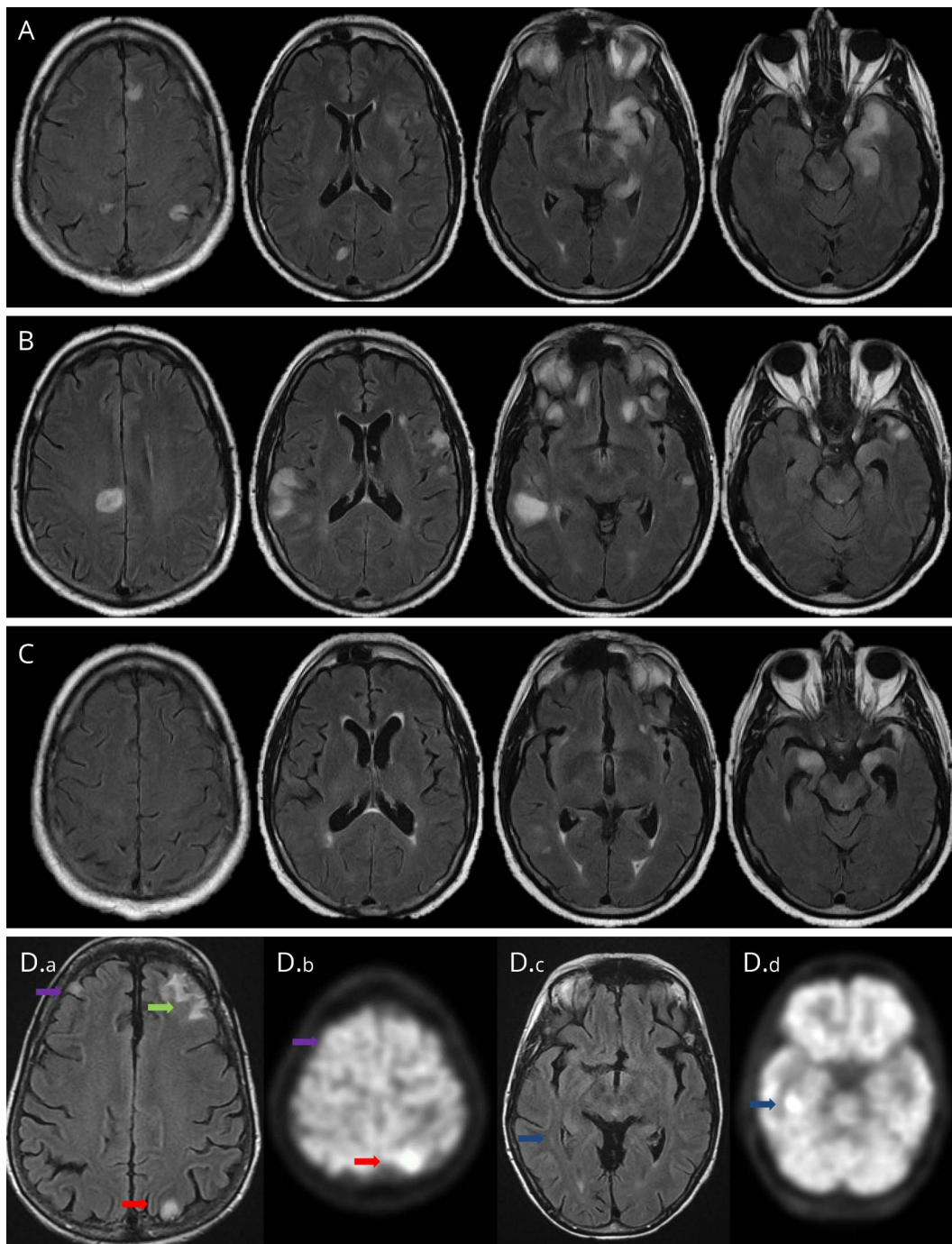
^a Initially thought to have a hereditary disorder, evaluated and treated late for an autoimmune cause.

^b Previously reported as patient 14 in Spatola et al.³

^c Evaluated and treated at University of California San Francisco.

^d Evaluated and treated at Mayo Clinic, Rochester, MN. GABA_AR autoimmunity confirmed at University of Barcelona after completion of this study.

Figure 2 Serial axial brain images from patients 3 (A–C, axial T2 FLAIR) and 4 (D, axial T2 FLAIR and. PET)



(A) At presentation, patient 3 had a large confluent lesion in the left mesial temporal lobe and hippocampus (including hippocampal tail) and adjacent orbital frontal cortex, and 2 smaller cortically based FLAIR hyperintense lesions in the right medial posterior frontal and right medial occipital lobes and left insula. Lesions were hypointense on T1 and had no abnormal enhancement following the administration of gadolinium (not shown). (B) Three months later, repeat MRI demonstrated improvement of earlier abnormalities and new juxta-cortical FLAIR hyperintense lesions in the bilateral frontal and temporal lobes, without abnormal enhancement (not shown). (C) MRI repeated 6 months after initial presentation demonstrated interval improvement in prior lesions and residual T2 hyperintensity within bilateral medial temporal lobes, and asymmetric bilateral temporal lobe atrophy, corresponding to prior regions of T2 hyperintensity. For patient 4, 5 years into her illness, MRI (D.a and D.c) demonstrated cortical and subcortical hyperintensities. FDG/PET-CT hypermetabolism (red and blue arrows, D.b and D.d) occurred in the presence (red arrow, D.a) and absence (blue arrow, D.c) of MRI lesions. (A) FLAIR cortical hyperintensity (purple arrow, D.a) without FDG/PET correlate is also indicated (purple arrow, D.b). Green arrow indicates the patient's biopsy site. FLAIR = fluid-attenuated inversion recovery.

dominated by nicotinic acetylcholine receptor superfamily antigenic specificities.⁵ In some encephalitis cases, GABA_AR-IgG may prove the only serologic clue to an autoimmune

pathogenesis. Other thymoma-pertinent IgG specificities encountered in autoimmune encephalitis include α -amino-3-hydroxy-5-methylisoxazole-4-propionic acid-R, muscle-type

and ganglionic ($\alpha 3$)-type acetylcholine receptors, striational, GAD65, leucine-rich glioma inactivated 1, and contactin associated protein 2.^{5,6}

Both patients we reported in detail were treated promptly with corticosteroids and plasma exchange, and had robust improvements, but relapsed upon treatment withdrawal. In contrast, an infant recognized late to have autoimmune encephalitis had cerebral atrophy and severe permanent neurologic sequelae. At the current time, the Euroimmun and Oxford laboratories identify 5–10 cases of autoimmune GABA_AR encephalitis per year. The number of cases identified prospectively at Mayo Clinic remains to be determined. A prospective study will compare the sensitivity and specificity of different specimen types (serum and CSF) and assays (CBA and IFA). Low titers of serum antibodies detected by CBA only appear less clinically specific.²

In summary, GABA_AR encephalitis should be considered in patients with encephalopathy and seizures (especially those refractory to antiepileptic drugs) with multifocal brain lesions on imaging. Prompt immunotherapy and neoplasm search should follow.

Author contributions

K.O'.C., P.K., L.K., V.M., C.B., B.T., S.M.: data collection, analysis, and interpretation, and critical revision of article. A.Z., C.Y.G.: data collection, analysis, and interpretation, drafting, and critical revision of article. J.M.G., M.D.G., S.J.P., V.A.L.: data collection and analysis, and critical revision of article. A.M.: study concept and design; data collection, analysis, and interpretation; drafting and critical revision of article; and study supervision.

Study funding

K.O'.C.'s fellowship was funded by Euroimmun, AG.

Disclosure

K. O'Connor reports no disclosures; P. Waters received honoraria from Biogen, Retrogenix, Euroimmun, UBC, Merco, holds a patent for, and receives royalties from assays for the detection of antibodies to Igl1, Caspr2, Tag-1, and GABA_AR, received research support from Euroimmun, and L. Komorowski is an employee of Euroimmun; A. Zekeridou has a patent pending for PDE10A-IgG paraneoplastic autoimmunity; C-Y Guo and V. Mgbachi report no disclosures. C. Probst is employed by and holds stock or stock options in Euroimmun; S. Mindorf is employed by Euroimmun; B. Teegan reports no disclosures; J.M. Gelfand served on the scientific advisory board for NIA, served on the editorial board for *Neurology: Neuroimmunology & Neuroinflammation*, receives royalties from Dynamed Plus, consulted for Biogen, Alexion, received research support (to

University of California, San Francisco) from Genentech, MedDay, was PI of an institutional Clinician Training Award from NMSS, and received compensation for medical-legal consulting as an expert witness, and his spouse is an associate editor for JAMA, received honoraria from UpToDate, and consulted for Zosano, Eli Lilly, Biohaven, eNeura. M.D. Geschwind received speaker honoraria from Oakstone, served on the editorial board for *Dementia & Neuropsychologia*, and received publishing royalties from John C. Wiley, consulted for Advanced Medical, Best Doctors, Grand Rounds, Gerson Lehrman Group, Guidepoint Global, LCN Consulting Optio Biopharma, Market Plus, InThought, various Medical-legal consulting, Biohaven, Quest, received research support from Quest Diagnostics, NIH/NIA, Alliance Biosecure, Michael J. Homer Family Fund, CurePSP, Tau Consortium. V.A. Lennon receives royalties from RSR/Kronus for sale of aquaporin-4 antibody testing kits and for commercial aquaporin-4 autoantibody testing performed outside Mayo Clinic and received research support from MN Partnership for Biotechnology and Medical Genomics. S.J. Pittcock and Mayo Clinic have a financial interest in patents that relate to function AQP4/NMO-IgG assays and NMO as a cancer marker, and S.J. Pittcock has a patent pending for GFAP, Septin-5 and MAP1B autoantibodies as biomarkers of neurologic autoimmunity, consulted for Alexion, Medimmune (paid to Mayo Clinic), and received research support from Grifols, Medimmune, Alexion, AEA, NIH. A. McKeon has patents pending for Septin 5 and MAP1B as markers of neurologic autoimmunity and paraneoplastic disorders, consulted for Grifols, Medimmune, Euroimmun, Alexion (no personal compensation), and received research support from Medimmune, Euroimmun, Grifols, Alexion. Disclosures available: Neurology.org/NN.

Publication history

Received by *Neurology: Neuroimmunology & Neuroinflammation* December 28, 2018. Accepted in final form February 14, 2019.

References

1. Hachon Y, Wright S, Waters P, et al. Paediatric autoimmune encephalopathies: clinical features, laboratory investigations and outcomes in patients with or without antibodies to known central nervous system autoantigens. *J Neurol Neurosurg Psychiatry* 2013;84:748–755.
2. Petit-Pedrol M, Armangue T, Peng X, et al. Encephalitis with refractory seizures, status epilepticus, and antibodies to the GABA_A receptor: a case series, characterisation of the antigen, and analysis of the effects of antibodies. *Lancet Neurol* 2014;13: 276–286.
3. Spatola M, Petit-Pedrol M, Simabukuro MM, et al. Investigations in GABA_A receptor antibody-associated encephalitis. *Neurology* 2017;88:1012–1020.
4. Dalmau J, Lancaster E, Martinez-Hernandez E, Rosenfeld MR, Balice-Gordon R. Clinical experience and laboratory investigations in patients with anti-NMDAR encephalitis. *Lancet Neurol* 2011;10:63–74.
5. Zekeridou A, McKeon A, Lennon VA. Frequency of synaptic autoantibody accompaniments and neurological manifestations of thymoma. *JAMA Neurol* 2016;73: 853–859.
6. Simabukuro MM, Petit-Pedrol M, Castro LH, et al. GABA_A receptor and LGI1 antibody encephalitis in a patient with thymoma. *Neurol Neuroimmunol Neuroinflamm* 2015;2:e73. doi: 10.1212/NXI.0000000000000073.