

UCSF

UC San Francisco Previously Published Works

Title

Symptomatic amyloid-related imaging abnormalities in an APOE $\epsilon 4/\epsilon 4$ patient treated with aducanumab

Permalink

<https://escholarship.org/uc/item/1ch0m646>

Journal

Alzheimer's & Dementia Diagnosis Assessment & Disease Monitoring, 12(1)

ISSN

2352-8729

Authors

VandeVrede, Lawren
Gibbs, Daniel M
Koestler, Mary
et al.

Publication Date

2020

DOI

10.1002/dad2.12101

Peer reviewed

SHORT REPORT

Symptomatic amyloid-related imaging abnormalities in an APOE $\epsilon 4/\epsilon 4$ patient treated with aducanumab

Lawren Vandevrede¹ | Daniel M Gibbs¹ | Mary Koestler¹ | Renaud La Joie¹ | Peter A. Ljubenkov¹ | Karine Provost¹ | David Soleimani-Meigooni¹ | Amelia Strom¹ | Elena Tsoy¹ | Gil D. Rabinovici^{1,2} | Adam L. Boxer¹

¹ Memory and Aging Center, Department of Neurology, University of California San Francisco, San Francisco, California, USA

² Department of Radiology and Biomedical Imaging, University of California San Francisco, San Francisco, California, USA

Correspondence

Lawren Vandevrede, 675 Nelson Rising Lane, Suite 190, San Francisco, CA 94158 USA.
Email: Lawren.Vandevrede@ucsf.edu

Abstract

Introduction: Amyloid-related imaging abnormalities (ARIA) are a common, dose-dependent effect of amyloid-targeting antibodies, strongly associated with the apolipoprotein E (APOE) $\epsilon 4$ allele.

Methods: We describe the clinical course and management of a 66-year-old white male (APOE $\epsilon 4/\epsilon 4$) enrolled in an observational study that included amyloid and tau positron emission tomography (PET), who received aducanumab through the ENGAGE clinical trial.

Results: Acute symptoms included headache and encephalopathy, and magnetic resonance imaging revealed ARIA-E and ARIA-H. Malignant hypertension and epileptiform activity were treated with nifedipine and levetiracetam. Subsequent clinical/imaging worsening prompted a course of methylprednisolone. Symptoms and ARIA-E resolved over 6 months, while ARIA-H persisted. Quantitative analysis of interval amyloid PET showed reduced signal in pre-existing areas but increased signal posteriorly; while tau PET showed increased signal overall.

Discussion: In an APOE $\epsilon 4/\epsilon 4$ patient, ARIA symptoms were accompanied by malignant hypertension and epileptiform activity, and pulsed steroids reversed edema. Studies from larger cohorts may clarify the optimal treatment and pathophysiology of ARIA.

KEYWORDS

aducanumab, Alzheimer's disease, amyloid-related imaging abnormalities, apolipoprotein E, flor-taucipir, FTP, Pittsburgh compound B

1 | INTRODUCTION

Aducanumab, a monoclonal antibody that binds and clears amyloid beta ($A\beta$) aggregates from the brain, has been evaluated for treatment of mild cognitive impairment and dementia due to Alzheimer's disease (AD).¹ In early clinical trials, aducanumab reduced parenchymal $A\beta$ aggregates demonstrated on amyloid positron emission

tomography (PET), though amyloid-related imaging abnormalities (ARIA) were a dose-limiting side effect.^{2,3}

ARIA refers to imaging findings related to underlying vasogenic edema (ARIA-E) and intracerebral hemorrhage (ARIA-H), and the risk of ARIA is a class effect of antibodies against $A\beta$ aggregates.⁴⁻⁶ ARIA from aducanumab is dose dependent and increased incidence has been associated with the $\epsilon 4$ allele of apolipoprotein E (APOE) gene

This is an open access article under the terms of the [Creative Commons Attribution-NonCommercial-NoDerivs](https://creativecommons.org/licenses/by-nc-nd/4.0/) License, which permits use and distribution in any medium, provided the original work is properly cited, the use is non-commercial and no modifications or adaptations are made.

© 2020 The Authors. *Alzheimer's & Dementia: Diagnosis, Assessment & Disease Monitoring* published by Wiley Periodicals, LLC on behalf of Alzheimer's Association

(APOE ϵ 4), similar to prior trials of A β -targeted antibodies.⁴⁻⁸ In two Phase 3 clinical trials of aducanumab, some form of ARIA occurred in 40% of patients in the highest dose (10 mg/kg) treatment arm, and was symptomatic in 10%.¹

Despite identification of ARIA as a consequence of anti-amyloid treatments, few detailed reports exist on the clinical course and management of this phenomenon. Therefore, herein we report the clinical history, course, management, and imaging findings of an APOE ϵ 4/ ϵ 4 retired neurologist with confirmed brain amyloidosis, who developed severe symptomatic ARIA after treatment with aducanumab.

2 | METHODOLOGY

2.1 | Clinical and neuropsychological testing

At age 64 and 67, the patient, who is White and male, underwent neurological assessment and neuropsychological testing as part of an observational study of early-onset AD at the University of California, San Francisco (UCSF), described further in eMethods in supporting information.

2.2 | Neuroimaging

Magnetic resonance imaging (MRI) was obtained at UCSF, and ¹¹C-Pittsburgh Compound B (¹¹C-PIB) and ¹⁸F-flortaucipir (¹⁸F-FTP) PET were obtained at Lawrence Berkeley National Laboratory. MRIs were obtained through the Phase 3 Study of Aducanumab in Early Alzheimer's Disease (ENGAGE, NCT02477800). Image acquisition, processing, and reference region selection are described in the eMethods.

2.3 | Human subjects approval

Written consent for participation in research and release of this information was obtained from the patient. The UCSF, University of California Berkeley, and Lawrence Berkeley National Laboratory institutional review boards (IRB) approved the PET studies. IRB approval for ENGAGE was obtained at UCSF.

3 | RESULTS

3.1 | Clinical history

The patient has previously detailed his personal experience with AD, including his unique perspective as a neurologist.⁹ Briefly, he had mild olfactory impairment at age 55, which was followed by mild memory symptoms starting at age 61. At age 62, he voluntarily retired from neurology and underwent neuropsychological testing that revealed subtle deficits in delayed recall and generative tasks of fluency. He

RESEARCH IN CONTEXT

Systematic review: The authors reviewed the literature using traditional methods. Amyloid-related imaging abnormalities (ARIA) are a known side effect of amyloid aggregate-targeting antibodies and associated with apolipoprotein E (APOE) ϵ 4, but few detailed reports are available on clinical symptoms, course, and management.

Interpretation: We report a severe case of ARIA that occurred after treatment with aducanumab through the ENGAGE clinical trial, wherein typical symptoms associated with ARIA (eg, headache, encephalopathy, focal neurologic deficits) were accompanied by malignant hypertension and epileptiform activity, which ultimately abated after treatment with methylprednisolone, nicardipine, and levetiracetam. Cognitive impairment and edema resolved in parallel over 6 months without sequelae.

Future directions: Further descriptions of typical and atypical ARIA symptoms and subsequent course and management from larger clinical cohorts are needed to guide diagnosis of this novel clinical entity and determine an appropriate approach to treatment. Detailed studies relating imaging findings to symptoms may elucidate the pathophysiology of ARIA.

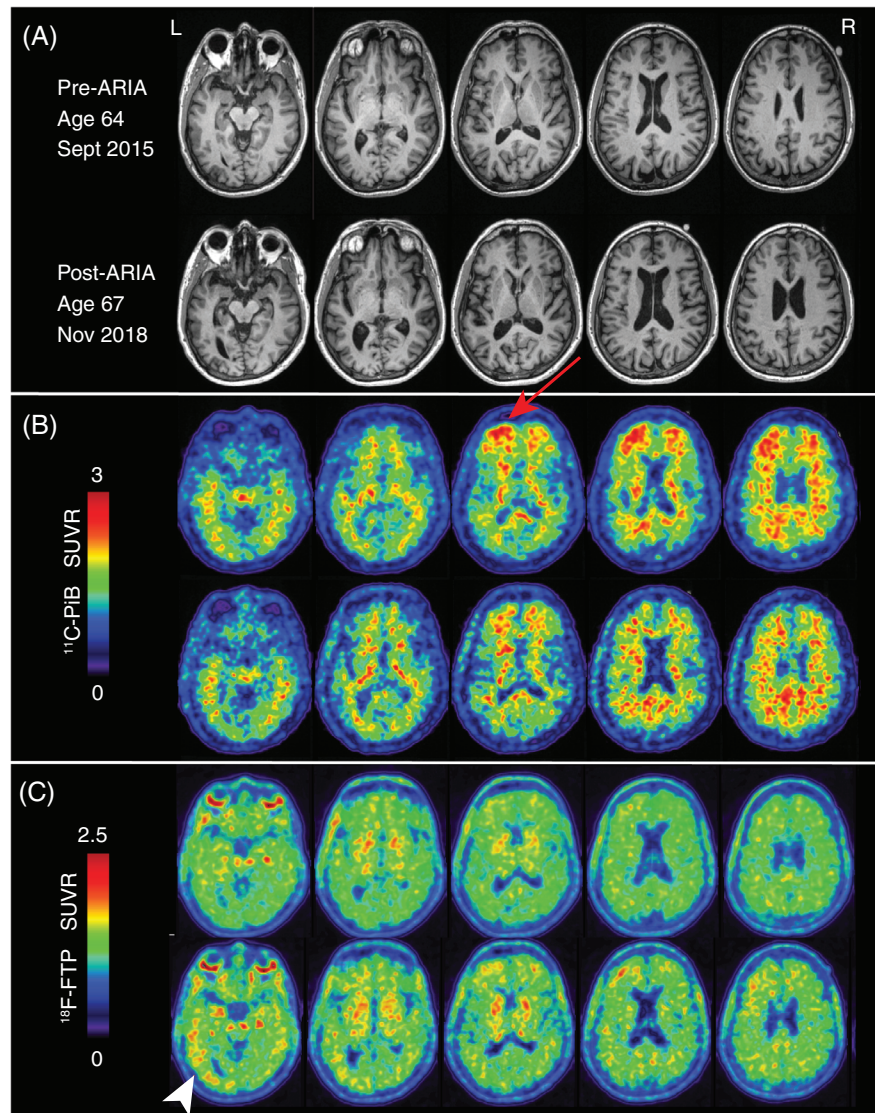
was diagnosed with mild cognitive impairment (Table S1 in supporting information).

In 2015, at age 64, he enrolled in an observational study at UCSF that revealed APOE ϵ 4/ ϵ 4 genotype, with MRI demonstrating minimal parietal and mesial temporal atrophy (Figure 1A). ¹¹C-PiB PET confirmed brain amyloidosis with increased signal predominantly in bilateral frontal lobes and precuneus (Figure 1B). ¹⁸F-FTP PET had off-target binding in the white matter, basal ganglia, and choroid plexus, with borderline cortical signal in the left temporal lobe (Figure 1C).

3.2 | ENGAGE trial and ARIA

In 2016, he enrolled in the ENGAGE trial for aducanumab, and he was randomized to the placebo arm for the 78 weeks of the trial. Afterward, he entered the open-label extension and began uptitration toward a target dose of 6 mg/kg. He received two monthly doses of aducanumab at 1 mg/kg and two doses at 3 mg/kg, after which time, he developed sudden-onset explosive headaches and fluctuating confusion, and he self-diagnosed alexia without agraphia. He presented to the hospital, where his systolic blood pressure was 206/116 on admission to the intensive care unit (ICU), where he received intravenous nicardipine. After stabilization of his blood pressure and resolution of his encephalopathy, he was discharged to home on oral antihypertensives.

FIGURE 1 Neuroimaging pre- and post-aducanumab/amyloid-related imaging abnormalities. A, T1 sequence magnetic resonance imaging obtained at age 64 in 2015 (top row), and age 67 in 2018 (bottom row). B, ^{11}C -Pittsburgh Compound B (^{11}C -PiB) positron emission tomography (PET) from 2015 (top row) and 2018 (bottom row), red arrow indicates area of focal increased uptake in the left frontal lobe, reduced after interval treatment with aducanumab. C, ^{18}F -florbetapir (^{18}F -FTP) PET from 2015 (top row) and 2018 (bottom row); white arrowhead indicates region of increased radiotracer signal in left inferior temporal lobe. D, Quantitative comparison of ^{11}C -PiB (top row) and ^{18}F -FTP W-score maps (bottom row), with positive voxels relative to healthy controls



On MRI, T2 fluid-attenuated inversion recovery (FLAIR) sequences revealed focal, confluent hyperintensities consistent with ARIA-E (Figure 2A), and susceptibility weighted imaging (SWI) showed micro-hemorrhages consistent with ARIA-H (Figure 2B), both maximal in the left frontal and temporoparietal lobes. In addition, contrast sequences revealed adjacent nodular enhancement consistent with blood brain barrier (BBB) disruption (Figure 2C). Notably, these areas had high radiotracer uptake on his prior ^{11}C -PiB PET from 2015.

Approximately 1 month later, his alexia without agrapha worsened, and repeat MRI showed increasing FLAIR hyperintensities in the left inferior temporal lobe, corresponding to the focal neurologic symptoms (Figure 2E). Electroencephalogram (EEG) revealed left temporal sharp waves (Figure 2D), and he was started on levetiracetam and treated with intravenous methylprednisolone 1000 mg for 5 days without oral taper. Headache and alexia resolved, and follow-up MRI showed dramatic improvement in ARIA-E. Montreal Cognitive Assessment (MoCA) was 22/30 at ARIA onset, and improved to 30/30 over 6 months (Figure 2E).

3.3 | Post-aducanumab/ARIA assessment

In 2018, almost 1 year after his episode of ARIA, he returned to UCSF for repeat evaluation. He remained high-functioning, though he noticed worsening lexical memory and new facial recognition difficulties. Repeat neuropsychological testing showed a decline in verbal/visual memory with stable language and visuospatial skills (Table S1). Compared to his prior MRI scan from 2015, he showed progression of atrophy most notable in the left posterior temporoparietal region (Figure 1A). ^{11}C -PiB PET showed significant decrease in cortical radiotracer retention in the left frontal lobe compared to 2015, with increased signal in the precuneus (Figure 1B). ^{18}F -FTP PET showed a mild increase in the left medial and lateral temporal lobes, right temporal lobe, bifrontal cortex, and precuneus (Figure 1C). Quantitative analysis of ^{11}C -PiB positivity at each time point compared to normal controls showed decreased total positive voxels, predominantly in left frontal lobe; while ^{18}F -FTP showed increased positivity, though overall changes were mild, reflecting the early stage of disease (Figure 1D).

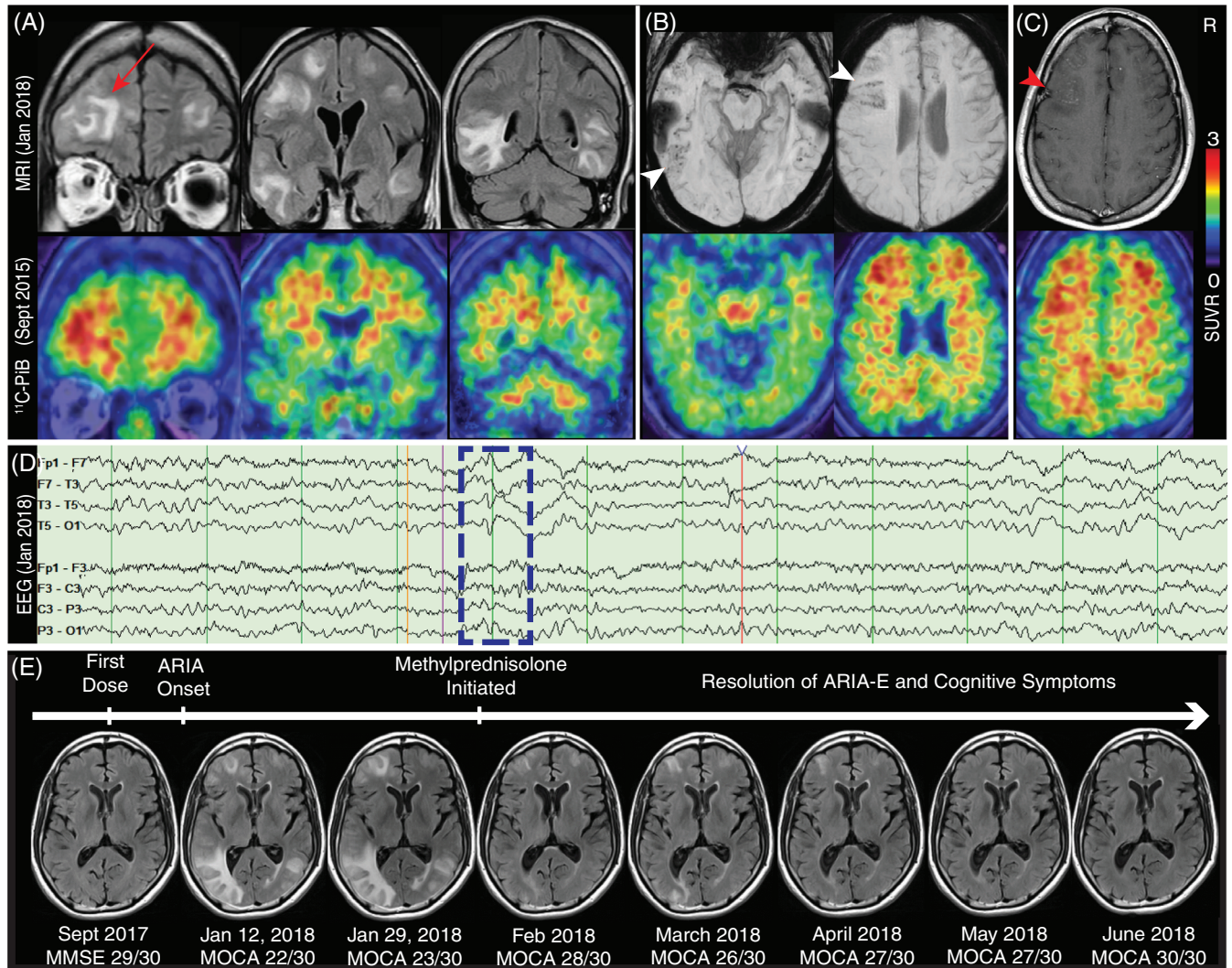


FIGURE 2 Amyloid-related imaging abnormalities (ARIA) after treatment with aducanumab. A, T2 fluid-attenuated inversion recovery (FLAIR) sequences (top) demonstrating ARIA-E after treatment with aducanumab, compared to 2015 ^{11}C -Pittsburgh Compound B (^{11}C -PiB) positron emission tomography (PET; bottom); red arrow highlights edema in area of high amyloid signal in left frontal pole. B, Susceptibility weighted imaging sequence demonstrating ARIA-H (top), compared to 2015 ^{11}C -PiB PET (bottom); white arrowheads indicate microhemorrhages in left frontal and temporal lobes. C, Post-contrast T1 sequence (top), compared to 2015 ^{11}C -PiB PET (bottom); red arrowhead indicates nodular enhancement in left frontal lobe. D, Electroencephalogram with left temporal sharps and after-going slow waves (dotted blue box), maximal electronegativity at T3 with field to T1, F7, T5, and O1. E, Sequential T2 FLAIR at the level of maximal edema, with subsequent resolution after treatment with intravenous steroids, with cognitive assessment showing resolution in parallel with ARIA-E

4 | DISCUSSION

Aducanumab, an amyloid-targeted antibody, appears to be highly effective at clearing brain amyloidosis, but this immune-mediated clearance has been associated with a risk of vasogenic edema and intracerebral hemorrhage, collectively known as ARIA, which is more common in patients with an APOE $\epsilon 4$ allele. In our patient with two APOE $\epsilon 4$ alleles, symptoms reported as typical of ARIA (headache, encephalopathy, and focal neurologic symptoms referable to areas of edema) were accompanied by severe atypical features of malignant hypertension and epileptiform activity, requiring ICU admission. After his discharge, symptom recurrence and worsening of ARIA prompted

treatment with methylprednisolone, which led to an effective resolution of symptoms and ARIA-E over the next 6 months.

In interval scans from an observational study in 2015 and 2018, treatment with aducanumab resulted in decreased global ^{11}C -PiB signal, with a significant decrease in the left frontal lobe, which is notable given the long imaging interval and that only four doses of aducanumab were received. On his 2018 scan, ^{11}C -PiB signal was increased posteriorly, particularly in the precuneus, which suggests either interval amyloid accumulation or renewed deposition after treatment cessation. On ^{18}F -FTP PET, minimal signal was present before aducanumab, but an increased overall signal was seen, predominantly in the left temporal lobe, consistent with atrophy and reported worsening symptoms.

We speculate that sufficient aducanumab exposure may not have been achieved to reduce tau PET signal.

Interestingly, MRI findings similar to ARIA-E are seen in both posterior reversible encephalopathy syndrome (PRES) and inflammatory reactions to cerebral amyloid angiopathy (iCAA), and there is significant overlap in clinical syndromes, including resolution of imaging changes in tandem with symptoms after treatment. In PRES, endothelial injury leads to breakdown of the BBB and is often associated with malignant hypertension,¹⁰ while in iCAA endothelial injury is caused by antibody targeting of vascular A β or increased mobilization of parenchymal A β to perivascular clearance pathways, suggesting a possible shared pathophysiology with ARIA-E.¹¹ Given the immune-mediated hypothesis of vascular injury in ARIA, we suspect the malignant hypertension in our patient is likely reactive to primary endothelial dysfunction via loss of auto-regulation.

Going forward, if anti-amyloid antibodies become part of future treatment regimens for AD, knowledge of symptoms related to ARIA and an approach to management will be critical for treating clinicians. Risk stratification with APOE ϵ 4 genotyping may help guide treatment decisions. Further studies are needed from larger clinical cohorts to determine the optimal approach to monitoring and treatment. Additional studies including co-localization of ARIA to amyloid and tau on PET and CAA on MRI may clarify the relationship between these entities and provide insights into the pathophysiology of ARIA and related clinical syndromes.

ACKNOWLEDGMENTS

We would like to thank William Jagust, MD, and the Lawrence Berkeley National Laboratory for the use of PET. This work was funded by the National Institute on Aging at the National Institute of Health through P50AG023501 (UCSF Alzheimer's Disease Research Center), 5T32AG023481 (L.V.), R01AG045611 (G.D.R.), 5R01AG038791-09 (A.L.B.), and 1U19AG063911-01 (A.L.B.); the Alzheimer's Association Research Fellowship 16-443577 (R.L.J.); the Alzheimer's Association Clinician Scientist Fellowship 19-617663 (D.N.S.M).

CONFLICTS OF INTEREST

Adam L. Boxer has received research support from NIH, the Tau Research Consortium, the Association for Frontotemporal Degeneration, Bluefield Project to Cure Frontotemporal Dementia, Corticobasal Degeneration Solutions, the Alzheimer's Drug Discovery Foundation, and the Alzheimer's Association. He has served as a consultant for Aeton, Abbvie, Alektor, Amgen, Arkuda, Arvinas, Asceneuron, Ionis, Lundbeck, Novartis, Passage BIO, Samumed, Third Rock, Toyama, and UCB, and received research support from Avid, Biogen, BMS, C2N, Cortice, Eli Lilly, Forum, Genentech, Janssen, Novartis, Pfizer, Roche, and TauRx. Other authors report no conflict of interest. Biogen, Incorporated, funded the ENGAGE trial, and Avid Radiopharmaceuticals enabled use of the precursor for ¹⁸F-Flortaucipir, but neither Biogen

nor Avid provided direct funding to the authors and were not involved in data analysis or interpretation. Biogen and Avid were allowed to review and comment on the manuscript prior to submission.

REFERENCES

1. Haeberlein SB, von Hehn C, Tian Y, et al. EMERGE and ENGAGE Topline Results: Two Phase 3 Studies to Evaluate Aducanumab in Patients With Early Alzheimer's Disease. 2019, CTAD 2019: San Diego, CA, USA.
2. Ferrero J, Williams L, Stella H, et al. First-in-human, double-blind, placebo-controlled, single-dose escalation study of aducanumab (BIIB037) in mild-to-moderate Alzheimer's disease. *Alzheimers Dement (N Y)*. 2016;2(3):169-176.
3. Sevigny J, Chiao P, Bussiere T, et al. The antibody aducanumab reduces Abeta plaques in Alzheimer's disease. *Nature*. 2016;537(7618):50-56.
4. Sperling RA, Jack CR, Jr, Black SE, et al. Amyloid-related imaging abnormalities in amyloid-modifying therapeutic trials: recommendations from the Alzheimer's Association Research Roundtable Workgroup. *Alzheimers Dement*. 2011;7(4):367-385.
5. Penninkilampi R, Brothers HM, Eslick GD. Safety and efficacy of anti-amyloid-beta immunotherapy in Alzheimer's Disease: a systematic review and meta-analysis. *J Neuroimmune Pharmacol*. 2017;12(1):194-203.
6. Sperling R, Salloway S, Brooks DJ, et al. Amyloid-related imaging abnormalities in patients with Alzheimer's disease treated with bapineuzumab: a retrospective analysis. *Lancet Neurol*. 2012;11(3):241-249.
7. Haeberlein SB, Gheuens S, Chen T, et al. Aducanumab 36-month data from PRIME: a randomized, double-blind, placebo-controlled Phase 1b study in patients with prodromal or mild Alzheimer's disease (S2.004). *Neurology*. 2018;90(15 Supplement):S2.004.
8. Swanson CJ, Zhang Y, Dhadda S, et al. Treatment of early AD Subjects with BAN2401, an anti- A β protofibril monoclonal antibody, significantly clears amyloid plaque and reduces clinical decline. *Alzheimer's & Dementia: The Journal of the Alzheimer's Association*. 2018;14(7):P1668.
9. Gibbs DM. Early awareness of Alzheimer disease: a neurologist's personal perspective. *JAMA Neurol*. 2019;76(3):249.
10. Fugate JE, Rabinstein AA. Posterior reversible encephalopathy syndrome: clinical and radiological manifestations, pathophysiology, and outstanding questions. *Lancet Neurol*. 2015;14(9):914-925.
11. Greenberg SM, Bacskai BJ, Hernandez-Guillamon M, Pruzin J, Sperling R, van Veluw SJ. Cerebral amyloid angiopathy and Alzheimer disease - one peptide, two pathways. *Nat Rev Neurol*. 2020;16(1):30-42.

SUPPORTING INFORMATION

Additional supporting information may be found online in the Supporting Information section at the end of the article.

How to cite this article: Vandevrede L, Gibbs DM, Koestler M, et al. Symptomatic amyloid-related imaging abnormalities in an APOE ϵ 4/ ϵ 4 patient treated with aducanumab. *Alzheimer's Dement*. 2020;12:e12101.

<https://doi.org/10.1002/dad2.12101>