

# UCLA

## UCLA Previously Published Works

### Title

Correction: Retinal nerve fiber layer thickness predicts CSF amyloid/tau before cognitive decline.

### Permalink

<https://escholarship.org/uc/item/1fv6v2xb>

### Journal

PLoS One, 15(7)

### Authors

Asanad, Samuel  
Fantini, Michele  
Sultan, William  
[et al.](#)

### Publication Date

2020

### DOI

10.1371/journal.pone.0236379

### Copyright Information

This work is made available under the terms of a Creative Commons Attribution License, available at <https://creativecommons.org/licenses/by/4.0/>

Peer reviewed

## CORRECTION

# Correction: Retinal nerve fiber layer thickness predicts CSF amyloid/tau before cognitive decline

Samuel Asanad, Michele Fantini, William Sultan, Marco Nassisi, Christian M. Felix, Jessica Wu, Rustum Karanjia, Fred N. Ross-Cisneros, Abhay P. Sagare, Berislav V. Zlokovic, Helena C. Chui, Janice M. Pogoda, Xianghong Arakaki, Alfred N. Fonteh, Alfredo A. Sadun, Michael G. Harrington


The fifteenth author's name is spelled incorrectly. The correct name is: Alfredo A. Sadun.

The following information is missing from the Funding statement: This study was also supported by Research to Prevent Blindness Inc. (unrestricted grant).

In the Discussion, there is an error in the third sentence of the second paragraph. The correct sentence is: Notably, this observed relationship between CSF protein levels and the retina is similar to that observed in the brain, where CSF A $\beta$  is inversely correlated with A $\beta$  load and neuropathology, while CSF Tau is directly correlated.

The figure legends in [S1 Fig](#) are incorrect. Please view the correct [S1 Fig](#) below.

[Fig 1](#) is incorrect. The authors have provided a corrected version here.

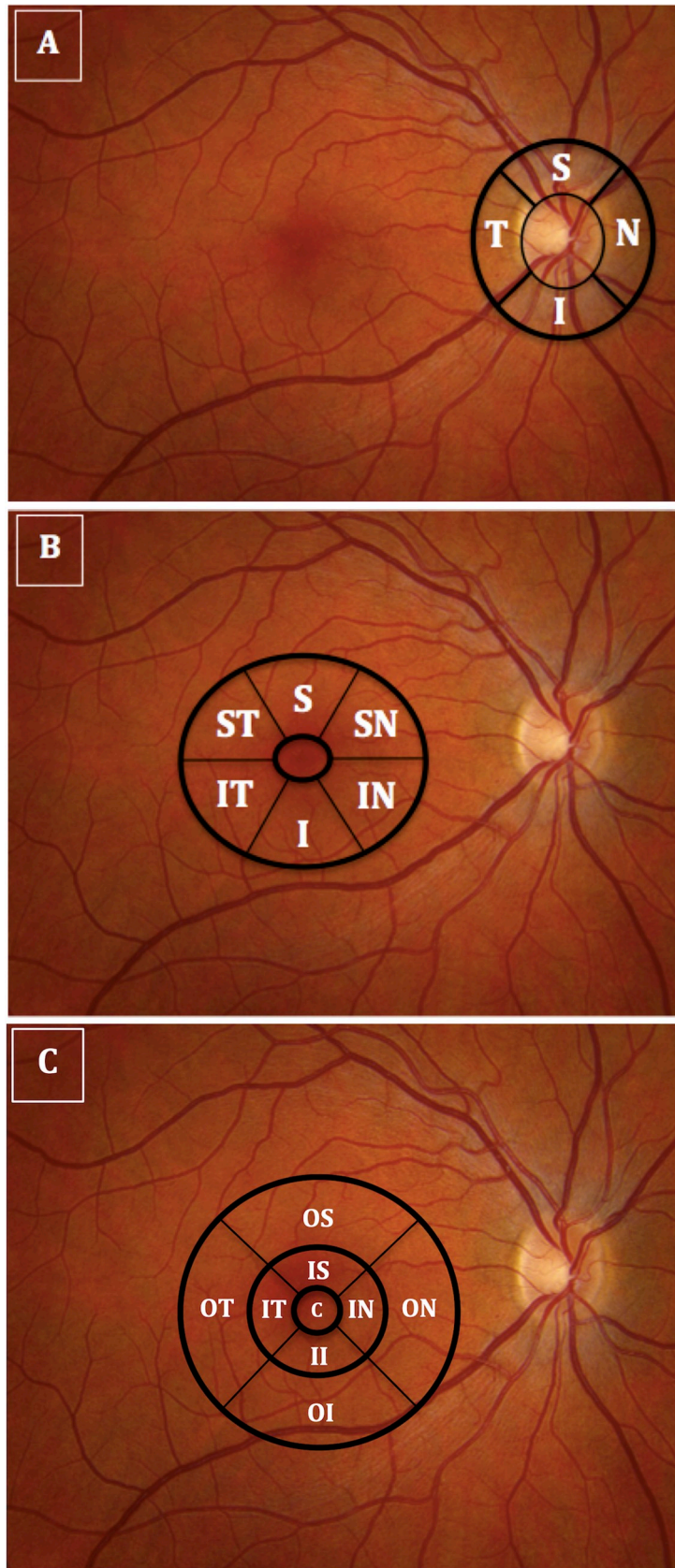


## OPEN ACCESS

**Citation:** Asanad S, Fantini M, Sultan W, Nassisi M, Felix CM, Wu J, et al. (2020) Correction: Retinal nerve fiber layer thickness predicts CSF amyloid/tau before cognitive decline. PLoS ONE 15(7): e0236379. <https://doi.org/10.1371/journal.pone.0236379>

**Published:** July 14, 2020

**Copyright:** © 2020 Asanad et al. This is an open access article distributed under the terms of the [Creative Commons Attribution License](#), which permits unrestricted use, distribution, and reproduction in any medium, provided the original author and source are credited.



**Fig 1. Illustrates optical coherence tomography imaging of the peripapillary and macular areas.** (A) The thicknesses of the 4 retinal nerve fiber layer quadrants (temporal, superior, nasal, inferior); (B) ganglion cell-inner plexiform layer sectors (superior-temporal, superior, superior-nasal, inferior-nasal, inferior, inferior-temporal); (C) macular full-thickness sectors (center, inner-superior, outer-superior, inner-inferior, outer-inferior, inner-temporal, outer-temporal, inner-nasal, outer-nasal) were measured using peripapillary and macular circular scans centered on the disc and on the fovea, respectively).

<https://doi.org/10.1371/journal.pone.0236379.g001>

## Supporting information

**S1 Fig. AD OCT scatter plots for OD: Series 1 = CH-PAT; Series 2 = CH-NAT.**  
(PDF)

## Reference

1. Asanad S, Fantini M, Sultan W, Nassisi M, Felix CM, Wu J, et al. (2020) Retinal nerve fiber layer thickness predicts CSF amyloid/tau before cognitive decline. *PLoS ONE* 15(5): e0232785. <https://doi.org/10.1371/journal.pone.0232785> PMID: 32469871