

UC Berkeley

UC Berkeley Previously Published Works

Title

Rates of Amyloid Imaging Positivity in Patients With Primary Progressive Aphasia

Permalink

<https://escholarship.org/uc/item/1hm128x5>

Journal

JAMA Neurology, 75(3)

ISSN

2168-6149

Authors

Santos-Santos, Miguel A
Rabinovici, Gil D
Iaccarino, Leonardo
[et al.](#)

Publication Date

2018-03-01

DOI

10.1001/jamaneurol.2017.4309

Peer reviewed

Rates of Amyloid Imaging Positivity in Patients With Primary Progressive Aphasia

Miguel A. Santos-Santos, MD; Gil D. Rabinovici, MD; Leonardo Iaccarino, MSc; Nagehan Ayakta, MSc; Gautam Tammewar, MSc; Iryna Lobach, PhD; Maya L. Henry, PhD; Isabel Hubbard, PhD; Maria Luisa Mandelli, PhD; Edoardo Spinelli, MD; Zachary A. Miller, MD; Peter S. Pressman, MD; James P. O'Neil, PhD; Pia Ghosh, MSc; Andreas Lazaris, MSc; Marita Meyer, MSc; Christa Watson, PhD; Soo Jin Yoon, MD; Howard J. Rosen, MD; Lea Grinberg, MD, PhD; William W. Seeley, MD; Bruce L. Miller, MD; William J. Jagust, MD; Maria Luisa Gorno-Tempini, MD, PhD

 Supplemental content

IMPORTANCE The ability to predict the pathology underlying different neurodegenerative syndromes is of critical importance owing to the advent of molecule-specific therapies.

OBJECTIVE To determine the rates of positron emission tomography (PET) amyloid positivity in the main clinical variants of primary progressive aphasia (PPA).

DESIGN, SETTING, AND PARTICIPANTS This prospective clinical-pathologic case series was conducted at a tertiary research clinic specialized in cognitive disorders. Patients were evaluated as part of a prospective, longitudinal research study between January 2002 and December 2015. Inclusion criteria included clinical diagnosis of PPA; availability of complete speech, language, and cognitive testing; magnetic resonance imaging performed within 6 months of the cognitive evaluation; and PET carbon 11-labeled Pittsburgh Compound-B or florbetapir F 18 brain scan results. Of 109 patients referred for evaluation of language symptoms who underwent amyloid brain imaging, 3 were excluded because of incomplete language evaluations, 5 for absence of significant aphasia, and 12 for presenting with significant initial symptoms outside of the language domain, leaving a cohort of 89 patients with PPA.

MAIN OUTCOMES AND MEASURES Clinical, cognitive, neuroimaging, and pathology results.

RESULTS Twenty-eight cases were classified as imaging-supported semantic variant PPA (11 women [39.3%]; mean [SD] age, 64 [7] years), 31 nonfluent/agrammatic variant PPA (22 women [71.0%]; mean [SD] age, 68 [7] years), 26 logopenic variant PPA (17 women [65.4%]; mean [SD] age, 63 [8] years), and 4 mixed PPA cases. Twenty-four of 28 patients with semantic variant PPA (86%) and 28 of 31 patients with nonfluent/agrammatic variant PPA (90%) had negative amyloid PET scan results, while 25 of 26 patients with logopenic variant PPA (96%) and 3 of 4 mixed PPA cases (75%) had positive scan results. The amyloid positive semantic variant PPA and nonfluent/agrammatic variant PPA cases with available autopsy data (2 of 4 and 2 of 3, respectively) all had a primary frontotemporal lobar degeneration and secondary Alzheimer disease pathologic diagnoses, whereas autopsy of 2 patients with amyloid PET-positive logopenic variant PPA confirmed Alzheimer disease. One mixed PPA patient with a negative amyloid PET scan had Pick disease at autopsy.

CONCLUSIONS AND RELEVANCE Primary progressive aphasia variant diagnosis according to the current classification scheme is associated with Alzheimer disease biomarker status, with the logopenic variant being associated with carbon 11-labeled Pittsburgh Compound-B positivity in more than 95% of cases. Furthermore, in the presence of a clinical syndrome highly predictive of frontotemporal lobar degeneration pathology, biomarker positivity for Alzheimer disease may be associated more with mixed pathology rather than primary Alzheimer disease.

JAMA Neurol. 2018;75(3):342-352. doi:10.1001/jamaneurol.2017.4309
Published online January 8, 2018.

Author Affiliations: Author affiliations are listed at the end of this article.

Corresponding Author: Miguel A. Santos-Santos, MD, 675 Nelson Rising Ln, Mission Bay Campus, San Francisco, CA 94158 (miguel.angel.santos.santos@gmail.com).

P primary progressive aphasia (PPA) is a clinically and pathologically heterogeneous condition in which language impairment is the predominant cause of functional impairment during the initial phases of disease.¹ In 2011, an international consortium of investigators established a classification scheme for the 3 most common variants: the semantic (svPPA), nonfluent/agrammatic (nfvPPA), and logopenic (lvPPA) variants of PPA.² Classification may occur at 1 of 3 levels: clinical, imaging-supported, or definite pathologic diagnosis. These guidelines reflected the accumulated knowledge of the patterns of speech and language dysfunction, brain atrophy, and underlying pathology typically associated with each clinical variant and represent a collective effort to increase comparability between studies and eventually improve the ability to predict the underlying pathology.

The ability to detect fibrillar amyloid- β plaque depositions using carbon 11-labeled Pittsburgh Compound-B (¹¹C-PIB)³ or fluorinated amyloid positron emission tomography (PET) tracers⁴ allows in-vivo identification of cases due to putative Alzheimer disease. A few studies have reported amyloid imaging and pathologic results in PPA.⁵⁻⁸ Taken together, these reports suggest that svPPA and nfvPPA are generally caused by frontotemporal lobar degeneration (FTLD),⁹ mainly tau (including Pick disease, corticobasal degeneration, progressive supranuclear palsy) and TAR-DNA binding protein 43 (TDP-43) proteinopathies, while lvPPA is mostly caused by Alzheimer disease. However, the prevalence of FTLD and Alzheimer disease pathologic findings or biomarkers in each variant has been inconsistent across the literature (svPPA, 0%-16% Alzheimer disease; nfvPPA, 13%-31%; lvPPA, 54%-92%).^{5-8,10-14} This may be caused by the fact that most of these studies are retrospective and may not have had adequate records or appropriate test batteries to apply the current criteria. Therefore, prospective validation with biomarker and autopsy data remains scarce and highly necessary.

We studied amyloid brain imaging in a large cohort of patients with prospectively diagnosed PPA to test the hypothesis that classification according to the current criteria in well-characterized patients with language and magnetic resonance imaging (MRI) evaluations will result in groups with largely homogeneous biomarker features. A second objective was to analyze amyloid "discordant" (amyloid positive svPPA and nfvPPA and amyloid negative lvPPA) and mixed cases (PPAm) in search of characteristics that may aid in their identification.

Methods

Participant Selection and Characterization

We recruited participants that presented prospectively to the University of California San Francisco (UCSF) Memory and Aging Center between January 2002 and December 2015 as part of an ongoing PPA research project. We included patients that met the following criteria: clinical diagnosis of PPA; availability of complete speech, language, and cognitive test results; MRI performed within 6 months of the cognitive evaluation; and PET ¹¹C-PiB or florbetapir F 18 brain scan results. As part of the research evaluation, all participants underwent a his-

Key Points

Question What are the rates and significance of amyloid imaging positivity in a large cohort of patients with the main variants of primary progressive aphasia (PPA) prospectively diagnosed according to 2011 consensus criteria?

Findings In this longitudinal case-series study, 24 of 28 patients with semantic variant PPA (86%) and 28 of 31 patients with nonfluent/agrammatic variant PPA (90%) had negative amyloid positron emission tomography scans, whereas 25 of 26 patients with logopenic variant (96%) and 3 of 4 patients with PPA with mixed phenotype (75%) had positive scans. The amyloid positive semantic PPA and nonfluent/agrammatic PPA cases with available autopsy data (2 of 4 and 2 of 3, respectively) all had a primary frontotemporal lobar degeneration and secondary Alzheimer disease pathologic diagnoses.

Meaning Primary progressive aphasia variant diagnosis according to the current classification scheme is highly predictive of Alzheimer disease biomarker status; biomarker positivity for Alzheimer disease may be more predictive of mixed pathology rather than primary Alzheimer disease.

tory and physical examination by a neurologist, a structured caregiver interview by a nurse, a battery of neuropsychological tests, multimodal brain imaging scans, as well as an extensive battery of language tests. After initial evaluation, a syndromic diagnosis was reached by consensus between the multidisciplinary evaluation team. Initial diagnosis was based on clinical judgment after considering all available neurologic, cognitive, language, and structural MRI data. Amyloid imaging results were not available for any participant at the time of initial diagnosis. Since 2002, the UCSF Memory and Aging Center PPA research project has classified patients with PPA into svPPA, nfvPPA, and lvPPA using the same core clinical evaluation presented in this article. The features used for classification have remained largely analogous since they were first described in 2004¹⁵; however, they have been refined and operationalized by senior investigators in the field as described in 2008 and 2011.^{2,16} The tripartite framework of the classification system and the nature of the delineated patient groups have not changed during the evolution of the criteria (see eAppendix 1 in the [Supplement](#)). Furthermore, each case that presented before 2011 was reviewed retrospectively to determine if their diagnosis would change with application of current criteria, and none warranted change. We report the prospective PPA clinical variant diagnoses made by consensus at presentation between 2002 and 2015. When it was not possible to identify a predominant area of language impairment or more than 1 area was impaired (eg, motor speech, repetition difficulties), a diagnosis of PPAm was made.

One hundred and nine patients were referred to the UCSF Memory and Aging Center for evaluation of language symptoms and underwent amyloid imaging between 2002 and 2015. Of these, 3 patients were excluded because of inability to complete the language evaluation owing to advanced severity of disease, 5 for absence of significant aphasia, and 12 for presenting with significant initial symptoms outside of the language domain and consequently not meeting root PPA criteria (eTable in the [Supplement](#)). This left a cohort of 89 patients

with PPA (28 svPPA [31.5%], 31 nfvPPA [34.8%], and 26 lvPPA [29.2%] with 4 PPAm [4.5%]).

We recruited healthy control individuals from the San Francisco Aging Cohort Study (matched for age, sex, and scanner type) for the cognitive (n = 10; mean [SD] age, 69 [8] years; 7 women [70%]) and MRI (n = 84; mean [SD] age, 64 [8] years; 50 women [60%]) contrasts with patients. All control individuals had a Clinical Dementia Rating Scale Sum of Boxes score of 0, a normal neurologic examination, and no cognitive complaints. All participants underwent written informed consent and the study was approved by the UCSF, University of California Berkeley, and Lawrence Berkeley National Laboratory human research committees.

Cognitive Tests

All patients received the UCSF neuropsychological battery¹⁷ and UCSF speech and language battery (Table 1), which have been described extensively in previous publications.^{18,19} Briefly, speech and syntactic production were evaluated using the spontaneous speech section from the Western Aphasia Battery and a writing sample, motor speech was evaluated using the Motor Speech Evaluation (MSE),²⁰ single word comprehension was evaluated with items of the Peabody Picture Vocabulary Test-revised,²¹ repetition by the Western Aphasia Battery repetition subtest, and syntactic comprehension abilities were tested using the Sequential Command subtest of the Western Aphasia Battery and by 1 of 2 experimental syntax comprehension tests that systemically vary sentence length and syntactic complexity to take into account the effect of verbal working memory load on syntactic comprehension (selected subtests of the Curtiss-Yamada Comprehensive Language Evaluation-Receptive²² or the UCSF Grammar Comprehension Test²³). The Curtiss-Yamada Comprehensive Language Evaluation-Receptive text was administered until 2010; the score on the 2 latter tests are summarized into 1 percentage correct syntax comprehension score in Table 1.

Structural Magnetic Resonance Imaging

All patients and control individuals underwent whole-brain structural MRI using a 1.5T (Siemens Healthcare),^{15,24} 3T (Siemens Healthcare),²⁵ or 4T (Bruker Corporation and Siemens Healthcare)²⁶ scanner as previously described. We used voxel-based morphometry to study gray-matter atrophy patterns of svPPA (n = 24), nfvPPA (n = 28), and lvPPA (n = 25) groups (only including cases with typical amyloid imaging status) as well as each individual case with discordant amyloid imaging status and each PPAm case (eAppendix 2 in the Supplement).

Positron Emission Tomography

Carbon 11-labeled Pittsburgh Compound-B (n = 99) and florbetapir F 18 (n = 10) PET were performed at Lawrence Berkeley National Laboratory as previously described.²⁷ Native space standardized uptake value ratios (SUVRs) were created for ¹¹C-PIB scans only by normalizing mean images (at 50- to 70-minutes postinjection) by mean activity in cerebellum gray matter. Visual reads of native space ¹¹C-PIB or florbetapir F 18 SUVR images were performed by experienced investigators blinded to clinical data (G.D.R., H.J.R., or W.J.J.) using published criteria.^{28,29} Visual

inspection based on these criteria has been validated previously as a reproducible and reliable estimate of increased tracer uptake when compared with quantitative analysis.^{28,30}

Neuropathology

All brain autopsies were performed by the UCSF Neurodegenerative Disease Brain Bank. Pathologic assessments were performed using institution-specific protocols²⁷ and included tissue sampling in regions relevant to the differential diagnosis of dementia based on published consensus criteria (eAppendix 3 in the Supplement).^{9,31}

Statistical Analysis of Clinical and Cognitive Data

Demographic and cognitive data were compared between PPA variants using 1-way analysis of variance followed by post hoc comparisons of continuous variables with Bonferroni adjustments. χ^2 test was used for dichotomous variables. To identify factors that may help identify PPA cases with discordant amyloid imaging within each PPA variant, we converted the raw cognitive test scores of amyloid discordant PPA cases into z scores with respect to the mean score of the group with typical amyloid imaging status. To highlight the pattern of impaired and relatively preserved cognitive functions in patients with PPAm, we calculated z scores with respect to the healthy control group.

Results

Demographic and Genetic Data

Comparison of demographic characteristics (Table 1) between variants revealed significantly older age at symptom onset in patients with nfvPPA than patients with svPPA or lvPPA. A significantly higher proportion of patients with lvPPA had at least 1 apolipoprotein E ϵ 4 allele (11 of 26 [44%]) compared with patients with nfvPPA (3 of 31 [11%]). No mutations of microtubule-associated protein tau (0 of 80), TDP-43 (0 of 74), granulin (0 of 84), or chromosome 9 open reading frame 72 (0 of 78) were found despite testing of most patients.

Cognitive and MRI Comparisons

As a group, patients with nfvPPA had less impairment on Mini-Mental State Examination and Clinical Dementia Rating Sum of Boxes (Table 1). All variants showed relatively preserved figure copying. Patients with svPPA showed preserved working memory and executive functions but more behavioral impairment than both nfvPPA and lvPPA groups. Patients with lvPPA performed worse on the number location and calculation tests than patients with svPPA and nfvPPA, respectively. Both patients with lvPPA and those with svPPA scored worse than patients with nfvPPA on free recall of a list of learned words, but only patients with lvPPA scored worse on recall of the Benson figure.

Language testing revealed expected group differences based on the criteria for PPA subtyping (Table 1). Patients with svPPA scored significantly worse than both nfvPPA and lvPPA groups on tests of verbal semantic knowledge and semantic association of pictures using the Pyramids and Palm Trees Test. Greater presence of apraxia of speech, dysarthria, and

Table 1. Demographics, Amyloid Imaging, Genes, and Cognition in Patients With svPPA, nvPPA, lvPPA, ivPPA, and PPA^m

Characteristic	svPPA Amyloid - (n = 24)				nvPPA Amyloid - (n = 28)				lvPPA Amyloid + (n = 25)				PPAm Amyloid + (n = 3)				Amyloid - (n = 1)				Control (n = 10)		
	A	B	C	D	E	F	G	Woman	Man	Woman	Man	Woman	Man	Woman	Man	Woman	Man	Woman	Man	Woman	Man	Z	NA
Patient identifier	NA																						
Age at symptom onset, y	59 (7) ^b	57	61	71	63	62	72	58 (8) ^b	67	55	61	66	58	NA									
Age at initial evaluation, y	63 (7) ^b	59	63	74	66	67	74	63 (8) ^b	70	57	66	70	61	69.5 (8.1)									
Sex	14 men; 10 women	Man	Woman	Woman	9 men; 19 women	Woman	Man	9 men; 16 women	Woman	Man	Woman	Man	7 men; 3 women	10 right 10 right									
Dominant hand	19 right; 2 left; 3 ambi- dextrous	Left	Right	Right	25 right; 2 left; 1 ambi- dextrous	Right	Right	16 women; 4 left; 1 ambi- dextrous	Right	Right	Right	Right	Right	Right	Right	Right	Right	Right	Right	Right	Right	Right	Right
Education, y	17 (3)	16	12	12	17 (3)	14	14	12	17 (3)	12	20	12	13	20	16.9 (2)								
Age at PET, y	63 (7)	62	63	74	68 (8)	67	70	74	63 (8)	70	66	70	61	NA									
PET SUVR	1.1 (0.1) ^d	1.23	2.4	2.01	1.2 (0.1) ^d	1.36	1.72	2.33	2.2 (0.3)	1.3	2.22	2.33	2.25	1.05	NA								
Apolipoprotein E ε4 allele copies	15 with 0; 9 with ≥1	E3/E4	E3/E3	E3/E4	25 with 0; 3 with ≥1 ^d	E3/E4	E3/E3	E3/E3	13 with 0; 11 with ≥1 ^b	E3/E3	E3/E3	E3/E3	E3/E3	E3/E3	NA								
Tau haplotype	16 with H1/H1; 7 with other	H1/H1	H1/H1	H1/H2	21 with H1/H1; 6 with other	H1/H1	H1/H1	H1/H1	14 with H1/H1; 9 with other	H1/H2	H1/H1	H1/H1	H1/H1	H1/H2	NA								
Pathologic diagnosis	See Table 2	NA	TDP-C + AD	TDP-C + AD	See Table 2	NA	PID + AD	NA	See Table 2	NA	NA	NA	NA	PID	NA								
CDR Total score	0.7 (0.4) ^b	0.5	1	1	0.5 (0.3) ^c	0.5	0	0.5	0.6 (0.2)	0.5	0.5	0.5	0.5	0	0								
CDR Sum of Boxes score	3.9 (2.3) ^b	3.5	1	6	1.9 (1.5) ^{c,d}	2	0	2	3.3 (1.8) ^b	3	1.5	4	3	0	0								
MMSE score	23 (7.3)	22	29	26	26 (3.7) ^d	27	25	25	22 (6.2) ^b	22	28 (-3.9)	19 (-24)	27 (-6.1)	13 (-37.5)	29.7 (0.7)								
NPI Total	32.3 (18.7) ^{b,d}	7	16	24	17.3 (14.5) ^c	25	0	0	10 (8.4) ^c	8	16	3	4	5	NA								
UPDRS	2 (2.4) ^b	6 ^e	0	0	13 (12) ^{c,d}	0	13	2	5.7 (9.1) ^b	2	1	10	1	21	NA								
Benson figure copy (on a scale of 1 to 17)	15.1 (1.3)	16	17	16	14.9 (1.9)	16	15	16	13.8 (3.6)	14	15 (-0.9)	0 (-13.9)	12 (-3.5)	15.7 (1.4)									
VOSP Number location (on a scale of 1 to 10)	8.9 (1.3) ^d	7 ^e	10	10	8.5 (1.5)	2 ^f	8	9	7.3 (2.5) ^c	10	9 (-1.1)	1 (-16.7)	6 (-7)	9.4 (1.1)									
Facial matching (on a scale of 1 to 12)	11.8 (0.7)	11 ^e	12	9 ^f	11.3 (1.4)	m	12	12	11 (3.1)	12	12 (0.4)	12 (0.4)	12 (0.4)	11.9 (0.3)									
Calculations (on a scale of 1 to 5)	3.9 (2.3) ^d	5	5	4	4.4 (0.8) ^d	5	5	5	3.2 (1.1) ^{b,c}	4	3 (-2.8)	2 (-4.5)	5 (0.5)	4.8 (0.4)									
CVLT-MSE Total recall	17 (8.3)	15	18	17	22.4 (6.2) ^d	31	28	25	17.4 (7.5) ^c	5 ^e	23 (-3.8)	9 (-10.4)	32 (0.4)	30.9 (3.1)									
CVLT-MSE 10 m free recall	2.5 (2.5) ^b	0	3	0	5.5 (2.6) ^{c,d}	7	9	8	3.3 (2.9) ^b	2	6 (-1.5)	2 (-4.6)	9 (0.8)	8.1 (1.3)									
Benson figure recall (on a scale of 1 to 17)	7.9 (4.6)	8	7	10	10.1 (3.6) ^d	4 ^e	10	7	6.3 (3.6) ^b	6	6 (-2.3)	0 (-4.4)	5 (-2.7)	12.7 (3.3)									

(continued)

Table 1. Demographics, Amyloid Imaging, Genes, and Cognition in Patients With svPPA, nfvPPA, IvPPA, and PPA^m (continued)

Characteristic	svPPA		nfvPPA		IvPPA		PPA ^m		Control (n = 10)		
	Amyloid- (n = 24)	Amyloid+ (n = 4)	Amyloid- (n = 28)	Amyloid+ (n = 3)	Amyloid+ (n = 25)	Amyloid- (n = 1)	Amyloid+ (n = 3)	Amyloid- (n = 1)			
Digits forward	6.3 (1.8) ^{b,d}	7	4.6 (1.1) ^c	3 ^e	4.2 (1.2) ^b	4	4 (-4.4)	4 (-4.4)	5 (3.1)	7 (1.2)	
Digits backward	4.4 (1.3) ^{b,d}	5	3.4 (1.2) ^c	2 ^e	2.8 (1.1) ^b	3	3 (-1.8)	2 (-2.6)	4 (-1)	4.8 (1.1)	
Modified trails (lines/min)	21.3 (12.5) ^{b,d}	1.5 ^e	13.4 (8.6) ^c	1.5 ^e	8.8 (8.8) ^b	1	24 (-1.1)	1.5 (-3.7)	5.5 (-3.3)	29.7 (8.1)	
Design fluency	8.4 (2.4)	15	6.3 (3.4)	7	6.7 (3.7)	7	9 (-1)	1 (-3.8)	9 (-1)	11.8 (2.9)	
Stroop interference	38.7 (18.7) ^{b,d}	27	22.8 (11) ^c	32	16.1 (11.1) ^b	16	20 (-2.5)	5 (-3.7)	22 (-2.3)	52 (12.8)	
Boston Naming Test (BNT, 15)	4.6 (3.2) ^{b,d}	1 ^e	12.1 (2.8) ^c	12	9.9 (4.1) ^c	4 ^e	14 (-0.9)	13 (-2.1)	8 (-8.4)	14.8 (0.4)	
Speech fluency (WAB, 10)	9 (0.5) ^b	10	7.1 (2) ^{c,d}	4 ^e	8.5 (1.4) ^b	8	9	9	9	9	NA
Information content (WAB, 10)	9.1 (1)	9	9 (0.9)	9	8.9 (1.7)	6 ^e	8	9	9	9	NA
Semantic fluency (animals)	7.3 (4.4)	2 ^e	10.3 (5.3)	9	9.9 (4.1)	5 ^e	12 (-2.8)	9 (-3.5)	12 (-2.8)	0 (-5.4)	24 (6.4)
Phonemic fluency (d words)	7 (4.3)	8	5.6 (2.6)	3 ^e	7.5 (4)	2 ^e	16 (-0.3)	4 (-2.7)	17 (-0.1)	0 (-3.6)	18.3 (3.4)
AOS (MSE, 7)	0 ^b	0	2.4 (2) ^{b,d}	2	0 ^b	0	4	2	0	0	0
Dysarthria rating (MSE, 7)	0 ^b	0	1.8 (2.1) ^{b,d}	0	0 ^b	0	3	0	0	0	0
PPVT total (on a scale of 1 to 16)	8.1 (3.8) ^{b,d}	9	14.5 (2) ^c	12 ^e	13.9 (2) ^c	9 ^e	15	15 (-1.4)	16	11 (-8)	15.3 (0.7)
PPVT total (on a scale of 1 to 52)	40 (7.2) ^{b,d}	42	48.1 (5.1) ^c	49	48.5 (2.8) ^c	46	50 (-1.8)	m	41 (-12.4)	45 (-7.6)	51.5 (0.8)
Sequential commands (WAB, 80)	74.5 (11.6)	59 ^e	70.3 (12.7)	57 ^e	66.8 (14.3)	58	70 (-5.5)	70 (-5.5)	72 (-4.3)	65 (-8.4)	79.2 (1.7)
Grammar comprehension, % ^h	93.1 (10.6)	87	87.9 (11.3)	60 ^g	84.5 (12.7)	m	85 (-5.1)	90 (-3.2)	88 (-3.9)	74 (-9.3)	98.4 (2.6)
Repetition (WAB, 100)	87.6 (15.6) ^d	89	83.9 (15)	72	73.9 (16) ^c	54 ^e	84 (-10.9)	79 (-14.4)	84 (-10.9)	81 (-13)	99.2 (1.4)

Abbreviations: AD, Alzheimer disease; AOS, apraxia of speech; BNT, Boston Naming Test; CBD, corticobasal degeneration; CDR, Clinical Dementia Rating Scale; CVLT, California Verbal Learning Test; IvPPA, logopenic PPA; m, missing; MMSE, Mini-Mental State Examination; MSE, Motor Speech Examination; NA, not applicable; nfvPPA, nonfluent/agrammatic PPA; NPI, neuropsychiatric inventory; PID, Pick's disease; PET, positron emission tomography; PPVT, Peabody's picture vocabulary test; PPTp, Pyramids and Palm Trees Picture version; svPPA, semantic PPA; SUVR, standardized uptake value ratio; u, unable to perform; TDP, TAR DNA-binding protein; UPDRS, Unified Parkinson Disease Rating Scale; VOSP, Visual Object and Space Perception battery; WAB, Western Aphasia Battery.

^a For svPPA, nfvPPA, IvPPA, and the control group, data are represented as mean (SD); for PPA^m only, patient scores followed by (z score) with respect to control group mean.

^b Significantly different than nfvPPA.

^c Significantly different than svPPA.

^d Significantly different than IvPPA.

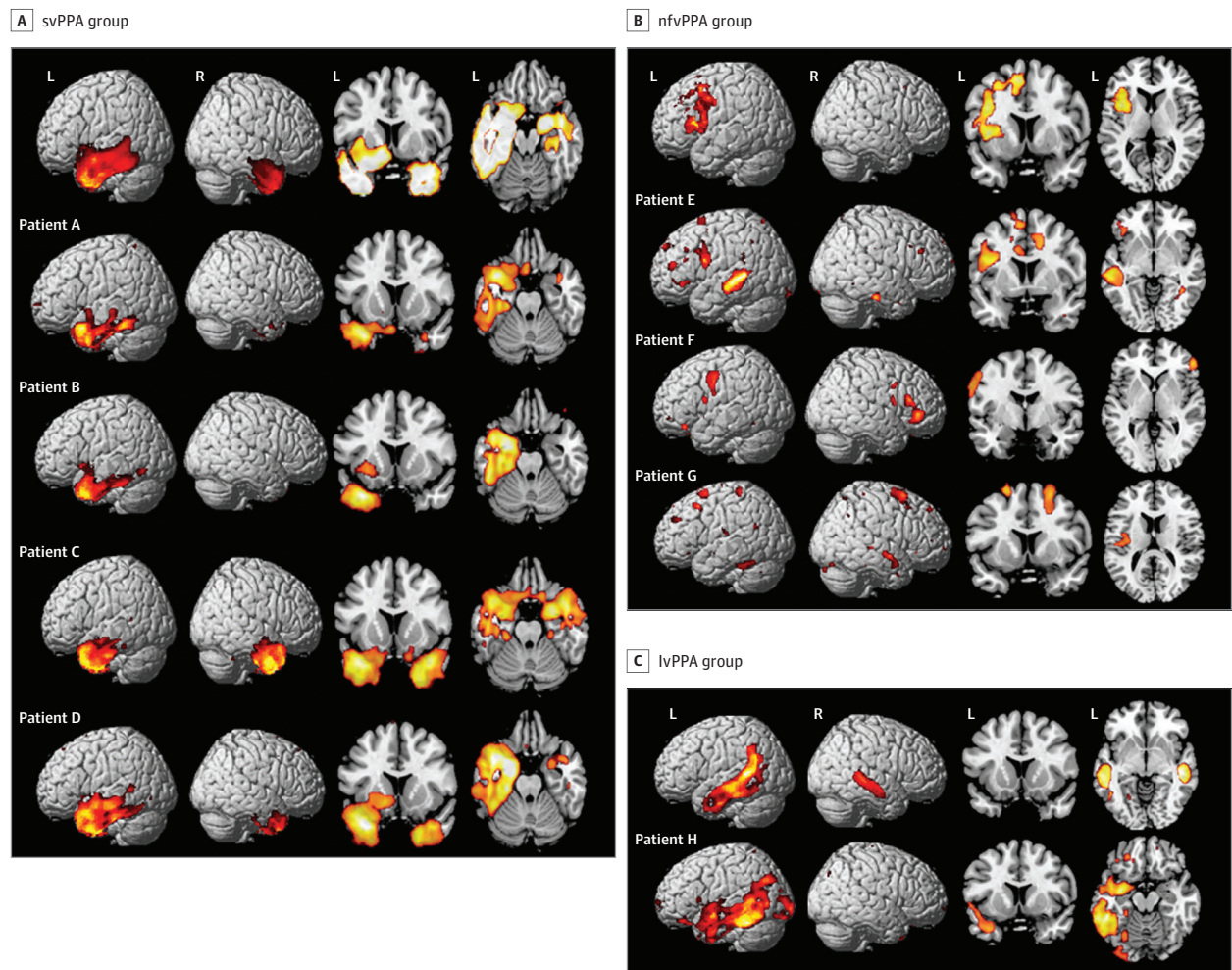
^e More than 1 SD worse than group with typical amyloid status.

^f More than 3 SD worse than group with typical amyloid status.

^g More than 2 SD worse than group with typical amyloid status.

^h Grammar comprehension tests used were either the Curtiss Yamada Comprehensive Language Evaluation receptive language test (CYCLE-R) or the University of California San Francisco grammar comprehension test and their scores are expressed as percentage correct.

Figure 1. Single-Participant Voxel-Based Morphometry of Amyloid Discordant Patients



A, The first row corresponds with the pattern of atrophy in the semantic PPA (svPPA) amyloid negative group ($n = 24$), and the subsequent rows correspond with amyloid discordant svPPA in patients A, B, C, and D. B, The first row corresponds with the pattern of atrophy in the amyloid negative nonfluent/agrammatic PPA (nfvPPA) group ($n = 28$), and the subsequent rows

correspond with amyloid discordant nfvPPA in patients E, F, and G. C, The first row corresponds with the pattern of atrophy in the logopenic PPA (lvPPA) amyloid positive group ($n = 25$), and the subsequent row corresponds with amyloid discordant lvPPA patient H. PPA indicates primary progressive aphasia. L indicates left; R, right.

decreased fluency scores differentiated patients with nfvPPA from both lvPPA and svPPA groups. Frank agrammatism in speech or writing was detected in 25 of 31 patients with nfvPPA (80.6%). Patients with lvPPA scored significantly worse than those in the svPPA group on sentence repetition.

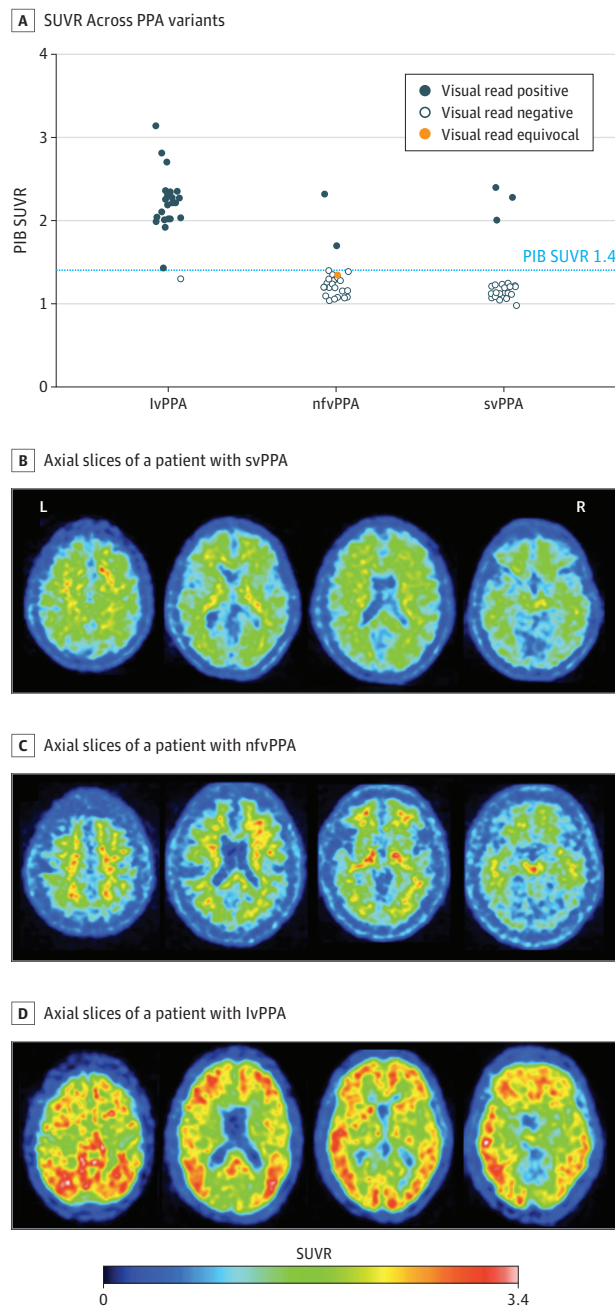
Voxel-based morphometry analysis of PPA subgroups vs control groups also revealed the expected patterns of atrophy associated with each variant (Figure 1), bilaterally predominantly left anterior temporal lobe in patients with svPPA, left posterior frontal lobe in patients with nfvPPA, and left midposterior temporal and inferior parietal lobes in patients with lvPPA.

Amyloid Imaging and Autopsy Results

Mean (SD) time between first-diagnosis PET and PET-autopsy was 244 (337) and 1641 (926) days, respectively. Overall prevalence of amyloid PET positivity in the PPA cohort was 35 of 89 (39.3%). Twenty-four of 28 patients with svPPA (85.7%)

and 28 of 31 patients with nfvPPA (90.3%) had negative amyloid PET scans, whereas 25 of 26 patients with lvPPA were amyloid positive (96.1%). For comparison, the rates of amyloid PET-positivity in patients with svPPA and nfvPPA were similar to those reported in cognitively normal individuals at a similar age (15%-20% in individuals aged 60-65 years³²), whereas the rate in lvPPA was much higher than expected for age. Of the 4 patients with PPA, 3 were amyloid positive and 1 was negative. Patients with lvPPA had significantly greater ¹¹C-PiB SUVR than those with nfvPPA and svPPA (Figure 2 and Table 1). Although they were considered to have positive results for the purposes of this study, 1 patient with svPPA and another with nfvPPA received “equivocally positive” amyloid PET reads. These patients showed evidence of focal tracer uptake in regions of early amyloid positivity (eg, precuneus/posterior cingulate cortex, dorsomedial and dorsolateral prefrontal cortex, in contrast to the widespread binding patterns across large

Figure 2. Amyloid Positron Emission Tomography in the 3 Main PPA Variants



Scatterplot depicting positron emission tomography carbon 11-labeled Pittsburgh Compound-B (¹¹C-PIB) standardized uptake value ratios (SUVR) across primary progressive aphasia (PPA) variants (A). ¹¹C-PIB axial slices of a representative patient with semantic PPA (svPPA) (B), nonfluent/agrammatic PPA (nfvPPA) (C), and logopenic PPA (lvPPA) (D). L indicates left; R, right.

regions of association cortex that are typical in advanced Alzheimer disease²⁷). Accordingly, both cases had global SUVRs consistent with early positivity (1.23 and 1.36, respectively) but lower than the conservative threshold used in our group to “rule-in” Alzheimer disease–like levels of binding (global SUVR, ≥ 1.40).

Autopsy diagnoses were available for 20 patients (Table 2). Overall, patients with positive amyloid scans all had intermediate to high Alzheimer disease neuropathological changes. When the PPA phenotype was lvPPA, positive amyloid PET was associated with primary Alzheimer disease, whereas when the PPA phenotype was nfvPPA or svPPA, the primary causative neuropathology was FTLD, with Alzheimer disease present as a contributing copathology. Conversely, all patients with negative amyloid imaging results had absent to low Alzheimer disease neuropathological changes, with FTLD as the primary causative neuropathology.

PPA With Discordant Amyloid Status

Amyloid Positive svPPA (Patients A-D)

All patients with amyloid positive svPPA (labeled as patients A-D) had ¹¹C-PIB SUVRs above 2.0 except patient A, who displayed significant amyloid binding only in the right frontal lobe and received an “equivocally positive” radiologic read. Autopsy data were available for patients B and C, who received a mixed pathologic diagnosis: FTLD-TDP-43 type C as the primary with Alzheimer disease contributing. Despite having the highest ¹¹C-PIB SUVR, patient B only showed intermediate Alzheimer disease neuropathological changes (Braak stage 2 and moderate [using the Consortium to Establish a Registry for Alzheimer Disease neuropsychological battery] neuritic but frequent diffuse plaques). Three of 4 (75%) had a apolipoprotein E $\epsilon 4$ allele. All patients showed the typical svPPA cognitive profile and atrophy pattern (Figure 1).

Amyloid Positive nfvPPA (Patients E-G)

Patients E, F, and G had ¹¹C-PIB SUVRs above 2.0 except patient E whose scan was read as “equivocally positive” and had an SUVR of 1.36. Patient E had 3 contributing pathologies: FTLD-corticobasal degeneration, Alzheimer disease (Braak 4, Consortium to Establish a Registry for Alzheimer Disease neuropsychological battery frequent), and FTLD-TDP-43 type A. Patient F (previously described³³) had a dual pathologic diagnosis: FTLD-Pick disease and Alzheimer disease (Braak 5, Consortium to Establish a Registry for Alzheimer Disease neuropsychological battery frequent). Language testing revealed varying degrees of motor speech impairment and agrammatism with spared verbal and visual semantics in all 3 amyloid positive nfvPPA cases. All cases showed atrophy in the left posterior frontal lobe with different areas of accompanying atrophy.

Amyloid Negative lvPPA (Patient H)

Patient H had amyloid negative lvPPA and an SUVR of 1.3 and autopsy data was not available. Her prominent impairment was in sentence repetition but also had worse single word comprehension than the amyloid positive group. Voxel-based morphometry revealed a frontotemporal pattern of atrophy.

PPA Mixed

Three of 4 patients with PPA (patients W, X, and Y) were amyloid positive and had SUVR greater than 2.2 (Table 1). The only patient that had an autopsy (patient Z) had FTLD-Pick disease. All patients showed word finding difficulties. At presentation, patients W and X showed impaired motor speech

Table 2. Pathological Diagnoses and Amyloid Imaging for All PPA

PPA Type	Primary Pathologic Diagnosis	Contributing Pathologic Diagnosis	Incidental Pathologic Diagnosis	Alzheimer Disease Neuropathological Change	Amyloid Imaging	PIB SUVR
svPPA						
1	FTLD-TDP-type C	PSP	NA	Braak 1, ^a CERAD 0	-	1.12
2	FTLD-TDP-type C	FTLD-tau unclassifiable	mild ASCL	Low ADNC (A1, B1, C0)	-	1.21
3	FTLD-PiD	NA	NA	Braak 1, ^a CERAD moderate	-	0.98
4 ^b	FTLD-TDP-type C	AD	mild ASCL; VID, mild CAA	Intermediate ADNC (A3, B1, C2)	+	2.40
5 ^c	FTLD-TDP-type C	AD	AGD, mild Ascl; severe CAA	High ADNC (A3, B3, C3)	+	2.01
nfvPPA						
1 ^d	FTLD-PiD	AD	moderate CAA and ASCL	Braak 5, ^a CERAD frequent	+	1.72
2	FTLD-PSP	NA	AGD; LBD	No ADNC (A0, B1, C0)	-	NA
3	FTLD-PiD	NA	mild ASCL	No ADNC (A0, B0, C0)	-	1.08
4	FTLD-PSP	NA	NA	No ADNC (A0, B1, C0)	-	1.20
5	FTLD-CBD	FTLD-TDP unclassifiable; AGD; LBD	mild ASCL, AD	Low ADNC (A1, B2, C0)	-	1.08
6	FTLD-CBD	VID; moderate Ascl	LBD; AD	Low ADNC (A1, B1, C1)	-	1.16
7 ^e	FTLD-CBD	AD; FTLD-TDP-A	mild ASCL	Intermediate ADNC (A2, B2, C3)	+	1.36
8	FTLD-CBD	NA	mild ASCL; AD	Low ADNC (A1, B3, C0)	-	1.07
9	FTLD-PiD	NA	mild ASCL; AD	Low ADNC (A1, B1, C0)	-	1.08
10	FTLD-CBD	VID	mild ASCL; AD	Low ADNC (A1, B0, C0)	-	1.16
11	FTLD-CBD	NA	mild ASCL	No ADNC (A0, B1, C0)	-	1.19
12	FTLD-CBD	LBD	NA	No ADNC (A0, B1, C0)	-	1.31
lvPPA						
1	AD	NA	VID; mild ASCL; moderate CAA	High ADNC (A3, B3, C3)	+	2.01
2	AD	NA	mild ASCL; mild CAA	High ADNC (A3, B3, C3)	+	2.33
3	AD	NA	mild CAA; limbic AGD	High ADNC (A3, B3, C3)	+	2.25
PPAm						
1 ^f	FTLD; PiD	NA	LBD; AD	Low ADNC (A1, B0, C0)	-	1.04

Abbreviations: AD, Alzheimer disease; ADNC, Alzheimer disease Neuropathological Changes; AGD, argyrophilic grain disease; ASCL, arteriosclerosis; CAA, cerebral amyloid angiopathy; CBD, corticobasal degeneration; CERAD, Consortium to Establish a Registry for Alzheimer Disease; FTLD, frontotemporal lobar degeneration; LBD, Lewy body disease; lvPPA, logopenic PPA; NA, not applicable; nfvPPA, nonfluent/agrammatic PPA; PiD, Pick disease; PPA, primary progressive aphasia; PPAm, PPA mixed; PSP, progressive supranuclear palsy; SUVR, standardized uptake value ratio; svPPA, semantic PPA; TDP, TAR DNA-binding protein; VID, vascular ischemic disease.

^a Complete ADNC score not available.

^b Patient B.

^c Patient C.

^d Patient F.

^e Patient F.

^f Patient Z.

(apraxia of speech and dysarthria), sentence repetition, and grammar comprehension. Patient Y presented with impaired semantics, sentence repetition, and grammar comprehension. Patient Z showed impaired grammar, semantics, sentence repetition, and grammar comprehension. Consistent with their clinical presentation, these patients did not show the typical patterns of atrophy seen in the 3 main variants (Figure 3).

Discussion

We report amyloid brain imaging and cognitive and structural MRI results in the largest PPA cohort, to our knowledge, prospectively diagnosed using current criteria. Classification according to PPA variant was associated with Alzheimer disease biomarker status, with the logopenic variant being associated with ¹¹C-PIB deposition in more than 95% of the patients with sporadic PPA. Furthermore, we found that most cases with typical svPPA and nfvPPA and an unexpected positive amyloid scan had mixed FTLD and Alzheimer disease pathology. These results suggest that typical clinical and MRI find-

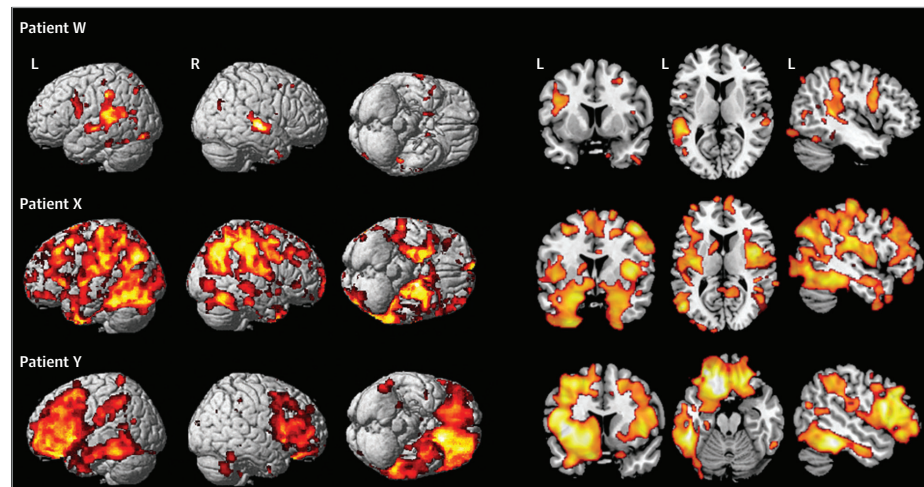
ings in svPPA and nfvPPA variants are associated with the presence of FTLD pathology, even in the face of discordant molecular Alzheimer disease biomarker results.

Association of PPA Variant Classification According to Current Consensus Criteria With Amyloid Imaging Biomarker Status

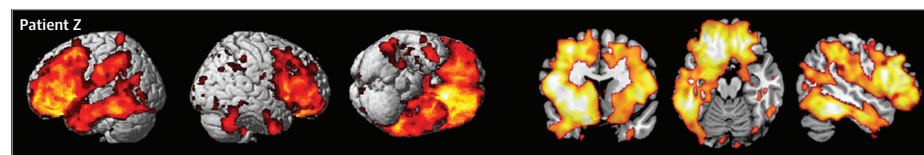
Four of 28 patients with svPPA (15%) and 3 of 31 patients with nfvPPA (10%) had a positive amyloid PET scan. These rates are similar to, if not slightly lower than, the reported prevalence of amyloid positivity in normal individuals at a similar age (15%-20%).³² These results are in line with other prospective studies, reporting amyloid positivity in 1 of 9 patients with svPPA and 2 of 8 patients with nfvPPA,⁸ 0 of 3 patients with svPPA and 0 of 11 patients with nfvPPA,¹⁰ and 3 of 9 patients with svPPA and 7 of 52 patients with nfvPPA³⁴ (the last study included patients labeled as having primary progressive apraxia of speech). Clinicopathologic studies retrospectively applying current criteria also report increased homogeneity of pathologic diagnoses within each PPA variant; however, the prevalence of an Alzheimer disease pathologic diagnosis is more heterogeneous, particularly in lvPPA and nfvPPA (0%-16%

Figure 3. Voxel-Based Morphometry of Gray Matter Atrophy Patterns

A Amyloid positive PPA



B Amyloid negative PPA



Voxel-based morphometry of gray matter atrophy patterns for amyloid positive primary progressive aphasia (PPA) mixed (PPAm) in patient W, X, and Y (A), and amyloid negative PPA in patient Z (B). L indicates left; R, right.

svPPA, 13%-31% nfvPPA, and 54%-77% lvPPA).^{5-7,35} Although well-studied cases of nfvPPA and svPPA with Alzheimer disease pathology have been reported,^{36,37} it is possible that the higher percentage of Alzheimer disease in these studies is due in part to the difficulty of retrospectively assessing key diagnostic features such as apraxia of speech, agrammatism, repetition, and semantic impairment. Even today, these key features are evaluated with different instruments across centers and represent a significant hurdle for comparison and generalization of results. Furthermore, all of the amyloid discordant cases with available autopsy data (two svPPA and two nfvPPA) in our study had primary FTLD and secondary Alzheimer's disease pathological diagnoses suggesting that a substantial proportion of amyloid positive svPPA and nfvPPA patients may have a primary FTLD pathologic diagnosis with amyloid as a contributing or incidental pathology.

Our finding of only 1 amyloid negative out of 26 patients with lvPPA (96% amyloid positive) is also in line with the rates of amyloid positivity (80%-100%) reported in other prospective PPA cohort studies.^{8,10,11} Despite the general association of lvPPA with Alzheimer disease, this study and others have reported cases of patients prospectively^{8,11-13} and retrospectively diagnosed as having lvPPA^{5-7,14} without Alzheimer disease biomarkers or pathology. The studies reporting retrospective diagnoses all report higher rates of non-Alzheimer disease pathology in lvPPA than the ones reporting prospective diagnoses possibly due to the absence of targeted neuropsychological evaluations that have been implemented more recently. The reasons for discrepancies in the rates of amyloid-negative lvPPA are unknown but probably reflect real

differences in patient cohorts (such as absence of mutation carriers in our cohort) as well as variability in the application of diagnostic criteria across centers.

PPA With Discordant Amyloid Status

We did not find any demographic, genetic, cognitive, or neuroimaging features that reliably distinguished amyloid positive svPPA or nfvPPA from their primarily amyloid-negative counterparts. Carrying an apolipoprotein E ϵ 4 allele was a risk factor for amyloid positivity even within just svPPA and nfvPPA (odds ratio, 5.6; 95% CI, 1.1-29.1; $P = .04$). No genetic mutations were found in any of these cases. All 4 amyloid-positive patients with svPPA showed the same language and atrophy profiles as the amyloid-typical group concordant with the available autopsy data and suggest FTLD may be the primary pathologic diagnosis in all 4 patients. Two patients showed highly impaired set shifting in the Modified Trail Making Test, which is unusual for typical svPPA and may reflect an Alzheimer disease contribution to the clinical picture.³⁸ All amyloid-positive patients with nfvPPA also showed the typical language profile and a common area of atrophy in the left posterior frontal lobe, although each case presented different areas of accompanying atrophy perhaps reflecting the heterogeneous pathologic diagnoses that are known to be associated with nfvPPA. The amyloid negative lvPPA case in our cohort showed more semantic impairment, and her pattern of left temporal atrophy was more anterior and left asymmetric than the amyloid positive lvPPA group. Recent studies have also reported a trend toward worse semantics¹³ and greater left asymmet-

ric anterior temporal atrophy and/or hypometabolism^{11,12} in amyloid-negative lvPPA. According to current genetic and pathologic data, most amyloid negative lvPPA cases are associated with an autosomal dominant granulin mutation^{11,39} or sporadic TDP-43-A pathology.⁵⁻⁷

Diagnosis According to Current PPA Consensus Criteria Classified the Majority of Patients Who Met Root PPA Criteria

Similar to other recent studies,⁶⁻⁸ we identified the initial predominantly impaired language domain and classify almost all (85 of 89 [95.5%]) patients that met root PPA criteria. However, some studies report inability to classify a higher proportion of patients, especially when attempting data-driven vs clinical classification methods.^{40,41} The 2 main issues described in previous reports are that a significant number of patients present with both agrammatism and sentence repetition impairment, thus meeting criteria for both nvfPPA and lvPPA, while other patients present only with anomia and thus do not meet any criteria.^{5,34} Despite the existence of unclear cases that required discussion, in our experience and that of others, application of current criteria and targeted speech and language assessments using clinical judgment to identify the predominantly impaired and relatively spared language domains can resolve many of these cases. Furthermore, visual inspection of MRI scans were always used when available to make an imaging-supported diagnosis as defined in the consensus criteria.² It is also important to note that the low number of mixed cases in our cohort might be related to the absence of progranulin mutation carriers, who have been shown to present with a logopenic-like mixed PPA syndrome.³⁹ A possible factor in the absence of patients presenting only anomia in our cohort could be that the aphasia tended to be further evolved before referral to our specialty center.

All 4 patients with PPAm in our cohort presented a mix of core features and atrophy typical of more than 1 variant, which were thought to contribute significantly to the clinical picture. Even before knowing the result of the amyloid imaging,

Alzheimer disease was the predicted pathology in both patients with mixed phonological and motor speech impairment due to the relative predominance of phonologic impairment, posterior vs frontal atrophy, and presence of impaired memory neuropsychological scores. No patients presented with another previously described PPAm phenotype of equally impaired grammatical production and verbal semantics.⁴² Further studies including larger numbers of mixed cases are needed to determine if these present with consistent clinical-pathologic associations.

Limitations

The main limitations of this study stem from the sample size and possible referral bias. Primary progressive aphasia is a rare disorder, and despite the relatively large size and extensive characterization (clinical, cognitive, and multimodal neuroimaging) of our cohort, the sample size is too small to establish firm conclusions. In particular, our findings with respect to the amyloid discordant and mixed PPA cases warrant further study. Another issue that could limit generalization of our results is referral bias. For example, a possible factor in the absence of patients presenting only anomia in our cohort could be that the aphasia tended to be further evolved prior to referral to our specialty center. Referral bias could also be a factor in the small numbers of mixed cases and patients with genetic mutations in our cohort compared to other centers that report a higher proportion of patients with these characteristics.

Conclusions

Primary progressive aphasia variant imaging-confirmed diagnosis according to 2011 consensus classification was associated with Alzheimer disease biomarker status. Furthermore, our results emphasize that positive amyloid biomarker status does not rule out the possibility of a primary FTLD pathologic process driving the clinical syndrome.

ARTICLE INFORMATION

Accepted for Publication: September 22, 2017.

Published Online: January 8, 2018.

doi:10.1001/jamaneurol.2017.4309

Author Affiliations: Department of Neurology, Memory and Aging Center, University of California San Francisco (Santos-Santos, Rabinovici, Iaccarino, Ayakta, Tammewar, Hubbard, Mandelli, Spinelli, Z. A. Miller, Pressman, Ghosh, Lazaris, Meyer, Watson, Yoon, Rosen, Grinberg, Seeley, B. L. Miller, Gorno-Tempini); Helen Wills Neuroscience Institute, University of California Berkeley, Berkeley (Rabinovici, Ayakta, Tammewar, Jagust); Department of Communication Sciences and Disorders, University of Texas, Austin (Henry); Life Sciences Division, Lawrence Berkeley National Laboratory, Berkeley, California (O'Neil, Jagust); Department of Pathology, University of California San Francisco, California (Grinberg, Seeley); Autonomous University of Barcelona, Cerdanyola del Valles, Spain (Santos-Santos); Department of Epidemiology and Biostatistics, University of California San Francisco (Lobach); Vita-Salute San

Raffaele University, Milan, Italy (Iaccarino, Spinelli); Department of Neurology, Eulji University Hospital, Daejeon, South Korea (Yoon); Cognition and Brain Plasticity Group, Bellvitge Biomedical Research Institute, L'Hospitalet de Llobregat, Barcelona, Spain (Santos-Santos); Fundació Alzheimer Memory Clinic and Research Center, Institut Català de Neurociències Aplicades, Barcelona, Spain (Santos-Santos); University of Colorado Denver, Denver (Pressman).

Author Contributions: Dr Santos-Santos had full access to all of the data in the study and takes responsibility for the integrity of the data and the accuracy of the data analysis.

Study concept and design: Santos-Santos, Rabinovici, Rosen, B. Miller, Gorno-Tempini.

Acquisition, analysis, or interpretation of data: Santos-Santos, Rabinovici, Iaccarino, Ayakta, Tammewar, Lobach, Henry, Hubbard, Mandelli, Spinelli, Z. Miller, Pressman, O'Neil, Ghosh, Lazaris, Meyer, Watson, Yoon, Grinberg, Seeley, Jagust.

Drafting of the manuscript: Santos-Santos, Iaccarino, Lobach, Hubbard, Ghosh, Meyer, Watson, Yoon.

Critical revision of the manuscript for important intellectual content: Santos-Santos, Rabinovici, Ayakta, Tammewar, Lobach, Henry, Hubbard, Mandelli, Spinelli, Z. Miller, Pressman, O'Neil, Lazaris, Rosen, Grinberg, Seeley, B. Miller, Jagust, Gorno-Tempini.

Statistical analysis: Santos-Santos, Iaccarino, Ayakta, Tammewar, Lobach, Hubbard, Mandelli, Spinelli.

Obtained funding: Rabinovici, O'Neil, Rosen, Seeley.

Administrative, technical, or material support: Henry, Mandelli, Z. Miller, O'Neil, Ghosh, Lazaris, Meyer, Watson, Yoon, Seeley.

Study supervision: Rabinovici, Rosen, B. Miller, Jagust, Gorno-Tempini.

Conflict of Interest Disclosures: Dr Jagust is a consultant to Genentech, Novartis, Bioclinica, and Biogen. Dr Seeley is a consultant for Merck and Biogen. No other disclosures were reported.

Funding/Support: The study was supported by grants from the Alfonso Martin Escudero Foundation, National Institutes of Health (National Institute of Neurological Disorders and Stroke grant R01 NS050915 and National Institute on Aging

grants P50 AG03006, P50 AG023501, P01 AG019724, R01 AG045611, R01 AG027859, and K24 DC015544-01), grant DHS04-35516 from the State of California, grant 03-75271 DHS/ADP/ARCC from the Alzheimer's Disease Research Centre of California; Alzheimer's Association, Larry L. Hillblom Foundation, John Douglas French Alzheimer's Foundation, Koret Family Foundation, Consortium for Frontotemporal Dementia Research, Tau Consortium, McBean Family Foundation, Career Scientist Award from the US Department of Veterans Affairs Clinical Sciences R&D Program, and Avid Radiopharmaceuticals.

Role of the Funder/Sponsor: The funders had no involvement in the study design, collection, analysis or interpretation of data, nor were they involved in writing the paper or the decision to submit this report for publication.

Additional Contributions: The authors thank the patients and their families for the time and effort they dedicated to the research.

REFERENCES

- Mesulam MM. Slowly progressive aphasia without generalized dementia. *Ann Neurol*. 1982;11(6):592-598.
- Gorno-Tempini ML, Hillis AE, Weintraub S, et al. Classification of primary progressive aphasia and its variants. *Neurology*. 2011;76(11):1006-1014.
- Klunk WE, Engler H, Nordberg A, et al. Imaging brain amyloid in Alzheimer's disease with Pittsburgh Compound-B. *Ann Neurol*. 2004;55(3):306-319.
- Landau SM, Thomas BA, Thurfjell L, et al; Alzheimer's Disease Neuroimaging Initiative. Amyloid PET imaging in Alzheimer's disease: a comparison of three radiotracers. *Eur J Nucl Med Mol Imaging*. 2014;41(7):1398-1407.
- Mesulam MM, Weintraub S, Rogalski EJ, Wieneke C, Geula C, Bigio EH. Asymmetry and heterogeneity of Alzheimer's and frontotemporal pathology in primary progressive aphasia. *Brain*. 2014;137(Pt 4):1176-1192.
- Harris JM, Gall C, Thompson JC, et al. Classification and pathology of primary progressive aphasia. *Neurology*. 2013;81(21):1832-1839.
- Chare L, Hodges JR, Leyton CE, et al. New criteria for frontotemporal dementia syndromes: clinical and pathological diagnostic implications. *J Neurol Neurosurg Psychiatry*. 2014;85(8):865-870.
- Leyton CE, Villemagne VL, Savage S, et al. Subtypes of progressive aphasia: application of the International Consensus Criteria and validation using β -amyloid imaging. *Brain*. 2011;134(Pt 10):3030-3043.
- Mackenzie IR, Neumann M, Bigio EH, et al. Nomenclature and nosology for neuropathologic subtypes of frontotemporal lobar degeneration: an update. *Acta Neuropathol*. 2010;119(1):1-4.
- Gil-Navarro S, Lladó A, Rami L, et al. Neuroimaging and biochemical markers in the three variants of primary progressive aphasia. *Dement Geriatr Cogn Disord*. 2013;35(1-2):106-117.
- Whitwell JL, Duffy JR, Strand EA, et al. Clinical and neuroimaging biomarkers of amyloid-negative logopenic primary progressive aphasia. *Brain Lang*. 2015;142:45-53.
- Matías-Guiu JA, Cabrera-Martín MN, Moreno-Ramos T, et al. Amyloid and FDG-PET study of logopenic primary progressive aphasia: evidence for the existence of two subtypes. *J Neurol*. 2015;262(6):1463-1472.
- Rohrer JD, Ridgway GR, Crutch SJ, et al. Progressive logopenic/phonological aphasia: erosion of the language network. *Neuroimage*. 2010;49(1):984-993.
- Rogalski E, Sridhar J, Rader B, et al. Aphasic variant of Alzheimer disease: clinical, anatomic, and genetic features. *Neurology*. 2016;87(13):1337-1343.
- Gorno-Tempini ML, Dronkers NF, Rankin KP, et al. Cognition and anatomy in three variants of primary progressive aphasia. *Ann Neurol*. 2004;55(3):335-346.
- Rabinovici GD, Jagust WJ, Furst AJ, et al. Abeta amyloid and glucose metabolism in three variants of primary progressive aphasia. *Ann Neurol*. 2008;64(4):388-401.
- Kramer JH, Jurik J, Sha SJ, et al. Distinctive neuropsychological patterns in frontotemporal dementia, semantic dementia, and Alzheimer disease. *Cogn Behav Neurol*. 2003;16(4):211-218.
- Gorno-Tempini ML, Murray RC, Rankin KP, Weiner MW, Miller BL. Clinical, cognitive and anatomical evolution from nonfluent progressive aphasia to corticobasal syndrome: a case report. *Neurocase*. 2004;10(6):426-436.
- Santos-Santos MA, Mandelli ML, Binney RJ, et al. Features of patients with nonfluent/agrammatic primary progressive aphasia with underlying progressive supranuclear palsy pathology or corticobasal degeneration. *JAMA Neurol*. 2016;73(6):733-742.
- Wertz R, LaPointe L, Rosenbek J. *Apraxia of Speech: The Disorders and Its Management*. New York, NY: Grune and Stratton; 1984.
- Dunn LM. *Peabody Picture Vocabulary Test-Revised (PPVT-R)*. Circle Pines, MN: American Guidance Service; 1981.
- About the test. CYCLE website. <http://thecycletest.com/test/>. Accessed November 20, 2017.
- Wilson SM, Dronkers NF, Ogar JM, et al. Neural correlates of syntactic processing in the nonfluent variant of primary progressive aphasia. *J Neurosci*. 2010;30(50):16845-16854.
- Mormino EC, Smiljic A, Hayenga AO, et al. Relationships between β -amyloid and functional connectivity in different components of the default mode network in aging. *Cereb Cortex*. 2011;21(10):2399-2407.
- Bettcher BM, Wilhelm R, Rigby T, et al. C-reactive protein is related to memory and medial temporal brain volume in older adults. *Brain Behav Immun*. 2012;26(1):103-108.
- Zhang Y, Schuff N, Ching C, et al. Joint assessment of structural, perfusion, and diffusion MRI in Alzheimer's disease and frontotemporal dementia. *Int J Alzheimers Dis*. 2011;2011:546871.
- Villeneuve S, Rabinovici GD, Cohn-Sheehy BI, et al. Existing Pittsburgh Compound-B positron emission tomography thresholds are too high: statistical and pathological evaluation. *Brain*. 2015;138(Pt 7):2020-2033.
- Rabinovici GD, Rosen HJ, Alkalay A, et al. Amyloid vs FDG-PET in the differential diagnosis of AD and FTLD. *Neurology*. 2011;77(23):2034-2042.
- Clark CM, Pontecorvo MJ, Beach TG, et al; AV45-A16 Study Group. Cerebral PET with florbetapir compared with neuropathology at autopsy for detection of neuritic amyloid- β plaques: a prospective cohort study. *Lancet Neurol*. 2012;11(8):669-678.
- Clark CM, Schneider JA, Bedell BJ, et al; AV45-A07 Study Group. Use of florbetapir-PET for imaging beta-amyloid pathology. *JAMA*. 2011;305(3):275-283.
- Hyman BT, Phelps CH, Beach TG, et al. National Institute on Aging-Alzheimer's Association guidelines for the neuropathologic assessment of Alzheimer's disease. *Alzheimers Dement*. 2012;8(1):1-13.
- Jansen WJ, Ossenkuppe R, Knol DL, et al; Amyloid Biomarker Study Group. Prevalence of cerebral amyloid pathology in persons without dementia: a meta-analysis. *JAMA*. 2015;313(19):1924-1938.
- Caso F, Gesierich B, Henry M, et al. Nonfluent/agrammatic PPA with in-vivo cortical amyloidosis and Pick's disease pathology. *Behav Neurol*. 2013;26(1-2):95-106.
- Botha H, Duffy JR, Whitwell JL, et al. Classification and clinicoradiologic features of primary progressive aphasia (PPA) and apraxia of speech. *Cortex*. 2015;69:220-236.
- Harris JM, Jones M. Pathology in primary progressive aphasia syndromes. *Curr Neurol Neurosci Rep*. 2014;14(8):466.
- Alladi S, Xuereb J, Bak T, et al. Focal cortical presentations of Alzheimer's disease. *Brain*. 2007;130(Pt 10):2636-2645.
- Knibb JA, Xuereb JH, Patterson K, Hodges JR. Clinical and pathological characterization of progressive aphasia. *Ann Neurol*. 2006;59(1):156-165.
- Pa J, Possin KL, Wilson SM, et al. Gray matter correlates of set-shifting among neurodegenerative disease, mild cognitive impairment, and healthy older adults. *J Int Neuropsychol Soc*. 2010;16(4):640-650.
- Rohrer JD, Crutch SJ, Warrington EK, Warren JD. Progranulin-associated primary progressive aphasia: a distinct phenotype? *Neuropsychologia*. 2010;48(1):288-297.
- Sajjadi SA, Patterson K, Arnold RJ, Watson PC, Nestor PJ. Primary progressive aphasia: a tale of two syndromes and the rest. *Neurology*. 2012;78(21):1670-1677.
- Wicklund MR, Duffy JR, Strand EA, Machulda MM, Whitwell JL, Josephs KA. Quantitative application of the primary progressive aphasia consensus criteria. *Neurology*. 2014;82(13):1119-1126.
- Mesulam MM, Wieneke C, Thompson C, Rogalski E, Weintraub S. Quantitative classification of primary progressive aphasia at early and mild impairment stages. *Brain*. 2012;135(Pt 5):1537-1553.