

# UC Davis

## UC Davis Previously Published Works

### Title

Medical management of acute ocular hypertension in a western screech owl (*Megascops Kennicottii*)

### Permalink

<https://escholarship.org/uc/item/1mm2q76x>

### Journal

Journal of Avian Medicine and Surgery, 28(1)

### ISSN

1082-6742

### Authors

Jayson, S  
Guzman, DSM  
Petritz, O  
[et al.](#)

### Publication Date

2014

### DOI

10.1647/2012-079

Peer reviewed

## **Medical Management of Acute Ocular Hypertension in a Western Screech Owl (*Megascops kennicottii*)**

Author(s): Stephanie Jayson , MA, Vet MB, MRCVS, David Sanchez-Migallon Guzman , LV, MS, Dipl ECZM (Avian), Dipl ACZM, Olivia Petritz , DVM, Dipl ACZM, Kate Freeman , MEM, DVM, Dipl ACVO, and David J. Maggs , BVSc, Dipl ACVO

Source: Journal of Avian Medicine and Surgery, 28(1):38-44. 2014.

Published By: Association of Avian Veterinarians

DOI: <http://dx.doi.org/10.1647/2012-079>

URL: <http://www.bioone.org/doi/full/10.1647/2012-079>

---

BioOne ([www.bioone.org](http://www.bioone.org)) is a nonprofit, online aggregation of core research in the biological, ecological, and environmental sciences. BioOne provides a sustainable online platform for over 170 journals and books published by nonprofit societies, associations, museums, institutions, and presses.

Your use of this PDF, the BioOne Web site, and all posted and associated content indicates your acceptance of BioOne's Terms of Use, available at [www.bioone.org/page/terms\\_of\\_use](http://www.bioone.org/page/terms_of_use).

Usage of BioOne content is strictly limited to personal, educational, and non-commercial use. Commercial inquiries or rights and permissions requests should be directed to the individual publisher as copyright holder.

## Medical Management of Acute Ocular Hypertension in a Western Screech Owl (*Megascops kennicottii*)

Stephanie Jayson, MA, Vet MB, MRCVS,  
David Sanchez-Migallon Guzman, LV, MS, Dipl ECZM (Avian), Dipl ACZM,  
Olivia Petritz, DVM, Dipl ACZM, Kate Freeman, MEM, DVM, Dipl ACVO,  
and David J. Maggs, BVSc, Dipl ACVO

**Abstract:** A wild young adult western screech owl (*Megascops kennicottii*) of unknown sex was presented for evaluation of an abnormal left eye (OS). Ophthalmic examination OS revealed raised intraocular pressure (37 mm Hg; reference interval 7–16 mm Hg), mydriasis, conjunctival and episcleral hyperemia, shallow anterior chamber due to anterior displacement of the lens and iris, rubeosis iridis, and engorgement of the pecten. The intraocular pressure in the right eye (OD) was 11 mm Hg. Multifocal pale, variably translucent, curvilinear to vermiform opacities were observed in the medial and ventral peripheral regions of the retina OD, consistent with focal retinitis. Mannitol (0.46 g/kg IV) was administered over 10 minutes. Forty minutes later, the intraocular pressure was 27 mm Hg OS and 13 mm Hg OD. Dorzolamide (one drop OS q12h), diclofenac (one drop OU q8–12h), and meloxicam (0.5 mg/kg PO q24h) were administered for 3 days. The intraocular pressure OS was within normal limits 1 day (11 mm Hg), 7 days (13 mm Hg), and 4 weeks (14 mm Hg) after this treatment. Complications arising during hospitalization and rehabilitation included superficial corneal ulceration of both eyes presumed secondary to trauma on being caught and superficial damage to a talon. The owl was released after a period of rehabilitation. Characteristic presenting signs as well as response to therapy suggest aqueous misdirection was the cause of ocular hypertension in this owl. To our knowledge, this is the first report of suspected aqueous misdirection and its medical management in a raptor.

**Key words:** glaucoma, ocular hypertension, mannitol, dorzolamide, avian, western screech owl, *Megascops kennicottii*

### Clinical Report

A young adult, wild western screech owl (*Megascops kennicottii*) of unknown sex, weighing 162 g, was presented to the William R. Pritchard Veterinary Medical Teaching Hospital at the University of California, Davis, CA, USA, for

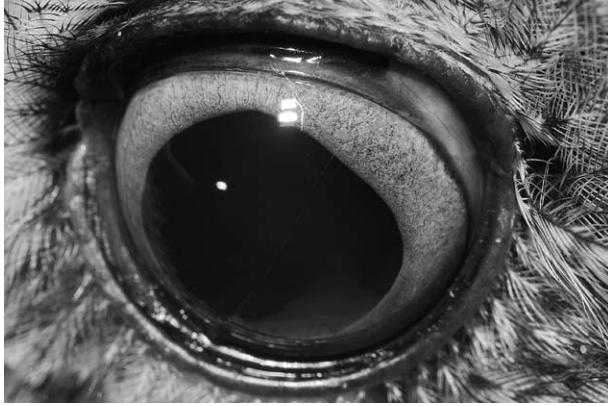
evaluation of an abnormal left eye (OS). The owl had been found in Placerville, CA, USA, by a member of the public and taken to the California Raptor Center. No previous history was known.

On presentation, the owl was quiet, alert, and responsive; in good body condition; and with no external evidence of trauma, including normal aural examination findings. Ophthalmic examination was performed by using diffuse light, slit-lamp biomicroscopy, and binocular indirect ophthalmoscopy. Pupils were not pharmacologically dilated as part of this or any subsequent examinations. Both eyes (OU) were open and appeared comfortable. No ocular discharge or facial asymmetry was observed. Globe position was normal OU. Anisocoria was present because of mydriasis OS. Direct pupillary light reflex was present in the right eye

---

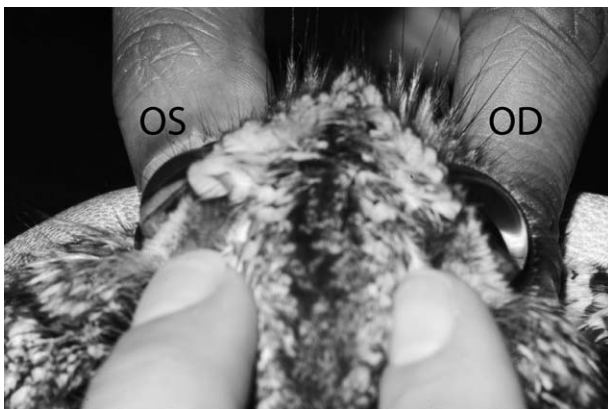From the Department of Veterinary Medicine, University of Cambridge, Madingley Road, Cambridge, Cambridgeshire, CB3 0ES, UK (Jayson); the Department of Veterinary Medicine and Epidemiology (Guzman), the Veterinary Medical Teaching Hospital (Petritz), and the Department of Surgical and Radiological Sciences (Freeman, Maggs), School of Veterinary Medicine, University of California, Davis, One Shields Ave, Davis, CA 95616, USA.

Present address: Manor Veterinary Centre, 373 Hagley Road, Edgbaston, Birmingham, West Midlands, B17 8DL, UK (Jayson); Ophthalmology for Animals, 8053 Valencia St, Aptos, CA 95003, USA (Freeman).

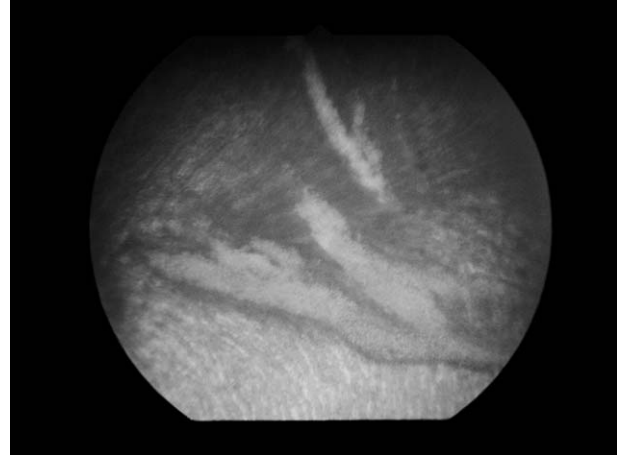


**Figure 1.** The left eye of a wild, young adult western screech owl of unknown sex at presentation. Note conjunctival and episcleral hyperemia and rubeosis iridis. The intraocular pressure in this eye was 37 mm Hg.

(OD) but absent OS. Menace response and dazzle reflex were absent OU, as is not uncommon in normally sighted raptors. Palpebral reflexes were complete OU. Examination OS revealed normal upper, lower, and third eyelids; marked conjunctival and episcleral hyperemia; adequate precorneal tear film; and a clear cornea. The anterior chamber was formed but very shallow because of forward displacement of the iris and lens. This displacement was more marked dorsally where the iris billowed forward more prominently at the collarette region than at the iris root or pupillary margin (Figs 1 and 2). There was moderate rubeosis iridis but no posterior synechia were seen.



**Figure 2.** The dorsal aspect of the head of the same owl as shown in Figure 1. The intraocular pressure was 37 mm Hg in the left eye (OS) and 11 mm Hg in the right eye (OD). Note the shallow anterior chamber OS relative to OD caused by anterior displacement of the lens-iris diaphragm believed to have resulted from aqueous misdirection.



**Figure 3.** Fundic photograph of the right eye (OD) of the same owl as shown in Figure 1 at presentation. Note the pale, variably translucent, curvilinear to vermiform opacities observed in the medial and ventral peripheral regions of the retina OD, consistent with focal retinitis.

Neither iridodonesis nor phacodonesis were observed. There was 1–2<sup>+</sup> aqueous flare and cells,<sup>1</sup> a small amount of anterior chamber fibrin, and a focal area of hyphema. The iridocorneal angle was evaluated and found to be within normal limits and similar between eyes. The anterior segment changes made fundic detail less distinct; however, the margins of the pecten were particularly indistinct and the pecten appeared engorged. No anterior segment abnormalities were observed OD. In particular, the anterior chamber was of appropriate and uniform depth. Fundic examination OD revealed pale, variably translucent, curvilinear to vermiform opacities in the medial and ventral peripheral regions of the retina OD, consistent with focal retinitis (Fig 3). The pecten was within normal limits. The horizontal limbal diameter was 16 mm OU, and the anterior-posterior corneal measurement (distance from limbus to anterior-most point on the cornea) was 6 mm OU. Fluorescein stain (BioGlo fluorescein sodium ophthalmic strips USP, HUB Pharmaceuticals, LLC, Rancho Cucamonga, CA, USA) was not retained by either cornea. After application of a single drop of proparacaine hydrochloride (proparacaine hydrochloride 0.5% ophthalmic solution USP, Falcon Pharmaceuticals Ltd, Fort Worth, TX, USA) OU, intraocular pressure (IOP) was estimated by using an applanation tonometer (TonoPen XL, Reichert Inc, Depew, NY, USA). To our knowledge, there are no published reference values for normal IOP in western screech owls, therefore, the reference interval for normal

eastern screech owls (*Megascops asio*) established using the TonoPen XL was used (reference interval 7–16 mm Hg).<sup>2,3</sup> The IOP was moderately elevated OS (37 mm Hg) but was normal OD (11 mm Hg). The ophthalmic diagnoses were anterior uveitis, ocular hypertension, and suspect pectenitis OS, along with retinitis OD. Differential diagnoses for ocular hypertension OS included goniodysgenesis and aqueous misdirection (or “malignant glaucoma”). Ocular hypertension OS could also have occurred secondary to anterior uveitis or lens subluxation. Given the wild origin of this free-living western screech owl, trauma and infectious agents were considered to be potential causes of the ocular findings. However, because of the significant ocular hypertension OS, medical management of the increased IOP was commenced before further diagnostic testing.

Anesthesia was induced with 5% isoflurane in oxygen delivered by face mask. The owl was intubated with a 2-mm uncuffed endotracheal tube and manually ventilated with 2% isoflurane in oxygen. A 0.7-mL blood sample was collected from the right jugular vein and submitted for a complete blood cell count and plasma biochemical analysis. Choanal and cloacal swabs were obtained and submitted for reverse transcriptase–polymerase chain reaction testing for West Nile virus. A 26-gauge catheter was placed in the right ulnar vein and 0.46 g/kg of a 25% solution of mannitol was administered intravenously over a period of 10 minutes. After recovery from general anesthesia and 40 minutes after completing the mannitol bolus, IOP was estimated again after applying proparacaine hydrochloride topically and using the same TonoPen XL as previously. IOP was measured as 27 mm Hg OS and 13 mm Hg OD.

Results of the complete blood cell count and plasma biochemical analysis were within reference intervals, except for mild hypercalcemia (16.0 mg/dL; reference interval 4.0–14.7 mg/dL) and mild hypoalbuminemia (0.8 g/dL; reference interval 1.0–3.5 g/dL).<sup>4</sup> The result of the West Nile virus reverse transcriptase–polymerase chain reaction was negative. A fecal examination, including a direct smear and flotation, was negative for parasites. Because the IOP OS remained above the upper reference value after mannitol treatment, topical therapy with 2% dorzolamide (one drop OS q12h) was initiated. Because of anterior uveitis and suspect pectenitis OS, as well as retinitis OD, treatment with 1% diclofenac (one drop OU q8–12h) and meloxicam (0.5 mg/kg PO q12h; Metacam, Boehringer Ingelheim Vetmedica, St Joseph, MO, USA) was also instigated.

On day 2 (24 hours after initial presentation), anisocoria had resolved. Supplemental fluids (50 mL/kg SC once) were administered to treat suspected subclinical dehydration due to mannitol therapy. By day 4, the anterior chamber was of normal depth, and trace flare, mild rubeosis iridis, and a small amount of fibrin and hemorrhage were observed in the ventral anterior chamber OS.<sup>1</sup> The retinal lesions OD had decreased in size but were still present and the posterior segment inflammation OS was improved. Application of fluorescein stain revealed an approximately 4 mm × 3 mm dorsal paraxial, superficial corneal ulcer OS. The ulcer was not associated with blepharospasm or ocular discharge and was presumed to be secondary to trauma while the bird was being caught. The IOP had reduced to within normal limits OS (11 mm Hg) and remained within the reference interval OD (10 mm Hg). Because of improvement of the anterior uveitis and the presence of a corneal ulcer, diclofenac was discontinued OS but treatment with diclofenac OD and meloxicam PO were continued because of posterior segment inflammation OU. Because of the normalized IOP OS, treatment with dorzolamide was discontinued and IOP scheduled for recheck within 24 hours. Ofloxacin (one drop OS q12h; ofloxacin ophthalmic solution 0.3%, Akorn Inc, Lake Forest, IL, USA) was initiated because of the presence of corneal ulceration.

On day 5 after initial presentation, the IOP continued to be within normal limits OU (12 mm Hg OS, 11 mm Hg OD). The superficial corneal ulcer OS was unchanged so topical administration of 0.3% hyaluronan (one drop OU q12h; iDrop Vet Plus, I-Med Animal Health, Dollard-des-Ormeaux, QC, Canada) was initiated. By day 11, the ulcer OS remained unchanged. Attempted debridement of the corneal epithelium at the periphery of the ulcer with a cotton-tipped applicator after applying topical anesthetic revealed that the corneal epithelium was firmly adhered to the underlying stroma. The IOP remained within normal limits OU (13 mm Hg OS, 12 mm Hg OD). Multifocal linear lesions were still present in the peripheral medial retina OD but they had reduced in size. The anterior chamber OS remained at normal depth and the anterior and posterior inflammation OS had improved significantly. A mild amount of fibrin was present on the anterior lens capsule. The frequency of administration of ofloxacin (one drop OS q8h) and hyaluronan (one drop OU q6–8h) was increased. Diclofenac OD and meloxicam PO were discontinued.

On day 18, ophthalmic examination revealed that the corneal ulcer OS had resolved; however, a new axial ovoid <5mm superficial corneal ulcer was noted OD and the chorioretinal lesions OD were further reduced in size but still present. The ulcer was treated with ofloxacin (one drop OD q8h), hyaluronan (one drop OU q8h), and meloxicam (0.5 mg/kg PO q12h) for 7 days. By day 24, the corneal ulceration had resolved OD and the owl was discharged for rehabilitation without any medication.

The owl was reexamined on day 35. The IOP was within normal limits (14 mm Hg OS, 12 mm Hg OD). Trace flare was present but no hemorrhage or fibrin were observed in the anterior chamber OS. A small amount of fibrosis was present on the anterior lens capsule OS; however, the rest of the lens was normal. A pinpoint superficial corneal ulcer was present OD. This was suspected to be caused by trauma after being caught and it resolved after treatment with ofloxacin (one drop OU q8h) for 24 hours. Multifocal linear opacities were still present in the medial peripheral retina OD. Because of their peripheral location and small size, they were believed to be unlikely to interfere with vision.

The owl was discharged for rehabilitation and released 2 months later with no further ocular abnormalities. The release was delayed due to a talon injury in the rehabilitation enclosure.

### Discussion

This report describes a case of ocular hypertension in a western screech owl. Characteristic ocular signs as well as response to therapy suggest that ocular hypertension was caused by aqueous misdirection. Medical management was successful and the owl was rehabilitated and later released. To our knowledge, this is the first report of suspected aqueous misdirection and its medical management in a raptor.

In humans, glaucoma is defined as a group of ocular disorders united by a clinically characteristic optic neuropathy, with the primary site of injury at the optic nerve head.<sup>5-7</sup> Until the late 20th century, ocular hypertension was included in the definition of human glaucoma. However, since the recognition of glaucomatous optic neuropathy in the absence of raised IOP (“normotensive glaucoma”) and of ocular hypertension in the absence of glaucomatous optic neuropathy, raised IOP has been described an important risk factor rather than a defining characteristic for glaucoma in humans.<sup>5-7</sup> The applicability of these definitions in veterinary

medicine is debated even in species such as the dog, in which glaucoma is diagnosed relatively frequently and the pathophysiology is relatively better understood than in other nonhuman species. Dependence on a definition of glaucoma that requires observing optic nerve head morphology is particularly problematic in birds because the pecten prevents fundoscopic examination of all but a small section of the optic nerve head. Therefore, a greater reliance is placed upon ocular hypertension in association with reduced vision in avian species. Likely because of this, reported cases of glaucoma in captive and free-living raptors are infrequent and none of these cases has demonstrated optic neuropathy consistent with the current definition of glaucoma in humans.<sup>8-15</sup> In the case described here, mydriasis and absence of a direct pupillary light reflex OS were suggestive of an afferent or efferent defect. They were considered most likely to be caused by mechanical restriction of iris movement secondary to anterior lens displacement. However, without definitive evidence of changes to the optic nerve head or reduced visual acuity, cases such as this may be more accurately defined as ocular hypertension rather than glaucoma,<sup>6</sup> especially when the elevated IOP is transient.

In all species studied to date, ocular hypertension is invariably caused by impaired aqueous humor outflow rather than by hypersecretion.<sup>7,16</sup> In fact, classification of ocular hypertension and glaucoma according to the location of impedance to aqueous humor outflow is recommended.<sup>7</sup> As in mammals, the aqueous humor of birds is produced by the ciliary body and flows from the posterior to the anterior chamber via the pupil. Given the presence of anterior uveitis and the markedly shallow anterior chamber in this owl, potential mechanisms for ocular hypertension were considered to be altered aqueous humor flow within the trabecular meshwork (secondary to anterior uveitis) or at the pupil (caused by pupillary block), aqueous misdirection and expansion of the vitreous body (malignant glaucoma), or some combination of these mechanisms, as is often the case in cats.<sup>7</sup> Diagnosis of aqueous misdirection requires demonstrating a uniformly shallow anterior chamber secondary to anterior displacement of the lens-iris diaphragm, apparently intact lens zonules, and a narrowed approach to an otherwise open iridocorneal angle,<sup>17</sup> all of which were observed in this bird. The pathogenesis of aqueous misdirection is poorly understood but it is thought to involve a change in the anatomic relationship between the lens, ciliary body, anterior hyaloid face, and vitreous, resulting in posterior misdirec-

tion of aqueous humor, expansion of the vitreous body, and forward movement of the iris-lens diaphragm evident as a shallow anterior chamber.<sup>18</sup>

Assuming that aqueous misdirection was involved in the pathogenesis of the ocular hypertension seen in this bird, it is interesting to consider potential causes for this apparently transient change. Given the wild origin of this free-living western screech owl and the excellent response to therapy, the most likely inciting causes are trauma or infection, as reported sporadically in humans.<sup>19–22</sup> However, to our knowledge, aqueous misdirection or malignant glaucoma have not been reported in any avian species. More commonly, glaucoma in raptors is reported secondary to traumatic uveitis.<sup>8–10,12,14,15</sup> To our knowledge, there is a single case report of glaucoma associated with bacterial endophthalmitis in a raptor,<sup>14</sup> although bacterial, viral, fungal, and parasitic agents have been implicated as causes of uveitis in birds.<sup>15</sup> Other reported causes of glaucoma in raptors are traumatic iridodialysis and cyclodialysis<sup>13</sup>; neither of which was observed in the present case, and primary glaucoma,<sup>11</sup> which would not be permanently corrected with short-term medical therapy as was the case in the current report.

Reducing IOP is the main therapeutic goal for ocular hypertension and glaucoma because it improves comfort and maximizes chances for retention of vision, which is particularly important in free-living raptors that rely on their sense of vision to catch prey. Medical management of raised IOP often involves a combination of drugs that act to decrease aqueous humor production and increase aqueous humor outflow.<sup>23</sup> Mannitol was chosen in this owl because it is an osmotic agent that increases plasma osmolality, thereby promoting diffusion of water back into plasma from the intraocular fluids, especially the vitreous body. This lowers IOP by reducing vitreous body volume directly and impairing the ultrafiltration process that contributes to aqueous humor formation. Reducing vitreous body volume also permits posterior movement of the lens-iris diaphragm, thereby reducing pupillary block and opening the iridocorneal angle.<sup>23</sup> Intravenous administration of mannitol is widely recommended for emergency management of ocular hypertension and glaucoma in dogs and cats and typically results in IOP reduction within 30 to 60 minutes, with effects lasting 6 to 8 hours.<sup>23</sup> However, to our knowledge, use of mannitol for managing ocular hypertension and glaucoma in birds has not been reported. In the present case, 0.46 g/kg mannitol was adminis-

tered intravenously over 10 minutes. Forty minutes later, IOP in the affected eye had been reduced by 10 mm Hg (approximately 27%) but it was still 11 mm Hg higher than the upper value of the reference interval for normal eastern screech owls,<sup>2,3</sup> and 14 mm Hg higher than that in the opposite eye of this bird. The dose of mannitol used in the present case was lower than that recommended for dogs and cats and toward the lower end of the range suggested for treatment of cerebral edema associated with head trauma in many avian species (0.25–2 mg/kg).<sup>24</sup> A higher dose may have been more effective at reducing intraocular pressure to within normal limits. Although adverse effects of mannitol in raptors are not known, mannitol can cause hemolysis, hyperkalemia, hypotension, pulmonary edema, and renal insufficiency in humans<sup>25</sup> so its use may not be recommended in cases of reduced cardiac or renal function.

After initial emergency management, IOP control may be maintained with a combination of topical hypotensive drugs such as carbonic anhydrase inhibitors, cholinergic agents, adrenergic agonists or antagonists, and prostaglandin analogs.<sup>23</sup> To our knowledge, the only drug that has been reported for medical management of glaucoma in raptors is a carbonic anhydrase inhibitor.<sup>9</sup> Dichlorphenamide was administered orally to 2 raptors with suspected glaucoma at the dose rate used in dogs and buphthalmos resolved in one case.<sup>10</sup> Carbonic anhydrase inhibitors reduce IOP by reducing the availability of bicarbonate for aqueous humor production. Along with other agents that decrease aqueous humor production, they are considered to be the topical hypotensive agent of choice for malignant glaucoma as they reduce the volume of aqueous humor misdirected into the vitreous, and therefore reduce the forces pushing the lens-iris diaphragm anteriorly.<sup>17</sup> They can be administered orally; however, topical preparations are currently favored as they have fewer adverse effects.<sup>7,23,26</sup> Dorzolamide 2% applied topically has been shown to significantly reduce IOP when administered every 8 hours in dogs and every 12 hours in cats.<sup>27–30</sup> In this western screech owl, IOP decreased from 27 mm Hg 40 minutes after discontinuing mannitol therapy to 11 mm Hg 72 hours later, during which time 2% topical dorzolamide was being applied topically every 12 hours. However, the role of dorzolamide in this reduction is not known because IOP was not measured immediately before applying dorzolamide.

The main complication noted during management of this patient was repeated corneal ulceration believed to be secondary to trauma while being caught or perhaps associated with topical administration of eye medications. This prolonged the rehabilitation process by approximately 1 month. Corneal ulceration did not improve with initial topical antibiotic therapy but resolved rapidly after increasing the frequency of topical antibiotic administration and applying a topical lubricating eye solution. Treating corneal ulceration more aggressively early on and educating rehabilitators in safe handling and topical administration technique could have helped to reduce the time spent in rehabilitation before release.

The prognosis of ocular hypertension and glaucoma in wild raptors appears to be poor as reported cases are often euthanized.<sup>9,11,14</sup> This report of the use of ocular hypotensive and anti-inflammatory agents to manage acute ocular hypertension in a raptor demonstrates that medical management may be effective in select cases. Although a definitive diagnosis of aqueous misdirection was not made in this owl, a shallow anterior chamber due to anterior displacement of the lens-iris diaphragm, as well as a rapid correction of ocular hypertension and anterior chamber depth in response to mannitol and dorzolamide were highly supportive of this diagnosis. Medical management of raised IOP has been reported to be successful within a 5-day period in 50% of humans with malignant glaucoma<sup>18</sup> and in 18 cats with malignant glaucoma (approximately 66% of cats treated) in one case series.<sup>17</sup> Evaluation of further cases is required to understand the effectiveness of medical management of this condition in raptors. Before commencing medical treatment in a wild raptor, other factors that may affect the individual's survival on return to the wild must be considered. Releasability after medical treatment may depend on a variety of factors such as the degree of visual impairment at initial presentation, age of the bird, and concurrent systemic illness and injuries.<sup>31</sup>

### References

- Hogan MJ, Kimura SJ, Thygeson P. Signs and symptoms of uveitis. I. Anterior uveitis. *Am J Ophthalmol.* 1959;47(5):155–170.
- Harris MC, Schorling JJ, Herring IP, et al. Ophthalmic examination findings in a colony of screech owls (*Megascops asio*). *Vet Ophthalmol.* 2008;11(3):186–192.
- Labelle AL, Whittington JK, Breau CB, et al. Clinical utility of a complete diagnostic protocol for the ocular evaluation of free-living raptors. *Vet Ophthalmol.* 2012;15(1):5–17.
- Teare JA, ed. *Reference Ranges for Physiological Values of Captive Wildlife* [book on CD-ROM]. Eagen, MN: International Species Information System; 2002.
- Foster PJ, Buhrmann R, Quigley HA, Johnson GJ. The definition and classification of glaucoma in prevalence surveys. *Brit J Ophthalmol.* 2002;86(2):238–242.
- Casson RJ, Chidlow G, Wood JPM, et al. Definition of glaucoma: clinical and experimental concepts. *Clin Experiment Ophthalmol.* 2012;40(4):341–349.
- McLellan GJ, Miller PE. Feline glaucoma—a comprehensive review. *Vet Ophthalmol.* 2011;14(suppl 1):15–29.
- Murphy CJ, Kern TJ, McKeever K, et al. Ocular lesions in free-living raptors. *J Am Vet Med Assoc.* 1982;181(11):1302–1304.
- Buyukmihci NC. Lesions in the ocular posterior segment of raptors. *J Am Vet Med Assoc.* 1985;187(11):1121–1124.
- Chitty JR. Use of dichlorphenamide in two cases of glaucoma in owls. *Newsl Mid East Falc Res Group.* 1995;3:4–5.
- Rayment LJ, Williams D. Glaucoma in a captive-bred great-horned owl (*Bubo virginianus virginianus*). *Vet Rec.* 1997;140(18):481–483.
- Cousquer G. Ophthalmological findings in free-living tawny owls (*Strix aluco*) examined at a wildlife veterinary hospital. *Vet Rec.* 2005;156(23):734–739.
- Williams DL, Gonzalez-Villavicencio CM, Wilson S. Chronic ocular lesions in tawny owls (*Strix aluco*) injured by road traffic. *Vet Rec.* 2006;159(5):148–153.
- MacLaren NE, Krohne SG, Porter RE Jr, et al. *Corynebacterium* endophthalmitis, glaucoma, and scleral ossicle osteomyelitis in a great horned owl (*Bubo virginianus*). *J Zoo Wildl Med.* 1995;26(3):453–459.
- Bayón A, Almela RM, Talavera J. Avian ophthalmology. *Eur J Companion Anim Pract.* 2007;17(3):253–265.
- Reinstein SL, Rankin AJ, Allbaugh R. Canine glaucoma: pathophysiology and diagnosis. *Compend Contin Educ Vet.* 2009;31(10):450–452.
- Czederpiltz JMC, La Croix NC, van der Woerd A, et al. Putative aqueous humor misdirection syndrome as a cause of glaucoma in cats: 32 cases (1997–2003). *J Am Vet Med Assoc.* 2005;227(9):1434–1441.
- Shahid H, Salmon JF. Malignant glaucoma: a review of the modern literature. *J Ophthalmol.* 2012;2012:852659. doi:10.1155/2012/852659.
- Theelen T, Klevering BJ. Malignant glaucoma following blunt trauma of the eye. *Ophthalmologe.* 2005;102(1):77–81.
- Jones BR. Principles in the management of oculomycosis. *Am J Ophthalmol.* 1975;79(5):719–751.



21. Lass JH, Thoft RA, Bellows AR, Slansky HH. Exogenous *Nocardia asteroides* endophthalmitis associated with malignant glaucoma. *Ann Ophthalmol.* 1981;13(3):317–321.
22. Jain V, Maiti A, Shome D, et al. *Aspergillus*-induced malignant glaucoma. *Cornea.* 2007;26(6):762–763.
23. Willis AM. Ocular hypotensive drugs. *Vet Clin North Am Small Anim Pract.* 2004;34(3):755–776.
24. Carpenter JW. *Exotic Animal Formulary.* 4th ed. St Louis, MO: Elsevier Saunders; 2012.
25. Ziai WC, Toung TJK, Bhardwaj A. Hypertonic saline: first-line therapy for cerebral edema. *J Neurol Sci.* 2007;261(1–2):157–166.
26. van der Woerd A. The treatment of acute glaucoma in dogs and cats. *J Vet Emerg Crit Care.* 2001;11(3):199–204.
27. Cawrse MA, Ward DA, Hendrix DV. Effects of topical application of a 2% solution of dorzolamide on intraocular pressure and aqueous humor flow rate in clinically normal dogs. *Am J Vet Res.* 2001;62(6):859–863.
28. Sigle KJ, Camaño-Garcia G, Carriquiry AL, et al. The effect of dorzolamide 2% on circadian intraocular pressure in cats with primary congenital glaucoma. *Vet Ophthalmol.* 2011;14(suppl 1):48–53.
29. Rainbow ME, Dziezyc J. Effects of twice daily application of 2% dorzolamide on intraocular pressure in normal cats. *Vet Ophthalmol.* 2003;6(2):147–150.
30. Dietrich UM, Chandler MJ, Cooper T, et al. Effects of topical 2% dorzolamide hydrochloride alone and in combination with 0.5% timolol maleate on intraocular pressure in normal feline eyes. *Vet Ophthalmol.* 2007;10(suppl 1):95–100.
31. Pauli A, Klauss G, Diehl K, Redig P. Considerations for release of raptors with ocular disease. *J Exot Pet Med.* 2007;16(2):101–103.

## University of Miami Avian & Wildlife Laboratory

# Academic Based Avian and Exotic Diagnostic Services



### High quality and cutting edge diagnostic services:

- ▶ Routine and specialized avian hematology and chemistry
- ▶ *Chlamydophila*, *Sarcocystis*, *E.cuniculi* testing
- ▶ Active research program
- ▶ Specialists in electrophoresis and aspergillosis diagnostics.

### Highly responsive customer service:

- ▶ Special handling of low volume samples
- ▶ Online access and e-mail available for test results
- ▶ Express shipping program available
- ▶ 24 hour turnaround time for most tests.

Put more than 30 years of clinical research  
and diagnostics to work for you...  
and your patients!



**U MIAMI**  
**AVIAN & WILDLIFE LABORATORY**

Phone: 800.596.7390 or 305.243.6700

E-Mail: [compathlab@med.miami.edu](mailto:compathlab@med.miami.edu)

[www.cpl.med.miami.edu](http://www.cpl.med.miami.edu)