

# Differentiating Benign From Malignant Bone Marrow B-Cell Lymphoid Aggregates

## A Statistical Analysis of Distinguishing Features

Abbey Johnston, MD; Russell K. Brynes, MD; Kaveh Naemi, DO; Niloufar Reisian, MD; Deepty Bhansali, MD; Xiaohui Zhao, MD, PhD; Sherif A. Rezk, MD

• **Context.**—Lymphoid aggregates are seen in a minority of bone marrow biopsy specimens, and when present, their neoplastic nature is often apparent by morphologic evaluation. However, the distinction between benign and malignant aggregates can be a diagnostic challenge when there are multiple aggregates with no documented history of lymphoma.

**Objective.**—To aid in the distinction between benign and malignant B-cell lymphoid aggregates.

**Design.**—Previously, we described specific distribution patterns for B and T lymphocytes within bone marrow aggregates. To statistically analyze the significance of these patterns as well as previously reported criteria, we examined 128 bone marrow specimens with benign aggregates and 78 specimens with documented malignant

B-cell aggregates and calculated specific odds ratios (ORs) and 95% confidence intervals (CIs) to aid in differentiating between benign and malignant B-cell aggregates.

**Results.**—Aggregates with infiltrative edges (OR, 80.54; 95% CI, 31.76–204.21), a B-cell pattern (OR, 30.08; 95% CI, 13.28–68.10), paratrabeular location (OR, 10.17; 95% CI, 3.96–26.12), size greater than 600  $\mu\text{m}$  (OR, 6.83; 95% CI, 3.61–12.93), or cytologic atypia correlated with malignancy.

**Conclusions.**—When taken collectively, the presence of more than 2 of these characteristic features was strongly predictive of malignancy.

(*Arch Pathol Lab Med.* 2015;139:233–240; doi: 10.5858/arpa.2013-0678-OA)

Lymphoid aggregates are relatively uncommon in bone marrow biopsy specimens, and when present, their distinction from non-Hodgkin lymphoma, particularly B-cell lymphomas, can represent a diagnostic challenge. Criteria have been suggested in a limited number of studies to aid in that distinction. It has been reported that benign lymphoid aggregates tend to have a nonparatrabeular location, distinct borders without interstitial spillage of lymphoid cells, and are typically small ( $<600\ \mu\text{m}$ ).<sup>1,2</sup> Malignant characteristics of lymphoid aggregates include predominance of B cells, infiltrative edges, paratrabeular location, inclusion of fat cells, location surrounding large sinuses, and large aggregates.<sup>1–5</sup> Moreover, the loss of benign aggregates in deeper sections is considered a prominent indicator of a benign process.<sup>6,7</sup> In a previous study,<sup>8</sup> we demonstrated distinct immunomorphologic patterns of B and T cells in benign and malignant aggregates. Associations between these various characteristics, including the distribution patterns of B and T lymphocytes, and the risk of a B-cell lymphoma in patients who have these bone marrow findings, have not been quantified.

The presence of lymphoid aggregates in the bone marrow has been reported to be more frequently associated with certain conditions including aging, autoimmune diseases, inflammatory conditions, and infectious disorders.<sup>2,9</sup> They have also been reported to be commonly identified in patients with myeloproliferative neoplasms, especially primary myelofibrosis,<sup>4</sup> and rarely in association with myelodysplastic syndromes.<sup>10</sup> Moreover, an increased incidence of benign aggregates in patients with lymphoma who have been treated with rituximab has also been reported.<sup>11,12</sup> These aggregates are often found in postchemotherapy bone marrow specimens and can mimic residual lymphoma.<sup>12,13</sup> Lymphoid aggregates have also been rarely reported in association with tobacco use and certain medications.<sup>14,15</sup>

The use of ancillary studies, such as immunohistochemistry, flow cytometry, and molecular analysis, to assist in distinguishing between benign and malignant aggregates has been investigated before, although in a relatively limited fashion.<sup>15–18</sup> Previous studies<sup>13,19,20</sup> have used only a limited antibody panel, or have only investigated the distinction between benign lymphoid aggregates and follicular lymphoma. We have recently reported a detailed description of the distribution patterns of B and T lymphocytes within bone marrow lymphoid aggregates, and the diagnostic utility of recognizing these patterns.<sup>8</sup> In the current study, we extend our observations by examining the different morphologic and immunophenotypic characteristics of a large number of both benign and malignant bone marrow lymphoid aggregates and apply statistical tools to validate previously proposed criteria for the distinction between benign and malignant B-cell aggregates.

Accepted for publication March 20, 2014.

From the Departments of Pathology and Laboratory Medicine, University of California Irvine School of Medicine, Orange (Drs Johnston, Reisian, Bhansali, Zhao, and Rezk); the University of Southern California Keck School of Medicine, Los Angeles (Dr Brynes); and Pathology and Laboratory Medicine, University of California San Francisco Medical Center, San Francisco (Dr Naemi).

The authors have no relevant financial interest in the products or companies described in this article.

Reprints: Sherif A. Rezk, MD, Departments of Pathology and Laboratory Medicine, UCI Medical Center, 101 The City Dr, Bldg 54, Room 4702, Orange, CA 92868 (e-mail: srezk@uci.edu).

## MATERIALS AND METHODS

A search of the pathology files at University of California Irvine Medical Center in Orange, California, from 1993 to 2011 identified 206 bone marrow biopsy cases with reported lymphoid aggregates. A subset of these cases was used in a previous study.<sup>8</sup> All specimens were formalin fixed and included the trephine and/or the clot biopsy specimens. To be considered adequate, a minimum of 3 marrow spaces was required. In a few cases, tissue loss in deeper sections used for immunohistochemical staining was encountered. If the loss of tissue involved the lymphoid aggregates of interest, such cases were excluded from the study. Of all cases, 128 contained benign lymphoid aggregates, while 78 contained malignant B-cell lymphoid aggregates. The benign aggregates were defined from the original morphologic and immunophenotypic examination that included immunohistochemistry and/or flow cytometry testing. Flow cytometry was performed on 82 cases, and 28 cases had B-cell gene rearrangement studies performed by polymerase chain reaction (PCR). Furthermore, all specimens were further reviewed by us and additional stains were used for confirmation of diagnosis in a subset of the cases. Cases with malignant aggregates include 23 cases of chronic lymphocytic leukemia, 18 cases of follicular lymphoma, 8 cases of lymphoplasmacytic lymphoma, 7 cases of mantle cell lymphoma, 9 cases of marginal zone lymphoma, 2 cases of a splenic marginal zone lymphoma, and 11 cases of diffuse large B-cell lymphoma with nodular aggregates. Flow cytometry was performed on 64 cases and B-cell gene rearrangement studies by PCR on 3 cases.

A panel of immunostains was performed on all cases, which included CD3 (polyclonal 1:200; Dako, Carpinteria, California) and CD20 (L26, 1:400; Dako). CD79a (JCB117, 1:200; Dako) immunostaining was done on cases with a history of treatment by rituximab. In addition, other markers were used in select cases to further clarify and confirm the nature of the aggregates. These included bcl-6 (PG-B6p, 1:20; Dako), CD23 (MHM6, 1:200; Dako), PD-1 (MRQ-22, 1:100; Cell Marque, Rocklin, California), and Ki-67 (MIB-1, 1:1000; Dako), which were used for 88 cases to assess for the presence or absence of residual germinal centers. In addition, staining with CD43 (DF-T1, 1:400; Dako),  $\kappa$  (polyclonal, 1:50 000; Dako),  $\lambda$  (polyclonal, 1:40 000; Dako), CD10 (56C6, 1:150; Leica Microsystems, Buffalo Grove, Illinois), and bcl-2 (124, 1:200; Dako) was performed on select malignant cases to confirm the malignant nature of the aggregates. We analyzed the staining patterns of the lymphoid aggregates with regard to the relative distribution patterns of the lymphoid populations.

Histologic characteristics of the aggregates were retrospectively evaluated. These features included the presence of infiltrative edges, paratrabeular location, cytologic atypia, and size of lymphoid aggregates. Infiltrative edges were defined as lymphoid aggregates with poorly circumscribed margins and with lymphocytes at the edge extending into the surrounding interstitium. Assessment of infiltrative edges was best appreciated by using CD3/CD20 immunostains. Paratrabeular localization was defined as aggregates intimately opposed to the marrow bony trabeculae, while aggregates in close proximity to the bony trabeculae were excluded. Cytologic atypia included cells that exhibited open chromatin, irregular nuclear contours, prominent nucleoli, or karyorrhexis. Large aggregates included those greater than 600  $\mu$ m in greatest dimension. Lymphoid aggregates exhibiting a predominance of T cells, haphazard mixtures of B and T cells, or central cores of T cells surrounded by a rim of B cells were characteristic of a T-cell pattern as previously described.<sup>8</sup> Aggregates composed of predominantly B cells or central cores of B cells surrounded by T cells (excluding germinal center formation) were identified as B-cell patterns.<sup>8</sup> Cases with more than 1 pattern were categorized in accordance with the dominant pattern; however, the presence of a B-cell pattern was used to define a case. The cases were recorded as either exhibiting or not exhibiting these characteristics. Variables including age and sex were also examined.

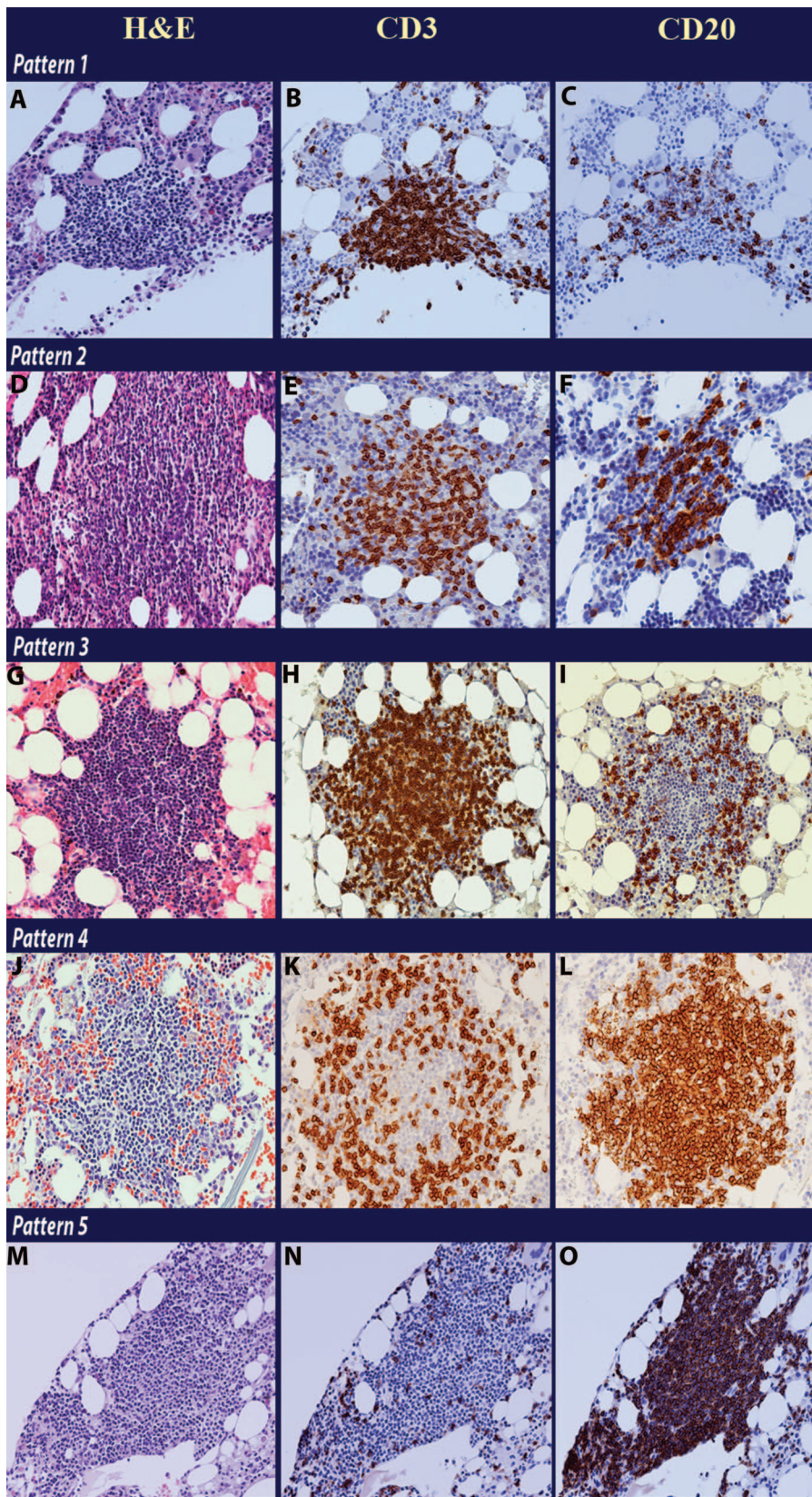
Follow-up information for patients with reactive lymphoid aggregates was available for 104 patients (81%) with a duration that varied from 1 year to 17 years. Thirty patients had 1-year

follow-up (29%), 22 patients had 2-year follow-up (21%), 24 patients had 3 to 5 years follow-up (23%), and 28 patients had more than 6 years follow-up (27%). Characteristics of the lymphoid aggregates were compared to the final benign or malignant diagnosis. The odds ratios (ORs) were calculated to assess the strength of the relationship between individual and combined characteristics, and the benign or malignant diagnoses. We further examined combinations of malignant characteristics to determine if multiple features were predictive of malignancy. The statistical difference between benign and malignant diagnoses with regard to each of 5 malignant characteristics was calculated by using the Pearson  $\chi^2$  test. After evaluating cases based solely on the number of malignant characteristics present, we examined the cases with regard to which malignant characteristics were present. These additional comparisons were evaluated with the Pearson  $\chi^2$  test. Furthermore, age and sex differences were also assessed. The statistical analyses were performed by using XLSTAT (version 2013.1.01, Addinsoft, Paris, France).

## RESULTS

Histologic and immunophenotypic characteristics of the aggregates were evaluated in all cases. The age range among the reactive cases was 12 to 99 years with a mean age of 57 years. This was similar to the age range of the malignant cases, which varied from 31 to 93 years with a mean age of 57 years. Females represented 54% of the reactive cases as opposed to 45% of the malignant cases ( $Z = 1.26$ ,  $P = .21$ ). Eighty-five of the benign cases (66%) and 76 malignant cases (97%) had aggregates present in the trephine biopsy sections, which permitted accurate evaluation for the presence of paratrabeular localization. The remaining cases contained aggregates only in the clot biopsy sections. Of the 128 benign cases, 101 cases (80%) displayed a T-cell pattern (34 cases with predominance of T cells, 50 cases with a mixture of T and B cells, and 18 cases with a core of T cells surrounded by B cells) (Figure 1, all panels). No residual germinal centers were identified in cases with a predominant B-cell pattern with bcl-6, CD23, and PD-1 stains. Forty benign cases (31%) contained large aggregates greater than 600  $\mu$ m and fewer than 15% of these cases had infiltrative edges or paratrabeular localization (Figure 2). No benign cases were found to have atypical lymphocytes. In contrast, for the malignant cases, B-cell patterns, infiltrative edges, and large size were the predominant characteristics (Table 1). Notably, more than 88% of the malignant cases had lymphoid aggregates with a B-cell pattern, while 85% of the cases exhibited infiltrative edge. The next highest percentage was for large aggregates at 76% of malignant diagnoses.

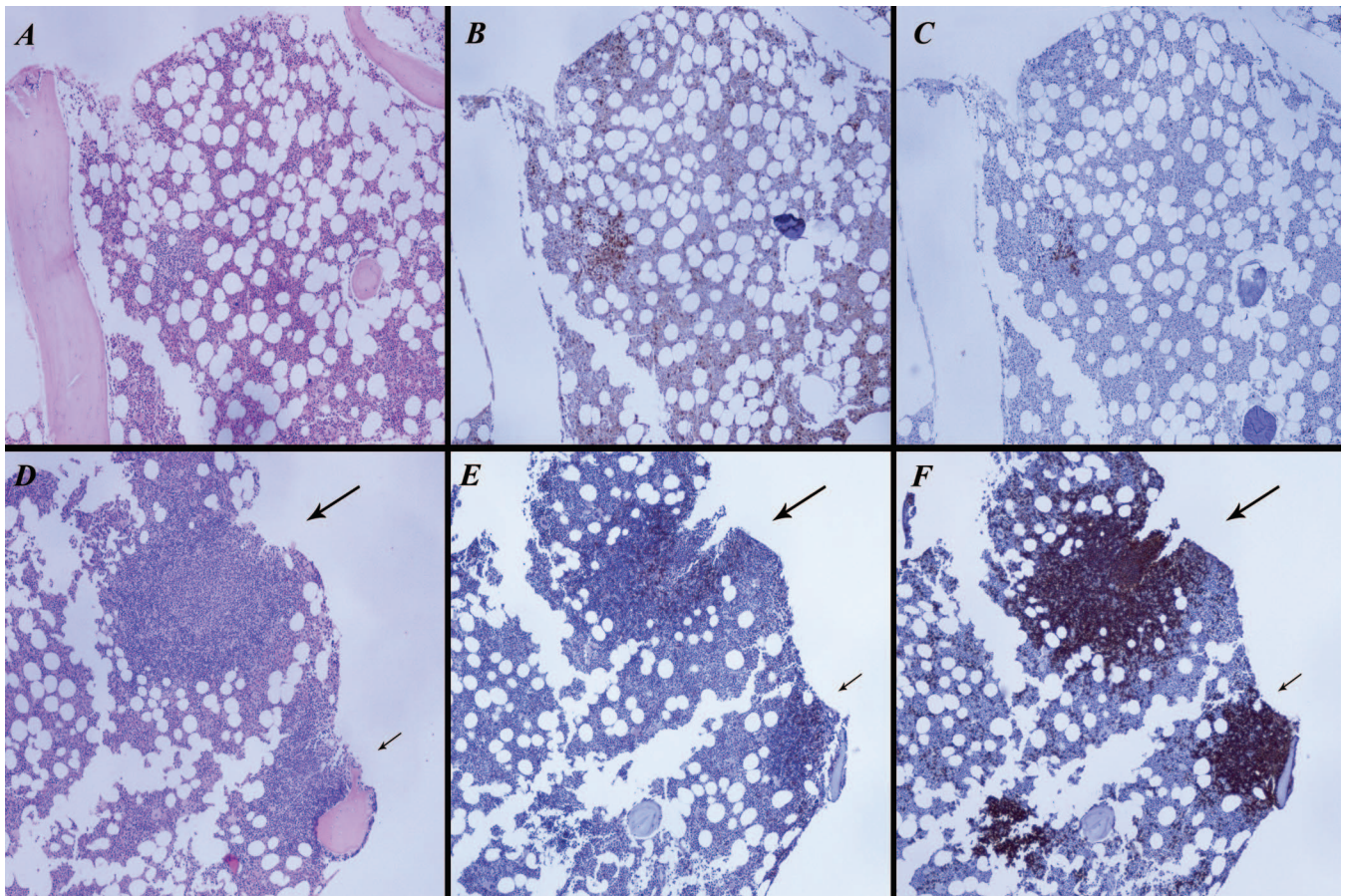
The ORs and 95% confidence intervals (CIs) for the presence of each characteristic were calculated and are listed in Table 2. The malignant cases had statistically greater odds of having each of the following characteristics: infiltrative edges, B-cell pattern, paratrabeular location, and large size. The highest ORs were found for infiltrative edges (OR, 80.54; 95% CI, 31.76–204.21) and B-cell patterns (OR, 30.08; 95% CI, 13.28–68.10). Malignant cases with T-cell patterns exhibited an OR of 0.03 and 95% CI of 0.01 to 0.08, indicating decreased odds of these patterns. The number of malignant lymphoid aggregate characteristics exhibited in each case was tallied. Seventy-three of the benign cases (57%) lacked malignant characteristics, whereas only 1 malignant case did not exhibit any of the malignant characteristics (Table 3). The percentage of malignant cases increased with addition of 1 or 2 characteristics (8.97% and 17.95%, respectively), and nearly a quarter of the cases exhibited 3, 4, or 5 characteristics each. The percentage of benign cases decreased with each



**Figure 1.** The composite picture shows the distribution patterns of CD3<sup>+</sup> T cells and CD20<sup>+</sup> B cells in bone marrow lymphoid aggregates. Pattern 1: hematoxylin-eosin (H&E) stain (A); CD3 shows predominance of T cells (B) and CD20 shows only scattered B cells (C). Pattern 2: H&E stain (D); a mixture of T and B lymphocytes haphazardly arranged are noted by CD3 (E) and CD20 (F) staining. Pattern 3: H&E stain (G); CD3 shows a core of T cells (H) surrounded by a rim of CD20<sup>+</sup> B cells (I). Pattern 4: H&E stain (J); a rim of CD3<sup>+</sup> T cells (K) is surrounding a central core of CD20<sup>+</sup> B cells (L). Pattern 5: H&E stain (M); CD3 shows rare T cells (N) and a predominance of CD20<sup>+</sup> B cells (O) (original magnification ×10 [A through O]).

additional characteristic, from 57.03% with no characteristics, to 25.00% with 1 characteristic, 15.63% with 2 characteristics, and only 2.34% with 3 characteristics. No benign cases exhibited 4 or 5 malignant characteristics (Table 3).

Cases with no or only 1 malignant characteristic were associated with benign diagnoses ( $\chi^2$  (1,N = 206) = 65.44,  $P$  < .001 and  $\chi^2$  (1,N = 206) = 8.11,  $P$  = .004, respectively). There was no significant difference between the number of



**Figure 2.** In the upper half of the composite figure, a small, well-circumscribed, nonparatrabeular lymphoid aggregate is identified on hematoxylin-eosin (H&E) stain (A), which consists predominantly of CD3<sup>+</sup> T cells (B) and scattered CD20<sup>+</sup> B cells (C). The morphologic appearance and the identification of a T-cell pattern by immunohistochemistry are consistent with a benign aggregate. In the lower half, 3 lymphoid aggregates are identified on H&E stain (D). All aggregates have infiltrative edges better appreciated with the CD20 stain, and the first aggregate is large (long arrow), while the second aggregate has a paratrabeular location (small arrow). Scattered CD3<sup>+</sup> cells are noted (E), while CD20 highlights most cells within the aggregates (F). The morphologic appearance and the identification of a B-cell pattern by immunohistochemistry are consistent with a malignant aggregate (original magnification  $\times 40$  [A through F]).

benign and malignant cases showing 2 malignant characteristics ( $\chi^2$  (1, N = 206) = 0.08,  $P = .78$ ). When lymphoid aggregates had 3 or more malignant characteristics, they were associated with malignant diagnoses ( $\chi^2$  (1, N = 206) = 28.45,  $P < .001$ ). The additive effect of characteristics was also evaluated on the basis of the strength of association with malignancy to see if it mattered which combination of characteristics was present. As the presence of a B-cell pattern was the characteristic found in the highest percentage of malignant cases (88.46%), we started with this feature, and then tallied the cases with a B-cell pattern

and infiltrative edges (the next highest percentage in the malignant cases at 85.90%) and so on. The results are shown in Table 4. Twenty-six benign cases had B-cell patterns but only 2 benign cases had a B-cell pattern and infiltrative edges. One of these 2 cases also contained a large aggregate and comes from a human immunodeficiency virus (HIV)-positive individual. Specimens from HIV-positive patients are summarized in Table 5. No benign cases had more than 3 malignant characteristics when evaluated in this order. Greater than 88% of malignant cases had a B-cell pattern, while 77% had both a B-cell pattern and infiltrative edges.

**Table 1. Characteristics of Lymphoid Aggregates According to Diagnosis**

Lymphoid Aggregate Characteristics	Benign Diagnosis		Malignant Diagnosis	
	No.	Percentage of Benign Cases	No.	Percentage of Malignant Cases
B-cell pattern	26	20.31	69	88.46
T-cell pattern	102	79.69	9	11.54
Infiltrative edges	9	7.03	67	85.90
Paratrabeular location <sup>a</sup>	6	7.06	34	97.43
Large size	40	31.25	59	75.64
Cytologic atypia	0	0.00	27	34.62

<sup>a</sup> Percentages for paratrabeular location were based on cases with trephine sections available (85 of 128 for benign cases and 76 of 78 for malignant cases).

Lymphoid Aggregate Characteristics	Odds Ratio	95% Confidence Interval
B-cell pattern	30.08	13.28–68.10
T-cell pattern	0.03	0.01–0.08
Infiltrative edges	80.54	31.76–204.21
Paratrabeular location	10.17	3.96–26.12
Large size	6.83	3.61–12.93
Cytologic atypia	NA <sup>a</sup>	NA <sup>a</sup>

Abbreviation: NA, nonapplicable.

<sup>a</sup> Odds ratio was not calculated for “atypia” because no benign cases exhibited this characteristic.

No. of Characteristics Identified	Bone Marrow Cases			
	Benign		Malignant	
	No.	Percentage	No.	Percentage
0	73	57.03	1	1.28
1	32	25.00	7	8.97
2	21	16.41	14	17.95
3	3	1.56	21	26.92
4	0	0.00	17	21.79
5	0	0.00	18	23.08

There were 23% of malignant cases with all 5 malignant characteristics. For every category of characteristics identified,  $\chi^2$  tests detected significant differences between the benign and malignant cases. Broad approximation of the ORs, relative strengths of associations among the characteristics, and statistical significance can be gleaned from these data. However, the 95% CIs for several of our ORs are wide, necessitating future examination of a larger cohort of bone marrow specimens to provide better approximations of the true OR. Some caution must also be used when interpreting our results as there may be a case selection bias. For cases to be included in our study, documentation of lymphoid aggregates had to be described in the report, which may have led to missing cases with lymphoid aggregates that were not documented.

### COMMENT

Although the identification of lymphoid aggregates in the bone marrow has been reported by some to be detected in up to 13% of older individuals,<sup>15,21</sup> it is overall a relatively uncommon finding in bone marrow biopsies.<sup>1,2</sup> Recently, we described distinct B- and T-lymphocyte distribution patterns in bone marrow lymphoid aggregates, where lymphoid

aggregates with a T-cell pattern (predominantly T cells, haphazard mixture of T and B cells, and centrally located T cells) were predictive of a benign process when correlated with the patient’s clinical features, diagnosis, and follow-up specimens, while the predominance of B cells or the presence of a central core of B cells surrounded by T cells was worrisome for malignancy.<sup>8</sup> In this study, we analyzed characteristics that have been reported to be useful in distinguishing benign from malignant B-cell lymphoid aggregates. Bone marrow specimens with malignant aggregates were found to have more than 30 times the likelihood of having a B-cell pattern in the lymphoid aggregates than bone marrows with benign aggregates (OR, 30.08; 95% CI, 13.28–68.10). The odds of having infiltrative edges were even greater (OR, 80.54; 95% CI, 31.76–204.21). Paratrabeular location and large aggregates were also significantly higher in the malignant bone marrows (Figure 2). As expected, a T-cell pattern had an OR below 1 (OR, 0.03; 95% CI, 0.01–0.08) indicating that T-cell patterns were closely associated with a benign diagnosis, rather than a malignant diagnosis.

From the hypothesis that increasing the number of malignant characteristics found in a case would be positively associated with malignancy, we found that cases displaying none of these characteristics were strongly associated with benign diagnoses. Surprisingly, cases with only 1 malignant characteristic were also strongly associated with benign diagnoses. The presence of 2 characteristics was frequently found in both benign and malignant cases and did not favor one diagnosis over the other. On the other hand, when 3 or more malignant characteristics were identified, nearly all the cases were malignant. This suggests that when evaluating lymphoid aggregates in the bone marrow, the presence of 2 characteristics should raise suspicion of malignancy but can be frequently seen in benign aggregates as well. The presence of 3 malignant characteristics is a reasonable threshold for raising a strong suspicion of malignancy. Also, when taking into account the relative strength of the ORs, certain characteristics, such as B-cell patterns and infiltrative edges, had stronger relationships with malignant cases than large size or paratrabeular location. In our data set, 7% of benign cases had infiltrative edges but only 2 benign cases had both a B-cell pattern and infiltrative edges, 1 of which was an HIV case. In contrast, 77% of the malignant cases had both of these characteristics. Therefore, considering which malignant characteristics are identified is critical in attempting to predict malignancy, especially when only 1 or 2 characteristics are present. Although paratrabeular location is one of the features that historically has been strongly suggestive of malignancy even on a stand-alone basis, 6 of 85 reactive cases with trephine biopsy sections in our study (7%) contained aggregates with a paratrabeular

Characteristics Identified	Bone Marrow Cases			
	Benign		Malignant	
	No.	Percentage	No.	Percentage
T-cell pattern	102	79.69	9	11.54
B-cell pattern	26	20.31	69	88.46
Infiltrative edges + B-cell pattern	2	1.56	60	76.92
Infiltrative edges + B-cell pattern + large size	1	0.78	50	64.10
Infiltrative edges + B-cell pattern + large size + paratrabeular location	0	0.00	27	34.62
Infiltrative edges + B-cell pattern + large size + paratrabeular location + cytologic atypia	0	0.00	18	23.08

**Table 5. Features of Cases With Human Immunodeficiency Virus (HIV) Infection**

Case No.	Age, y/Sex	Pattern	Infiltrative Edges	Paratrabeular Location	Cell Atypia	Size: Large	% of BM
1	26/M	4 (central core of B cells surrounded by T cells)	Yes	No	No	Yes	20
2	36/M	2 (mixture of B and T cells)	No	No	No		10
3	44/M	2 (mixture of B and T cells)	No	No	No	Yes	10
4	35/M	1 (predominance of T cells)	No	No	No		<5
5	33/F	2 (mixture of B and T cells)	No	NA	No		10
6	29/F	1 (predominance of T cells)	No	Yes	No		5
7	26/M	1 (predominance of T cells)	No	No	No		20
8	40/F	5 (predominance of B cells)	No	Yes (on deeper sections)	No	Yes	<10
9	37/M	2 (mixture of B and T cells)	Yes	No	No	Yes	15
10	52/M	2 (mixture of B and T cells)	No	No	No		5

Abbreviations: AIDS, acquired immunodeficiency syndrome; BM, bone marrow; ESRD, end-stage renal disease; GERD, gastroesophageal reflux disease; H&E, hematoxylin-eosin; ITP, idiopathic thrombocytopenic purpura; IV, intravenous; NA, nonapplicable; Neg, negative; NP, not performed; PCR, polymerase chain reaction; Pos, positive; TB, tuberculosis; †, increased; −, negative.

**Table 6. Features of Reactive Cases With Paratrabeular Lymphoid Aggregates**

Pattern	Infiltrative Edges	Paratrabeular Location	Cell Atypia	Size: Large	Associated Interstitial Lymphs	% of BM	PCR	
<b>Cases With True Paratrabeular Aggregates</b>								
1	5 (predominance of B cells)	No	Yes (on deeper sections)	No	Yes	No	<10	Pos
2	1 (predominance of T cells)	No	Yes	No	No	No	<5	Inconclusive
3	1 (predominance of T cells)	No	Yes	No	No	No	<10	Neg
4	2 (mixture of B and T cells)	No	Yes	No	No	No	<10	Neg
5	1 (predominance of T cells)	No	Yes	No	No	No	<10	Neg
6	2 (mixture of B and T cells)	Yes	Yes	No	Yes	No	<10	Inconclusive
<b>Cases With Lymphocytes Touching the Paratrabeular Bone</b>								
1	1 (predominance of T cells)	No	Yes	No	No	No	<5	Neg
2	1 (predominance of T cells)	No	Yes	No	No	No	<10	Neg
3	2 (mixture of B and T cells)	No	Yes	No	No	No	<5	Inconclusive

Abbreviations: BM, bone marrow; DM, diabetes mellitus; HIV, human immunodeficiency virus; ITP, idiopathic thrombocytopenic purpura; Neg, negative; NP, not performed; PCR, polymerase chain reaction; PET, positron emission tomography; Pos, positive.

**Table 5. Extended**

H&E	Flow			Diagnosis and Comments
	PCR	Cytometry	Follow-up	
2 ill-defined lymphohistiocytic aggregates with slightly ↑ interstitial T cells	NP	NP	Yes 17 y	Normal BM, HIV diagnosed 4 y prior. Follow-up shows ITP, hepatitis B, and glaucoma but no evidence of lymphoma. Patient current living status unknown.
Several ill-defined lymphoid aggregates but no infiltrative edges seen	NP	NP	Yes 2 y	Normal BM, HIV diagnosed 2 y prior. History of IV drug abuse and β-thalassemia trait. Follow-up for 2 y shows cerebral toxoplasmosis, cryptococcal meningitis but no evidence of lymphoma. Patient died 28 mo later from acute myocardial infarction.
2 large ill-defined lymphohistiocytic aggregates	NP	—	Yes 2 y	Normal BM, HIV diagnosed 7 y prior. Follow-up shows hepatitis C and brachial cleft cyst. BM 18 months later normal with 1 small aggregate. Patient living status unknown.
1 small well-defined lymphoid aggregate with slightly ↑ interstitial T cells	NP	NP	Yes 3 y	Normal BM, HIV diagnosed 1 y prior. History of hepatitis B and C and hepatosplenomegaly. Follow-up for 3 y shows staphylococcal infection with no evidence of lymphoma. Patient living status unknown.
2 small well-defined lymphoid aggregates	NP	—	Yes 13 y	Normal BM, HIV diagnosed 4 y prior. Follow-up for 13 y shows TB meningitis, seizures, B12 deficiency, and GERD but no lymphomas. Patient is alive till the present time.
1 small lymphoid aggregate with paratrabeular localization on deeper sections	Neg	—	Yes 9 y	Normal BM. History of HIV diagnosed 2 y prior and ITP. Follow-up BM after 2 y shows no aggregates. Follow-up for 9 y unremarkable with no lymphomas. Patient is alive till the present time.
Several ill-defined lymphohistiocytic aggregates, 1 with paratrabeular localization	NP	—	Yes 1 y	Normal BM. HIV diagnosed 2 y prior. Patient developed pneumocystis infection. Patient died within 11 mo from AIDS and sepsis.
2 large ill-defined lymphoid aggregates	Pos	NP	Yes 7 y	Patient with HIV, hepatitis C, and ITP. Axillary lymph node biopsy 2 y later showed multiple granulomas with no lymphoma. Flow cytometry findings were negative. Follow-up for 7 y shows cervical squamous cell carcinoma with no evidence of lymphoma. Patient is alive till the present time.
1 large ill-defined lymphohistiocytic aggregate	NP	—	Yes 1 y	Normal BM. HIV diagnosed 1 y prior. History of Burkitt lymphoma. Patient died of acute myeloid leukemia and sepsis 16 mo later.
1 small ill-defined lymphohistiocytic aggregate	NP	—	Yes 6 y	Markedly hypocellular BM. HIV diagnosed 1 y prior. Follow-up for 6 y shows hepatitis C, hemochromatosis, and ESRD. Patient died after 6 y from multiorgan failure.

**Table 6. Extended**

Flow Cytometry Available	Follow-up	Comments
<b>Cases With True Paratrabeular Aggregates</b>		
NP	Yes 7 y	40-y-old woman with HIV, hepatitis C, and ITP. Axillary lymph node biopsy 2 y later showed multiple granulomas with no lymphoma. Flow cytometry findings were negative. Follow-up for more than 7 y shows cervix squamous cell carcinoma and rectal carcinoma in situ with no evidence of lymphoma. Patient is alive till the present time.
NP	Yes 6 y	36-y-old man with aplastic anemia. Follow-up BM finding in 1 y is negative with no aggregates seen. Follow-up for 6 y shows no lymphoma.
NP	Yes 8 y	58-y-old woman with history of nodal mantle cell lymphoma a year prior. A previous BM finding a year prior was negative with no aggregates. CD79a test was performed. Follow-up for 8 y with several PET scans shows complete remission.
Neg	No 18 mo	78-y-old man with features of aplastic anemia including erythroid hypoplasia. Follow-up for 5 mo showed persistent anemia and upper gastrointestinal bleeding.
Neg	Yes 2 y	38-y-old woman with sciatica and neutropenia. The neutropenia was due to infectious mononucleosis (serology +). Follow-up for almost 2 y is completely negative.
Neg	Yes 5 y	70-y-old woman with history of splenic marginal zone lymphoma and splenectomy 5 y prior. Follow-up for nearly 2 y shows chronic kidney disease, DM, normal scan findings, and normal blood counts.
<b>Cases With Lymphocytes Touching the Paratrabeular Bone</b>		
Neg	Yes 9 y	73-y-old woman with history of nodal follicular lymphoma, treated with rituximab. Current BM showed only T cells paratrabeular. CD79a test was also performed. No bcl-2 staining was done given the near exclusive presence of T cells. 5 y later: relapsed follicular lymphoma involving BM.
Neg	Yes 5 y	29-y-old woman with history of HIV diagnosed 2 y prior and ITP. Follow-up BM test after 2 y shows no aggregates. Follow-up for 9 y unremarkable with no lymphomas. Patient is alive till the present time.
Neg	Yes	49-y-old man with history of orbital follicular lymphoma. Follow-up shows relapsed orbital diffuse large B-cell lymphoma after 5 y with negative BM findings. PET scan findings consistently negative elsewhere. Limited to orbital area with no lymphadenopathy.

location. Careful review of these cases showed no definitive evidence of malignancy. Table 6 shows detailed description of these 6 cases along with available follow-up information, and PCR and flow cytometry results. Additionally, information is included for 3 cases in our benign series that had nonparatrabeular lymphoid aggregates but in which some of the lymphocytes touched the paratrabeular bone. Touching of the bony by benign lymphoid aggregates without surrounding the entire paratrabeular space has been previously described.<sup>6</sup>

In bone marrow biopsies from HIV-positive patients, caution must be used not to overinterpret lymphoid aggregates. As others have noted, many of the previously described features that can be worrisome for malignancy, including increased size, poorly circumscribed margins, variable cytologic atypia, and a lymphohistiocytic pattern with no distinct granuloma formation, can be found in such patients.<sup>22–24</sup> Correlation with flow cytometry results can be helpful in such cases to detect a clonal population. Furthermore, correlation with the clinical presentation is extremely important, as these patients usually do not present with an isolated bone marrow process and if they present with a systemic lymphoma, it is usually a high-grade B-cell lymphoma, which should make the distinction in the bone marrow between a benign and malignant process less difficult. Table 5 shows the details of 10 HIV cases in our study with benign aggregates, where ill-defined margins, increased number of interstitial lymphocytes, and increased number of interspersed histiocytes were the notable morphologic features seen. The neoplastic lymphoid aggregates in Hodgkin lymphoma cases may also cause confusion, but usually contain a mixture of B and T lymphocytes or mainly T cells and are usually accompanied by a background of other inflammatory cells including eosinophils, plasma cells, and histiocytes in addition to Reed-Sternberg cells.<sup>5,15</sup> Sometimes granulomas are identified or evidence of increased background fibrosis is noted. In addition, benign lymphoid aggregates are occasionally seen in Hodgkin lymphoma.

In conclusion, assessment of 5 key morphologic and immunophenotypic features (large size, presence of infiltrative edges, paratrabeular localization, presence of cytologic atypia, and a B-cell distribution pattern) can help in the distinction between benign and malignant B-cell lymphoid aggregates in the bone marrow. We recommend careful morphologic examination and evaluation of CD3 and CD20 stains. The identification of more than 2 of the 5 characteristics was strongly suggestive of malignancy and was statistically associated with malignant diagnoses (Table 3). The presence of 2 malignant characteristics was frequently found in both benign and malignant cases and should still raise suspicion of malignancy, although it statistically did not favor one diagnosis over the other. There was significant association with benign diagnosis when only 1 or none of the characteristics was noted.

#### References

1. Foucar K, Viswanatha DS, Wilson CS. Non-neoplastic lymphoid and plasma cell disorders. In: King DW, ed. *Non-Neoplastic Disorders of Bone Marrow*. Washington, DC: American Registry of Pathology; 2008:249–282. *AFIP Atlas of Nontumor Pathology*; 1st series.

2. Thiele J, Zirbes TK, Kvasnicka HM, Fischer R. Focal lymphoid aggregates (nodules) in bone marrow biopsies: differentiation between benign hyperplasia and malignant lymphoma—a practical guideline. *J Clin Pathol*. 1999;52(4):294–300.

3. Brunning RD. Lesions simulating lymphoma and miscellaneous tumor-like lesions in the bone marrow. In: Brunning RD, ed. *Tumors of the Bone Marrow*. Washington, DC: American Registry of Pathology; 1994:409–437. *AFIP Atlas of Tumor Pathology*, 3rd series.

4. Franco V, Florena AM, Aragona F, Campesi G. Immunohistochemical evaluation of bone marrow lymphoid nodules in chronic myeloproliferative disorders. *Virchows Arch A Pathol Anat Histopathol*. 1991;419(4):261–266.

5. Nelson B. Bone marrow evaluation for lymphoma. In: Jaffe ES, Vardiman J, Campo E, Arber D, eds. *Hematopathology*. Philadelphia, PA: Elsevier Press; 2010: 887–917.

6. Salisbury JR, Deverell MH, Cookson MJ. Three-dimensional reconstruction of benign lymphoid aggregates in bone marrow trephines. *J Pathol*. 1996;178(4): 447–450.

7. Salisbury JR, Deverell MH, Seaton JM, Cookson MJ. Three-dimensional reconstruction of non-Hodgkin's lymphoma in bone marrow trephines. *J Pathol*. 1997;181(4):451–454.

8. Naemi K, Brynes RK, Reisman N, et al. Benign lymphoid aggregates in the bone marrow: distribution patterns of B and T lymphocytes. *Hum Pathol*. 2013; 44(4):512–520.

9. Engels K, Oeschger S, Hansmann ML, Hillebrand M, Kriener S. Bone marrow trephines containing lymphoid aggregates from patients with rheumatoid and other autoimmune disorders frequently show clonal B-cell infiltrates. *Hum Pathol*. 2007;38(9):1402–1411.

10. Magalhaes SM, Filho FD, Vassallo J, Pinheiro MP, Metzke K, Lorand-Metze I. Bone marrow lymphoid aggregates in myelodysplastic syndromes: incidence, immunomorphological characteristics and correlation with clinical features and survival [discussion in *Leuk Res*. 2002;26(6):531]. *Leuk Res*. 2002;26(6):525–530.

11. Douglas VK, Gordon LI, Goolsby CL, White CA, Peterson LC. Lymphoid aggregates in bone marrow mimic residual lymphoma after rituximab therapy for non-Hodgkin lymphoma. *Am J Clin Pathol*. 1999;112(6):844–853.

12. Raynaud P, Caulet-Maugendre S, Foussard C, et al. T-cell lymphoid aggregates in bone marrow after rituximab therapy for B-cell follicular lymphoma: a marker of therapeutic efficacy? *Hum Pathol*. 2008;39(2):194–200.

13. West RB, Warnke RA, Natkunam Y. The usefulness of immunohistochemistry in the diagnosis of follicular lymphoma in bone marrow biopsy specimens. *Am J Clin Pathol*. 2002;117(4):636–643.

14. Demoor T, Bracke KR, Maes T, et al. Role of lymphotoxin-alpha in cigarette smoke-induced inflammation and lymphoid neogenesis. *Eur Respir J*. 2009;34(2): 405–416.

15. Foucar K. Non-neoplastic disorders of lymphoid cells. In: Foucar K, Czuchlewski D, eds. *Bone Marrow Pathology*, 3rd ed. Chicago, IL: ASCP Press; 2010:449–473.

16. Ben-Ezra J, Hazelgrove K, Ferreira-Gonzalez A, Garrett CT. Can polymerase chain reaction help distinguish benign from malignant lymphoid aggregates in bone marrow aspirates? *Arch Pathol Lab Med*. 2000;124(4):511–515.

17. Ben-Ezra JM, King BE, Harris AC, Todd WM, Kornstein MJ. Staining for Bcl-2 protein helps to distinguish benign from malignant lymphoid aggregates in bone marrow biopsies. *Mod Pathol*. 1994;7(5):560–564.

18. Bluth RF, Casey TT, McCurley TL. Differentiation of reactive from neoplastic small-cell lymphoid aggregates in paraffin-embedded marrow particle preparations using L-26 (CD20) and UCHL-1 (CD45RO) monoclonal antibodies. *Am J Clin Pathol*. 1993;99(2):150–156.

19. Chetty R, Echezarreta G, Comley M, Gatter K. Immunohistochemistry in apparently normal bone marrow trephine specimens from patients with nodal follicular lymphoma. *J Clin Pathol*. 1995;48(11):1035–1038.

20. Torlakovic E, Torlakovic G, Brunning RD. Follicular pattern of bone marrow involvement by follicular lymphoma. *Am J Clin Pathol*. 2002;118(5):780–786.

21. Girodon F, Favre B, Carli PM, et al. Minor dysplastic changes are frequently observed in the bone marrow aspirate in elderly patients without hematological disease. *Clin Lab Haematol*. 2001;23(5):297–300.

22. Delacretaz F, Perey L, Schmidt PM, Chave JP, Costa J. Histopathology of bone marrow in human immunodeficiency virus infection. *Virchows Arch A Pathol Anat Histopathol*. 1987;411(6):543–551.

23. Karcher DS, Frost AR. The bone marrow in human immunodeficiency virus (HIV)-related disease: morphology and clinical correlation. *Am J Clin Pathol*. 1991;95(1):63–71.

24. Ricci D, Ponzoni M, Zoldan MC, Germagnoli L, Faravarelli A. Bone marrow biopsy in 50 AIDS patients: a diagnostic approach. *Pathologica*. 1995; 87(6):640–645.