

# UC Davis

## UC Davis Previously Published Works

### Title

Topical Ripasudil for the Treatment of Primary Corneal Endothelial Degeneration in Dogs

### Permalink

<https://escholarship.org/uc/item/1pn5j528>

### Journal

Translational Vision Science & Technology, 11(9)

### ISSN

2164-2591

### Authors

Michalak, Sarah R  
Kim, Soohyun  
Park, Sangwan  
et al.

### Publication Date

2022-09-01

### DOI

10.1167/tvst.11.9.2

Peer reviewed

# Topical Ripasudil for the Treatment of Primary Corneal Endothelial Degeneration in Dogs

Sarah R. Michalak<sup>1</sup>, Soohyun Kim<sup>1</sup>, Sangwan Park<sup>1</sup>, M. Isabel Casanova<sup>1</sup>, Morgan A. W. Bowman<sup>1</sup>, Michelle Ferneding<sup>1</sup>, Brian C. Leonard<sup>1</sup>, Kathryn L. Good<sup>1</sup>, Jennifer Y. Li<sup>2</sup>, and Sara M. Thomasy<sup>1,2</sup>

<sup>1</sup> Department of Surgical and Radiological Sciences, School of Veterinary Medicine, University of California Davis, Davis, California, USA

<sup>2</sup> Department of Ophthalmology & Vision Science, School of Medicine, University of California Davis, Davis, California, USA

**Correspondence:** Sara M. Thomasy, Department of Surgical and Radiological Sciences, School of Veterinary Medicine, 1 Shields Ave., University of California, Davis, CA 95616, USA.  
e-mail: [smthomasy@ucdavis.edu](mailto:smthomasy@ucdavis.edu)

**Received:** April 5, 2022

**Accepted:** August 3, 2022

**Published:** September 1, 2022

**Keywords:** canine; corneal endothelium; Fuchs endothelial corneal dystrophy (FECD); Rho associated kinase inhibitor (ROCK); ripasudil

**Citation:** Michalak SR, Kim S, Park S, Casanova MI, Bowman MAW, Ferneding M, Leonard BC, Good KL, Li JY, Thomasy SM. Topical ripasudil for the treatment of primary corneal endothelial degeneration in dogs. *Transl Vis Sci Technol.* 2022;11(9):2, <https://doi.org/10.1167/tvst.11.9.2>

**Purpose:** The purpose of this study was to evaluate the tolerability and efficacy of topical rho-kinase inhibitor ripasudil in the treatment of primary corneal endothelial degeneration (PCED) in dogs.

**Methods:** Twenty-one eyes of 12 client-owned, PCED-affected dogs received topical ripasudil 4 times daily. Ophthalmic examination, ultrasonic pachymetry (USP), Fourier-domain optical coherence tomography (FD-OCT), and in vivo confocal microscopy were performed at baseline and 1, 3, 6, and 12 months. Effects of treatment on corneal thickness, corneal edema extent, and endothelial cell density (ECD) were evaluated by repeated-measures ANOVA or Friedman test. Individual eyes were classified as improved, progressed, or stable at 12 months using clinical response criteria. Kaplan-Meier curves and log-rank test were used to compare ripasudil-treated eyes to age-, breed/size-, and disease stage-matched historical controls.

**Results:** During treatment, 12 dogs developed conjunctival hyperemia, 4 demonstrated reticular bullous epithelial edema, and 2 developed corneal stromal hemorrhage. No adverse event necessitated permanent cessation of ripasudil. Central corneal thickness measured by USP significantly progressed from baseline to 12 months. Corneal thickness by FD-OCT, ECD, and edema extent did not differ over time. Considered individually, 5 eyes improved, 8 remained stable, and 8 progressed. The log-rank test found less edema progression in ripasudil-treated eyes compared to historical controls.

**Conclusions:** Ripasudil was well-tolerated in PCED-affected dogs. Response to therapy varied; 62% of eyes showed improved or stable disease whereas 38% progressed. Ripasudil-treated eyes progressed more slowly than historical controls.

**Translational Relevance:** Topical ripasudil offered a therapeutic benefit in a subset of patients using a canine model of endothelial degeneration, which may guide future trials in humans.

## Introduction

Corneal endothelial cells play a critical role in the preservation of corneal deturgescence and transparency through barrier function and active ion transport processes.<sup>1</sup> Corneal endothelial damage may result from surgical injury, trauma, ocular hypertension, anterior uveitis, and heritable conditions, such as endothelial dystrophies.<sup>2</sup> Fuchs' endothelial corneal dystrophy (FECD) is the most common endothelial

dystrophy in humans, affecting up to 4% of the US population over 40 years of age.<sup>3</sup> Patients with FECD exhibit progressive loss of corneal endothelial cells, resulting in guttae in early stages and edema, scarring, and significant visual impairment once a critically low endothelial cell density (ECD) is reached.<sup>2</sup>

Corneal endothelial degeneration in human patients is frequently treated with penetrating or lamellar corneal transplantation.<sup>4,5</sup> In recent years, graft-sparing techniques, such as Descemet's stripping only (DSO), and cell-based therapies have gained

considerable attention in the treatment of FECD in a subset of patients.<sup>6–10</sup> The use of Rho-associated kinase (ROCK) inhibitors, such as ripasudil, a ROCK inhibitor approved for the treatment of glaucoma and ocular hypertension in Japan, may expand the role of graft-sparing techniques in the treatment of corneal endothelial degeneration. Rho kinase is a downstream effector of Rho guanosine triphosphate that modulates cell adhesion, cell morphology, extracellular matrix organization, membrane permeability, actomyosin contractility, and DNA synthesis.<sup>11–16</sup> Various ROCK inhibitors, including ripasudil and Y-27632, have been shown in vitro and in ex vivo tissue models to promote corneal endothelial cell proliferation and adhesion<sup>17,18</sup> and to inhibit apoptosis of corneal endothelial cells.<sup>17–19</sup> In vivo studies using rabbit, canine, and non-human primate corneal wound models have demonstrated that ROCK inhibitors enhance corneal endothelial wound healing, improve corneal transparency, and reduce corneal thickness after injury.<sup>17,20,21</sup>

Although numerous studies have demonstrated success using ROCK inhibitors in the treatment of FECD as an adjuvant to DSO or after transcorneal freezing,<sup>6,7,22,23</sup> few studies have explored the use of ROCK inhibitors for the treatment of corneal endothelial degeneration without endothelial denudation. The lack of corneal donor tissue in many parts of the world necessitates investigation of pharmacologic and cell-based therapies for endothelial degeneration initially in animal models followed by clinical trials in human patients. Spontaneous, primary corneal endothelial degeneration (PCED) has been described in dogs and has been characterized as breed-related and presumptively heritable<sup>24,25</sup> or age-related.<sup>26,27</sup> The breed-related condition known as corneal endothelial dystrophy is an adult-onset, bilateral disease that results in primary degeneration of the corneal endothelium. It has been established as a spontaneous model for FECD based on the presumed heritability and shared clinical and histologic features.<sup>24,25</sup> Both dogs and humans can also experience age-related degeneration of the corneal endothelium due to the limited proliferative capacity of corneal endothelial cells.<sup>26–28</sup> Dogs have been shown to have an endothelial cell proliferative capacity intermediate between non-human primates and rabbits based on corneal wound healing models,<sup>20,29,30</sup> making dogs an appropriate model for assessing therapies for corneal endothelial diseases. Thus, the purpose of this pilot study is to evaluate the tolerability and efficacy of the topical ROCK inhibitor ripasudil for the treatment of corneal endothelial degeneration in a canine model through a prospective, open-label clinical trial with additional comparison to untreated historical controls.

## Materials and Methods

### Animals

This study was approved by the Institutional Animal Care and Use Committee of the University of California - Davis (#19568) and performed according to the Association for Research in Vision and Ophthalmology resolution on the use of animals in research. Prior to study entry, informed consent was obtained for dogs with a presumptive diagnosis of PCED assigned by board-certified veterinary ophthalmologists from the University of California - Davis Veterinary Medical Teaching Hospital and other specialty hospitals in California and Nevada between November 2018 and February 2020. Baseline ophthalmic examination, ultrasonic pachymetry (USP), Fourier-domain optical coherence tomography (FD-OCT), and in vivo confocal microscopy (IVCM) were performed to confirm the diagnosis of PCED. Dogs with evidence of moderate to marked endothelial cell pleomorphism and polymegathism on IVCN and an ECD  $<1700$  cells/mm<sup>2</sup> with or without corneal edema were included. Dogs with secondary causes of endothelial disease or corneal edema, including glaucoma, anterior uveitis, corneal ulceration, lens instability, or trauma, were excluded. Individual eyes were further characterized at baseline as having mild disease or moderate to severe disease based on the extent of corneal edema. Eyes with  $<40\%$  of the corneal surface affected by edema were classified as having mild disease, whereas eyes with  $>40\%$  of the corneal surface affected by edema were classified as having moderate to severe disease.

### Treatment

After enrollment, owners applied one drop of topical ripasudil hydrochloride hydrate (Glanatec ophthalmic solution 0.4%; Natural Pharmacy, Osaka, Japan) in affected eyes four times daily during the study period. Owners recorded the times of administration on a medication log. Dogs with moderate to severe corneal edema or corneal bullae were prescribed hypertonic saline ophthalmic ointment as deemed necessary by the examiner. Any additional medications required for the management of concurrent diseases were noted for all dogs.

### Clinical Evaluation and Ophthalmic Imaging

Before and at 1, 3, 6, and 12 months after initiating treatment with ripasudil, all eyes underwent

complete ophthalmic examination, including digital slit-lamp biomicroscopy (Imaging Module IM 900; Haag Streit, Koeniz, Switzerland), handheld slit-lamp biomicroscopy (SL-15; Kowa American Corporation, Torrance, CA), binocular indirect ophthalmoscopy (Keeler Instruments Inc., Broomall, PA) using a 28 diopter (D) indirect lens (Volk Optical, Inc., Mentor, OH), and Schirmer tear-test 1 (STT1; Intervet, Inc., Summit, NJ). Central, nasal, temporal, superior, and inferior corneal thickness was measured using USP (Pachette 3; DGH Technology, Inc., Exton, PA), as previously described.<sup>24,25</sup> Intraocular pressures (IOPs) were measured by rebound tonometry (TonoVet; Icare Finland). Adverse events identified on examination were recorded and described using the semiquantitative preclinical ocular toxicology scoring (SPOTS) system.<sup>31</sup> Animals were placed in sternal recumbency, and FD-OCT (RTVue 100, software version 6.1, 26000 A scan/sec, 5- $\mu$ m axial resolution, 840-nm superluminescent diode, Optovue, Inc., Fremont, CA) and IVCN (ConfoScan 4 Nidek Technologies, Gamagori, Japan; HRT3 Heidelberg Engineering, Franklin, MA) of the central cornea were performed using previously described methods.<sup>24,25,32</sup> Intravenous sedation was administered as needed for imaging. Last, corneas were stained with fluorescein sodium (Ful-Glo strips USP 1 mg; Akorn Inc.) to assess for corneal ulceration.

Central corneal thickness (CCT) and the thickness of the epithelium, stroma, and Descemet's membrane (DM)-endothelium complex measurements were obtained from FD-OCT images using the RTVue measuring tool. Corneal ECD was measured from IVCN scans using the ConfoScan 4 NAVIS imaging software, as described previously.<sup>24,25</sup> An area of interest of 0.05 mm<sup>2</sup> or greater was used to determine the ECD using the average of 3 images per eye. The percentage of cornea affected by edema was estimated using digital photographs at each time point and image analysis software (ImageJ, <http://www.rsbweb.nih.gov/ij/>). The image analyst was masked to both the identity of the dog and the time during the treatment course at which all images were obtained.

### Clinical Response Criteria

Due to variability in disease severity and response to therapy, individual eyes were also classified as improved, progressed, or stable at the final time point using defined clinical response criteria based on changes in corneal edema, ECD, and corneal thickness compared to baseline. Eyes were considered improved if they demonstrated >10% increase in ECD, >10% decrease in percentage of cornea affected by edema,

and/or >20% decrease in CCT. Eyes were considered progressed if they demonstrated >10% decrease in ECD, >10% increase in percentage of cornea affected by edema, and/or >20% increase in CCT. Eyes that did not meet criteria for improved nor progressive disease were characterized as stable.

For CCT, the cutoff of 20% was selected based on a previous study that showed a mean diurnal percentage of variation ( $\pm$  standard deviation) in CCT of  $7.5 \pm 4.5\%$  in beagle dogs,<sup>33</sup> making a change >20% unlikely to occur by factors such as time measured. The cutoffs of 10% change for ECD and extent of the cornea affected by edema were chosen based on a longitudinal study in Boston Terriers with breed-related corneal endothelial dystrophy, which demonstrated a significant change in mean ECD of 13% over  $11.8 \pm 1.2$  months and a significant change in mean corneal edema extent of 13% over  $10.7 \pm 1.4$  months.<sup>24</sup>

### Owner Survey

Owner surveys were conducted at the 12-month time point after the initiation of therapy with ripasudil. Owners estimated their dog's vision (1 = poor through 10 = excellent) and corneal cloudiness (1 = mild to 10 = severe) before and after treatment with topical ripasudil. The survey asked owners to recall any side effects they attributed to topical ripasudil. Owners reported if they believed their pet's quality of life had changed since the initiation of therapy, if they thought the treatment was cost effective, if they were satisfied with the treatment, and if they would recommend this treatment to other dogs affected with PCED.

After completion of the study period, owners were offered the option to continue ripasudil therapy. Surgical intervention with superficial keratectomy and conjunctival advancement hood flap was recommended in dogs with significant disease progression.

### Comparison to Historical Controls

Canine cases of corneal endothelial dystrophy/degeneration from the University of California - Davis Veterinary Medical Teaching Hospital (1991–2014) published in a retrospective study by Leonard et al. were used as historical controls to compare the progression of PCED-affected eyes with and without topical ripasudil therapy.<sup>34</sup> The medical record data collected for the retrospective study were obtained, which included age, breed, weight, sex, and ophthalmic examination and diagnostic findings. Inclusion criteria consisted of a clinical diagnosis of corneal endothelial dystrophy/degeneration by a board-certified veterinary ophthalmologist or resident and a supporting

description of corneal edema as part of the ophthalmic examination. Patients were excluded if they had a history of intraocular surgery, chronic anterior uveitis, glaucoma, anterior lens luxation, and/or glaucoma. Because all control dogs demonstrated at least one eye with corneal edema as part of the inclusion criteria, dogs in the ripasudil treatment group with bilaterally compensated disease (lacking corneal edema bilaterally) were excluded from this analysis. Based on the gathered information from the medical records, each ripasudil-treated eye was matched with an eye from the retrospective study with similar age, breed/size, and severity corneal edema at baseline to include in comparative analysis. Controls were selected based on signalment and baseline disease stage alone without knowledge of progression at the time of selection. Ripasudil-treated and control eyes were further classified using the previously described corneal edema progression criteria by Leonard et al.<sup>34</sup> Progression criteria were described as follows: “Criterion 1: Eyes recorded as having clear (non-edematous) corneas during the first visit, but showed signs of CED in the contralateral globe, subsequently progressing to any degree of corneal edema in the unaffected globe at later visits. Criterion 2: Eyes recorded as having mild corneal edema during the first visit and subsequently progressing to severe corneal edema at later visits. Criterion 3: Eyes recorded as having focal corneal edema during the first visit and subsequently progressing to diffuse corneal edema in later visits.” Kaplan-Meier curves were generated to demonstrate time to corneal edema progression for each group, defined as the time from initial examination to when an eye met any of the three progression criteria. If any eye met more than one criterion of progression, the shortest time to progression was used.

## Statistical Analysis

Differences in corneal thickness, extent of corneal edema, and ECD across time points were evaluated by repeated measures ANOVA or Friedman test for Gaussian and non-Gaussian data, respectively. For the extent of corneal edema, percentages were transformed using the arcsine transformation for statistical analysis. Normality was determined for each data set by the Anderson-Darling test for normality. Post hoc tests were performed using Wilcoxon signed ranks. For analysis comparing eyes from the current study to historical controls, a log-rank test was performed to assess for differences in distribution of corneal edema progression between the two groups. For all analyses, a *P* value of < 0.05 was considered significant.

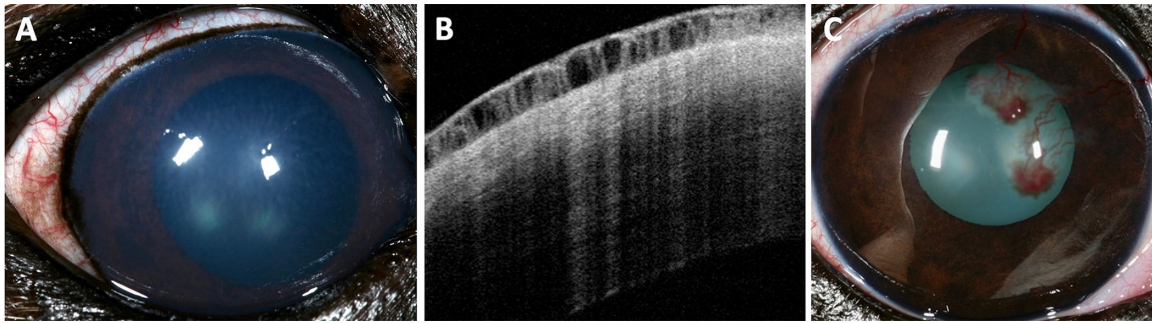
## Results

### Study Population

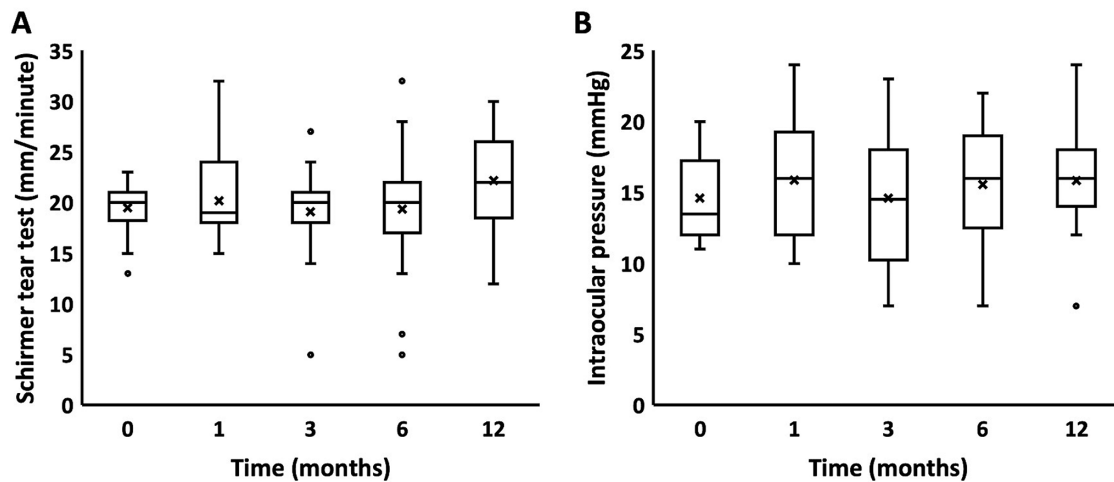
Twenty-one eyes of 12 PCED-affected dogs were included in the study and examined before and at mean  $\pm$  standard deviation  $1.4 \pm 0.4$ ,  $3.6 \pm 0.5$ ,  $6.6 \pm 1.7$ , and  $12.9 \pm 1.0$  months after initiating treatment with ripasudil. The study population consisted of four Boston terriers, one Jack Russell terrier, one Australian terrier, one keeshond, one West Highland white terrier, and four small mixed breed dogs. The three eyes not included in the study were enucleated prior to enrollment. Age at enrollment ranged from 4 to 13 years with a mean age of 10 years. Five dogs, the Boston terriers and Jack Russell terrier, were presumed to have corneal endothelial dystrophy based on breed and age of onset, whereas the remaining seven dogs were diagnosed with age-related endothelial degeneration. Eleven eyes were characterized as having mild disease at baseline, and 10 eyes were characterized as having moderate to severe disease at baseline based on the extent of corneal edema. Nine eyes of seven dogs concurrently received topical hypertonic saline ointment (Muro 128, Sodium chloride hypertonicity ophthalmic ointment 5%, Bausch & Lomb Incorporated, Laval, Quebec, Canada) during the treatment period. Two of nine eyes that received topical hypertonic saline were classified as mildly affected at baseline, and the remaining eyes receiving hypertonic saline were classified as moderate to severely affected at baseline.

### Tolerability

Topical ripasudil was well-tolerated throughout the treatment period with the most common adverse events being conjunctival hyperemia, which occurred in twenty eyes of twelve dogs, reticular bullous epithelial edema in four eyes of four dogs, and corneal stromal hemorrhage in four eyes of two dogs (Fig. 1). The conjunctival hyperemia occurred bilaterally in all dogs with two eyes aside from one dog, in which conjunctival hyperemia developed unilaterally. Most dogs developed only mild and often transient conjunctival hyperemia. Corneal stromal hemorrhage occurred bilaterally in both affected dogs, and both dogs had corneal neovascularization prior to starting ripasudil therapy. Reticular bullous epithelial edema occurred unilaterally in all four dogs and was not consistently observed at each visit despite continuation of ripasudil. No adverse event necessitated permanent cessation of ripasudil, and only three dogs required short-term treatment with a topical anti-inflammatory (neomycin sulfate,



**Figure 1.** Representative images demonstrating adverse events observed after initiation of therapy with topical ripasudil in three dogs. **(A)** A digital photograph of conjunctival hyperemia in the right eye of a 10-year-old male castrated keeshond, 1 month after starting topical ripasudil. **(B)** A Fourier-Domain optical coherence tomography image demonstrating reticular bullous epithelial edema in an 11-year-old male castrated Boston terrier, 3 months after starting topical ripasudil. **(C)** A digital photograph of focal corneal stromal hemorrhage in a 12-year-old female spayed Boston terrier, 1 month after starting topical ripasudil. This patient had pre-existing corneal neovascularization bilaterally.



**Figure 2.** No significant differences in tear production or intraocular pressure (IOP) were found across time points in PCED-affected dogs treated with topical ripasudil. **(A)** Schirmer tear test-1 results and **(B)** IOPs at baseline and at 1, 3, 6, and 12 months after initiating therapy with topical ripasudil. *Box plots* depict median, mean (X), and 25th and 75th percentiles. *Whisker plots* show maximum and minimum values. *Circles* indicate outliers. No significant differences were found using 1-way repeated measures ANOVA. Twenty-one eyes were included in the analysis.

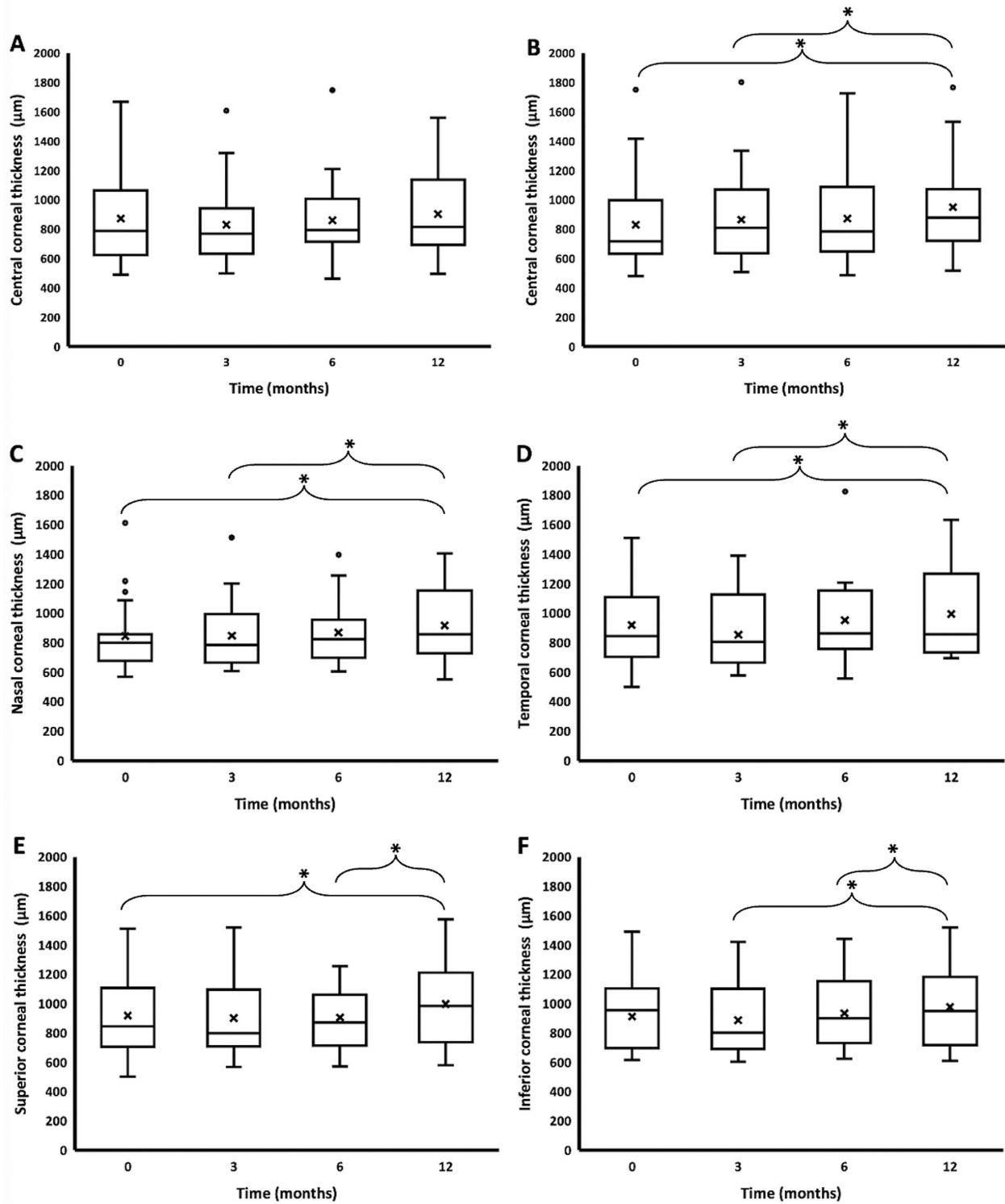
polymyxin B sulfate, and dexamethasone ophthalmic ointment; Bausch & Lomb Incorporated) to address these adverse events. No significant differences in tear production or IOP results were found between baseline and subsequent measurements (Fig. 2).

## Efficacy

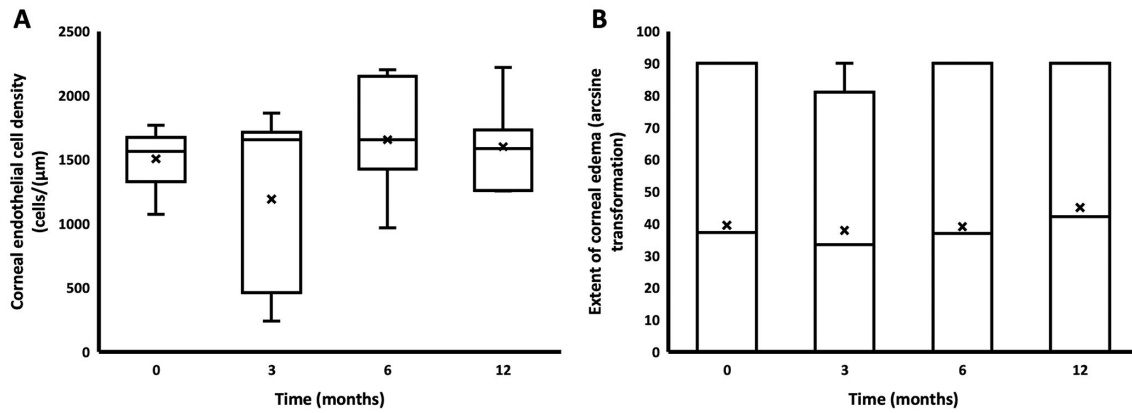
Significant differences were found in CCT as measured by USP between baseline (median 720  $\mu\text{m}$ , interquartile range 640–960  $\mu\text{m}$ ) and 12 months (median 879  $\mu\text{m}$ , interquartile range 726–1069  $\mu\text{m}$ ;  $P < 0.05$ ) and between 3 months (median 809  $\mu\text{m}$ , interquartile range 636–1072  $\mu\text{m}$ ) and 12 months ( $P < 0.05$ ). Significant differences in nasal, temporal,

superior, and inferior corneal thickness were identified across some time points as seen in Figure 3. However, full CCT and the thickness of the epithelium, stroma, and DM-endothelial complex as measured by FD-OCT did not differ significantly over time (see Fig. 3). Additionally, no significant differences were found in ECD and corneal edema extent across time points (Fig. 4).

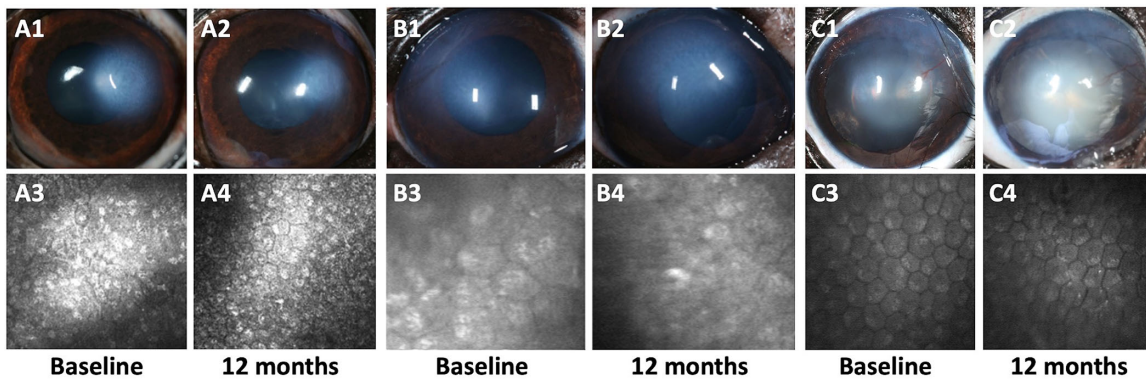
When considered individually using the clinical response criteria, 5 eyes (24%) were classified as improved, 8 (38%) remained stable, and 8 (38%) progressed at the 12-month time point. Of dogs with both eyes included in the study, six dogs (66%) demonstrated similar responses bilaterally, whereas three (33%) had disparate responses between eyes. The dogs



**Figure 3.** Corneal thickness measurements by Fourier-domain optical coherence tomography (FD-OCT) and ultrasonic pachymetry (USP) across time points in PCED-affected dogs treated with topical ripasudil. **(A)** Central corneal thickness measurements by FD-OCT. **(B)** Central, **(C)** nasal, **(D)** temporal, **(E)** superior, and **(F)** inferior corneal thickness measurements by USP at baseline and at 3, 6, and 12 months after initiating therapy with topical ripasudil. *Box plots* depict median, mean (X), and 25th and 75th percentiles. *Whisker plots* show maximum and minimum values. *Circles* indicate outliers. Asterisks (\*) indicate statistical significance using 1-way repeated measures ANOVA or Friedman’s ( $P < 0.05$ ). Twenty-one eyes were included in the analysis.



**Figure 4.** No significant differences in endothelial cell density (ECD) or extent of corneal edema were found across time points in PCED-affected dogs treated with topical ripasudil. Corneal ECD by in vivo confocal microscopy (A) and corneal edema extent (arcsine transformation) (B) at baseline and at 3, 6, and 12 months after initiating therapy with topical ripasudil. Box plots depict median, mean (X), and 25th and 75th percentiles. Whisker plots show maximum and minimum values. Circles indicate outliers. Number of eyes included in the analysis were 12 A and 21 B.



**Figure 5.** Representative digital photographs and in vivo confocal microscopy images of PCED-affected eyes at baseline and the 12-month time point demonstrating variable responses to topical ripasudil. (A) An 8-year-old male castrated Boston terrier demonstrated improved corneal edema (A1 to A2) and improved corneal ECD (A3 to A4) from  $1565 \pm 150$  cells/mm<sup>2</sup> at baseline to  $1733 \pm 224$  cells/mm<sup>2</sup> at 12 months. (B) A 5-year-old male castrated chihuahua mix demonstrated progressive corneal edema (B1 to B2) and decreased ECD (B3 to B4) from  $1324 \pm 138$  cells/mm<sup>2</sup> at baseline to  $881 \pm 17$  cells/mm<sup>2</sup> at 12 months. (C) A 12-year-old male castrated shih tzu demonstrated stable corneal edema (C1 to C2) and stable ECD (C3 to C4) from  $1674 \pm 199$  cells/mm<sup>2</sup> at baseline to  $1588 \pm 30$  cells/mm<sup>2</sup> at 12 months. Endothelial cell density is reported as mean  $\pm$  standard deviation.

with disparate responses between eyes were classified as having the same severity of disease bilaterally at baseline. For eyes classified as mildly affected at baseline, four eyes (36%) were characterized as improved, four (36%) eyes were stable, and three (27%) eyes progressed at the final time point. By contrast, for eyes classified as moderately to severely affected at baseline, only one eye (10%) was characterized as improved, four eyes (40%) were stable, and five eyes (50%) progressed over the treatment period. Only one (20%) of the improved eyes and one (12.5%) of the stable eyes received topical hypertonic saline during the treatment period. The remaining seven eyes that received topical hypertonic saline progressed during

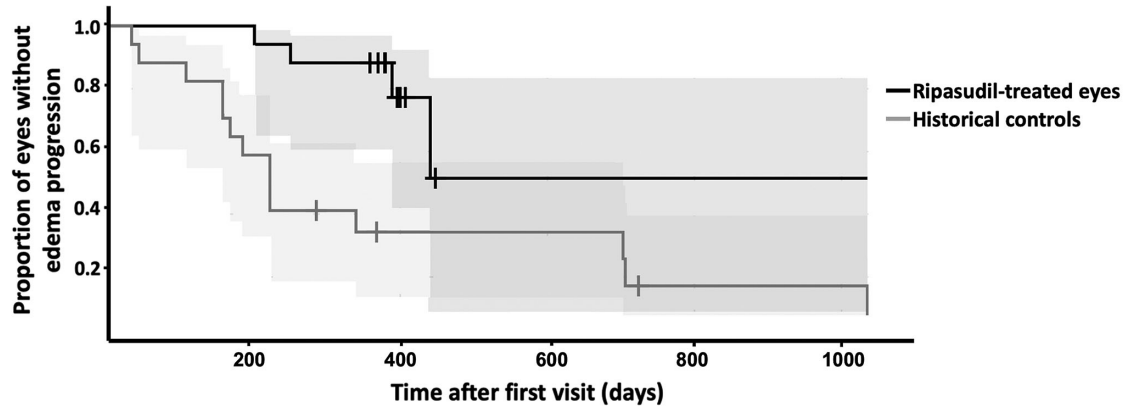
the treatment period. Representative images from each outcome are demonstrated in Figure 5.

### Owner Survey and Follow-Up

All (12/12) owners responded to the survey after study completion. Five owners (42%) reported improvement in vision, and seven owners (58%) reported improvement in corneal clarity at the end of the treatment period. Eleven owners (92%) were satisfied with the treatment and would recommend ripasudil to other owners of dogs with PCED.

After conclusion of the study period, five dogs (42%) were continued on topical ripasudil therapy, and





**Figure 6.** Kaplan-Meier curves demonstrated that PCED-affected dogs treated with topical ripasudil progressed more slowly than historical controls. Tick marks indicate censored subjects, and the shaded area indicates 95% confidence intervals. Median time from the initial visit to meeting any of the progression criteria in historical controls was 223 days. Median time to progression was not reached in ripasudil-treated eyes. Log-rank test identified a significant difference in distribution of time to progression between eyes receiving topical ripasudil and untreated historical controls ( $P = 0.023$ ). Seventeen ripasudil-treated eyes from the current study and 17 untreated, age- and breed/size-matched historical controls<sup>34</sup> were included in the Kaplan-Meier curves and analysis.

two dogs (17%) were enrolled in a study evaluating a different topical ROCK inhibitor. One dog (8%) underwent unilateral superficial keratectomy and conjunctival advancement hood flap due to significant progression of corneal edema and the development of bullous keratopathy. Ripasudil was discontinued in two dogs (17%) after completion of the study. One dog (8%) was lost to follow-up, and one dog (8%) was humanely euthanized shortly after the study period for reasons unrelated to ocular disease.

### Comparison to Historical Controls

Kaplan-Meier curves were generated for both ripasudil-treated eyes in the current study and untreated age- and breed/size-matched historical control eyes<sup>34</sup> (Fig. 6). Four ripasudil-treated eyes of two dogs (a Boston terrier and Jack Russell terrier) were excluded due to having bilaterally compensated disease without corneal edema in either eye, leaving 17 ripasudil-treated eyes of 10 dogs for analysis. Seventeen historical control eyes of 10 dogs were selected to approximately match the age, breed/size, and stage of disease at baseline as the ripasudil-treated eyes. Breeds were matched if possible and when not possible, the dogs were matched by body weight. Ages were matched within 3 years. Severity and extent of corneal edema at baseline were matched between groups based on medical record data, with no more than one stage difference in corneal edema severity between eyes (for example, mild and moderate edema could be paired together, but mild and severe edema could not). The control group consisted of 3 Boston terriers, 1 West

Highland white terrier, 1 dachshund, 1 Schipperke, 1 miniature poodle, 1 shih tzu, and 1 German Short-haired Pointer with a mean age of 10.9 years (range = 6 to 15 years).

Of the seventeen ripasudil-treated eyes, one progressed in accordance with criterion one, one progressed in accordance with criterion two, and two progressed in accordance with criterion three. Of the seventeen historical controls, three progressed in accordance with criterion one, two progressed in accordance with criterion two, and eight progressed in accordance with criterion three. All remaining eyes were censored at the time of the last follow-up visit. Median time from the initial visit to meeting any of the progression criteria in historical controls was 223 days. Median time to progression was not reached in ripasudil-treated eyes. The log-rank test identified a significant difference in distribution of time to edema progression between eyes receiving and not receiving topical ripasudil ( $P = 0.023$ ) with less progression in the ripasudil treatment group.

### Discussion

Primary corneal endothelial degeneration is widely considered a progressive, irreversible disease process, and previous studies have not shown spontaneous improvement in PCED-affected dogs.<sup>24,25,34</sup> However, several eyes receiving topical ripasudil in the current study were shown to improve or remain stable, suggesting a potential therapeutic benefit of topical ROCK inhibition in these cases. Eyes classified as having

mild disease at baseline were more likely to exhibit favorable outcomes than more severely affected eyes. Specifically, mildly versus severely affected eyes demonstrated improvement in 36% and 10% of eyes, respectively. Although 40% of severely affected eyes demonstrated stable disease in comparison to 36% of mildly affected eyes, this outcome is considered less favorable in severely affected eyes as vision and comfort are often already compromised at advanced stages of disease. Therefore, this study suggests a potential benefit of ripasudil in early disease, as supported by findings in previous studies of human patients with FECD.<sup>35</sup>

Whereas statistically significant progression of central corneal thickness was found with USP measurements, a previous study demonstrated that manual FD-OCT measurements demonstrate less variability than USP measurements of corneal thickness in eyes with corneal disease.<sup>36</sup> Therefore, the relevance of the statistically significant difference in corneal thickness by USP when no significant differences were identified using FD-OCT should not be overstated.

A retrospective study by Leonard et al. documented disease progression in CED-affected dogs based on the extent and severity of corneal edema over time.<sup>34</sup> Using the same progression criteria applied to eyes in the current study, we demonstrated a statistically significant difference in corneal edema progression with and without ripasudil therapy. Eyes receiving topical ripasudil demonstrated less edema progression over time, further supporting a potential therapeutic benefit. Although several eyes treated with topical ripasudil still progressed, ripasudil may offer a nonsurgical option to stabilize or prolong disease progression in patients with endothelial degeneration.

This study investigates the use of a topical ROCK inhibitor without disruption of the existing corneal endothelium. However, ROCK inhibitors have more routinely been used as an adjunctive or rescue therapy after surgical disruption of the corneal DM-endothelium complex through DSO in human patients.<sup>6,7</sup> Previous studies have shown favorable responses to ripasudil following DSO with improved endothelial cell densities in ripasudil-treated eyes compared to those who underwent DSO without ripasudil therapy.<sup>7,37,38</sup> Excision of abnormal endothelial cells and the associated Descemet's membrane is thought to allow for peripheral endothelial cells to proliferate and migrate to restore corneal deturgescence.<sup>6,38,39</sup> Alleviation of contact-inhibition through physical denudation of the corneal endothelium may enhance the benefit of ROCK inhibition. The clinical benefit observed with ripasudil without endothelial disruption in the current study may be related to reduction of endothelial cell apoptosis or improved

endothelial cell proliferation, migration, and adhesion following loss of endothelial cells, as have been seen in vitro and in ex vivo tissue models.<sup>17-19</sup> Future studies may investigate the use of ROCK inhibitors in PCED-affected dogs following corneal endothelial denudation with or without the injection of cultured endothelial cells. As graft-sparing and cell-based therapies for endothelial dysfunction continue to gain traction, further investigation of ROCK inhibition as an adjuvant to these techniques is warranted.

There were several limitations to this study that should be considered. First, this was an open-label trial without a placebo control group. Spontaneous improvement in dogs with PCED has not previously been reported. Thus, any improvement in corneal thickness, corneal edema, or corneal ECD was attributed to the administered treatment. To account for the lack of a placebo control group, additional Kaplan-Meier and log-rank analyses were performed to compare disease progression of ripasudil-treated eyes to age- and breed/size-matched historical controls from a previously published retrospective study using the same progression criteria. Admittedly, the inclusion criteria of the current study differed from the retrospective study, as advanced imaging was included in confirming the diagnosis of PCED prior to initiating ripasudil therapy. Therefore, dogs that would be excluded based on the inclusion criteria of the retrospective study (i.e. dogs with bilateral compensated disease) were excluded from this additional analysis.

One theoretical confounding factor was the use of topical hypertonic saline in some eyes with corneal edema. However, a previous study demonstrated only a 2% to 4% decrease in corneal thickness following the application of hypertonic saline ointment in healthy dogs,<sup>40</sup> whereas we used a cutoff of 20% to denote clinically significant improvement or progression of corneal thickness. Additionally, only one of the five eyes that improved during the treatment period received hypertonic saline, and seven of nine eyes that received hypertonic saline progressed during the treatment period. This suggests that the administration of topical hypertonic saline alone cannot account for the favorable responses encountered in a subset of eyes.

Dogs with marked variation in disease stage at baseline were enrolled, and sample sizes were relatively small, which reduced statistical power. To address variation in disease stage and progression, affected eyes were considered individually using clinical response criteria. The underlying cause of corneal degeneration differed between enrolled dogs, with some dogs, such as Boston terriers, presumably having heritable corneal endothelial dystrophy whereas others demonstrated age-related corneal degeneration. It is

possible that the etiology of endothelial degeneration may affect response to therapy, although subgroup analysis could not be performed due to the small sample size in each group. Future randomized, controlled, and double-blind studies with stricter inclusion criteria to limit the variation in disease stage and underlying cause of corneal degeneration are warranted.

Topical ripasudil was well-tolerated in PCED-affected dogs with conjunctival hyperemia being the most common adverse event observed, consistent with previous tolerability studies.<sup>41,42</sup> An additional adverse event was the development of reticular bullous epithelial edema, which has also been reported in a series of human patients receiving the topical ROCK inhibitor netarsudil.<sup>43,44</sup> However, unlike in human patients, the reticular bullous epithelial edema was transient in these dogs and resolved without discontinuation of ripasudil as this change was appreciated at some visits but not all. The cause of reticular bullous epithelial edema remains unknown but may involve ROCK-inhibitor induced disruption of actin cytoskeleton organization and tight junctions of corneal epithelial cells.<sup>44</sup> The disappearance of the bullae without cessation of ripasudil may indicate that the edema was present as a result of the underlying disease rather than an adverse drug event, that the adverse event was truly transient or occurred only shortly after administration, or that topical hypertonic saline ointment may have aided in resolution of the bullae. Corneal stromal hemorrhage is a rare occurrence reported in humans receiving ROCK inhibitors, including a case report of a 76-year-old man with pre-existing peripheral corneal neovascularization and concurrent primary open angle glaucoma treated with topical netarsudil.<sup>45</sup> Interestingly, both dogs that demonstrated corneal stromal hemorrhage also had pre-existing corneal neovascularization as seen in image C of [Figure 1](#). One of the dogs that experienced corneal stromal hemorrhage also had diabetes mellitus, which has been shown to increase vascular permeability.<sup>46</sup> It is suspected that conjunctival hyperemia occurs due to ROCK inhibitor-induced vascular smooth muscle relaxation and modulation in vascular endothelial cells.<sup>41</sup> We hypothesize that blood vessels in the cornea undergo similar changes in vascular permeability with ROCK inhibition, predisposing to corneal hemorrhage. Therefore, the use of ROCK inhibitors in patients with underlying corneal vascularization or concurrent conditions resulting in increased vascular permeability should be avoided. Finally, no difference in IOP was found across time points, consistent with previous studies showing lack of clinically significant IOP reduction with netarsudil in normotensive dogs<sup>47</sup> and in dogs with primary open angle glaucoma.<sup>48</sup>

In summary, eyes with PCED demonstrated variable responses to therapy, though overall, eyes treated with topical ripasudil demonstrated less corneal edema progression than untreated historical controls. Additionally, eyes with mild disease showed more favorable responses to ripasudil therapy, suggesting a potential benefit in dogs with early PCED without significant decompensation. Stage of disease at baseline was one factor found to be associated with a positive outcome, but additional investigation is necessary to determine other factors that may be predictive of an individual's response. This open-label pilot study serves as a guide for the development of future clinical trials evaluating the use of ROCK inhibitors in canine disease models of corneal endothelial degeneration.

## Acknowledgments

The authors thank Monica Motta, Megan Gragg, Carina Pasqualino, and Michelle McCorkell for assisting with the patient examinations and David Maggs, Steven Hollingsworth, Andrea Minella, Kelly Knickelbein, and Kirsten Steele for case referral.

Supported by the National Institutes of Health R01EY016134, P30EY12576, and K08EY028199, the Center for Companion Animal Health at the UC Davis School of Veterinary Medicine, and the Jane Lin Fong Ophthalmic Clinical Trial Support Fund.

Disclosure: **S.R. Michalak**, None; **S. Kim**, None; **S. Park**, None; **M.I. Casanova**, None; **M.A.W. Bowman**, None; **M. Ferneding**, None; **B.C. Leonard**, None; **K.L. Good**, None; **J.Y. Li**, None; **S.M. Thomasy**, None

## References

1. Mishima SO, Hedbys B. Physiology of the Cornea. *Intl Ophthalmol Clin*. 1968;8(3):527–560.
2. Tuft SJ, Coster DJ. The corneal endothelium. *Eye*. 1990;4(3):389–424.
3. Li YJ, Minear MA, Rimmner J, et al. Replication of TCF4 through association and linkage studies in late-onset Fuchs endothelial corneal dystrophy. *PLoS One*. 2011;6(4):e18044.
4. Ing JJ, Ing HH, Nelson LR, Hodge DO, Bourne WM. Ten-year postoperative results of penetrating keratoplasty. *Ophthalmology*. 1998;105(10):1855–1865.
5. Price F, Feng M, Price M. Evolution of Endothelial Keratoplasty: Where Are We Headed?. *Cornea*. 2015;34:S41–S47.

6. Moloney G, Petsoglou C, Ball M, et al. Descemetorhexis Without Grafting for Fuchs Endothelial Dystrophy—Supplementation With Topical Ripasudil. *Cornea*. 2017;36(6):642–648.
7. Macsai MS, Shiloach M. Use of Topical Rho Kinase Inhibitors in the Treatment of Fuchs Dystrophy After Descemet Stripping Only. *Cornea*. 2019;38(5):529–534.
8. Davies E, Jurkunas U, Pineda R. Predictive Factors for Corneal Clearance After Descemetorhexis Without Endothelial Keratoplasty. *Cornea*. 2018;37(2):137–140.
9. Huang MJ, Kane SK, Dhaliwal D. Descemetorhexis Without Endothelial Keratoplasty Versus DMEK for Treatment of Fuchs Endothelial Corneal Dystrophy. *Cornea*. 2018;37(12):1479–1483.
10. Kinoshita S, Koizumi N, Ueno M, et al. Injection of Cultured Cells with a ROCK Inhibitor for Bullous Keratopathy. *N Engl J Med*. 2018;378(11):995–1003.
11. Garnock-Jones K. Ripasudil: First Global Approval. *Drugs*. 2014;74(18):2211–2215.
12. Ishizaki T, Maekawa M, Fujisawa K, et al. The small GTP-binding protein Rho binds to and activates a 160 kDa Ser/Thr protein kinase homologous to myotonic dystrophy kinase. *EMBO J*. 1996;15(8):1885–1893.
13. Shimokawa H, Takeshita A. Rho-Kinase Is an Important Therapeutic Target in Cardiovascular Medicine. *Arterioscler Thromb Vasc Biol*. 2005;25(9):1767–1775.
14. Koga T, Koga T, Awai M, Tsutsui J, Yue BY, Tanihara H. Rho-associated protein kinase inhibitor, Y-27632, induces alterations in adhesion, contraction and motility in cultured human trabecular meshwork cells. *Exp Eye Res*, 2006;82(3):362–370.
15. Hall A. Rho GTPases and the actin cytoskeleton. *Science*. 1998;279(5350):509–514.
16. Rao V, Epstein P. Rho GTPase/Rho Kinase Inhibition as a Novel Target for the Treatment of Glaucoma. *BioDrugs*, 2007;21(3):167–177.
17. Okumura N, Okazaki Y, Inoue R, et al. Effect of the Rho-Associated Kinase Inhibitor Eye Drop (Ripasudil) on Corneal Endothelial Wound Healing. *Invest Ophthalmol Vis Sci*. 2016;57(3):1284.
18. Okumura N, Ueno M, Koizumi N, et al. Enhancement on Primate Corneal Endothelial Cell Survival In Vitro by a ROCK Inhibitor. *Invest Ophthalmol Vis Sci*. 2009;50(8):3680.
19. Goldstein A, Aldrich BT, Skeie JM, et al. Assessing the Effects of Ripasudil, a Novel Rho Kinase Inhibitor, on Human Corneal Endothelial Cell Health. *J Ocular Pharmacol Therapeut*. 2018;34(10):692–699.
20. Miyagi H, Kim S, Li J, Murphy CJ, Thomasy SM. Topical Rho-Associated Kinase Inhibitor, Y27632, Accelerates Corneal Endothelial Regeneration in a Canine Cryoinjury Model. *Cornea*. 2019;38:352–359.
21. Okumura N, Koizumi N, Kay E, et al. The ROCK Inhibitor Eye Drop Accelerates Corneal Endothelium Wound Healing. *Invest Ophthalmol Vis Sci*. 2013;54(4):2493.
22. Koizumi N, Okumura N, Ueno M, Kinoshita S. New Therapeutic Modality for Corneal Endothelial Disease Using Rho-Associated Kinase Inhibitor Eye Drops. *Cornea*. 2014;33(Suppl 11):S25–S31.
23. Koizumi N, Okumura N, Ueno M, Nakagawa H, Hamuro J, Kinoshita S. Rho-Associated Kinase Inhibitor Eye Drop Treatment as a Possible Medical Treatment for Fuchs Corneal Dystrophy. *Cornea*. 2013;32(8):1167–1170.
24. Thomasy SM, Cortes DE, Hoehn AL, Calderon AC, Li JY, Murphy CJ. In Vivo Imaging of Corneal Endothelial Dystrophy in Boston Terriers: A Spontaneous, Canine Model for Fuchs' Endothelial Corneal Dystrophy. *Invest Ophthalmol Vis Sci*. 2016;57(9):495–503.
25. Shull OR, Reilly CM, Davis LB, Murphy CJ, Thomasy SM. Phenotypic Characterization of Corneal Endothelial Dystrophy in German Short-haired and Wirehaired Pointers Using In Vivo Advanced Corneal Imaging and Histopathology. *Cornea*. 2018;37(1):88–94.
26. Sanchez R. The cornea. In: Gould D, McLellan G, eds. *BSAVA Manual of Canine and Feline Ophthalmology*, 3rd edn. Gloucester, England: British Small Animal Veterinary Association; 2014:200–231.
27. Bayley KD, Read RA, Gates MC. Superficial keratectomy as a treatment for non-healing corneal ulceration associated with primary corneal endothelial degeneration. *Vet Ophthalmol*, 2019.22(4):485–492.
28. Joyce NC. Proliferative capacity of corneal endothelial cells. *Exp Eye Res*. 2012.95(1):16–23.
29. Befanis PJ, Peiffer RL, Brown D. Endothelial repair of the canine cornea. *Am J Vet Res* 1981;42:590–595
30. Park S, Leonard BC, Raghunathan VK, et al. Animal models of corneal endothelial dysfunction to facilitate development of novel therapies. *Ann Transl Med*. 2021;9(15):1271.
31. Eaton JS, Bentley PE, Thomasy SM, Murphy CJ. The SPOTS System: An Ocular Scoring System Optimized for Use in Modern Preclinical Drug Development and Toxicology. *J Ocular Pharmacol Ther*. 2017;33(10):718–734.

32. Strom AR, Cortés DE, Rasmussen CA, et al. In vivo evaluation of the cornea and conjunctiva of the normal laboratory beagle using time- and Fourier-domain optical coherence tomography and ultrasound pachymetry. *Vet Ophthalmol.* 2016;19(1):50–56.
33. Martín-Suárez E, Molleda C, Tardón R, et al. Diurnal variations of central corneal thickness and intraocular pressure in dogs from 8:00 am to 8:00 pm. *Canadian Vet J*, 2014; 55(4):361–365.
34. Leonard BC, Kermanian CS, Michalak SR, et al. A Retrospective Study of Corneal Endothelial Dystrophy in Dogs (1991–2014). *Cornea.* 2020;40(5):578–583.
35. Okumura N, Kinoshita S, Koizumi N. Application of Rho Kinase Inhibitors for the Treatment of Corneal Endothelial Diseases. *J Ophthalmol.* 2017;2017:2646904.
36. Hoehn A, Thomasy S, Kass P, et al. Comparison of ultrasonic pachymetry and Fourier-domain optical coherence tomography for measurement of corneal thickness in dogs with and without corneal disease. *Vet J*, 2018;242: 59–66.
37. Moloney G, Garcerant Congote D, Hirnschall N, et al. Descemet Stripping Only Supplemented With Topical Ripasudil for Fuchs Endothelial Dystrophy 12-Month Outcomes of the Sydney Eye Hospital Study. *Cornea.* 2020;40(3):320–326.
38. Borkar DS, Veldman P, Colby KA. Treatment of Fuchs Endothelial Dystrophy by Descemet Stripping Without Endothelial Keratoplasty. *Cornea.* 2016;35(10):1267–1273.
39. Davies E, Jurkunas U, Pineda R. Predictive Factors for Corneal Clearance After Descemetorhexis Without Endothelial Keratoplasty. *Cornea.* 2018;37(2):137–140.
40. Samuel M, Thomasy SM, Calderon AS, Kass PH, Collins K, Murphy CJ. Effects of 5% sodium chloride ophthalmic ointment on thickness and morphology of the normal canine cornea. *Vet Ophthalmol.* 2019;22(3):229–237.
41. Tanihara H, Inoue T, Yamamoto T, et al. Phase 1 clinical trials of a selective Rho kinase inhibitor, K-115. *JAMA Ophthalmol.* 2013;131:1288–1295.
42. Tanihara H, Inoue T, Yamamoto T, et al. Phase 2 randomized clinical study of a Rho kinase inhibitor, K-115, in primary open-angle glaucoma and ocular hypertension. *Am J Ophthalmol.* 2013;156:731–736.
43. Wisely CE, Liu KC, Gupta D, et al. Reticular Bullous Epithelial Edema in Corneas Treated with Netarsudil: A Case Series. *Am J Ophthalmol.* 2020;217:20–26.
44. Tran JA, Jurkunas UV, Yin J, et al. Netarsudil-associated reticular corneal epithelial edema. *Am J Ophthalmol Case Rep*, 2022;25:101287.
45. Asanad S, Zhang R, Saeedi OJ. Corneal Hemorrhage Associated with Netarsudil in the Setting of Corneal Neovascularization. *Ophthalmol Glaucoma.* 2020;3(5):392.
46. Wang J, Xu X, Elliott MH, Zhu M, Le YZ. Müller cell-derived VEGF is essential for diabetes-induced retinal inflammation and vascular leakage. *Diabetes.* 2010;59(9):2297–2305.
47. Yang VY, Miller PE, Keys DA, et al. Effects of 0.02% netarsudil ophthalmic solution on intraocular pressure of normotensive dogs. *Vet Ophthalmol.* 2021;24(S1):87–95.
48. Leary KA, Lin KT, Steibel JP, Harman CD, Komáromy AM. Safety and efficacy of topically administered netarsudil in normal and glaucomatous dogs with ADAMTS10-open-angle glaucoma (ADAMTS10-OAG). *Vet Ophthalmol.* 2021;24(S1):75–86.