

UCLA

UCLA Previously Published Works

Title

Cerebellar, limbic, and midbrain volume alterations in sudden unexpected death in epilepsy

Permalink

<https://escholarship.org/uc/item/1qr472zn>

Journal

Epilepsia, 60(4)

ISSN

0013-9580

Authors

Allen, Luke A
Vos, Sjoerd B
Kumar, Rajesh
[et al.](#)

Publication Date





2019-04-01

DOI

10.1111/epi.14689

Peer reviewed

Cerebellar, limbic, and midbrain volume alterations in sudden unexpected death in epilepsy

Luke A. Allen^{1,2,3}  | Sjoerd B. Vos^{2,3,4,5} | Rajesh Kumar^{3,6,7,8,9} | Jennifer A. Ogren^{3,10} | Rebecca K. Harper¹⁰ | Gavin P. Winston^{1,2}  | Simona Balestrini^{1,2} | Britta Wandschneider^{1,2} | Catherine A. Scott^{1,3} | Sebastien Ourselin¹¹ | John S. Duncan^{1,2}  | Samden D. Lhatoo^{3,12,13}  | Ronald M. Harper^{3,6,10} | Beate Diehl^{1,2,3}

¹Department of Clinical and Experimental Epilepsy, University College London Institute of Neurology, London, UK

²Magnetic Resonance Imaging Unit, Epilepsy Society, London, UK

³Center for Sudden Unexpected Death in Epilepsy Research, National Institute of Neurological Disorders and Stroke, Bethesda, Maryland

⁴Wellcome/Engineering and Physical Sciences Research Council Centre for Interventional and Surgical Sciences, University College London, London, UK

⁵Translational Imaging Group, Centre for Medical Image Computing, University College London, London, UK

⁶Brain Research Institute, University of California, Los Angeles, Los Angeles, California

⁷Department of Anesthesiology, David Geffen School of Medicine at University of California, Los Angeles, Los Angeles, California

⁸Department of Radiological Sciences, David Geffen School of Medicine at University of California, Los Angeles, Los Angeles, California

⁹Department of Bioengineering, University of California, Los Angeles, Los Angeles, California

¹⁰Department of Neurobiology, David Geffen School of Medicine at University of California, Los Angeles, Los Angeles, California

¹¹School of Biomedical Engineering and Imaging Sciences, St Thomas' Hospital, King's College London, London, UK

¹²Epilepsy Center, Neurological Institute, University Hospitals Case Medical Center, Cleveland, Ohio

¹³Department of Neurology, University of Texas Health Sciences Center at Houston, United States

Correspondence

Luke Allen, Department of Clinical and Experimental Epilepsy, Institute of Neurology, University College London, London, UK.

Email: Luke.allen.15@ucl.ac.uk

Funding information

National Institute of Neurological Disorders and Stroke, Grant/Award Number: U01-NS090407; Medical Research Council, Grant/Award Number: G0802012 and MR/M00841X/1; National Institute for Health Research University College London Hospitals Biomedical Research Centre

Summary

Objective: The processes underlying sudden unexpected death in epilepsy (SUDEP) remain elusive, but centrally mediated cardiovascular or respiratory collapse is suspected. Volume changes in brain areas mediating recovery from extreme cardiorespiratory challenges may indicate failure mechanisms and allow prospective identification of SUDEP risk.

Methods: We retrospectively imaged SUDEP cases ($n = 25$), patients comparable for age, sex, epilepsy syndrome, localization, and disease duration who were high-risk ($n = 25$) or low-risk ($n = 23$), and age- and sex-matched healthy controls ($n = 25$) with identical high-resolution T1-weighted scans. Regional gray matter volume, determined by voxel-based morphometry, and segmentation-derived structure sizes were compared across groups, controlling for total intracranial volume, age, and sex.

L.A.A. is first author; R.M.H. and B.D. are senior authors.

This is an open access article under the terms of the Creative Commons Attribution License, which permits use, distribution and reproduction in any medium, provided the original work is properly cited.

© 2019 The Authors. *Epilepsia* published by Wiley Periodicals, Inc. on behalf of International League Against Epilepsy

Results: Substantial bilateral gray matter loss appeared in SUDEP cases in the medial and lateral cerebellum. This was less prominent in high-risk subjects and absent in low-risk subjects. The periaqueductal gray, left posterior and medial thalamus, left hippocampus, and bilateral posterior cingulate also showed volume loss in SUDEP. High-risk subjects showed left thalamic volume reductions to a lesser extent. Bilateral amygdala, entorhinal, and parahippocampal volumes increased in SUDEP and high-risk patients, with the subcallosal cortex enlarged in SUDEP only. Disease duration correlated negatively with parahippocampal volume. Volumes of the bilateral anterior insula and midbrain in SUDEP cases were larger the closer to SUDEP from magnetic resonance imaging.

Significance: SUDEP victims show significant tissue loss in areas essential for cardiorespiratory recovery and enhanced volumes in areas that trigger hypotension or impede respiratory patterning. Those changes may shed light on SUDEP pathogenesis and prospectively detect patterns identifying those at risk.

KEYWORDS

cerebellum, limbic, magnetic resonance imaging, midbrain, sudden unexpected death in epilepsy

1 | INTRODUCTION

The processes underlying sudden unexpected death in epilepsy (SUDEP) remain elusive. Circumstances surrounding the fatal event suggest a centrally mediated cardiovascular or respiratory collapse following a generalized tonic-clonic seizure (GTCS).¹ Because SUDEP is the leading cause of premature death among people with epilepsy,² efforts to noninvasively characterize potential underlying neural mechanisms mediating SUDEP and highlight imaging biomarkers are essential.

Brain structural imaging studies of SUDEP have revealed volume changes among key structures involved in autonomic and respiratory regulation in people who succumbed to SUDEP and those at high risk.³ Individuals with frequent GTCSs, who are at highest risk of SUDEP,⁴ exhibit cortical thickness changes in key areas that are autonomic, somatosensory, and breathing coordination sites.⁵ Less attention has been directed to structures essential for recovery from compromised breathing or cardiovascular circumstances.

Regional brain volume assessments in patients who succumb may allow determination of processes that contribute to the fatal event or fail to provide adequate compensatory recovery. Those assessments may prospectively and noninvasively identify biomarkers for individuals at risk and were the objectives of this study.

2 | MATERIALS AND METHODS

2.1 | Subjects

Twenty-five individuals who suffered definite ($n = 12$) or probable ($n = 13$) SUDEP⁶ were retrospectively identified after updating an earlier initial search.³ Living high-risk ($n = 25$) and

Key Points

- Brain volumes in cortical, subcortical, and cerebellar sites that influence blood pressure and breathing patterns are altered in SUDEP
- Volumes increased in the amygdala, entorhinal cortex, parahippocampal gyrus, and subcallosal cortex, which induce apnea or hypotension
- Volumes decreased in the cerebellum, periaqueductal gray, posterior cingulate, and posterior thalamus, sites involved in recovery from cardiorespiratory dysfunction
- Periaqueductal gray and posterior cingulate volume loss, and increased subcallosal volume, were exclusive to SUDEP
- Areas inducing apnea and hypotension may be hyperactive, and recovery sites may be impaired due to tissue loss; structural trends may aid risk assessment

low-risk ($n = 23$) patients and healthy controls ($n = 25$) were identified similarly (Table 1 for group characteristics). Patients at high risk of SUDEP were those experiencing more than three GTCSs per year, the most significant factor associated with SUDEP,⁴ and distinguished >80% of SUDEP cases (21/25) in our data. Low-risk patients were those who did not experience GTCSs. All clinical information used for risk stratification was obtained from multidisciplinary team meeting reports and clinic letters closest to data collection and confirmed with the most-recent follow-up. Survival of all non-SUDEP subjects

TABLE 1 Group characteristics of SUDEP cases, high-risk patients, low-risk patients, and HC

Characteristics	SUDEP, n = 25	High risk, n = 25	Low risk, n = 23	HC, n = 25
Age, y, mean ± SD	34.4 ± 13.5	32 ± 7.5	30 ± 8.1	38 ± 12.1
Gender, M:F	18:07	18:07	16:07	18:07
Disease duration, y, mean ± SD	22.8 ± 14.2	21.4 ± 8.6	16.6 ± 9.9	N.A.
GTCSs/mo, past 12 mo, mean ± SD	2.7 ± 2.5	2.5 ± 1.5	N.A.	N.A.
Focal: generalized epilepsy	22:03	22:03	19:14	N.A.
AEDs ATOS, n, mean ± SD	2.2 ± 0.8	2.7 ± 1.1	2.1 ± 0.9	N.A.
AEDs historic, n, mean ± SD	4.8 ± 3.2	8.4 ± 3.2	3.4 ± 2.8	N.A.
Exposed to phenytoin, n	5	8	3	N.A.
Long-term phenytoin users, >10 years, n	2	3	0	N.A.
Polytherapy, n	10	15	8	N.A.
Duotherapy, n	10	6	9	N.A.
Monotherapy, n	5	4	6	N.A.
Seizure onset zone				
L temporal, HS	1	2	1	N.A.
L temporal, no HS	1	1	1	N.A.
R temporal, HS	0	1	0	N.A.
R temporal, no HS	2	1	2	N.A.
Frontal	6	5	6	N.A.
Temporal+	7	6	2	N.A.
Generalized	3	3	4	N.A.
Posterior head regions	2	1	2	N.A.
Focal, unknown	3	3	5	N.A.

AED, antiepileptic drug; ATOS, at time of scan; F, female; GTCS, generalized tonic-clonic seizure; HC, healthy controls; HS, hippocampal sclerosis; L, left; M, male; N.A., not applicable; R, right; SD, standard deviation; SUDEP, sudden unexpected death in epilepsy.

was confirmed through examination of clinical records. All scans were obtained within a defined period, ensuring identical imaging protocols: (1) all subjects underwent the same high-resolution three-dimensional (3D) T1-weighted scan; and (2) individuals with insufficient clinical data, large brain lesions, and/or previous neurosurgery were excluded. High- and low-risk patients, comparable for age, sex, epilepsy syndrome, seizure focus localization, and duration, were identified to account for potential volume changes accompanying these factors. Each SUDEP case was also matched with a comparable healthy control for age and sex. Table 1 shows group characteristics. Table S1 outlines individual clinical characteristics of SUDEP, high-risk, and low-risk patients. The study was approved by the UK National Research Ethics Committee under an ongoing database research project on autonomic and imaging biomarkers of SUDEP (04/Q0512/77 and 14/SW/0021) and a local audit on mortality in epilepsy.

2.2 | Magnetic resonance imaging acquisition

Scanning was performed at the Epilepsy Society (Chalfont St Peter, Buckinghamshire, UK) on a 3.0-Tesla Signa HDx (GE

Medical Systems) scanner, using standard imaging gradients (maximum strength = 40 mT/m, slew rate = 150 T/m/s). All subjects underwent the same fast spoiled gradient-echo 3D T1 scan (repetition time = 8.3 milliseconds, echo time = 3.1 milliseconds, slices = 170, slice thickness = 1.1 mm, matrix size = 256 × 256, field-of-view = 240 × 240 mm).

2.3 | Voxel-based morphometry

Voxel-based morphometry (VBM) was implemented with the computational anatomy toolbox (CAT12),⁷ using SPM12 (Statistical Parametric Mapping; <http://www.fil.ion.ucl.ac.uk/spm>) and MATLAB 2017b (MathWorks), to explore gray matter (GM) volume differences across the whole brain between groups. Images were denoised using the spatial-adaptive non-local means filter and normalized to MNI152 template space, before being segmented into GM, white matter (WM), and cerebrospinal fluid (CSF) classes. Modulated images were then smoothed with an 8-mm full-width-at-half-maximum Gaussian kernel and entered into a full-factorial model, with group as factor, and age and sex as covariates. An absolute threshold mask of probability = 0.2 was applied to account for

edge effects between different tissue types. Total intracranial volume (TIV; the sum of WM, GM, and CSF) was used to proportionally scale the data to account for differences in whole brain size across subjects, and results were familywise error rate corrected at $P < 0.05$, unless otherwise stated.

2.4 | Regional structure parcellation using geodesic information flows

2.4.1 | Parcellation method

For validation and determination of difference magnitudes, structures showing significantly increased or reduced volume using VBM were segmented in each subject using a whole-brain parcellation scheme based on geodesic information flows.⁸ Regional brain volumes were obtained by extracting areas of interest from the parcellation and multiplying the number of voxels in each area by the voxel volume.

2.4.2 | Statistical analysis

Permutation t tests were employed to assess structural differences between groups; for each contrast, members from each group were randomly permuted (10 000 times) to obtain an empirical null distribution. P values were corrected for multiple comparisons using the false discovery rate (FDR). Data were initially scaled by total intracranial volume, and adjusted for age and sex using linear regression. All processes were carried out in MATLAB 2017b.

2.4.3 | Correlations: brain volume and clinical variables

Partial correlations (IBM SPSS 25) examined whether structural sizes from whole-brain parcellation depended on disease duration or GTCS frequency, controlling for age, sex, and TIV. Correlations with GTCS frequency were considered in two ways. We first examined correlations with SUDEP and high-risk subjects as one group. We then correlated volume with GTCS frequency in SUDEP and high-risk groups separately.

Further partial correlations assessed relationships between structural size and the time between magnetic resonance imaging (MRI) and SUDEP, controlling for disease duration, seizure frequency, age, sex, and TIV. P values were FDR-corrected.

2.5 | Contributions to tissue loss from medications

Several antiepileptic drugs (AEDs) induce structural changes via toxic processes. Medications in all patients were documented and summarized by group in Table S1. We compared the number of AEDs used at scan time, and the total number of AEDs tried across groups with nonparametric tests (IBM

SPSS 25). Additionally, we repeated all volumetry analyses having removed individuals with known phenytoin exposure ($n = 5$ SUDEP, $n = 8$ high risk, $n = 3$ low risk) due to known cerebellar atrophy related to its use.⁹

3 | RESULTS

3.1 | Cerebellar volume loss

Compared with healthy controls (Figure 1A) and low-risk subjects (Figure S1A), SUDEP showed major bilateral volume loss of the cerebellum, across medial, lateral, and vermal portions (VBM). High-risk subjects also showed reduced GM volume compared with healthy controls, but in the vermis only (Figure S2A). Subanalyses, removing those with a history of phenytoin use, revealed similar but less extensive patterns of cerebellar volume loss (particularly in lateral portions) in SUDEP and high-risk subjects versus healthy controls (Figure S3A,B); no other results changed significantly as a consequence of removing these subjects. Regional segmentation comparisons revealed reduced volumes of the bilateral exterior cerebellar GM in SUDEP versus healthy controls (Figures 1 and 2B,C). High- and low-risk groups did not show reduced volume of segmented cerebellar structures.

3.2 | Thalamic and limbic alterations

The left posterior and medial thalamus and posterior hippocampus exhibited reduced GM volume in SUDEP (Figure 1B,C) and high-risk subjects (Figure S2A) versus healthy controls (VBM). Additionally, SUDEP but not high-risk subjects showed volume loss in these areas when compared with low-risk subjects (Figure S1A). VBM also revealed periaqueductal gray (PAG) and bilateral posterior cingulate GM volume loss in SUDEP versus healthy controls (Figure 1B,C). Regional segmentation analysis showed the left thalamic parcel was smaller in SUDEP versus healthy controls (Figures 1C and 2A).

The bilateral amygdala, entorhinal cortex, parahippocampal gyrus, and subcallosal cortex showed increased GM volume in SUDEP versus healthy controls (regional segmentation and VBM; Figures 2E-L and 3, respectively). Regional segmentation analysis also revealed that all of these structures were larger in SUDEP versus low-risk patients (Figure 2E-L). High-risk patients showed increased right amygdala GM volume versus healthy controls, using VBM (Figure S2C), and regional segmentation analysis showed increased bilateral amygdala and parahippocampal gyrus volume (vs healthy controls and low-risk patients; Figure 2E-H) and entorhinal cortex volume (vs healthy controls only; Figure 2I-J). Compared with low-risk patients, both high-risk and SUDEP groups manifested

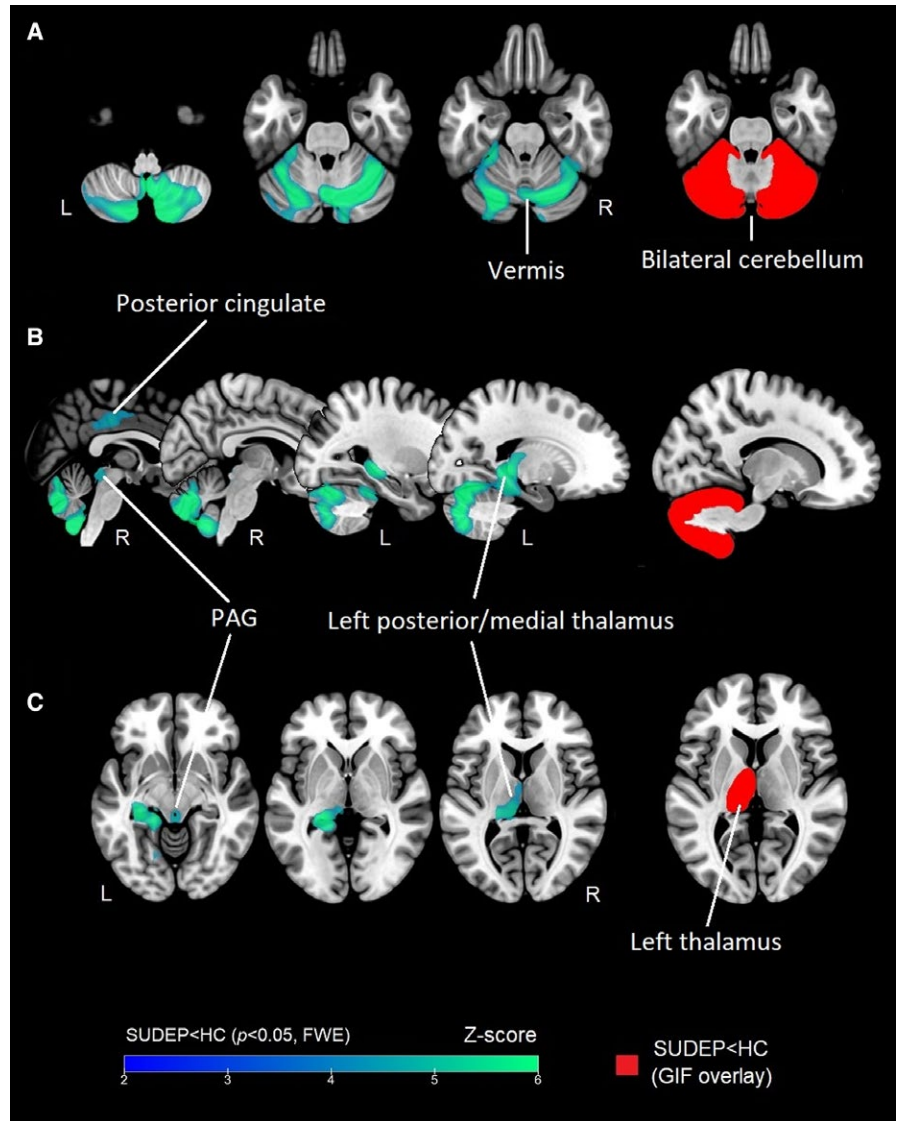


FIGURE 1 Regional gray matter volume loss in sudden unexpected death in epilepsy (SUDEP) compared with healthy controls (HC), found in the bilateral cerebellum and vermis (A, B), periaqueductal gray (PAG; B, C), left medial and posterior thalamus (C), and bilateral posterior cingulate (B). Voxel-based morphometry contrast maps are overlaid onto a standard (MNI152) brain. The masks of segmented regions exhibiting reduced size in SUDEP < HC ($P < 0.05$ familywise error [FWE]-corrected) are overlaid in red. GIF, geodesic information flow

increased right amygdala GM using VBM ($P < 0.001$ uncorrected; Figure S1B,C).

3.3 | Correlational analyses

Significant partial correlations appeared between disease duration and left ($r = -0.325$, $P = 0.008$) and right ($r = -0.318$, $P = 0.009$) parahippocampal gyrus size. Significant partial correlations also appeared between time to SUDEP from MRI in the left ($r = -0.4$, $P = 0.03$) and right ($r = -0.55$, $P = 0.006$) anterior insula (Figure 4A,B) and the left ($r = -0.38$, $P = 0.04$) and right ($r = -0.47$, $P = 0.013$) midbrain (Figure 4C,D).

GTCS frequency correlated positively with the right posterior cingulate ($r = 0.37$, $P = 0.005$) and bilateral anterior cingulate (left: $r = 0.28$, $P = 0.029$; right: $r = 0.26$, $P = 0.039$) volume, when SUDEP and high-risk subjects were analyzed in the same group ($n = 50$). When considered separately,

high-risk patients ($n = 25$) showed positive correlations with the bilateral anterior cingulate (left: $r = 0.40$, $P = 0.036$; right: $r = 0.55$, $P = 0.005$), but insignificant correlations with the right posterior cingulate ($r = 0.35$, $P = 0.057$). When analyzed alone, SUDEP cases ($n = 25$) showed positive correlations with the right hippocampus ($r = 0.54$, $P = 0.006$), but right posterior cingulate correlations were not significant ($r = 0.35$, $P = 0.063$). Negative correlations emerged with the left mid cingulate ($r = -0.39$, $P = 0.042$) and left anterior insula ($r = -0.45$, $P = 0.02$).

3.4 | Antiepileptic medication

The number of AEDs used at scan time did not significantly differ across patient groups. High-risk patients had been tried on a significantly greater number of AEDs throughout epilepsy duration versus SUDEP ($t = 3.97$, $P < 0.001$) and low-risk patients ($t = 6.1$, $P < 0.001$).

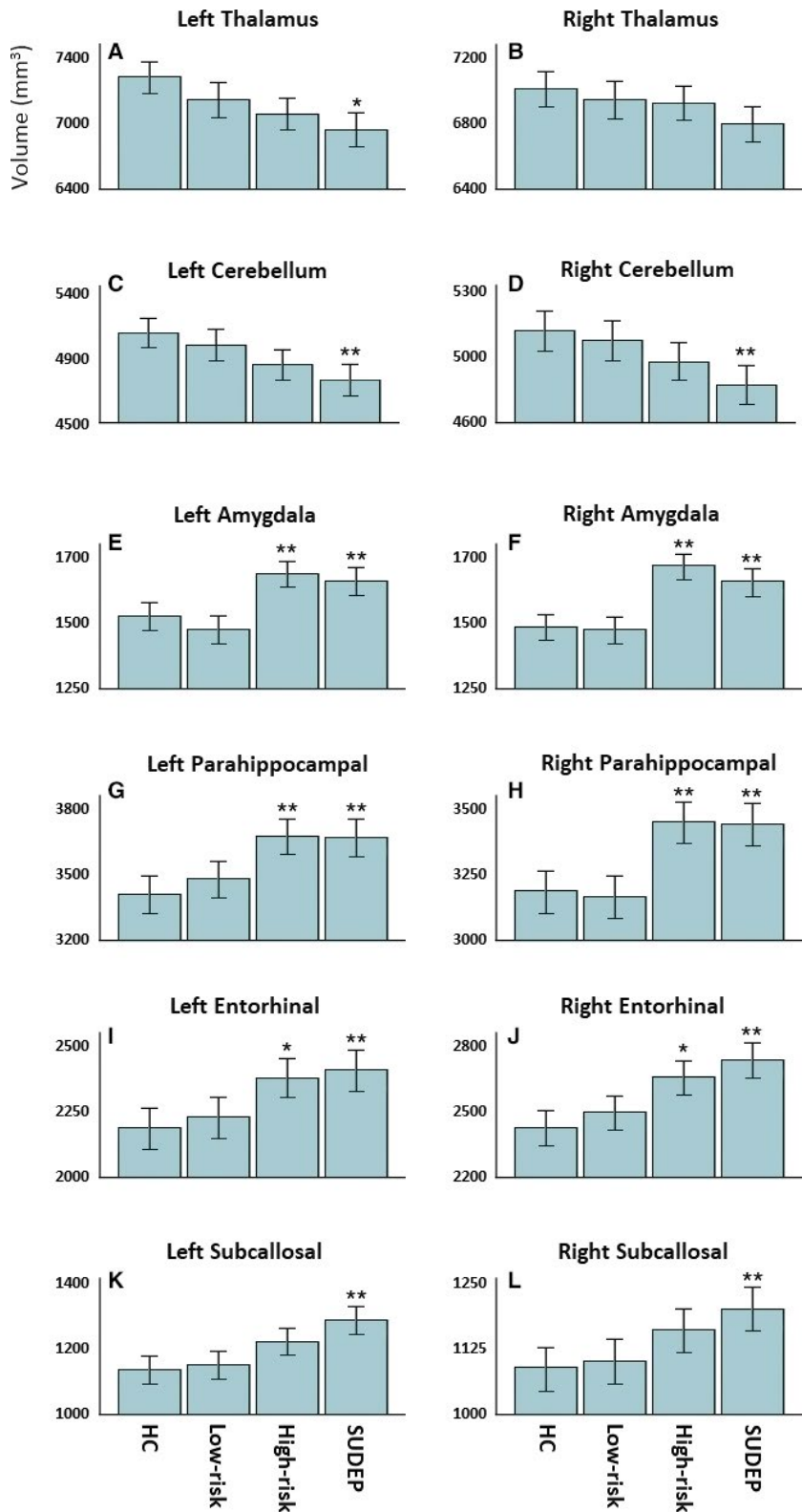


FIGURE 2 Bar graphs showing group volume differences in the thalamus (A, B), exterior cerebellar gray matter (C, D), amygdala (E, F), parahippocampal gyrus (G, H), entorhinal cortex (I, J), and subcallosal cortex (K, L). **Significant at $P < 0.05$ false discovery rate (FDR)-corrected compared with low-risk and healthy controls. *Significant at $P < 0.05$ FDR-corrected compared with healthy controls only. HC, healthy controls; SUDEP, sudden unexpected death in epilepsy

4 | DISCUSSION

4.1 | Summary

The most prominent outcome was a substantial loss of cerebellar volume in subjects who succumbed to SUDEP and,

to a lesser extent, those at high risk, a finding of consequence to the syndrome, because the cerebellum is essential to recover from compromised cardiovascular and breathing circumstances. Other sites which maintain blood pressure integrity and project to the cerebellum—the PAG and bilateral posterior cingulate—also showed tissue loss; critically, these

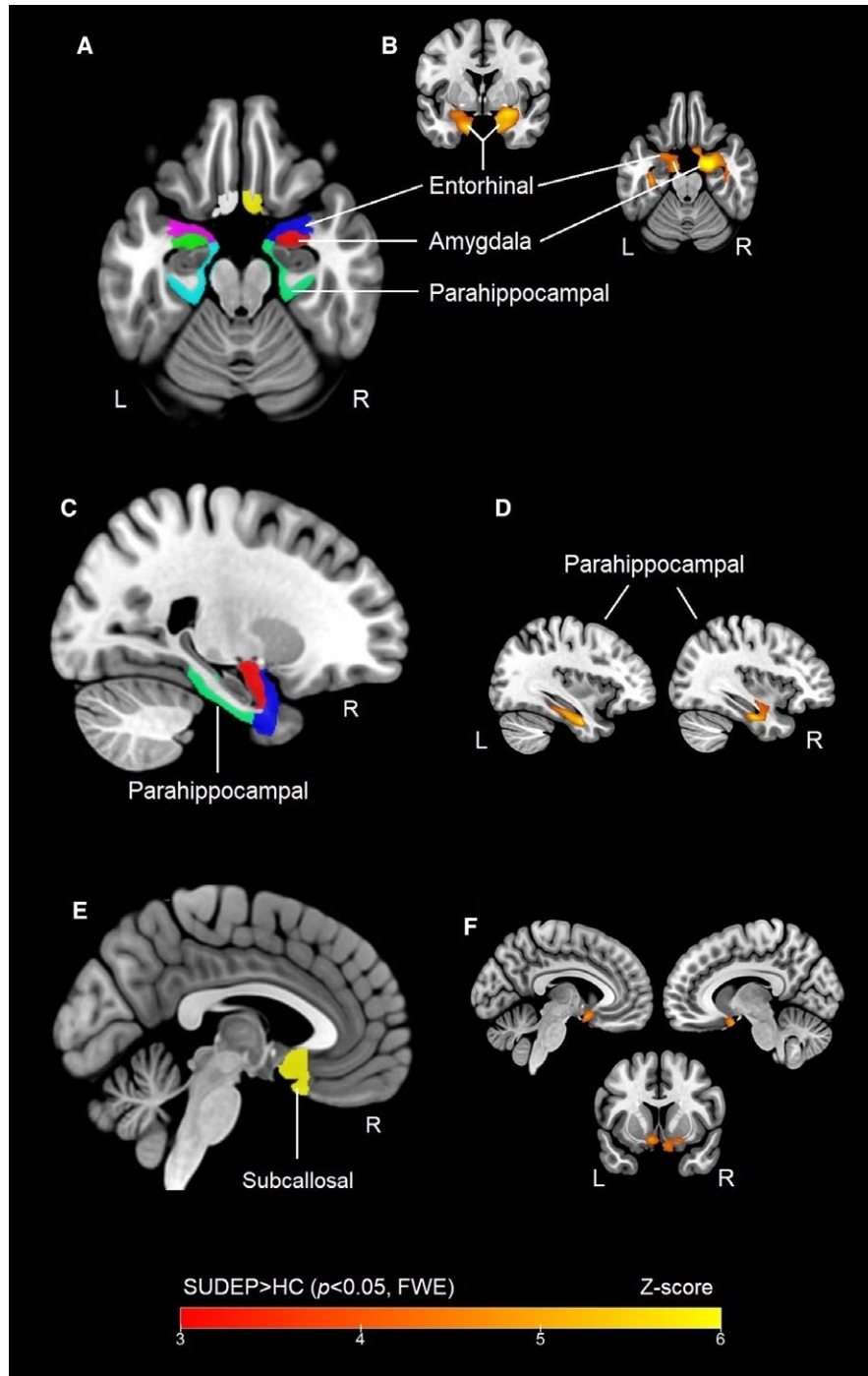


FIGURE 3 Regional volume increases in sudden unexpected death in epilepsy (SUDEP) compared with healthy controls (HC), in the bilateral amygdala, entorhinal cortex, subcallosal cortex, and parahippocampal gyrus (B, D and F). Statistical Parametric Mapping contrast is overlaid in warm colors (red-yellow). Parcellation analyses (A, C, and E) show masks of segmented regions exhibiting increased size in SUDEP > HC ($P < 0.05$ familywise error [FWE]-corrected) overlaid in solid colors

findings were evident only in SUDEP. In addition, volume increases appeared in more rostral sites, which trigger apnea (amygdala) and hypotension (subcallosal cortex), most prominently in SUDEP. Many of the alterations appeared in comparison both to healthy controls and to patients with epilepsy at low risk for SUDEP.

4.2 | Cerebellar volume loss

Extensive volume loss within the cerebellum was apparent in SUDEP, and to a lesser extent in high-risk patients, compared with healthy controls, but not in low-risk patients. The cerebellum plays a major role in dampening extreme

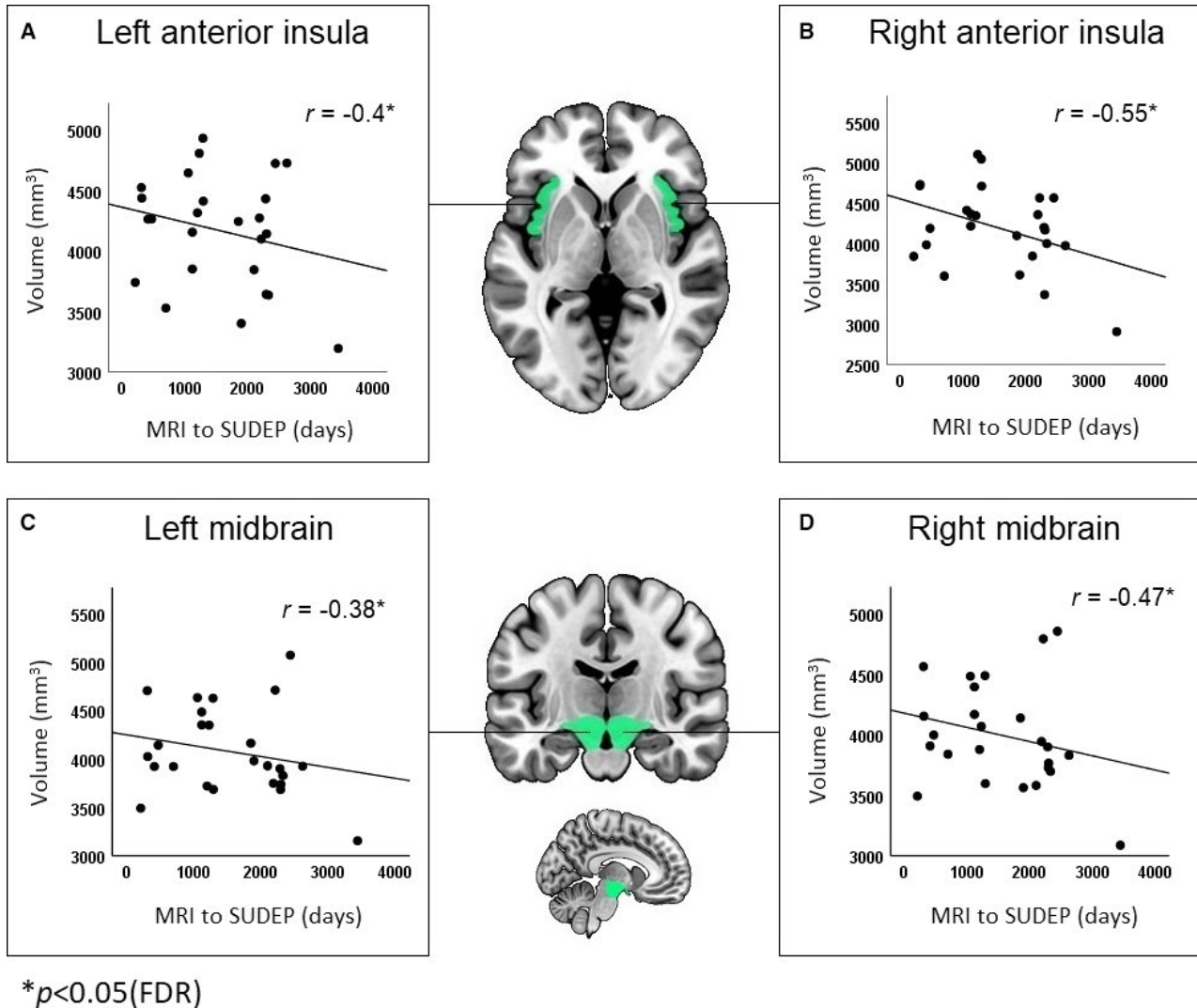


FIGURE 4 Correlations between brain volumes and disease duration across all epilepsy subjects (A, B) and time from magnetic resonance imaging (MRI) to sudden unexpected death in epilepsy (SUDEP) in SUDEP cases only (C-F). *Significant at $P < 0.05$ (false discovery rate [FDR]-corrected). Covariates were seizure frequency, age, sex, and total intracranial volume (and disease duration for C and D)

blood pressure changes,¹⁰ chemosensing, recovery from hypercarbia,¹¹ and timing of upper airway and diaphragm action in obstructive and central apnea,¹² all relevant issues in the circumstances surrounding SUDEP.¹³ Cerebellar volume loss occurs commonly in epilepsy and is associated with poor surgical outcome,¹⁴ chronicity,¹⁵ GTCSs,¹⁶ and AED use.⁹ These issues are of major concern, because all, particularly poor surgical outcome¹⁷ and GTCSs,¹⁸ involve cohorts at greatest risk of SUDEP. The substantial cerebellar tissue loss may result from excitotoxic processes following excessive activation of pontine or long climbing fibers of olivary projections. The structural impingement of climbing fibers on Purkinje dendrites is such that excessive activation readily kills Purkinje neurons,¹⁹ a process well known in the neurotoxicity field, but presumably operating similarly with hypoxia or ischemia from prolonged apnea or hypotension during ictal events. Successive ictal

episodes accompanying chronic GTCSs would lead to repetitive apneic periods or rapid declines in blood pressure, establishing a scenario for Purkinje cell death. The damaged Purkinje cells cannot effectively control the deep fastigial “autonomic” and “breathing” nuclei, reducing the potential for recovery from hypotension or apnea. Profound hypotension often accompanies ictal events in GTCSs^{20,21}; an inability to recover from such blood pressure losses may lead to SUDEP.²²

4.3 | Cerebellar volume loss: breathing implications

The cerebellum is instrumental in recovery from compromised breathing circumstances.²³ Cerebellar somatomotor coordination is essential for timely dilation of the upper airway ahead of descent of the diaphragm; such coordination

prevents airway collapse in obstructive apnea. This coordination is sometimes lost in syndromes with cerebellar injury and compromised breathing such as heart failure, as demonstrated by out-of-phase cerebellar functional MRI signals in response to breathing challenges²⁴; cerebellar injury accompanies heart failure. Cerebellar participation is needed to restore breathing from sustained central apnea; the deep cerebellar nuclei contain chemosensitive neurons to assist recovery from increased hypercapnia.

4.4 | Descending influences from damaged structures

Altered structures in anterior areas have the potential to exaggerate those descending influences on cardiorespiratory areas, or in other areas with tissue loss, reduce influences. Volume loss appeared in the PAG and bilateral posterior cingulate in SUDEP, as well as the left posterior thalamus and hippocampus in both SUDEP and high-risk groups; the latter finding has been described earlier,³ with the posterior thalamic damage presumably contributing to failure to sense low oxygen and hypercapnia²⁵; dysfunctional responses to hypercapnia²⁵ are pronounced in the left posterior thalamus in congenital central hypoventilation syndrome. The PAG receives direct projections from the amygdala central nucleus.²⁶ Both the PAG and posterior cingulate assist respiratory and cardiovascular regulation, showing single neuron discharge related to both breathing and cardiac timing.²⁷ PAG volume loss has been shown earlier in SUDEP.²⁸

Hippocampal tissue loss is common in epilepsy, and as with cerebellar Purkinje neurons, likely results from excitotoxic processes, in the hippocampal case presumably from overexcitation of Schaffer collaterals (axonal collaterals from CA3 pyramidal cells that project to the CA1 of hippocampus). These projections are glutamatergic (ie, excitatory), with the potential for cell destruction with exaggerated hypoxia-induced activation.

The ventrolateral PAG can elicit substantial increases in sustained (ie, “freezing”) muscle tone via the lateral vermis of the cerebellum, a source of concern when attempting to initiate cyclic breathing during an ictal event.²⁹ Deficient cardiorespiratory compensatory mechanisms mediated by the PAG have been shown to contribute to SUDEP in mice.³⁰

Volume loss of PAG, posterior cingulate, left posterior thalamus, and hippocampus raises the possibility that compromised excitatory or timing signals from descending influences on the cerebellum may further blunt central breathing control.

4.5 | Anterior limbic volume increases

The increased amygdala volume is relevant because of its marked influences on breathing; stimulation elicits apnea

in human epilepsy³¹ and triggering of respiratory phase changes in animal models.³² Similar amygdala volume increases have been described in SUDEP³ and in the common epilepsies.³³ Volume increases may result from multiple processes, including enhanced activation from experience³⁴ and inflammatory processes.³⁵ Increased bilateral amygdala and hippocampus volume is observed in a subtype of subjects with mesial temporal lobe epilepsy³⁶; these subjects also have the poorest surgical outcome and are at greatest risk of SUDEP.¹⁷ Increased amygdala volume may reflect a heightened propensity for processes leading to apnea, which if not corrected by cerebellar recovery sites due to volume loss could result in an increased potential for a fatal outcome.

A potential explanation, and notable limitation of this study, is that the elevated medial temporal volume may result from tissue sagging from brain atrophy, particularly in the posterior fossa, which can cause tissue accumulation in the medial fossa. Future studies evaluating epilepsy cohorts, particularly those involving subjects with chronic epilepsy, should take this possibility into account.

The subcallosal cortex was enlarged only in SUDEP, and represents a significant concern if enhanced volumes indicate increased influences; electrical stimulation of the structure results in profound hypotension.²² As with amygdala influences, the combination of ineffectual cerebellar dampening of hypotension with enhanced subcallosal-elicited blood pressure declines could be catastrophic.

4.6 | Antiepileptic drugs

Cerebellar atrophy in patients with epilepsy following use of particular AEDs, such as phenytoin, is well described.⁹ We documented medication history of all patients, including exposure to phenytoin. The number of patients with phenytoin exposure in the SUDEP, high-risk, and low-risk groups was five, eight, and three, respectively, with only two SUDEP and three high-risk patients having long-term use (>10 years). Subanalyses of the SUDEP and high-risk groups, with removal of those with phenytoin exposure (and controlling for phenytoin use as a binary covariate), showed similar patterns of cerebellar volume loss to those groups before removal, although reduced in extent (particularly in lateral cerebellar areas; Figure 4), suggesting that tissue loss here, specifically in the vermis, a region particularly important in blood pressure control, cannot be solely attributed to phenytoin use. Notably, removing these subjects did not significantly alter other findings of increased or decreased volume. Across groups, the number of AEDs in the treatment regimen of patients at scan time did not significantly differ. However, high-risk patients had, on average, tried a number of AEDs throughout their epilepsy duration that was significantly greater than for SUDEP cases

and low-risk patients. No significant differences between SUDEP and low-risk patients appeared with total number of AEDs historically trialed. Although high-risk subjects and SUDEP cases had historically tried a greater number of AEDs compared with low-risk subjects, there is currently little evidence to suggest that any individual AED or combination of AEDs is responsible for SUDEP or a significant elevation in risk. Specifically, lamotrigine is not associated with increased SUDEP risk, as was previously thought, and the number of AEDs used is not an independent SUDEP risk factor.³⁷ Rather, additional AEDs reduce the risk of SUDEP in drug-refractory patients.³⁸ It should, however, be noted that the precise role of AEDs in SUDEP risk is not entirely clear, and studies exploring this aspect are needed. In summary, the role of seizures or AED use in cerebellar atrophy in epilepsy remains unclear, despite evidence for both.^{9,39} However, either scenario is concerning, given the cerebellum's vital roles and the major volume loss in SUDEP. Medication-induced injury remains an important consideration for epilepsy imaging studies.

4.7 | Correlational analyses with clinical variables

Reduced parahippocampal volume correlated with disease duration across all epilepsy subjects. Progressive atrophy of mesial temporal structures occurs in temporal lobe epilepsy,⁴⁰ and reduced volume of subcortical structures, including the parahippocampal gyri, is associated with greater disease duration in the common epilepsies.³³ Our data reinforce an association between reduced subcortical volume and disease duration. It should, however, be noted that, being a cross-sectional design, the current study did not assess progressive changes in structural volumes due to lack of follow-up scans in many subjects. Progressive changes could be assessed with longitudinal imaging studies, which may elucidate the evolution of volumetric alterations and their association with SUDEP risk, a future objective of imaging research into epilepsy and SUDEP.

Bilateral anterior insula and midbrain volumes correlated negatively ($P < 0.05$ FDR-corrected) with time to SUDEP from MRI, meaning volumes were increased the closer to SUDEP from scan time. This suggests that progressive enlargement of certain structures may accompany processes leading to SUDEP, although this would need to be assessed with longitudinal imaging studies.

4.8 | Generalized tonic–clonic seizures

Because both people at high risk and cases of SUDEP experience GTCSs, a key aim of imaging studies is to outline their association with regional volume and consider any changes in relation to group comparisons with people

not experiencing GTCSs (healthy controls and people at low risk). We assessed the association between GTCSs and regional volumes by performing correlational analyses. If regional increases or decreases in volume resulted from GTCSs, significant correlations between GTCS frequency and volume changes should occur. However, correlation analyses with GTCS frequency and the size of structures that showed group differences (ie, the reduced cerebellar, vermal, and thalamic volume, or the increased amygdala, entorhinal, parahippocampal, or subcallosal volume) were not strong or significant in SUDEP or high risk. One structure that showed a significant group difference (SUDEP < healthy control), the right posterior cingulate, showed a weak significant positive correlation with GTCS frequency (only when SUDEP and high-risk subjects were considered in the same group). However, because this was a positive correlation, it may not offer insight into the volume loss of this structure observed in SUDEP. Significant positive correlations between GTCS frequency and volume were also observed for the bilateral anterior cingulate, when combining both SUDEP and high-risk subjects in one group. Cortical thickening of the cingulate has recently been demonstrated in GTCS patients.⁵ Volume elevations associated with gliosis resulting from hyperexcitability due to repeated seizures may be operating,⁴¹ and may be indicative of limbic network dysfunction linked to GTCSs.⁴²

When the high-risk and SUDEP groups were considered separately, correlations between the right posterior cingulate volume and GTCS frequency became nonsignificant in both groups, and the finding of increased anterior cingulate volume with increased GTCS frequency remained the same in high-risk patients but became nonsignificant in SUDEP. In SUDEP cases only, additional significant correlations between volume and GTCS frequency emerged, including a positive correlation with the right hippocampus and negative correlations with the left mid cingulate and left anterior insula. These findings suggest that brain volumetric processes related to elevated GTCS frequency may be manifested differently in high-risk and SUDEP subjects.

Finally, a critical difference between the high-risk and SUDEP groups (which had very similar GTCS frequencies) was volume loss in the PAG and posterior cingulate, and increased volume of the subcallosal cortex, which was evident only in SUDEP. If specific to GTCSs, such volume alterations would be expected in high-risk subjects as well, but this was not the case, suggesting that these alterations may be separate from processes determining GTCS frequency. GTCS will remain a critical issue in all studies investigating SUDEP, especially imaging ones, and efforts to take this into account should be made in any future studies.

4.9 | Stratification of living subjects into high and low risk

Living high- and low-risk patients were classified based on experience and frequency of GTCSs. High-risk subjects were those experiencing more than three GTCSs per year. Although risk stratification is difficult, we based our classification on the leading SUDEP risk factor, which also distinguished >80% of SUDEP cases here. The only variable to distinguish a greater number of SUDEP cases was presence of GTCSs, which is a weaker SUDEP risk factor,¹⁸ and its use to define high-risk would only limit interpretation of results. Although this may be seen as a limitation, it should also be noted that, in doing so, other factors known to influence volume changes, such as disease duration, could be partially accounted for by attempting to match subjects with similar attributes; thus, we were able to shed light not only on imaging changes related to SUDEP but on the greatest risk factor associated with the fatal event.

5 | CONCLUSION

Sudden unexpected death in epilepsy is accompanied by tissue changes within brain structures that trigger cardiovascular and breathing collapse, and cerebellar and brainstem structures that are protective for recovery from such collapse. High-risk subjects showed alterations within similar regions, suggesting such features could be used to prospectively identify patients at risk. Noninvasive volumetric assessments within identified sites may shed light on failing mechanisms and represent further biomarkers of SUDEP.

ACKNOWLEDGMENTS

We are grateful for support from the National Institutes of Health National Institute of Neurological Disorders and Stroke U01-NS090407 (Center for SUDEP Research). J.S.D. and S.B.V. are supported by the National Institute for Health Research University College London Hospitals Biomedical Research Centre (NIHR BRC UCLH/UCL High Impact Initiative). G.P.W. was supported by the Medical Research Council (G0802012, MR/M00841X/1). We are grateful to the Wolfson Foundation and the Epilepsy Society for supporting the Epilepsy Society MRI scanner. This work was supported by the National Institute for Health Research University College London Hospitals Biomedical Research Centre. S.B. was supported by the Muir Maxwell Trust and Epilepsy Society.

DISCLOSURE

None of the authors has any conflict of interest to disclose. We confirm that we have read the Journal's position on issues

involved in ethical publication and affirm that this report is consistent with those guidelines.

ORCID

Gavin P. Winston  <https://orcid.org/0000-0001-9395-1478>

John S. Duncan  <https://orcid.org/0000-0002-1373-0681>

Samden D. Lhatoo  <https://orcid.org/0000-0001-8626-1137>

Luke A. Allen  <https://orcid.org/0000-0002-4988-1457>

REFERENCES

- Ryvlin P, Nashef L, Lhatoo SD, et al. Incidence and mechanisms of cardiorespiratory arrests in epilepsy monitoring units (MORTEMUS): a retrospective study. *Lancet Neurol*. 2013;12:966–77.
- Surges R, Sander JW. Sudden unexpected death in epilepsy: mechanisms, prevalence, and prevention. *Curr Opin Neurol*. 2012;25:201–7.
- Wandschneider B, Koepp M, Scott C, et al. Structural imaging biomarkers of sudden unexpected death in epilepsy. *Brain*. 2015;138:2907–19.
- DeGiorgio CM, Markovic D, Mazumder R, et al. Ranking the leading risk factors for sudden unexpected death in epilepsy. *Front Neurol*. 2017;8:473.
- Ogren JA, Tripathi R, Macey PM, et al. Regional cortical thickness changes accompanying generalized tonic-clonic seizures. *Neuroimage Clin*. 2018;20:205–15.
- Nashef L, So EL, Ryvlin P, et al. Unifying the definitions of sudden unexpected death in epilepsy. *Epilepsia*. 2012;53:227–33.
- Gaser C, Dahnke R. CAT—a computational anatomy toolbox for the analysis of structural MRI data. Paper presented at: 22nd Annual Meeting of the Organization for Human Brain Mapping; June 26–30, 2016; Geneva, Switzerland.
- Cardoso MJ, Modat M, Wolz R, et al. Geodesic information flows: spatially-variant graphs and their application to segmentation and fusion. *IEEE Trans Med Imaging*. 2015;34:1976–88.
- De Marcos FA, Ghizoni E, Kobayashi E, et al. Cerebellar volume and long-term use of phenytoin. *Seizure*. 2003;12:312–5.
- Ramu A, Bergmann F. The role of the cerebellum in blood pressure regulation. *Experientia*. 1967;23:383–4.
- Calton MA, Howard JR, Harper RM, et al. The cerebellum and SIDS: disordered breathing in a mouse model of developmental cerebellar Purkinje cell loss during recovery from hypercarbia. *Front Neurol*. 2016;7:78.
- Henderson LA, Woo MA, Macey PM, et al. Neural responses during Valsalva maneuvers in obstructive sleep apnea syndrome. *J Appl Physiol*. 2003;94:1063–74.
- Massey CA, Sowers LP, Dlouhy BJ, et al. Mechanisms of sudden unexpected death in epilepsy: the pathway to prevention. *Nat Rev Neurol*. 2014;10:271–82.
- Marcian V, Marecek R, Koritakova E, et al. Morphological changes of cerebellar substructures in temporal lobe epilepsy: a complex phenomenon, not mere atrophy. *Seizure*. 2018;54:51–7.
- Oyegbile TO, Bayless K, Dabbs K, et al. The nature and extent of cerebellar atrophy in chronic temporal lobe epilepsy. *Epilepsia*. 2011;52:698–706.

16. Szabo CA, Lancaster JL, Lee S, et al. MR imaging volumetry of subcortical structures and cerebellar hemispheres in temporal lobe epilepsy. *AJNR Am J Neuroradiol.* 2006;27:2155–60.
17. Tomson T, Nashef L, Ryvlin P. Sudden unexpected death in epilepsy: current knowledge and future directions. *Lancet Neurol.* 2008;7:1021–31.
18. Harden C, Tomson T, Gloss D, et al. Practice guideline summary: sudden unexpected death in epilepsy incidence rates and risk factors: report of the Guideline Development, Dissemination, and Implementation Subcommittee of the American Academy of Neurology and the American Epilepsy Society. *Neurology.* 2017;88:1674–80.
19. Welsh JP, Yuen G, Placantonakis DG, et al. Why do Purkinje cells die so easily after global brain ischemia? Aldolase C, EAAT4, and the cerebellar contribution to posthypoxic myoclonus. *Adv Neurol.* 2002;89:331–59.
20. Lhatoo S, Noebels J, Whittemore V, et al. Sudden unexpected death in epilepsy: identifying risk and preventing mortality. *Epilepsia.* 2015;56:1700–6.
21. Bozorgi A, Chung S, Kaffashi F, et al. Significant postictal hypotension: expanding the spectrum of seizure-induced autonomic dysregulation. *Epilepsia.* 2013;54:e127–30.
22. Lacuey N, Hampson JP, Theeranaew W, et al. Cortical structures associated with human blood pressure control. *JAMA Neurol.* 2018;75:194–202.
23. Xu F, Frazier DT. Role of the cerebellar deep nuclei in respiratory modulation. *Cerebellum.* 2002;1:35–40.
24. Ogren JA, Macey PM, Kumar R, et al. Impaired cerebellar and limbic responses to the Valsalva maneuver in heart failure. *Cerebellum.* 2012;11:931–8.
25. Harper RM, Macey PM, Woo MA, et al. Hypercapnic exposure in congenital central hypoventilation syndrome reveals CNS respiratory control mechanisms. *J Neurophysiol.* 2005;93:1647–58.
26. Hopkins DA, Holstege G. Amygdaloid projections to the mesencephalon, pons and medulla oblongata in the cat. *Exp Brain Res.* 1978;32:529–47.
27. Ni HF, Zhang JX, Harper RM. Cardiovascular-related discharge of periaqueductal gray neurons during sleep-waking states. *Brain Res.* 1990;532:242–8.
28. Mueller SG, Bateman LM, Laxer KD. Evidence for brainstem network disruption in temporal lobe epilepsy and sudden unexplained death in epilepsy. *Neuroimage Clin.* 2014;5:208–16.
29. Koutsikou S, Crook JJ, Earl EV, et al. Neural substrates underlying fear-evoked freezing: the periaqueductal grey-cerebellar link. *J Physiol.* 2014;592:2197–213.
30. Kommajosyula SP, Tupal S, Faingold CL. Deficient post-ictal cardiorespiratory compensatory mechanisms mediated by the periaqueductal gray may lead to death in a mouse model of SUDEP. *Epilepsy Res.* 2018;147:1–8.
31. Dlouhy BJ, Gehlbach BK, Kreple CJ, et al. Breathing inhibited when seizures spread to the amygdala and upon amygdala stimulation. *J Neurosci.* 2015;35:10281–9.
32. Harper RM, Frysinger RC, Trelease RB, et al. State-dependent alteration of respiratory cycle timing by stimulation of the central nucleus of the amygdala. *Brain Res.* 1984;306:1–8.
33. Whelan CD, Altmann A, Botia JA, et al. Structural brain abnormalities in the common epilepsies assessed in a worldwide ENIGMA study. *Brain.* 2018;141:391–408.
34. Lazar SW, Kerr CE, Wasserman RH, et al. Meditation experience is associated with increased cortical thickness. *Neuroreport.* 2005;16:1893–7.
35. Vezzani A, Granata T. Brain inflammation in epilepsy: experimental and clinical evidence. *Epilepsia.* 2005;46:1724–43.
36. Bernhardt BC, Hong SJ, Bernasconi A, et al. Magnetic resonance imaging pattern learning in temporal lobe epilepsy: classification and prognostics. *Ann Neurol.* 2015;77:436–46.
37. Hesdorffer DC, Tomson T, Benn E, et al. Do antiepileptic drugs or generalized tonic-clonic seizure frequency increase SUDEP risk? A combined analysis. *Epilepsia.* 2012;53:249–52.
38. Ryvlin P, Cucherat M, Rheims S. Risk of sudden unexpected death in epilepsy in patients given adjunctive antiepileptic treatment for refractory seizures: a meta-analysis of placebo-controlled randomised trials. *Lancet Neurol.* 2011;10:961–8.
39. Hagemann G, Lemieux L, Free SL, et al. Cerebellar volumes in newly diagnosed and chronic epilepsy. *J Neurol.* 2002;249:1651–8.
40. Caciagli L, Bernasconi A, Wiebe S, et al. A meta-analysis on progressive atrophy in intractable temporal lobe epilepsy: time is brain? *Neurology.* 2017;89:506–16.
41. Binder DK, Steinhäuser C. Functional changes in astroglial cells in epilepsy. *Glia.* 2006;54:358–68.
42. Bernhardt BC, Worsley KJ, Besson P, et al. Mapping limbic network organization in temporal lobe epilepsy using morphometric correlations: insights on the relation between mesiotemporal connectivity and cortical atrophy. *Neuroimage.* 2008;42:515–24.

SUPPORTING INFORMATION

Additional supporting information may be found online in the Supporting Information section at the end of the article.

How to cite this article: Allen LA, Vos SB, Kumar R, et al. Cerebellar, limbic, and midbrain volume alterations in sudden unexpected death in epilepsy. *Epilepsia.* 2019;00:1–12. <https://doi.org/10.1111/epi.14689>