

# UC Davis

## UC Davis Previously Published Works

### Title

Parkinsonism Versus Concomitant Parkinson's Disease in Fragile X-Associated Tremor/Ataxia Syndrome

### Permalink

<https://escholarship.org/uc/item/1rk4n147>

### Journal

Movement Disorders Clinical Practice, 7(4)

### ISSN

2330-1619

### Authors

Salcedo-Arellano, María Jimena  
Wolf-Ochoa, Marisol Wendy  
Hong, Tiffany  
[et al.](#)

### Publication Date


2020-05-01

### DOI

10.1002/mdc3.12942

Peer reviewed

# Parkinsonism Versus Concomitant Parkinson's Disease in Fragile X–Associated Tremor/Ataxia Syndrome

María Jimena Salcedo-Arellano, MD,<sup>1,2,3,4</sup>  Marisol Wendy Wolf-Ochoa, BS,<sup>3,4</sup> Tiffany Hong, MS,<sup>3,4</sup> Sarwat Amina, PhD,<sup>3,4</sup> Flora Tassone, PhD,<sup>2,5</sup> Mirna Lechpammer, MD,<sup>4</sup> Randi Hagerman, MD,<sup>1,2</sup> and Verónica Martínez-Cerdeño, PhD<sup>2,3,4,\*</sup>

**ABSTRACT:** **Background:** Fragile X–associated tremor/ataxia syndrome (FXTAS) is a late-onset neurodegenerative disorder associated with premutation alleles (55–200 CGG repeats) of the fragile X mental retardation 1 (*FMR1*) gene. FXTAS is characterized by the presence of ubiquitin-positive inclusions in neurons and astrocytes and by cerebellar tremor and ataxia. Parkinsonism has been reported in FXTAS, but most patients lack the characteristic rest tremor and severe rigidity seen in idiopathic Parkinson's disease (PD). **Objective:** To describe the frequency of concomitant PD in FXTAS. **Methods:** We reviewed the medical record of 40 deceased patients diagnosed with FXTAS and performed a pathology analysis to confirm both FXTAS and PD. **Results:** Clinical histories indicated that 5 FXTAS patients were diagnosed with idiopathic PD and 2 with atypical parkinsonian syndrome. After pathological examination, we found that 7 patients in the PD clinical diagnosis group had dopaminergic neuronal loss; however, only 2 of 7 presented Lewy bodies (LBs) in the substantia nigra. Therefore, a total of 5% of the 40 cohort patients met the pathologic criteria for the concomitant diagnosis of FXTAS and PD. In addition, 2 patients not clinically diagnosed with PD also had nigral neuronal loss with LBs in substantia nigra. In total 10% of these 40 patients had LBs. **Conclusion:** This report expands our understanding of clinical symptoms and unusual presentations in patients with FXTAS and the concept that the parkinsonism found in FXTAS is sometimes indistinguishable from PD. We propose that *FMR1* should be recognized as one of the exceptional genetic causes of parkinsonism with presynaptic dopaminergic loss and LBs.

Fragile X–associated tremor/ataxia syndrome (FXTAS) is a late-onset neurodegenerative disorder associated with premutation alleles (55–200 CGG repeats) of the fragile X mental retardation 1 (*FMR1*) gene. Expansions of more than 200 CGG repeats give rise to fragile X syndrome, the most common inherited form of cognitive impairment.<sup>1,2</sup> FXTAS is characterized by the presence of ubiquitin-positive inclusions in neurons, astrocytes, and Purkinje cells. FXTAS symptoms include cerebellar ataxia, postural/intention tremor, cognitive deficits, peripheral neuropathy, autonomic dysfunction, and psychiatric involvement.<sup>3</sup> Parkinsonism has also been reported in

FXTAS in approximately 29% to 60% of patients<sup>4,5</sup>; the presentation is heterogeneous, and more than 50% show bradykinesia, approximately 70% present with mild rigidity in the upper limbs, and 25% to 40% of the patients with FXTAS may develop a mild rest tremor at the later stages of the disease. However, although the premutation is not typically associated with a pure Parkinson's disease (PD) phenotype, some carriers do have many classic features of idiopathic PD.<sup>5–7</sup>

Parkinsonism is the clinical term for disorders with prominent bradykinesia and variable associated symptoms that are accompanied

<sup>1</sup>Department of Pediatrics, University of California, Davis, School of Medicine, Sacramento, California, USA; <sup>2</sup>Medical Investigation of Neurodevelopmental Disorders Institute (MIND), University of California, Davis, Sacramento, California, USA; <sup>3</sup>Institute for Pediatric Regenerative Medicine and Shriners Hospitals for Children Northern California, Sacramento, California, USA; <sup>4</sup>Department of Pathology and Laboratory Medicine, University of California, Davis, School of Medicine, Sacramento, California, USA; <sup>5</sup>Department of Biochemistry and Molecular Medicine, University of California, Davis, Sacramento, California, USA

\*Correspondence to: Dr. Verónica Martínez-Cerdeño, Shriners Hospital for Children Northern California, 2425 Stockton Blvd., Sacramento, CA 95817; E-mail: vmartinezcerdeno@ucdavis.edu

**Keywords:** fragile X mental retardation 1 gene, fragile X associated tremor/ataxia syndrome, Parkinson's disease, parkinsonism, neuropathology. Relevant disclosures and conflicts of interest are listed at the end of this article.

Received 6 January 2020; revised 10 February 2020; accepted 9 March 2020.

Published online 9 April 2020 in Wiley Online Library (wileyonlinelibrary.com). DOI: 10.1002/mdc3.12942

by the degeneration of the nigrostriatal dopaminergic system.<sup>8</sup> Parkinsonism diseases include but are not limited to PD, diffuse Lewy body (LB) disease, progressive supranuclear palsy, multiple system atrophy, corticobasal degeneration, vascular parkinsonism, and drug-induced parkinsonism.<sup>8</sup> PD is a heterogenous entity in which the major symptom is parkinsonism that is usually idiopathic or attributed to familial mutations and that fulfills specific clinical and pathological diagnostic criteria. The Movement Disorder Society clinical diagnostic criteria for PD includes bradykinesia in combination with either rest tremor, rigidity, or both.<sup>8</sup> The pathological criterion for PD is the combination of neuronal loss and the presence of LBs and/or Lewy neurites, which are the product of the pathological aggregation of  $\alpha$ -synuclein in neuronal cells and their processes, respectively, in surviving dopaminergic neurons in the substantia nigra (SN). The finding of dopaminergic cell loss in the SN alone is not sufficient to diagnose definite PD.

## Methods

### Sample Collection

Samples from 40 FXTAS postmortem human subjects, 28 males and 12 females, were obtained from the FXTAS/FXS brain repository at the University of California, Davis, School of Medicine. All donors had given written informed consent for a brain autopsy and the use of the material and clinical information for research purposes. The bank currently holds 70 brains from pre-mutation carriers. Patients with FXTAS had symptoms for many years before death and were clinically diagnosed based on the presence of intention tremor, cerebellar gait ataxia, parkinsonism, memory, and executive function deficits and the presence of the *FMR1* premutation.<sup>9</sup> The diagnosis was confirmed with the postmortem presence of intranuclear ubiquitin positive inclusions in neurons and astrocytes. Brains from donors with a gray zone expansion (44–54 CGG repeats) and those lacking complete medical histories or missing neuropathological reports were excluded from our analysis.

### Macroscopic Analysis

Every brain was cut in 1 cm coronal slices. Weight of the fresh and fixed brain was recorded with attached and detached posterior fossa content. High-quality photographs were taken for further comparison with radiological findings. We evaluated cortical ribbon thickness, architectural abnormalities such as abnormal gyration, corpus callosum thickness, size of the ventricles, gray–white matter junction, and firmness in the cortical vascular watershed regions. The hippocampus was examined for possible malrotation. The size and shape of the caudate, putamen, globus pallidus, mammillary bodies, and thalamus were inspected as well. Both the brainstem and the cerebellum were cut perpendicular to the long axis of the brainstem for the evaluation of the cerebellar cortical thickness, the size and shape of white matter and deep nuclei, and pigmentation of SN and locus coeruleus.

### Microscopic Analysis

Blocks from donor brains were fixed by immersion in formalin, embedded in paraffin wax, and cut at a section thickness of 5  $\mu$ m. Sections of the mid-SN were examined under light microscopy to estimate neural loss. The main histological stain for all cases was hematoxylin and eosin; the samples were also stained with  $\alpha$ -synuclein to evaluate positive intraneural inclusions and neurites. The definitive neuropathological diagnosis of PD was given to cases presenting with at least 1 LB in the SN in addition to significant neuronal cell loss in the SN.

### CGG Repeat Sizing

All cases had known premutation status prior to their death. Genomic DNA was isolated from brain tissue (100 mg) using standard procedures (Trizol; Invitrogen, Carlsbad, CA). CGG repeat allele size was determined using both polymerase chain reaction and Southern blot analysis as previously described.<sup>10,11</sup>

### Immunostaining

A block of tissue ( $2 \times 2 \times 0.25 \mu\text{m}^2$ ) containing the SN for each case was immersed in 30% sucrose (Fisher, Hampton, NH) and embedded in optimal cutting temperature compound (Fisher). Blocks were cut into 5  $\mu$ m sections using a cryostat. We used the primary monoclonal antibody against  $\alpha$ -synuclein stain, secondary antibody donkey antirabbit conjugated with biotin (1:150; Jackson Laboratory, Bar Harbor, ME), amplified with avidin-biotin complex (ABC; Vector Laboratories, Burlingame, CA), and developed with 3,3'-diaminobenzidine (DAB) (Vector). Tissue was dehydrated and defatted, mounted on glass slides, and coverslipped with dibutylphthalate polystyrene xylene.

### Definition of Parkinsonism

A systematic review of the entire available medical history of the 40 premutation carriers with confirmed diagnoses of FXTAS was performed. The authors looked for the medical report of core parkinsonian features: masked facies, bradykinesia, rest tremor, limb rigidity, shuffling gait, and low voice tone. The 7 cases with a diagnosis of idiopathic PD or atypical parkinsonian syndrome were diagnosed and followed by neurologists for many years prior to their death. The authors are unaware of the diagnostic criteria used at the time the clinical diagnosis was made.

## Results

We reviewed the clinical history of 40 deceased patients previously diagnosed with FXTAS. We performed gross and histopathological analysis in all patients. Of the 40 patients, 18 (45%) were reported by their physician to have parkinsonian features, 11 of 28 males (39%) and 7 of 12 females (58%); 7 (17.5%) of them, 4 males and 3 females, were clinically diagnosed with either idiopathic PD or atypical parkinsonian syndrome. All 7 presented with

bradykinesia and muscle rigidity and 4 also presented with mild tremor at rest always accompanied by intention tremor. Pathological analysis reported nigral neuronal loss in all patients, ranging from mild to moderate, but only 2 had concomitant LBs in the SN. In addition, 2 patients were never diagnosed with PD based on their clinical presentation, but the postmortem pathology reported both reduced pigmentation of SN as well as the presence of LBs in the cytoplasm that were synuclein positive. In both cases the finding of LBs is considered incidental<sup>12</sup>; however, it may represent presymptomatic PD in the very beginning stages of the disease<sup>13</sup> or mild symptomatology was masked by other neurological findings resulting from a different concomitant pathology specifically FXTAS. After performing gross and microscopic analysis, we found that only 5% of the patients met the definite criteria of concomitant PD with FXTAS (Fig. 1); however, a total of 10% of the 40 FXTAS brains had LBs. Clinical and pathological features for the evaluated patients are summarized in Table 1. We herein included a short clinical synopsis for those cases found with LB pathology.

## Case 1

Case 1 is an 81-year-old male with 75 CGG repeats with a diagnosis of FXTAS because of an intention tremor and ataxia that was also diagnosed with PD 5 years before death. He also experienced rest tremor, rigidity, hallucinations, paranoia, delusions, anxiety, depression, sleep difficulties, and problems swallowing. In addition, medical history included antral ulcer, carotid vascular disease, gout, hypercholesterolemia, hyperlipidemia, bladder carcinoma, and benign prostate hyperplasia. Neurological exam revealed rest and intention tremor, ataxia, dementia, and cogwheeling rigidity. He received donepezil to treat his dementia during his last year of life and carbidopa levodopa for PD. His last admission to the hospital was attributed to delirium secondary to sepsis from a urinary tract infection and pneumonia. He died less than a month later. Pathology revealed slight

generalized atrophy on the right cerebellar and cerebral hemispheres, mildly atrophied hippocampus, and mild pigment loss in the SN and locus coeruleus with Lewy body disease in the SN, locus coeruleus, and deep layers of para-hippocampal cortex, but no neocortical LBs. He met the criteria for definite PD by his pathology showing Braak 4 (see Table 1).

## Case 7

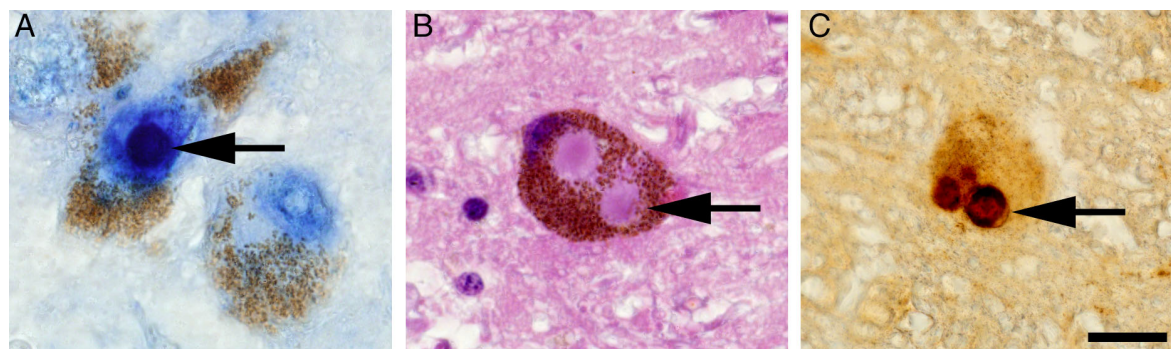
This is a case of an 84-year-old male with 71 CGG repeats. He developed intention tremor and parkinsonian symptoms during his 70s. He received a PD diagnosis by the age of 80. He was unable to walk without a cane by 82 with a rapid deterioration leading to his death 2 years later. Pathology evaluation demonstrated FXTAS intranuclear inclusions in neurons of the hippocampus and SN as well as marked loss of Purkinje cells. He also had moderate loss of dopaminergic cells and the presence of LBs in the SN.

## Case 8

This is a case of a 67-year-old male with 112 CGG repeats. His balance problems started in his early 60s; however, intention tremor and parkinsonism were not evident until the age of 66 and are reported as mild in the clinical history. He also had history of a mild right-sided stroke 5 years before death. He was never diagnosed with PD or related diseases. His medical record reported resistant hypertension requiring treatment with multiple antihypertensive medications as well as social anxiety, sleep apnea, and prostate cancer. Pathology evaluation showed FXTAS inclusions as well as loss of pigmentation of the SN and the presence of LBs.

## Case 9

Case 9 is an 81-year-old male with 67 CGG repeats. He developed balance problems starting in his mid-70s leading to frequent



**FIG. 1.** Pathology of concomitant fragile X-associated tremor/ataxia syndrome and Parkinson's disease. (A) Ubiquitin positive intranuclear inclusion (blue) in a dopaminergic cell of the substantia nigra (brown = dopamine). (B) Lewy bodies in dopaminergic neuron (hematoxylin and eosin staining; brown = dopamine). (C)  $\alpha$ -Synuclein (dark brown) positive Lewy bodies in dopaminergic neuron (light brown = dopamine). Arrows point to inclusions and Lewy bodies. Scale bar: 30  $\mu$ m. Images taken from case 9.

**TABLE 1** Summary of clinical presentation and pathology findings

Case	1	2	3	4	5	6	7	8	9
Sex	M	F	M	F	F	M	M	M	M
Age at death	81	91	74	80	83	69	84	67	81
CGG	75	30,57	79	30,75	27,59	58	71	112	67
Clinical Dx	PD	PD	PD	Atypical parkinsonian syndrome	PD	Atypical parkinsonian syndrome	PD	No clinical dx of PD	No clinical dx of PD
Age at onset of symptoms	70	80	65	72	78	65	70	61	75
First neurologic symptom	Rest tremor	Rest tremor	Gait ataxia	Gait ataxia	Intermittent rest tremor	Mild kinetic tremor	Rest tremor	Gait ataxia	Muscle weakness
Medical treatment	Carbidopa levodopa for 5 years, donepezil	Memantine, ropinirole	Carbidopa levodopa with response, deep brain stimulation	Carbidopa levodopa	Carbidopa levodopa, memantine, donepezil	Carbidopa levodopa, ropinirole	NA	None	None
FXTAS stage	3	5	NA	4	5	NA	3	4	NA
Motor syndrome									
Kinetic tremor	+	+	+	+	+	+	+	+	+
Rest tremor	+	-	+	-	+	-	+	+	+
Cerebellar ataxia	+	+	+	+	-	+	-	+	+
Muscular rigidity	+	+	+	+	+	+	+	-	-
Bradykinesia	+	+	+	+	+	+	+	-	-
Masked facies	-	+	-	+	+	-	+	-	-
Neuropsychiatric profile									
Anxiety	+	-	+	-	-	-	-	+	-
Depression	+	-	+	-	-	-	-	-	-
Dementia	+	+	-	+	+	-	-	-	-
Psychosis/paranoia	+	-	-	-	-	-	-	-	-
Pathology									
Intranuclear inclusions	+	+	+	+	+	+	+	+	+
LB	+	-	-	-	-	-	-	+	+
Braak stage	4	≤2	≤2	≤2	≤2	No PD pathology in CNS	3	3	3
Dopaminergic neuronal loss	Mild	+	+	+	Mild	Mild	+	Mild	Mild
Other highlights	LBS found in SN, locus ceruleus, and deep layers of parahippocampal cortex	Small vessel disease	Mild thin central cortex	Shortening of the frontal pole and thin superior temporal gyrus	Iron deposits in cerebellum	Hemosiderin laden macrophages	Marked drop out of Purkinje cells	Twin inclusions found in Purkinje cells	Neurofibrillary tangles Mitochondrial myopathy (accumulation of abnormal mitochondria)

Cases included in this study, their symptoms, presence of LBS, and loss of dopaminergic cells in the SN. .2 indicates that tissue from the olfactory nucleus and lower brainstem was unavailable for analysis. M, male; F, female; PD, Parkinson's disease; dx, diagnosis; FXTAS, fragile X-associated tremor/ataxia syndrome; NA, not available at time of death; LBS, Lewy bodies; CNS, central nervous system; SN, substantia nigra.

falling. His clinical history is remarkable for the diagnosis of mitochondrial myopathy with severe dysphagia and proximal muscle weakness at the age of 77. Muscle biopsy reported some muscle fibers containing an accumulation of structurally abnormal mitochondria displaying dense bodies and crystalloid inclusions. He presented with mild tremor, predominantly intentional, and required the use of a walker as a result of ataxia and muscle weakness. His other medical problems included prostate cancer at the age of 70, decreased bone density, arteriosclerotic heart disease requiring angioplasty of the right coronary artery, cataract surgery at the age of 79, and memory loss during the last month of his life. He was never diagnosed with PD or Alzheimer's disease. Pathological evaluation found moderate cortical atrophy, neurofibrillary tangles in the hippocampus, and reduced pigmentation in the lateral portion of SN as well as the presence of LB and FXTAS inclusions.

## Discussion

Parkinsonism is reported in approximately 29% to 60% of patients diagnosed with FXTAS<sup>5,6</sup> with rigidity and bradykinesia being the most prevalent of the parkinsonian symptoms.<sup>5,6</sup> In our patient cohort, 45% of the patients had parkinsonian features reported in their medical record. PD is the most common of the recognized parkinsonian disorders. The variability of its clinical presentation keeps challenging the established criteria for diagnosis of PD. However, the motor syndrome with the pathological findings of SN neurodegeneration and synuclein deposition forming LBs remain the gold standard of PD diagnosis.<sup>14</sup> PD is then defined as a synucleinopathy. However, an exception category has recently been created by the Movement Disorder Society to include genetic cases—parkin (*PRKN*) and leucine rich repeat kinase 2 (*LRRK2*)—that meet the clinical PD criteria but have infrequent<sup>15,16</sup> or absent LBs on autopsy.<sup>17</sup> *PRKN*-PD has an autosomal recessive inheritance pattern and an early onset of the disease.<sup>18</sup> On the other hand, *LRRK2* is especially prevalent in some populations; however, it has a very low penetrance.<sup>19</sup> These 2 genes are part of a handful of genes recognized to form monogenic forms of PD.<sup>18</sup> Of the 7 patients, 5 clinically diagnosed with PD in our patient cohort had an absence of LBs on pathological evaluation; however, their late onset of clinical symptoms and the absence of family history makes the presence of parkinsonism less likely to be attributable to *PRKN* or *LRRK2* mutations.

We also came across with the fact that the 7 FXTAS cases clinically diagnosed with PD had a CGG repeat number in the lower end of the premutation range: between 57 and 79 CGG repeats. Prior studies have reported a parkinsonian phenotype in patients with lower size *FMR1* premutation expansions,<sup>20–22</sup> and a very low prevalence of *FMR1* premutation in patients with clinical PD (0%–1%).<sup>23</sup> In fact, the association has been more often found between *FMR1* gray zone alleles (40–54 CGG repeats) and clinical PD in both males and females.<sup>24–27</sup> In premutation carriers, De Pablo-Fernandez and colleagues<sup>28</sup> reported

2 cases of concomitant FXTAS and PD, both also carrying a lower end CGG repeat number. Our findings expand on the concept that the parkinsonism found in patients with FXTAS is sometimes indistinguishable from the parkinsonism described in the diagnostic criteria of idiopathic PD,<sup>29</sup> and many premutation carriers with FXTAS are still erroneously diagnosed with PD alone.<sup>30–33</sup> The clinical presentation can be challenging even to experts in movement disorders because of the extensive symptom overlap between FXTAS and PD with the caveat that the motor symptoms in patients with FXTAS have, in many instances, a positive response to treatment with dopaminergic medications.<sup>29</sup> Even when imaging results show no dopamine transporter deficit,<sup>34</sup> abnormal DaTSCANs have been reported in approximately 47% of patients with FXTAS, specifically those with multiple system atrophy–like features.<sup>35</sup> Screening for the *FMR1* gene premutation should be ordered in patients presenting with intention tremor and/or cerebellar ataxia and a family history of fragile X–related disorders, including fragile X syndrome, fragile X–associated primary ovarian deficiency, or fragile X–associated neuropsychiatric disorder and parkinsonian features or PD. FXTAS caused by RNA toxicity and mitochondrial dysfunction likely leads to dopaminergic depletion, but only a limited number develop LBs. However, our findings provide insufficient support to conclude that mutations in the *FMR1* gene can cause definite PD in the presence of FXTAS. We propose that *FMR1* should be recognized as one of the exceptional genetic causes of parkinsonism and even atypical parkinsonian syndrome with mild to moderate presynaptic dopaminergic loss and sometimes with the presence of LBs (in 10% of FXTAS brains).

## Acknowledgment

The authors would like to thank the donors and their families for their great contribution to the field of neurodegenerative disorders, especially for the further understanding of the pathology of fragile X–associated tremor/ataxia syndrome.

## Author Roles

(1) Research Project: A. Conception, B. Organization, C. Execution; (2) Manuscript Preparation: A. Writing of the First Draft, B. Review and Critique.

M.J.S.-A.: 1A, 1B, 1C, 2A

M.W.W.-O.: 1C

T.H.: 1C

S.A.: 1C

F.T.: 1C, 2B

M.L.: 1C, 2B

R.H.: 1A, 1B, 2B

V.M.C.: 1A, 1B, 1C, 2A, 2B

## Disclosures

**Ethical Compliance Statement:** Postmortem human subjects were obtained from the fragile X–associated tremor/ataxia syndrome/fragile X syndrome brain repository at the University of California, Davis, School of Medicine. All donors had given written informed consent for a brain autopsy and the use of the material and clinical information for research purposes. We confirm that we have read the Journal’s position on issues involved in ethical publication and affirm that this work is consistent with those guidelines.

**Funding Sources and Conflict of Interest:** This research was supported by the National Institute of Child Health and Human Development Grant R01 HD036071, the University of California Davis MIND Institute (Medical Investigation of Neurodevelopmental Disorders) U54 HD 079125, the National Institute of Neurological Disorders and Stroke Grant R01 1NS107131 and Shriners Hospitals for Children–Northern California. The authors declare no conflict of interest.

**Financial Disclosures for the Previous 12 Months:** R.J. Hagerman has received funding from Zynherba, Ovid, and the Azrieli Foundation for carrying out treatment studies in patients with fragile X syndrome. She has also consulted with Fulcrum, Ovid, and Zynherba regarding treatment studies in individuals with fragile X syndrome. F. Tassone has received funds from Asuragen and Zynherba for studies in fragile X syndrome and associated disorders.

## References

- Hagerman PJ. Current gaps in understanding the molecular basis of FXTAS. *Tremor Other Hyperkinet Mov (N Y)* 2012;2.
- Hagerman RJ, Hall DA, Coffey S, et al. Treatment of fragile X-associated tremor ataxia syndrome (FXTAS) and related neurological problems. *Clin Interv Aging* 2008;3(2):251–262.
- Seritan AL, Kim K, Benjamin I, Seritan I, Hagerman RJ. Risk factors for cognitive impairment in fragile X-associated tremor/ataxia syndrome. *J Geriatr Psychiatry Neurol* 2016;29(6):328–337.
- Juncos JL, Lazarus JT, Graves-Allen E, et al. New clinical findings in the Fragile X-Associated Tremor Ataxia Syndrome (FXTAS). *Neurogenetics* 2011;12(2):123–135.
- Niu YQ, Yang JC, Hall DA, et al. Parkinsonism in fragile X-associated tremor/ataxia syndrome (FXTAS): revisited. *Parkinsonism Relat Disord* 2014;20(4):456–459.
- Jacquemont S, Hagerman RJ, Leehey MA, et al. Penetrance of the fragile X-associated tremor/ataxia syndrome in a premutation carrier population. *JAMA* 2004;291(4):460–469.
- Loesch D, Hagerman R. Unstable mutations in the FMR1 gene and the phenotypes. *Adv Exp Med Biol* 2012;769:78–114.
- Postuma RB, Berg D, Stern M, et al. MDS clinical diagnostic criteria for Parkinson’s disease. *Mov Disord* 2015;30(12):1591–1601.
- Hall DA, Birch RC, Anheim M, et al. Emerging topics in FXTAS. *J Neurodev Disord* 2014;6(1):31.
- Tassone F, Pan R, Amiri K, Taylor AK, Hagerman PJ. A rapid polymerase chain reaction-based screening method for identification of all expanded alleles of the fragile X (*FMR1*) gene in newborn and high-risk populations. *J Mol Diagn* 2008;10(1):43–49.
- Filipovic-Sadic S, Sah S, Chen L, et al. A novel FMR1 PCR method for the routine detection of low abundance expanded alleles and full mutations in fragile X syndrome. *Clin Chem* 2010;56(3):399–408.
- Markesbery WR, Jicha GA, Liu H, Schmitt FA. Lewy body pathology in normal elderly subjects. *J Neuropathol Exp Neurol* 2009;68(7):816–822.
- Dickson DW, Fujishiro H, DelleDonne A, et al. Evidence that incidental Lewy body disease is pre-symptomatic Parkinson’s disease. *Acta Neuropathol* 2008;115(4):437–444.
- Berg D, Postuma RB, Bloem B, et al. Time to redefine PD? Introductory statement of the MDS Task Force on the definition of Parkinson’s disease. *Mov Disord* 2014;29(4):454–462.
- Bertoli-Avella AM, Giroud-Benitez JL, Akyol A, et al. Novel parkin mutations detected in patients with early-onset Parkinson’s disease. *Mov Disord* 2005;20(4):424–431.
- Dzamko N, Gysbers AM, Bandopadhyay R, et al. LRRK2 levels and phosphorylation in Parkinson’s disease brain and cases with restricted Lewy bodies. *Mov Disord* 2017;32(3):423–432.
- Postuma RB, Berg D, Adler CH, et al. The new definition and diagnostic criteria of Parkinson’s disease. *Lancet Neurol* 2016;15(6):546–568.
- Bonifati V. Genetics of Parkinson’s disease—state of the art, 2013. *Parkinsonism Relat Disord* 2014;20:S23–S28.
- Bonifati V. LRRK2 low-penetrance mutations (Gly2019Ser) and risk alleles (Gly2385Arg)—linking familial and sporadic Parkinson’s disease. *Neurochem Res* 2007;32(10):1700–1708.
- Hall DA, Berry-Kravis E, Zhang W, et al. FMR1 gray-zone alleles: association with Parkinson’s disease in women? *Mov Disord* 2011;26(10):1900–1906.
- Hall D, Tassone F, Klepitskaya O, Leehey M. Fragile X-associated tremor ataxia syndrome in FMR1 gray zone allele carriers. *Mov Disord* 2012;27(2):296–300.
- Trost N, Cook M, Hammersley E, et al. White matter changes in patients with Parkinson’s disease carrying small CGG expansion FMR1 alleles: a pilot study. *Neurodegener Dis* 2014;14(2):67–76.
- Hall DA, Hagerman RJ, Hagerman PJ, Jacquemont S, Leehey MA. Prevalence of *FMR1* repeat expansions in movement disorders. *Neuroepidemiology* 2006;26(3):151–155.
- Loesch DZ, Tassone F, Mellick GD, et al. Evidence for the role of FMR1 gray zone alleles as a risk factor for parkinsonism in females. *Mov Disord* 2018;33(7):1178–1181.
- Entezari A, Khaniani MS, Bahrami T, Derakhshan SM, Darvish H. Screening for intermediate CGG alleles of *FMR1* gene in male Iranian patients with parkinsonism. *Neurological Sci* 2017;38(1):123–128.
- Loesch DZ, Tassone F, Lo J, et al. New evidence for, and challenges in, linking small CGG repeat expansion FMR1 alleles with Parkinson’s disease. *Clin Genet* 2013;84(4):382–385.
- Toft M, Aasly J, Bisceglia G, et al. Parkinsonism, FXTAS, and FMR1 premutations. *Mov Disord* 2005;20(2):230–3.
- De Pablo-Fernandez E, Doherty KM, Holton JL, et al. Concomitant fragile X-associated tremor ataxia syndrome and Parkinson’s disease: a clinicopathological report of two cases. *J Neurol Neurosurg Psychiatry* 2015;86(8):934–936.
- Hall DA, Howard K, Hagerman R, Leehey MA. Parkinsonism in *FMR1* premutation carriers may be indistinguishable from Parkinson disease. *Parkinsonism Relat Disord* 2009;15(2):156–159.
- Cilia R, Kraff J, Canesi M, et al. Screening for the presence of FMR1 premutation alleles in women with parkinsonism. *JAMA Neurol* 2009;66(2):244–249.
- Healy DG, Bressman S, Dickson J, et al. Evidence for pre and postsynaptic nigrostriatal dysfunction in the fragile X tremor–ataxia syndrome. *Mov Disord* 2009;24(8):1245–1247.
- Hedrich K, Pramstaller PP, Stübke K, et al. Premutations in the FMR1 gene as a modifying factor in Parkin-associated Parkinson’s disease? *Mov Disord* 2005;20(8):1060–1062.
- Yachnis AT, Roth HL, Heilman KM. Fragile X Dementia Parkinsonism Syndrome (FXDPS). *Cogn Behav Neurol* 2010;23(1):39–43.
- Hall DA, Jennings D, Seibyl J, Tassone F, Marek K. *FMR1* gene expansion and scans without evidence of dopaminergic deficits in parkinsonism patients. *Parkinsonism Relat Disord* 2010;16(9):608–611.
- Galbraith K. CAT 7: neurogenetic parkinsonian conditions. <https://www.parkinsons.org.uk/professionals/cat-7-neurogenetic-parkinsonian-conditions>. Accessed February 9, 2020.