

UCSF

UC San Francisco Previously Published Works

Title

Volumetric analysis demonstrates that true and false lumen remodeling persists for 12 months after thoracic endovascular aortic repair.

Permalink

<https://escholarship.org/uc/item/1sn0w6g9>

Journal

Journal of Vascular Surgery Cases and Innovative Techniques, 2(3)

ISSN

2468-4287

Authors

Suh, Ga-Young

Hirotsu, Kelsey

Dake, Michael

et al.

Publication Date

2016-09-01

DOI

10.1016/j.jvscit.2016.05.001

Peer reviewed

Volumetric analysis demonstrates that true and false lumen remodeling persists for 12 months after thoracic endovascular aortic repair

Ga-Young Suh, PhD,^a Kelsey Hirotsu, BS,^b Ramin E. Beygui, MD,^c Michael D. Dake, MD,^c Dominik Fleischmann, MD,^d and Christopher P. Cheng, PhD,^a *Stanford, Calif*

A 62-year-old man underwent an elephant trunk procedure followed by thoracic endovascular aortic repair (TEVAR). Computed tomography angiography-based models were built to quantify volume of the whole aorta and true and false lumens preoperatively, before TEVAR, after TEVAR, and at follow-up at 3, 6, and 12 months. With TEVAR, descending aortic true lumen volume increased by 54%, then increased additionally by 60% during 12 months. The descending aortic false lumen volume regressed continuously for 12 months following TEVAR, with the most rapid rate from 6 to 12 months at 16 cm³/month. TEVAR immediately increased true lumen volume and continued to remodel the true and false lumens throughout the following 12 months. (*J Vasc Surg Cases* 2016;2:101-4.)

Current management of thoracic aortic dissections includes conservative medical management and surgical or endovascular repair.¹ Elephant trunk repair is indicated in patients with extensive dissections including the aortic arch and descending aorta and can be followed by thoracic endovascular aortic repair (TEVAR) to minimize the potential risk of additional invasive open surgery.²

To understand the anatomic evolution of aortic interventions and long-term remodeling, precise measures of true and false lumen geometry at multiple time points are crucial. We present a case of a thoracic aortic dissection undergoing a staged elephant trunk procedure and TEVAR. Thoracic aortic volume was quantified throughout the staged repair and the following 12 months. Written consent was acquired from the subject.

CASE REPORT

A 62-year-old man with a history of an acute type A dissection and ascending aortic repair in 2010 presented with a chronic aortic arch and descending aortic dissection in January 2013. The dissection extended from the left subclavian ostium to bilateral common iliac arteries with a 7.4-cm aneurysmal dilation involving the

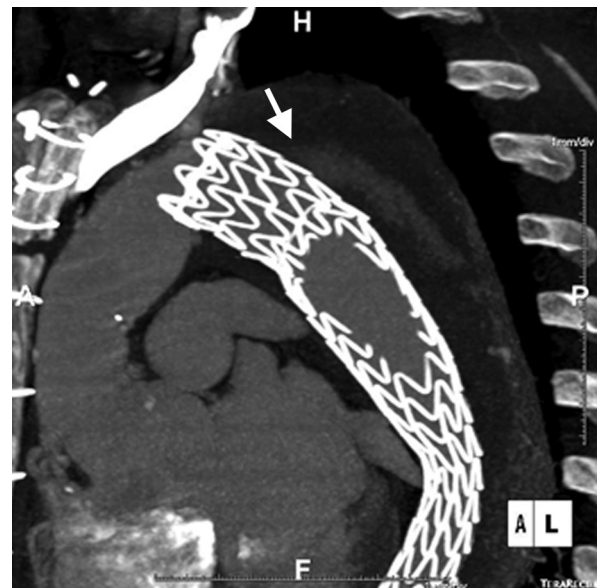


Fig 1. Sagittal computed tomography image showing the endoleak within the false lumen of the descending aorta (*arrow*). The image was acquired before the endoleak repair.

From the Department of Surgery,^a School of Medicine,^b Department of Cardiothoracic Surgery,^c and Department of Radiology,^d Stanford University.

G.S. and K.H. contributed equally to this article and share first authorship. Author conflict of interest: G.-Y.S. has received a research gift from W. L. Gore & Associates. M.D.D. is a consultant for Cook Medical and W. L. Gore & Associates. C.P.C. has received a research gift from W. L. Gore & Associates.

Correspondence: Ga-Young Suh, PhD, 300 Pasteur Dr, Ste H3600, Stanford, CA 94305-5642 (e-mail: gysuh@stanford.edu).

The editors and reviewers of this article have no relevant financial relationships to disclose per the Journal policy that requires reviewers to decline review of any manuscript for which they may have a conflict of interest.

2468-4287

© 2016 The Author(s). Published by Elsevier Inc. on behalf of Society for Vascular Surgery. This is an open access article under the CC BY-NC-ND license (<http://creativecommons.org/licenses/by-nc-nd/4.0/>).

<http://dx.doi.org/10.1016/j.jvscit.2016.05.001>

aortic arch and the proximal descending aorta. Perfusion to intra-abdominal organs was within normal ranges: the celiac trunk and superior mesenteric artery arose from both the true and false lumens; the right renal, accessory left renal, and inferior mesenteric arteries arose from the true lumen; and the left renal artery arose predominantly from the false lumen. Because his type A dissection in 2010 was repaired in another country, no outside hospital records were available for review.

We planned a staged repair (elephant trunk procedure plus TEVAR) to treat the extensive dissection in the aortic arch and descending aorta. This was intended to allow the patient's recovery, to reassess the thoracic aortic anatomy, and to reduce the risk of spinal cord ischemia after TEVAR. An elephant trunk

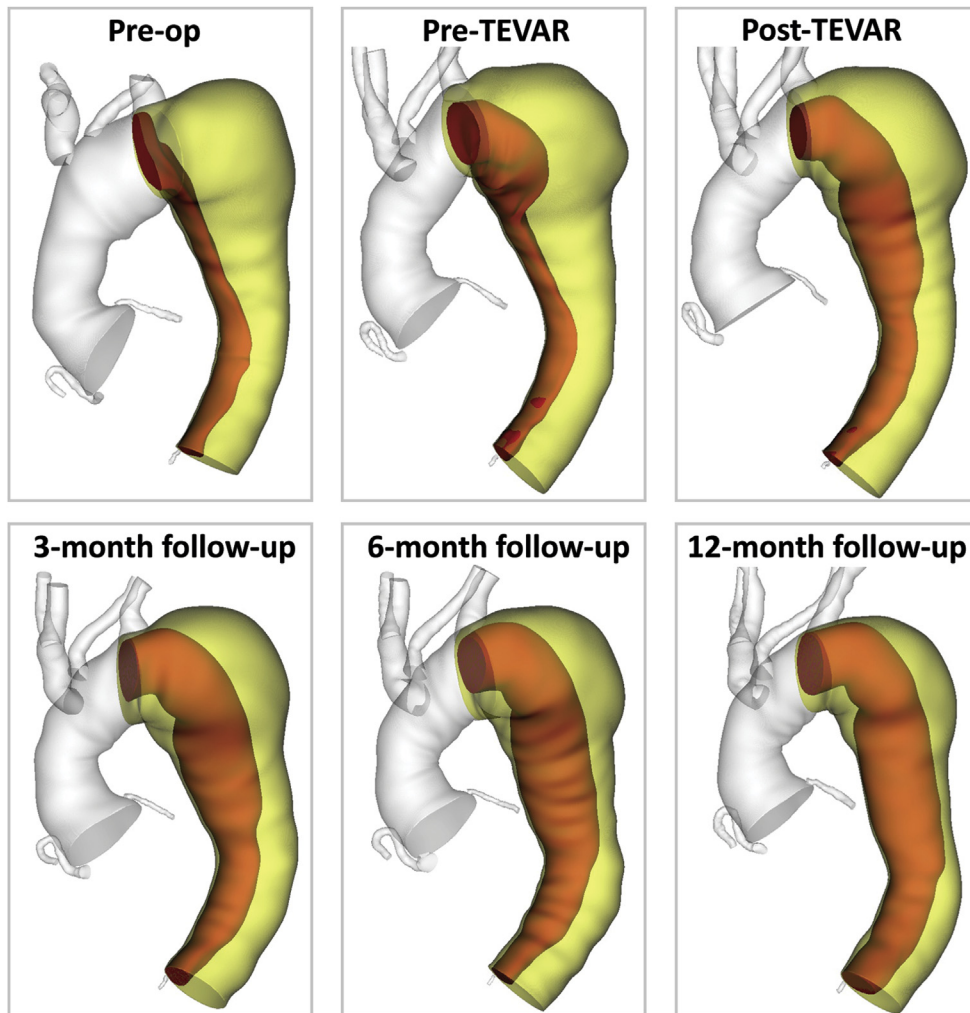


Fig 2. Preoperative, pre-thoracic endovascular aortic repair (TEVAR), post-TEVAR, 3-month follow-up, 6-month follow-up, and 12-month follow-up models. The whole aorta (*gray*), whole descending aorta (*yellow*), and true lumen (*red*) are visualized.

procedure was performed to replace the arch with a Dacron graft (Hemashield, 30 × 100 mm; Atrium Medical, Hudson, NH). The graft was inserted into the descending aorta with the elephant trunk terminating in the true lumen; anastomosis was established between the evaginated aorta circumferentially. The rest of the graft was retracted into the mediastinum and the superior aspect of the graft was excised for arch vessel placement. The arch vessels, on a small Carrel patch, were reimplemented onto the graft using the peninsula technique.³

A week later, TEVAR was performed to cover the proximal descending aortic dissection (Gore Conformable TAG, 34 × 200 mm; W. L. Gore & Associates, Newark, Del). A lumbar drain was placed before the procedure. A device length of 200 mm was selected on the basis of multiple intraoperative measurements with fluoroscopy. The endograft was deployed within the elephant trunk (30-mm diameter) distal to the left subclavian artery, extending to the level of the diaphragm superior to the celiac artery. The

false lumen of the left subclavian artery was occluded with an Amplatzer plug (12 × 8 mm; St. Jude Medical, St. Paul, Minn). A small endoleak superior to the proximal graft was found immediately postoperatively.

Five months later, the patient returned for repair of the type II endoleak whereby the left subclavian artery perfused the false lumen of the descending aorta (Fig 1). A covered stent was placed in the proximal left subclavian artery with proximal extension into the true aortic lumen, effectively excluding the false lumen. Subsequent aortograms demonstrated no persistent connection between the subclavian artery and aortic false lumen.

Chest computed tomography angiograms were acquired at six time points including preoperatively, before the elephant trunk procedure; pre-TEVAR, between the elephant trunk procedure and TEVAR; post-TEVAR, immediately after TEVAR; and at follow-ups at 3, 6, and 12 months after TEVAR. Each computed tomography angiogram was used to build three-dimensional

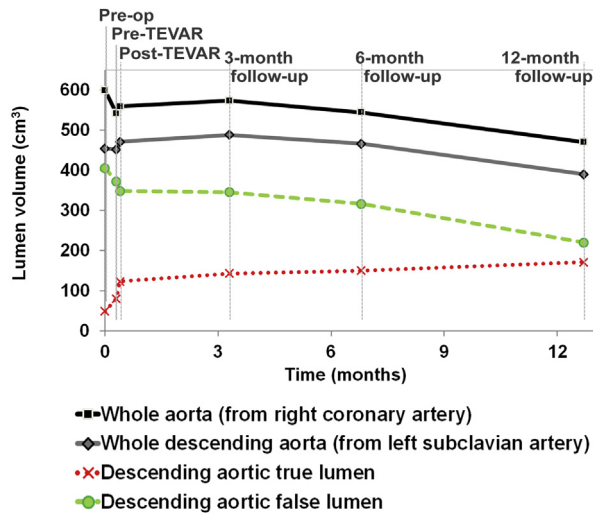


Fig 3. Progression of aortic volumes. Whole aorta including ascending aorta (black square), whole descending aorta (gray diamond), descending aortic true lumen (red cross), and descending aortic false lumen (whole descending aorta – true lumen; green circle) were plotted with respect to time (months) since preoperative image acquisition. TEVAR, Thoracic endovascular aortic repair.

lumen models of the thoracic aorta.^{4,5} Along the lumen paths, whole and true lumen cross sections were segmented and lofted to form volumetric representations. The lumen volume was quantified separately for the whole aorta (true and false lumen from the right coronary ostium to the 11th rib intercostal artery ostium), whole descending aorta (true and false lumen from the left subclavian ostium to the intercostal artery ostium), descending aortic true lumen (true lumen with contrast enhancement, including endograft after TEVAR), and descending aortic false lumen (Fig 2).

From preoperative to pre-TEVAR time points, whole aorta volume decreased by 10% (-58 cm^3); whole descending aorta volume decreased $<1\%$ (-3 cm^3). From pre-TEVAR to post-TEVAR time points, whole descending aorta volume increased by 4% ($+19 \text{ cm}^3$), with a 6% decrease (-24 cm^3) in false lumen volume and a 54% increase ($+43 \text{ cm}^3$) in true lumen volume. From post-TEVAR to the 12-month follow-up time, true lumen volume increased by 60% ($+48 \text{ cm}^3$) and false lumen volume decreased by 34% (-128 cm^3). During 12-month follow-up, the whole aorta, whole descending aorta, and false lumen regressed most rapidly from 6 to 12 months by 13, 13, and $16 \text{ cm}^3/\text{month}$, respectively. The true lumen expanded most rapidly from post-TEVAR to 3 months by $7 \text{ cm}^3/\text{month}$ (Fig 3).

DISCUSSION

The elephant trunk procedure (preoperative to pre-TEVAR time points) decreased whole aorta volume by excluding the proximal arch dissected volume. TEVAR (pre-TEVAR to post-TEVAR time points) induced a larger increase in true lumen volume than decrease in false lumen volume, leading to an increase in whole descending aortic

volume. This suggests that the endograft may acutely expand not only the true lumen but also the whole descending aorta before false lumen thrombosis and decompression.

During 12 months of follow-up, the presence of the endograft combined with progression of thrombosis and decompression continued to remodel the true and false lumens. The true lumen expansion rate was greatest in the first 3 months after TEVAR, whereas the false lumen regression rate increased with time. This fast true lumen expansion implies that the chronic outward force of the endograft may be greater immediately after TEVAR because of greater oversizing. The false lumen regression may have slowed because of endoleak during the first 5 months after TEVAR.⁶ Correspondingly, endoleak stabilization may have contributed to accelerated false lumen regression in the following months.

Many studies regarding post-TEVAR remodeling have observed diametric trends regarding true lumen expansion and false lumen regression.^{7,8} However, diametric measurements are less reliable and precise than volumetric measurements to track aortic remodeling, especially with complex aneurysm geometries.^{9,10} Among prior studies with volume analysis, Sigman et al and Stanley et al reported true and false lumen changes after TEVAR; however, the data were averaged for populations in which follow-up ranged from <1 month to >35 months after TEVAR.^{11,12} Andacheh et al reported the time course of remodeling during 12 months; however, preoperative anatomy was not reported to set a baseline before TEVAR.¹³

This case highlights how staged elephant trunk repair and TEVAR of complex thoracic aortic disease alter the aortic volumetric anatomy postoperatively and during the following 12 months. Despite endoleak during early follow-up, favorable remodeling was observed. This consisted of false lumen regression, reducing further risk of dilation and rupture, and true lumen volume expansion, promoting adequate perfusion of distal organs. This case uniquely includes separate volumetric analysis for the whole aorta and the true lumen and false lumen of the thoracic aorta. The temporal data may help establish long-term patterns in rates of false lumen regression and true lumen expansion, which may offer insight into postoperative management of similar patients. Considering the continued evolution of post-TEVAR changes, longer term follow-up is necessary to understand the full course of aortic remodeling.

REFERENCES

1. Nienaber CA, Zannetti S, Barbieri B, Kische S, Schreck W, Rehders TC. Investigation of STent grafts in patients with type B aortic Dissection: design of the INSTEAD trial—a prospective, multicenter European randomized trial. *Am Heart J* 2005;149:592-9.
2. Johnson PT, Corl FM, Black JH, Fishman EK. The elephant trunk procedure for aortic aneurysm repair: an illustrated guide to surgical technique with CT correlation. *AJR Am J Roentgenol* 2011;197:W1052-9.
3. Sundaram B, Quint LE, Patel HJ, Deeb GM. CT findings following thoracic aortic surgery. *RadioGraphics* 2007;27:1583-94.

4. Wilson N, Wang K, Dutton RW, Taylor CA. A software framework for creating patient specific geometric models from medical imaging data for simulation based medical planning of vascular surgery. *Lect Notes Comput Sci* 2001;2208:449-56.
5. Suh GY, Beygui R, Marangi R, Fleischmann D, Cheng CP. Aortic arch vessel geometries and deformations in patients with thoracic aortic aneurysms and dissections. *J Vasc Interv Radiol* 2014;25:1903-11.
6. Huang W, Yang F, Luo J, Xie M, He P, Luo S, et al. Outcomes and morphologic changes of immediate type Ia endoleak following endovascular repair of acute type B aortic dissection. *Ann Vasc Surg* 2015;29:174-82.
7. Lombardi JV, Cambria RP, Nienaber CA, Chinesa R, Mossop P, Haulon S, et al. Aortic remodeling after endovascular treatment of complicated type B aortic dissection with the use of a composite device design. *J Vasc Surg* 2014;59:1544-54.
8. Eriksson MO, Steuer J, Wanhainen A, Thelin S, Eriksson LG, Nyman R. Morphologic outcome after endovascular treatment of complicated type B aortic dissection. *J Vasc Interv Radiol* 2013;24:1826-33.
9. Wever JJ, Blankensteijn JD, Mali WP, Eikelboom BC. Maximal aneurysm diameter follow-up is inadequate after endovascular abdominal aortic aneurysm repair. *Eur J Vasc Endovasc Surg* 2000;20:177-82.
10. Nomura Y, Sugimoto K, Gotake Y, Yamanaka K, Sakamoto T, Muradi A, et al. Comparison of volumetric and diametric analysis in endovascular repair of descending thoracic aortic aneurysm. *Eur J Vasc Endovasc Surg* 2015;50:53-9.
11. Sigman MM, Palmer OP, Ham SW, Cunningham M, Weaver FA. Aortic morphologic findings after thoracic endovascular aortic repair for type B aortic dissection. *JAMA Surg* 2014;149:977-83.
12. Stanley GA, Murphy EH, Knowles M, Ilves M, Jessen ME, Dimairo JM, et al. Volumetric analysis of type B aortic dissections treated with thoracic endovascular aortic repair. *J Vasc Surg* 2011;54:985-92.
13. Andacheh ID, Donayre C, Othman F, Walot I, Kopchok G, White R. Patient outcomes and thoracic aortic volume and morphologic changes following thoracic endovascular aortic repair in patients with complicated chronic type B aortic dissection. *J Vasc Surg* 2012;56:644-50.

Submitted Jan 4, 2016; accepted May 2, 2016.