

UCSF

UC San Francisco Previously Published Works

Title

Deep arteriovenous malformations in the basal ganglia, thalamus, and insula: Multimodality management, patient selection, and results

Permalink

<https://escholarship.org/uc/item/1t18d2jh>

Journal

World Neurosurgery, 82(3)

ISSN

1878-8750

Authors

Potts, MB
Jahangiri, A
Jen, M
[et al.](#)

Publication Date

2014-09-01

DOI

10.1016/j.wneu.2014.03.033

Peer reviewed

Deep Arteriovenous Malformations in the Basal Ganglia, Thalamus, and Insula: Multimodality Management, Patient Selection, and Results

Matthew B. Potts¹, Arman Jahangiri¹, Maxwell Jen¹, Penny K. Sneed², Michael W. McDermott¹, Nalin Gupta^{1,3}, Steven W. Hetts⁴, William L. Young^{5,6}, Michael T. Lawton^{1,6}, for the UCSF Brain AVM Study Project

Key words

- Arteriovenous malformations
- Basal ganglia
- Radiosurgery
- Surgery
- Thalamus
- Therapeutic embolization

Abbreviations and Acronyms

AVM: Arteriovenous malformation

CI: Confidence interval

MRI: Magnetic resonance imaging

OR: Odds ratio

RS: Rankin scale

SRS: Stereotactic radiosurgery



From the Departments of ¹Neurological Surgery, ²Radiation Oncology, ³Pediatrics, ⁴Radiology, and ⁵Anesthesia and Perioperative Care, and the ⁶Center for Cerebrovascular Research, University of California, San Francisco, San Francisco, California, USA

To whom correspondence should be addressed:

Michael T. Lawton, M.D.

[E-mail: lawtonm@neurosurg.ucsf.edu]

Citation: *World Neurosurg.* (2014) 82, 3/4:386-394.

<http://dx.doi.org/10.1016/j.wneu.2014.03.033>

Journal homepage: www.WORLDNEUROSURGERY.org

Available online: www.sciencedirect.com

1878-8750/\$ - see front matter © 2014 Elsevier Inc.

All rights reserved.

INTRODUCTION

Arteriovenous malformations (AVMs) of the basal ganglia, thalamus, and insula pose significant treatment challenges. Such deep AVMs are known to have aggressive natural histories, with annual hemorrhage rates ranging from 10% to 34% (2, 20) and mortality rates up to 62.5% (17). The difficulties associated with microsurgical resection of deep AVMs have prompted some to consider them inoperable (12). However, radiosurgical treatment of deep AVMs is associated with significant complications and hemorrhage during the latency period (2, 6, 7, 14, 20) as well as lower obliteration rates compared with other locations (7, 17). More recent surgical experiences with deep AVMs have shown improving results, with superior obliteration rates and lower

■ **OBJECTIVE:** This study sought to describe a single institution's experience treating arteriovenous malformations (AVMs) of the basal ganglia, thalamus, and insula in a multimodal fashion.

■ **METHODS:** We conducted a retrospective review of all deep AVMs treated at our institution between 1997 and 2011 with attention to patient selection, treatment strategies, and radiographic and functional outcomes.

■ **RESULTS:** A total of 97 patients underwent initial treatment at our institution. 64% presented with hemorrhage with 29% located in the basal ganglia, 41% in the thalamus, and 30% in the insula. 80% were Spetzler-Martin grade III-IV. Initial treatment was microsurgical resection in 42%, stereotactic radiosurgery (SRS) in 45%, and observation in 12%. Radiographic cure was achieved in 54% after initial surgical or SRS treatment (71% and 23%, respectively) and in 63% after subsequent treatments, with good functional outcomes in 78% (median follow-up 2.2 years). Multivariate logistic regression analysis revealed treatment group and age as factors associated with radiographic cure, whereas Spetzler-Martin score and time to follow-up were significantly associated with improved/unchanged functional status at time of last follow-up. Posttreatment hemorrhage occurred in 11% (7% of surgical and 18% of SRS patients).

■ **CONCLUSIONS:** Modern treatment of deep AVMs includes a multidisciplinary approach utilizing microsurgery, SRS, embolization, and observation. Supplementary grading adds meaningfully to traditional Spetzler-Martin grading to guide patient selection. Surgical resection is more likely to result in obliteration compared with SRS, and is associated with satisfactory results in carefully selected patients.

mortality compared with radiosurgical series (4, 12).

At our institution, the treatment of brain AVMs is performed by a multidisciplinary team that includes neurosurgeons, neurologists, interventional neuroradiologists, and radiation oncologists. The Spetzler-Martin and Supplementary AVM grading systems are important considerations in deciding to treat a deep AVM with surgical resection, stereotactic radiosurgery (SRS), or observation. In general, known surgical risks associated with higher-grade AVMs (Spetzler-Martin and Supplementary grades IV and V) favor SRS or observation. Conversely, superior obliteration rates and lower posttreatment hemorrhage rates in surgically managed

AVMs make lower grade AVMs more appealing for surgical resection. It is not clear, however, whether such generalizations can be applied to deep-seated AVMs or whether the challenges associated with deep location and a more aggressive natural history warrant different treatment strategies. In an attempt to further elucidate these issues, we present here a series of 97 patients with deep AVMs treated in a multidisciplinary fashion.

METHODS

Data Collection

This study was approved by the Institutional Review Board of the University of

California, San Francisco, and conducted in compliance with Health Insurance Portability and Accountability Act regulations. The prospective registry of the University of California, San Francisco, Brain Arteriovenous Malformation Study Project was searched to identify patients with basal ganglia, thalamic, and insular AVMs who were treated at our institution between 1997 and 2011. Patients were excluded if they had received prior treatments at an outside institution or before the study period. Patients were categorized based on their initial treatment (surgical resection, SRS, or observation) during the defined study period. We conducted a retrospective review of this database as well as medical records, pretreatment and posttreatment radiographic studies, and clinical follow-up evaluations. Recorded pretreatment characteristics included age at initial treatment, clinical presentation, functional status, and AVM characteristics such as location, Spetzler-Martin grade and Supplemental grade. The Spetzler-Martin AVM grading scale (19) incorporates AVM size (<3 cm, 3 to 6 cm, or >6 cm), venous drainage pattern (deep vs. superficial), and eloquence of the AVM location (eloquent vs. non-eloquent). The Supplemental AVM grading scale (9) incorporates patient age (<20 years, 20 to 40 years, or >40 years), hemorrhage on presentation (ruptured versus unruptured), and AVM compactness (compact vs. diffuse).

Patient Selection

Patients with AVMs of the basal ganglia, thalamus, and insula are reviewed by our institution's multidisciplinary cerebrovascular team, which includes neurosurgeons, neurologists, interventional neuroradiologists, and radiation oncologists. In general, surgical preference is given to small AVMs with compact niduses, superficial venous drainage, and hemorrhagic presentation. Patients with poorer functional status at presentation are also often selected for surgical resection. Conversely, SRS is favored for larger AVMs, nonhemorrhagic presentations, and good functional status. Observation is typically reserved for deep AVMs deemed too large for safe surgical resection or SRS. Patient preference and medical comorbidities are also considered when deciding treatment recommendations.

Surgical Resection

Microsurgical resection was performed by the senior author (M.T.L.). As reported previously (16), the surgical approaches used to resect basal ganglia, thalamic, and insular AVMs fall into 3 broad categories: transylvian, transcallosal, and transcortical. Transylvian approaches require a wide splitting of the Sylvian fissure to expose the insula. From there, AVMs at the surface of the insula can be resected, whereas deeper AVMs of the insula and basal ganglia can be reached through a transinsular corridor. Transylvian variations include the anterior and posterior transinsular (15) and the supracarotid-infracarotid (21) approaches. Transcallosal approaches require interhemispheric dissection to expose the corpus callosum (8, 18). Variations include the anterior ipsilateral transcallosal for lesions of the superior thalamus, anterior contralateral transcallosal for lesions of the thalamus and caudate nucleus, transcallosal-transchoroidal for medial thalamic lesions, and posterior transcallosal for more posterior lesions of the superior thalamus. Finally, transcortical approaches take advantage of hematoma or encephalomalacia surrounding an AVM that provides a direct, non-anatomical corridor to the AVM. The choice of surgical approach was based on AVM location, arterial supply, and presence of surrounding hematoma or encephalomalacia.

Stereotactic Radiosurgery

SRS was performed for all cases using the model B, C, 4C, or Perfexion Leksell Gamma Knife (Electa Instruments, Atlanta, GA, USA). After administration of local anesthetic, a Leksell head frame was placed and patients underwent pre-SRS imaging, which included a stereotactic angiogram and gadolinium-enhanced magnetic resonance imaging (MRI). Results of these studies were superimposed to aid in target delineation, which was performed by the attending radiation oncologist and neurosurgeon. The treatment plan was created by a physicist using GammaPlan treatment planning software (Electa, Stockholm, Sweden) and approved by the attending radiation oncologist and neurosurgeon. Volume-staged SRS was considered if the treatment volume exceeded 8 to 10 cm³, treating approximately 8 to 10 cm³ per stage spaced 3 to 6 months apart. After treatment, patients were discharged home.

Outcome Evaluation

Two main outcome measures were examined: radiographic response to treatment and functional outcome. Radiographic response was determined based on post-treatment angiograms. For surgical resection, posttreatment angiograms typically were obtained during the early postoperative period (most often on postoperative day 1 to 3). Conversely, for SRS, posttreatment angiograms are typically obtained 3 to 5 years after treatment. Radiographic response was graded as complete obliteration or partial/no response. Functional neurologic outcome was assessed using the Rankin Scale (RS). Neurologic assessments were performed by a neurologist, neurosurgeon, or associated nurse clinician. The pretreatment RS was obtained from routine pretreatment clinic visits or admission physicals. Follow-up information was obtained during routine posttreatment clinic visits, subsequent hospital admissions, or telephone interviews. Good outcomes were defined as a final RS score of 1 to 2, whereas poor outcomes were defined as a final RS >2. Functional improvement was defined as a decrease in the RS score from the preoperative examination to the final follow-up examination. Deterioration was likewise defined as an increase in the RS score.

Statistical Analysis

Statistical analysis was performed using JMP 10.0 (SAS Inc., Cary, North Carolina, USA). Frequency distributions and summary statistics were calculated for all baseline characteristics and outcome measures. For all categorical variables (e.g., Spetzler-Martin grade), a cross-tabulation was generated and a Pearson χ^2 test was used to compare distributions among the 3 initial treatment groups (surgical resection, SRS, and observation). Continuous variables (e.g., age) were compared with a t test. Univariate analyses of factors associated with radiographic outcome (obliterated vs. not obliterated) and functional outcome (improved/unchanged vs. worsened RS) were also performed. Factors that were significantly associated with these dichotomous outcomes on univariate analysis were then incorporated into multivariate analyses using nominal logistic regression models. Statistical significance was defined as $P < 0.05$.

RESULTS

Patient and AVM Characteristics

Between 1997 and 2011, 108 patients with basal ganglia, thalamic, and insular AVMs were treated at our institution. Of those, 9 had undergone prior treatments (surgery or SRS) for their AVM, whereas 2 patients underwent endovascular embolization in preparation for surgical resection at other institutions. These patients were excluded, leaving 97 patients for inclusion in this analysis. Of note, 4 patients in this analysis had been followed up with observation at outside institutions before being referred to our institution for further management. Mean age of the included 97 patients was 32 years, with a relatively equal sex distribution (47% female, 53% male). The majority (64%) presented with hemorrhage, whereas seizure accounted for 11% and focal deficit and headache each accounted for 8% of presentations. Overall, 29% of AVMs were located in the basal ganglia, 41% in the thalamus, and 30% in the insula. Fifty-eight percent were located on the left, 39% on the right, and 3% were bilateral thalamic AVMs. The majority of AVMs were Spetzler-Martin grade III or IV (44% and 36%, respectively), whereas 12% were grade II and 7% were grade V. There were no Spetzler-Martin grade I AVMs in this series. Supplementary AVM grades were more evenly distributed, with 20% grade I, 32% grade II, 22% grade III, 24% grade IV, and only 2% grade V. Initial treatment for this population during the study period included surgical resection in 42%, SRS in 45%, and observation in 12%.

Table 1 describes the baseline characteristics of each initial treatment group. Notable differences between treatment groups included age ($P = 0.049$), presentation ($P = 0.035$), and AVM location ($P < 0.0001$). More patients managed with surgery presented with hemorrhage (75%) compared with the cohorts treated with SRS (64%) or observation (25%). In the surgical group, the majority of AVMs were located within the insula (59%), compared with only 7% in the SRS group and 17% of those managed with observation. In addition, pretreatment functional neurologic status based on the RS also differed among treatment groups ($P = 0.017$), with patients treated surgically having overall poorer RS grades than the SRS or observation groups.

Table 1. Patient and Arteriovenous Malformation Characteristics Based on Initial Treatment

	Surgical Resection	SRS	Observation	All	P Value
Total	41 (42%)	44 (45%)	12 (12%)	97	
Mean age (years \pm SD)	29.9 \pm 17	30.6 \pm 18.7	44.2 \pm 20.2	32 \pm 18.6	0.049
Sex					0.2
Female	17 (41%)	25 (57%)	4 (33%)	46 (47%)	
Male	24 (59%)	19 (43%)	8 (67%)	51 (53%)	
Presentation					0.035
Hemorrhage	31 (75%)	28 (64%)	3 (25%)	62 (64%)	
Focal deficit	1 (2%)	6 (14%)	1 (8%)	8 (8%)	
Seizure	4 (10%)	5 (11%)	2 (17%)	11 (11%)	
Headache	3 (7%)	3 (7%)	2 (17%)	8 (8%)	
Incidental	2 (5%)	1 (2%)	2 (17%)	5 (5%)	
Enlarging head circumference	0	1 (2%)	0	1 (1%)	
Unknown	0	0	2 (17%)	2 (2%)	
Location					< 0.0001
Basal ganglia	8 (20%)	15 (34%)	5 (42%)	28 (29%)	
Thalamus	9 (22%)	26 (59%)	5 (42%)	40 (41%)	
Insula	24 (59%)	3 (7%)	2 (17%)	29 (30%)	
Side					0.41
Left	21 (51%)	29 (66%)	6 (50%)	56 (58%)	
Right	19 (46%)	13 (30%)	6 (50%)	38 (39%)	
Bilateral	1 (2%)	2 (5%)	0	3 (3%)	
Pretreatment Rankin scale*					0.017
1	18 (44%)	29 (69%)	7 (63%)	54 (58%)	
2	3 (7%)	7 (17%)	3 (27%)	13 (14%)	
3	9 (22%)	2 (5%)	0	11 (12%)	
4	6 (15%)	3 (7%)	1 (9%)	10 (11%)	
5	5 (12%)	1 (2%)	0	6 (6%)	

AVM, arteriovenous malformation; SRS, stereotactic radiosurgery.

*Pretreatment Rankin scale values were not available for 3 patients (2 in the SRS group and 1 in the conservative management group). The denominator for percentage calculations was therefore adjusted accordingly.

Table 2 describes the AVM characteristics for each treatment group based on the Spetzler-Martin and Supplementary AVM grading scales. As expected, there were several significant differences among treatment groups based on the variables comprising these 2 scales. Size, venous drainage pattern, and the overall Spetzler-Martin grade were all significantly different ($P = 0.001$, $P = 0.0004$, and $P < 0.0001$,

respectively). The majority of AVMs in the surgical group were small (< 3 cm, 66%) compared with the SRS (48%) and observation (17%) groups. In addition, there were no large (> 6 cm) AVMs treated with initial surgery, whereas both the SRS and the observation groups contained large AVMs (7% and 33%, respectively). Eloquence was not a significant factor among treatment groups because the vast majority (98%) of

Table 2. Spetzler-Martin and Supplementary Arteriovenous Malformation Grading

	Surgical Resection (n = 41)	SRS (n = 44)	Observation (n = 12)	All (n = 97)	P Value
Spetzler-Martin grade					
AVM size (cm)					0.001
<3	27 (66%)	21 (48%)	2 (17%)	50 (52%)	
3 to 6	14 (34%)	20 (45%)	6 (50%)	40 (41%)	
>6	0	3 (7%)	4 (33%)	7 (7%)	
Venous drainage					
Superficial	13 (32%)	1 (2%)	1 (8%)	15 (15%)	0.0004
Deep	28 (68%)	43 (98%)	11 (92%)	82 (85%)	
Eloquence					
No	1 (2%)	1 (2%)	0	2 (2%)	0.76
Yes	40 (98%)	43 (97%)	12 (100%)	95 (98%)	
Spetzler-Martin grade					
I	0	0	0	0	< 0.0001
II	9 (22%)	2 (5%)	1 (8%)	12 (12%)	
III	23 (56%)	19 (43%)	1 (8%)	43 (44%)	
IV	9 (22%)	20 (45%)	6 (50%)	35 (36%)	
V	0	3 (7%)	4 (33%)	7 (7%)	
Supplementary grade					
Age at treatment (years)					0.14
<20	14 (34%)	14 (32%)	3 (25%)	31 (32%)	
20 to 40	13 (32%)	17 (39%)	1 (8%)	31 (32%)	
>40	14 (34%)	13 (30%)	8 (67%)	35 (36%)	
Hemorrhagic presentation					
Ruptured	31 (76%)	28 (64%)	3 (25%)	62 (64%)	0.006
Unruptured	10 (24%)	16 (36%)	9 (75%)	35 (36%)	
Compactness					
Compact	37 (90%)	36 (82%)	6 (55%)	79 (82%)	0.038
Diffuse	4 (10%)	8 (18%)	5 (45%)	17 (17%)	
Supplementary grade					
I	11 (27%)	8 (18%)	0	19 (20%)	0.059
II	14 (34%)	16 (36%)	1 (9%)	31 (32%)	
III	8 (20%)	10 (23%)	3 (27%)	21 (22%)	
IV	7 (17%)	9 (20%)	4 (63%)	23 (24%)	
V	1 (2%)	1 (2%)	0	2 (2%)	
Supplemented Spetzler-Martin grade					
Combined grade					< 0.0001
II	0	0	0	0	
III	0	0	0	0	

AVM, arteriovenous malformation; SRS, stereotactic radiosurgery.

Continues

deep AVMs in this study were considered eloquent. Within the Supplementary AVM grading scale, unruptured presentation and compactness were also significantly different among treatment groups ($P = 0.006$ and $P = 0.038$, respectively). AVMS treated surgically were less likely to be diffuse (only 10%) compared with those in the SRS and observation groups (18% and 45%, respectively). Interestingly, both age and overall Supplementary AVM grade were not significantly different among treatment groups. However, the supplemented Spetzler-Martin grade (Spetzler-Martin + Supplementary AVM grades) was different among groups ($P < 0.0001$), with the lowest overall grades in the surgical group and the highest overall grades in the observation group (Table 2).

AVM Management

As described in Tables 1 and 2, the initial AVM treatment was surgical resection in 42%, SRS in 45%, and observation in 12%. Pretreatment embolization was used more often before surgical resection than SRS (51% vs. 9%, respectively, $P < 0.0001$). In all cases of pretreatment embolization, AVM feeding arteries were embolized to reduce blood flow to the AVM. The majority of patients undergoing pretreatment embolization were treated with a single round, although 1 SRS and 3 surgical resection patients underwent 2 rounds of embolization, whereas an additional surgical resection patient underwent 3 rounds. Pretreatment embolization was performed between 1 and 11 days preoperatively for all but 1 patient in the surgical group. This additional patient suffered a stroke during pretreatment embolization, so his surgical resection was postponed 6 months to allow time for recovery. For SRS patients, pretreatment embolization was initiated between 1 and 81 days before SRS. Table 3 lists the surgical approaches used based on AVM location. Overall, transsylvian approaches were used in 68%, transcortical in 15%, and transcortical in 17%.

For the 44 patients who initially underwent SRS, mean target volume was 7.4 cm³ (median 4.6 cm³, range 0.12 to 28.1 cm³). Mean modified Pollock radio-surgery-based AVM grade (13) was 1.85 (median 1.62, range 0.7 to 4.52). Twelve patients underwent staged treatments (2 stages in 10 and 3 stages in 2 patients).

Table 2. Continued

	Surgical Resection (n = 41)	SRS (n = 44)	Observation (n = 12)	All (n = 97)	P Value
IV	13 (32%)	5 (11%)	0	18 (19%)	
V	9 (22%)	10 (23%)	0	19 (20%)	
VI	12 (29%)	17 (39%)	2 (18%)	31 (32%)	
VII	6 (15%)	4 (9%)	0	10 (10%)	
VIII	1 (2%)	6 (14%)	8 (73%)	15 (16%)	
IX	0	1 (2%)	1 (9%)	2 (2%)	
X	0	1 (2%)	0	1 (1%)	

AVM, arteriovenous malformation; SRS, stereotactic radiosurgery.

The median prescription dose administered was 17 Gy (range 15 to 20 Gy), with the vast majority treated to the 50% isodose line.

No patient in the observation group underwent any treatments directed at the AVM nidus. One patient had a feeding artery aneurysm that was embolized, and a second patient underwent embolization of an associated aneurysm.

Radiographic Outcomes

All patients in the surgery group underwent a postoperative angiogram. Per protocol, the majority of postoperative angiograms were obtained within 3 days of surgical resection. Longer intervals to postoperative angiography were required

in patients not medically stable for angiography. For purposes of analyzing radiographic response to SRS, we only included posttreatment imaging performed after a latency period of approximately 3 years, which was available in 50% of the SRS patients. In this group, the mean time after treatment imaging was 4 years (median 3.8 years, range 2.9 to 6 years), with angiography for 21 patients and an MRI for 1. Of note, there were no post-SRS imaging studies performed within 3 years of treatment that showed complete obliteration of an AVM. Tables 3 and 4 detail the radiographic results based on initial treatment group (surgery or SRS). Among patients in the surgical and SRS groups, radiographic obliteration was

achieved after initial treatment in 54%. Among these patients, 16 had repeat imaging after subsequent treatments (discussed later), bringing the overall obliteration rate to 63%. No AVM obliteration was observed on follow-up imaging in the observation group.

Univariate analysis identified several variables that were significantly associated with obliteration after the first treatment. Obliteration rates were higher in the surgical group (71%) compared with the SRS (23%) and observation (0%) groups ($P < 0.0002$). Insular lesions were more likely to be completely obliterated (79%) than lesions in the basal ganglia or thalamus (54% and 31%, respectively, $P = 0.0021$). AVMs with superficial venous drainage were more likely to be completely obliterated than those with deep drainage (92% vs. 44%, $P = 0.0008$). Finally, older patients were more likely to achieve complete obliterations compared with younger patients based on the Supplementary AVM age grade (48% age <20 years, 36% age 20 to 40 years, and 83% age >40 years, $P = 0.0066$). A nominal logistic regression model comprising the variables identified in univariate analysis found treatment group (surgery vs. SRS: odds ratio [OR] 4.6, 95% confidence interval [CI] 1.04 to 23.8, $P = 0.044$) and age (≤ 40 vs. > 40 years: OR 0.4, CI 0.17 to 0.86, $P = 0.018$) as independent variables associated with radiographic outcome after AVM treatment.

Subsequent Treatments

Of the 38 patients in the surgical and SRS groups with radiographic documentation of residual AVM after their initial treatment, 24 underwent subsequent treatment at our institution (Figure 1). Four of these patients underwent a third round of treatment, whereas 1 patient ultimately underwent 4 separate treatments. Subsequent treatments were performed in 8 patients from the surgical group and 16 patients from the SRS group. SRS was used in all 8 surgical patients (mean target volume of 1.7 cm³, median prescription dose of 18.25 Gy, range 17 to 20 Gy, treated to 50% isodose line in all but 1 patient). Follow-up imaging obtained approximately 1 year after SRS treatment was available in 4 of these patients and showed residual AVM in all. There was no longer-term imaging available for these

Table 3. Summary of Microsurgical Approaches Used Based on Arteriovenous Malformation Location

Microsurgical Approach	Basal Ganglia	Thalamus	Insula	Total
Transylvian	5 (12%)	0	23 (56%)	28 (68%)
Transinsular—anterior	2 (5%)	0	9 (22%)	11 (27%)
Transinsular—posterior	2 (5%)	0	14 (34%)	16 (39%)
Supracarotid-infracarotid	1 (2%)	0	0	1 (2%)
Transcallosal				6 (15%)
Contralateral	2 (5%)	0	0	2 (5%)
Transchoroidal	0	3 (7%)	0	3 (7%)
Posterior	0	1 (2%)	0	1 (2%)
Transcortical	1 (2%)	5 (12%)	1 (2%)	7 (17%)
Transfrontal	1 (2%)	0	0	1 (2%)
Transtemporal	0	3 (7%)	1 (2%)	4 (10%)
Transparietal	0	2 (5%)	0	2 (5%)

Percentages expressed as total number of surgical patients (n = 41).

Table 4. Radiographic Outcomes*

	Surgical [†] Resection	SRS [‡]	All
Number of patients	41 (100%)	22 (50%)	63
After initial treatment*			
No residual AVM	29 (71%)	5 (23%)	34 (54%)
Residual AVM	12 (29%)	17 (77%)	29 (46%)
Mean time to imaging	3 days	4 years	—
After all treatments [§]			
No residual AVM	30 (73%)	10 (45%)	40 (63%)
Residual AVM	11 (27%)	12 (55%)	23 (37%)

AVM, arteriovenous malformation; SRS, stereotactic radiosurgery.
 *Includes 1 patient with post-SRS magnetic resonance imaging instead of angiogram.
 †Includes only post-SRS images obtained approximately 3 or more years after treatment (range 2.9 to 6 years after SRS). Of note, all imaging studies performed on SRS patients before 3 years posttreatment showed residual AVM.
 ‡Numbers in parentheses indicate the percentage of patients in each initial treatment group with radiographic follow-up.
 §Includes the last recorded imaging result for each patient, including those who underwent subsequent treatments.

patients. Salvage SRS was also used in 13 of the initial SRS treatment patients (mean target volume of 3.2 cm³, median prescription dose of 18 Gy, range 15 to 20 Gy, 10 treated to 50% isodose line, 1 patient staged). Follow-up imaging was available in 11 of these patients, with 3 achieving complete obliteration. Surgery was used in the remaining 3 patients initially treated with SRS as well as an additional 4 patients in whom salvage SRS treatment failed. Surgery was deemed safe in these patients based on the presence of new hemorrhage or significant reduction of the AVM volume after prior SRS treatments. Complete resection was achieved in 4 of these patients. One of the patients with a subtotal resection went on to receive another round of salvage radiosurgery, but still had residual AVM at time of last imaging. Posttreatment hemorrhage led to subsequent treatment in 3 patients, whereas the remaining patients were treated for residual AVM found on routine post-treatment imaging.

Functional Outcomes and Posttreatment Hemorrhage

Median follow-up for the total population was 2.2 years (mean 3.2 years, ranging from immediately posttreatment to 14 years). Functional outcome status was available in 94 patients (97%), with 79% having good outcomes (RS 1-2) at time of last follow-up. Among the 92 patients who

had both pretreatment and posttreatment RS scores available, 82% had either improved or remained unchanged at time of last follow-up compared with their pretreatment functional status. **Figure 2** compares the pretreatment and posttreatment (time of last follow-up) RS distributions for the overall population as well as by initial treatment group. Of note, length of follow-up significantly differed among treatment groups ($P < 0.0001$) with a median of 0.6 years in the surgical resection group (mean 1.3, range immediately postoperatively to 10 years), 4.1 years in the SRS group (mean 4.7, range immediately posttreatment to 14 years), and 3.2 years in the observation group (mean 4.3, range immediately after diagnostic angiogram to 13 years). Univariate analysis identified several factors associated with improved/unchanged functional status (vs. worsened functional status) at time of last follow-up, including treatment group (surgery 95%, SRS 71%, observation 70%, $P = 0.006$), pretreatment RS (77% RS 1 to 2, 93% RS 3 to 5, $P = 0.047$), Spetzler-Martin score (100% grade II, 79% grade III, 85% grade IV, and 43% grade V, $P = 0.015$), and time to last follow-up (88% with follow-up ≤ 5 years and 58% with follow-up > 5 years, $P = 0.006$). Subsequent multivariate analysis of the total population incorporating significant factors identified by univariate analysis confirmed that a good functional outcome was associated with the Spetzler-Martin

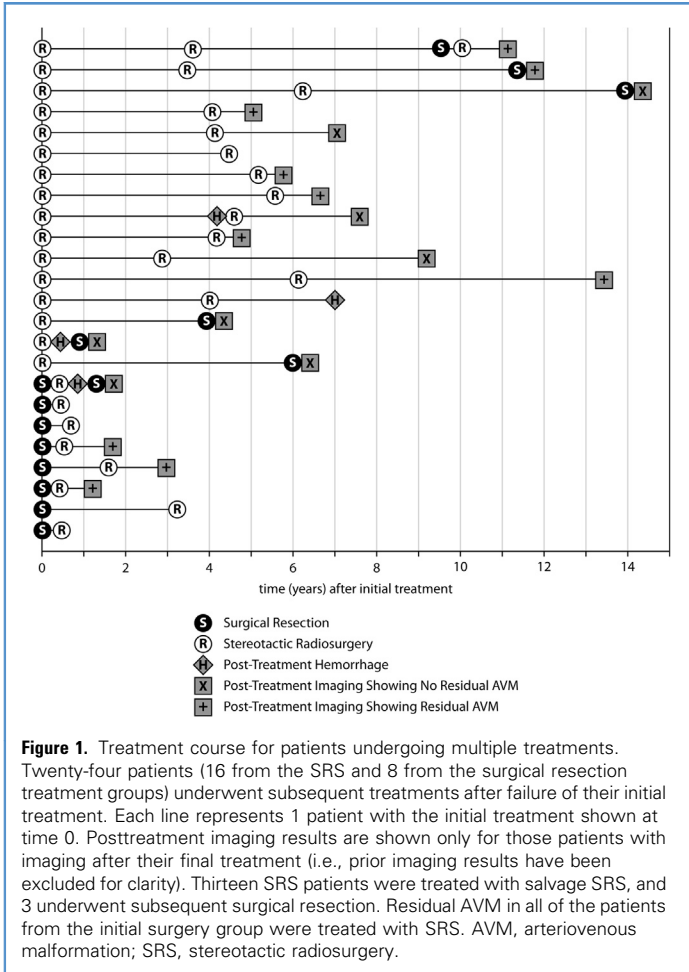
score (SMG 2 to 4 vs. 5: OR 14.7, CI 1.8 to 178.6, $P = 0.01$) and time to last follow-up (OR 0.03 for each increasing year, CI 0.002 to 0.4, $P = 0.008$).

Posttreatment hemorrhage was recorded in 11 patients (11%); 3 patients (7%) in the surgical group and 8 patients (18%) in the SRS group. In 2 patients treated with staged surgical resection, hemorrhage occurred after the first of 2 stages. In both instances, a gross total resection of the residual AVM was achieved during the second stage. An additional patient from the surgical resection group who had undergone a subtotal resection followed by SRS suffered a hemorrhage approximately 9 months after her initial resection (and 6 months after SRS). This patient then underwent a second surgical resection during which a gross total resection was achieved. The remaining 8 hemorrhages occurred in the initial SRS treatment group, with a median time to hemorrhage after initial SRS of 1.4 years (mean 2.5 years, range 3.2 months to 7 years). One of these patients had failed initial SRS treatment and undergone subsequent salvage SRS 3 years before hemorrhage. Two of these patients from the initial SRS group underwent subsequent surgical gross total resection. One patient from the initial SRS treatment group ultimately suffered 3 additional posttreatment hemorrhages. This patient had a Spetzler-Martin grade V bilateral thalamic AVM that was deemed inoperable. Given that her initial hemorrhages occurred during the post-SRS latency period, the decision was made to continue observation. This patient died after the fourth hemorrhage. Of note, there were no hemorrhages recorded in the observation group. Overall, the annual posttreatment hemorrhage rate after SRS was 3.9% (8 hemorrhages over 207.2 years).

There were 7 recorded deaths among this population, ranging from 1.5 to 7 years after the initial treatment. Three deaths were directly attributable to a posttreatment hemorrhage, and an additional death occurred within 6 months of a posttreatment hemorrhage. The cause of death is not known in the remaining 3 patients.

Discussion

This study demonstrates the application of a multidisciplinary approach to the treatment

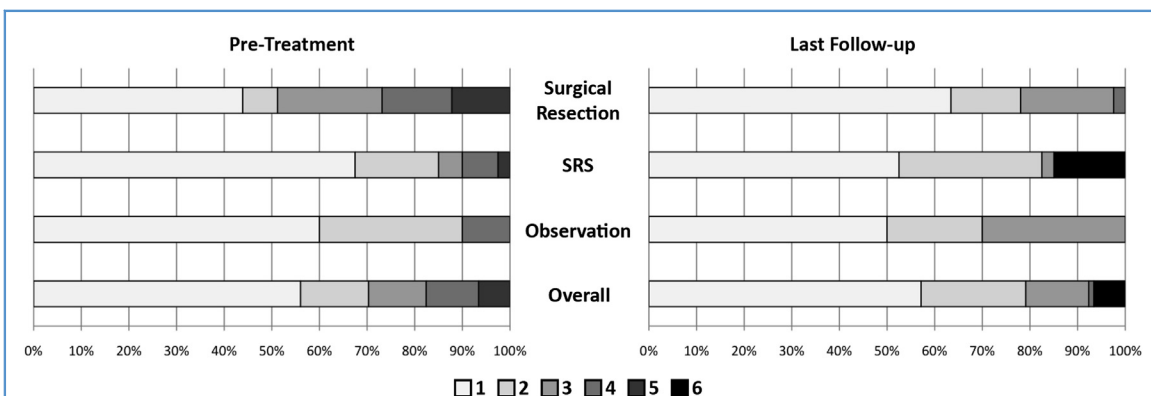


observation was reserved mostly for larger AVMs of the basal ganglia and thalamus without hemorrhagic presentation. SRS was most often used for intermediate grade AVMs of the basal ganglia and thalamus. However, there was significant overlap between treatment groups, making such generalizations inexact. The Spetzler-Martin grading system does little more than distinguish the size of deep AVMs because they are typically eloquent and drain deeply. The Supplementary grading system adds an important anatomical component, namely nidus compactness or diffuseness, which is critical in the central core of the cerebral hemisphere. Furthermore, the Supplementary grade sizes up the patient, concisely quantitating his natural history risk, neurological condition, and recoverability with scores for hemorrhagic presentation and age. In general, older patients with unruptured AVMs and intact neurological examinations are managed with observation or SRS, whereas younger patients with ruptured AVMs and presenting deficits are selected for microsurgical resection. Although the Spetzler-Martin and Supplementary AVM grading scales encompass universal AVM variables with known associations to surgical outcomes, there are other patient variables such as medical comorbidities and patient preferences that must also be considered when deciding on treatment strategies. Unfortunately we were unable to analyze such factors in this study.

of basal ganglia, thalamic, and insular AVMs. As expected, most Spetzler-Martin and Supplementary grading scale variables significantly differed among initial

treatment groups. Surgical resection was most often applied to smaller, compact AVMs in the insula with superficial drainage and hemorrhagic presentation. Conversely,

Overall, in our practice, we found surgical resection to have the greatest efficacy in terms of AVM obliteration. When choosing surgical resection, the potential



risks of surgery are weighed against the natural history of an AVM. Rupture is the most devastating event that can occur in an untreated or incompletely treated AVM, and deep-seated AVMs are reported to have rupture rates as high as 34% (2, 20). In our series, there were no instances of hemorrhage after complete resection or obliteration of an AVM. Successful surgical resection thus immediately eliminates the risk of hemorrhage. The 3 instances of hemorrhage within the surgical treatment group occurred in patients who had residual AVM after their first operation. In the SRS group, 8 patients suffered post-treatment hemorrhages, all with residual AVM. Prior series of deep AVMs treated with radiosurgery have reported annual posttreatment hemorrhage rates ranging from 1.3% to 9.5%, depending on size, location, prior history of hemorrhage, and time since radiosurgical treatment (1, 5, 10, 14, 17). It is important to note that the postradiosurgical hemorrhage rates in our series and prior series are lower than the natural history of deep-seated AVMs.

Our overall obliteration rate in the SRS treatment after initial treatment was just 23% and increased to 45% after subsequent treatments (including 7 patients who underwent subsequent surgical resection). This obliteration rate is below that of several prior series of radiosurgery for deep-seated AVMs. Three-year obliteration rates have been reported from 57% to 68% (5, 10), with overall obliteration rates as high as 81% (1, 5, 7, 10, 11, 14). There are several variables that can account for such differences. In general, we tend to favor surgery over radiosurgery, which leaves higher-grade AVMs in the SRS treatment group. Examination of our SRS treatment parameters also shows that our prescription doses tend to be lower than that of other reported series. In this series, the median marginal prescription dose was 17 Gy, whereas other large series have reported median marginal doses from 18 to 25 Gy (5, 7, 11, 14). Both size and marginal dose are known to be associated with AVM obliteration (3, 5, 7, 10).

Although we show that surgical management is associated with superior obliteration rates, we do not see a similar effect with functional outcomes. In fact, functional outcome is more associated with the Spetzler-Martin grading scale and time to last follow-up. This finding

suggests that our management strategy does in fact provide comparable functional outcomes for all patients and that surgical resection, radiosurgery, and observation all have their place in the treatment of deep-seated AVMs.

An important aspect of this study is our management of initial treatment failures. In general, incomplete surgical resection is managed with subsequent SRS. Partial or no response to initial SRS is most often treated with salvage SRS if the same risk factors precluding surgical resection are still present. If initial SRS resulted in sufficient reduction in AVM size, however, surgical resection can be considered. In addition, post-SRS hemorrhage often facilitates surgery by creating a route of access through the hematoma or separating the nidus from eloquent brain. Hemorrhage also diminishes the patient's neurological condition such that surgical risks compare more favorably to natural history risks. These factors make surgical resection a viable and successful option, and are reflected in a Supplementary score that is lowered by post-SRS hemorrhage.

This study has several limitations. Although the timing of radiographic outcomes was fairly uniform within treatment groups (immediate postoperative period for surgical resection and 3 to 5 years posttreatment for SRS and observation), time to follow-up functional status was significantly variable, with shorter follow-up time for patients in the initial surgical resection group compared with SRS or observation. This makes it difficult to compare functional outcomes among treatment groups or to adequately analyze factors associated with functional outcome. Indeed, time to last follow-up was associated with functional outcomes. However, it is understandable that surgical patients, who were more likely to obtain cure of their AVMs, would not undergo as extensive long-term follow-up as patients treated with SRS or those followed with observation. In addition, we only had three-year radiographic follow-up in 50% of the SRS patients (compared with post-surgical radiographic follow-up in 100% of surgical patients). As a tertiary care center, patients often receive follow-up imaging and care at other institutions and we were not able to obtain more records. Finally, although we report 7 deaths within this population, it is not clear whether all of

these deaths were necessarily related to complications of AVM treatment. However, 4 of these deaths occurred in close enough proximity to AVM treatment or posttreatment hemorrhage that it can safely be assumed they were related.

CONCLUSIONS

This large series of deep AVMs demonstrates the importance of a multidisciplinary treatment approach. Supplementary grading, with its consideration of age, bleeding status, and compactness, added meaningfully to traditional Spetzler-Martin grading and guided treatment decisions. Treatment modality was significantly associated with radiographic obliteration, with surgical resection more likely to result in obliteration compared with SRS and observation. Overall functional status was improved or unchanged in this deep AVM population. This experience demonstrates that within the context of a multidisciplinary team, highly selected patients with deep AVMs can be treated microsurgically with satisfactory results.

REFERENCES

1. Andrade-Souza YM, Zadeh G, Scora D, Tsao MN, Schwartz ML: Radiosurgery for basal ganglia, internal capsule, and thalamus arteriovenous malformation: clinical outcome. *Neurosurgery* 56: 56-63 [discussion 63-64], 2005.
2. Fleetwood IG, Marcellus ML, Levy RP, Marks MP, Steinberg GK: Deep arteriovenous malformations of the basal ganglia and thalamus: natural history. *J Neurosurg* 98:747-750, 2003.
3. Flickinger JC, Kondziolka D, Maitz AH, Lunsford LD: An analysis of the dose-response for arteriovenous malformation radiosurgery and other factors affecting obliteration. *Radiother Oncol* 63:347-354, 2002.
4. Gross BA, Duckworth EAM, Getch CC, Bendok BR, Batjer HH: Challenging traditional beliefs: microsurgery for arteriovenous malformations of the basal ganglia and thalamus. *Neurosurgery* 63:393-410 [discussion 410-411], 2008.
5. Kano Hideyuki, Kondziolka Douglas, Flickinger John C, Yang Huai-che, Flannery Thomas J, Niranjan Ajay, Novotny Josef Jr, Lunsford L Dade: Stereotactic radiosurgery for arteriovenous malformations, part 4: management of basal ganglia and thalamus arteriovenous malformations. *J Neurosurg* 116:33-43, 2012.
6. Kano H, Kondziolka D, Flickinger JC, Yang H-C, Flannery TJ, Awan NR, Niranjan A, Novotny J, Lunsford LD: Stereotactic radiosurgery for arteriovenous malformations, part 3: outcome predictors and risks after repeat radiosurgery. *J Neurosurg* 116:21-32, 2012.

7. Kiran NAS, Kale SS, Kasliwal MK, Vaishya S, Gupta A, Singh Sharma M, Shankar Sharma B, Kumar Mahapatra A: Gamma knife radiosurgery for arteriovenous malformations of basal ganglia, thalamus and brainstem—a retrospective study comparing the results with that for AVMs at other intracranial locations. *Acta Neurochir (Wien)* 151: 1575-1582, 2009.
8. Lawton MT, Golfinos JG, Spetzler RF: The contralateral transcallosal approach: experience with 32 patients. *Neurosurgery* 39:729-734 [discussion 734-735], 1996.
9. Lawton MT, Kim H, McCulloch CE, Mikhak B, Young WL: A supplementary grading scale for selecting patients with brain arteriovenous malformations for surgery. *Neurosurgery* 66:702-713 [discussion 713], 2010.
10. Nagy G, Major O, Rowe JG, Radatz MWR, Hodgson TJ, Coley SC, Kemeny AA: Stereotactic radiosurgery for arteriovenous malformations located in deep critical regions. *Neurosurgery* 2011.
11. Nicolato A, Foroni R, Crocco A, Zampieri PG, Alessandrini F, Bricolo A, Gerosa MA: Gamma knife radiosurgery in the management of arteriovenous malformations of the basal ganglia region of the brain. *Minim Invasive Neurosurg* 45:211-223, 2002.
12. Perret G, Nishioka H: Report on the cooperative study of intracranial aneurysms and subarachnoid hemorrhage. Section VI. Arteriovenous malformations. An analysis of 545 cases of cranio-cerebral arteriovenous malformations and fistulae reported to the cooperative study. *J Neurosurg* 25: 467-490, 1966.
13. Pollock BE, Flickinger JC: Modification of the radiosurgery-based arteriovenous malformation grading system. *Neurosurgery* 63:239-243, 2008.
14. Pollock BE, Gorman DA, Brown PD: Radiosurgery for arteriovenous malformations of the basal ganglia, thalamus, and brainstem. *J Neurosurg* 100:210-214, 2004.
15. Potts MB, Chang EF, Young WL, Lawton MT: UCSF Brain AVM Study Project: Transsylvian-transinsular approaches to the insula and basal ganglia: operative techniques and results with vascular lesions. *Neurosurgery* 70:824-834 [discussion 834], 2012.
16. Potts MB, Young WL, Lawton MT; for the UCSF Brain AVM Study Project: Deep arteriovenous malformations in the basal ganglia, thalamus, and insula: microsurgical management, techniques, and results. *Neurosurgery* 2013.
17. Sasaki T, Kurita H, Saito I, Kawamoto S, Nemoto S, Terahara A, Kirino T, Takakura K: Arteriovenous malformations in the basal ganglia and thalamus: management and results in 101 cases. *J Neurosurg* 88:285-292, 1998.
18. Shucart WA, Stein BM: Transcallosal approach to the anterior ventricular system. *Neurosurgery* 3: 339-343, 1978.
19. Spetzler RF, Martin NA: A proposed grading system for arteriovenous malformations. *J Neurosurg* 65:476-483, 1986.
20. Stapf C, Mohr JP, Pile-Spellman J, Solomon RA, Sacco RL, Connolly ES: Epidemiology and natural history of arteriovenous malformations. *Neurosurg Focus* 11:e1, 2001.
21. Waldron JS, Lawton MT: The supracarotid-intrafrontal approach: surgical technique and clinical application to cavernous malformations in the antero-inferior Basal Ganglia. *Neurosurgery* 64 (3 Suppl):86-95 [discussion 95], 2009.

Conflict of interest statement: This research is funded in part by the National Institutes of Health, R01 NS034949 (W.L.Y.) and P01 NS044155 (Center for Cerebrovascular Research). The authors have no personal or financial interests in the drugs, materials, or devices described in this article.

Received 10 July 2013; accepted 14 March 2014; published online 19 March 2014

Citation: World Neurosurg. (2014) 82, 3/4:386-394. <http://dx.doi.org/10.1016/j.wneu.2014.03.033>

Journal homepage: www.WORLDNEUROSURGERY.org

Available online: www.sciencedirect.com

1878-8750/\$ - see front matter © 2014 Elsevier Inc. All rights reserved.



ELSEVIER

360 Park Avenue South, New York, NY 10010

Subscription Customer Service

3251 Riverport Lane, Maryland Heights, MO 63043

Tel: (314) 447-8871 (International)

Tel: (800) 654-2452 (US)

Fax: (314) 447-8029 (US and International)

Email: journalscustomerservice-usa@elsevier.com

Advertising Orders and Inquiries

Inquiries regarding advertising in **WORLD NEUROSURGERY** should be directed to:

Bob Heiman

RH Media LLC

Office: +1-856-673-4000

Mobile: +1-856-520-9632

Fax: +1-856-673-4001

Email: bob.rhmedia@comcast.net

Ratecards: www.elsmediakits.com

The website for submitting an article to **WORLD NEUROSURGERY**, including the Guide for Authors link,

can be found online at **Ulysses Portal:**

<http://ees.elsevier.com/worldneurosurgery/>