

# UCLA

## UCLA Previously Published Works

### Title

Coccidioidomycosis Fungal Infection in the Hand Mimicking a Metacarpal Enchondroma

### Permalink

<https://escholarship.org/uc/item/1tq7v5rq>

### Journal

Journal of Hand Surgery (European Volume), 25(5)

### ISSN

1753-1934

### Authors

HUANG, JI  
SEEGER, LL  
JONES, NF

### Publication Date

2000-10-01

### DOI

10.1016/s0266-7681(00)80017-0

Peer reviewed

# COCCIDIOIDOMYCOSIS FUNGAL INFECTION IN THE HAND MIMICKING A METACARPAL ENCHONDROMA

J. I. HUANG, L. L. SEEGER and N. F. JONES

From the Department of Radiological Sciences and the Department of Orthopaedic Surgery, UCLA School of Medicine, Los Angeles, California, USA

**Coccidioidomycosis, an infection caused by the fungus *Coccidioides immitis*, rarely affects the hand, but we report an unusual case which mimicked the radiological appearance of an enchondroma in the metacarpal. Curettage and bone grafting in combination with long-term antifungal therapy are necessary for successful treatment of coccidioidomycosis of the hand.**

*Journal of Hand Surgery (British and European Volume, 2000) 25B: 5: 475-477*

## INTRODUCTION

An enchondroma is the most common bony tumour in the hand and usually occurs in the proximal or middle phalanges or metacarpals (Shimizu, 1997). Enchondromas have a fairly characteristic radiographic appearance.

Coccidioidomycosis is extremely rare in the hand. The fungus *Coccidioides immitis* usually causes a pulmonary infection, but rarely extrapulmonary dissemination may occur with bone involvement in 20% of these patients (Dalinka et al, 1971). We report a patient with coccidioidomycosis, which mimicked the appearance of an enchondroma of the metacarpal.

## CASE REPORT

A 16-year old Hispanic youth from central California presented with a 1-month history of pain and swelling over the dorsal aspect of the left hand. He denied any previous history of trauma. He was not immunocompromised and had no significant past medical or surgical history. Specifically, he denied any symptoms of fever, chills, cough, shortness of breath or chest pain.

Examination revealed diffuse swelling over the dorsal aspect of the left middle finger metacarpal which was minimally tender. He had full flexion and extension of the middle finger. Radiographs of the hand (Fig 1) showed a 1.5cm lytic lesion in the neck of the metacarpal. It was fairly well defined, but lacked a sclerotic border. Thick, benign-appearing unilaminar periosteal new bone extended from the mid-shaft to the metacarpal neck. This was circumferential, with a cleavage plane between the periosteal bone and the cortex. The radiographs and history suggested a pathological fracture through an enchondroma. At follow-up 1 month later, radiographs showed excellent healing of the fracture.

Subsequently, curettage of the lesion and bone grafting using cancellous bone from the distal radius was carried out. Histological examination of the curetted material with haematoxylin and eosin stains showed non-caseating granulomatous inflammation with coccidioidal spherules containing endospores (Figs 2 and 3). Special silver stains showed doubly

refractive walls, consistent with the diagnosis of coccidioidomycosis (Fig 4).

The incisions healed uneventfully and the pain and swelling resolved. The patient was referred back to his primary physician for antifungal therapy of the coccidioidomycosis but was subsequently lost to follow-up.

## DISCUSSION

Coccidioidomycosis is a fungal infection caused by *Coccidioides immitis*, a dimorphic fungus endemic to the southwestern United States, Central America and parts of South America. Because of increasing immigration from and tourism to these regions, coccidioidal infection is of increasing concern to physicians. Infection with *C. immitis* typically causes self-limited pulmonary disease, with extrapulmonary manifestations occurring in less than 1% of infections (Bried and Galgiani, 1986). A higher risk of dissemination exists in Filipino and black populations (Feise, 1958). Although disseminated coccidioidomycosis is rare, it can be fatal if the causative agent is not recognized and treated. Most patients with disseminated disease have experienced pulmonary symptoms such as cough, dyspnoea and chest pain.

Complementation fixation tests can be used to confirm the diagnosis and monitor the progression of the disease.

*Coccidioides immitis* is believed to be parasitic in the red marrow which may be present at the ends of long bones into adult life (Dalinka et al. 1971). In general, coccidioidomycosis has a predilection for bony protuberances such as the tibial tubercle, malleoli, epicondyles and the ends of long bones (Carter, 1934; McGahan et al, 1981). Coccidioidal lesions in the joints most frequently affect the ankle and knee, followed by the phalanges, then tarsal and carpal bones. Coccidioidomycosis of the hand has only rarely been described. In a series of 24 patients with 44 skeletal lesions, two were in the proximal phalanx and two were in the metacarpals (Bried and Galgiani, 1986).

Unfortunately, there are no pathognomonic clinical or radiographic findings in osseous lesions associated with *Coccidioides immitis*. The lesions are often confused with those caused by tuberculosis, blastomycosis, cryptococcus, metastatic carcinoma and bacterial

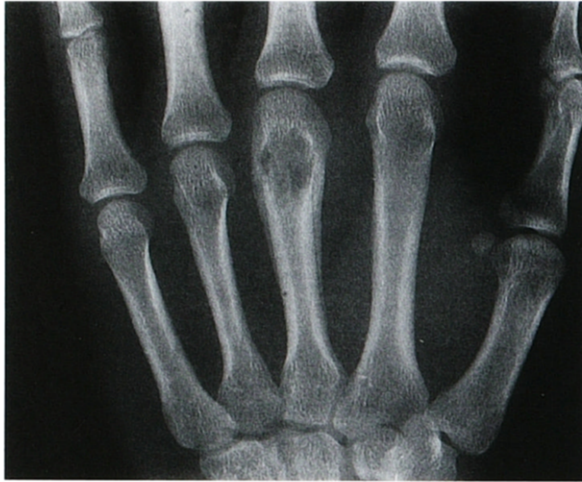

Fig 1 Posteroanterior radiograph of the hand showing a 1.5 cm long lytic lesion at the distal part of the middle finger metacarpal. Benign appearing laminar periosteal new bone surrounds the lesion.

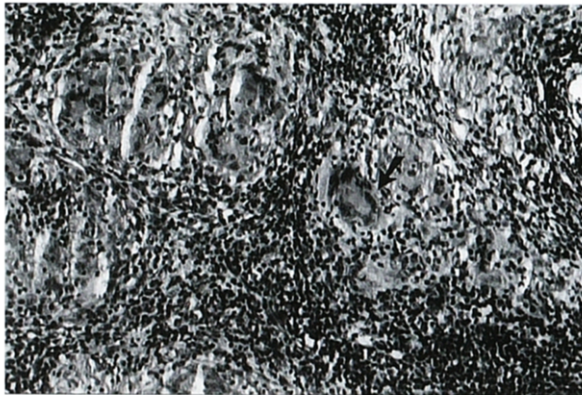

Fig 2 Multiple non-caseating granulomas indicative of an infectious process. A multinucleated giant cell (arrow) is seen in the centre (haematoxylin and eosin, original magnification  $\times 100$ ).

infections (Dalinka et al, 1971). The lesions usually show well defined borders or a well circumscribed, punched-out radiographic appearance, and involvement is often multifocal (Carter, 1934). Periosteal new bone formation accompanied by cortical expansion is sometimes seen (Mazet, 1955).

Enchondromas are typically solitary, oval or spherical-shaped intramedullary lesions involving the diaphysis or metaphysis, with the proximal phalanges being the most common location, followed by the middle phalanges and the metacarpals (Mirra, 1989). They are often asymptomatic or associated with painless swelling. Radiographic features are usually characteristic. Endosteal scalloping is common and cortical expansion may

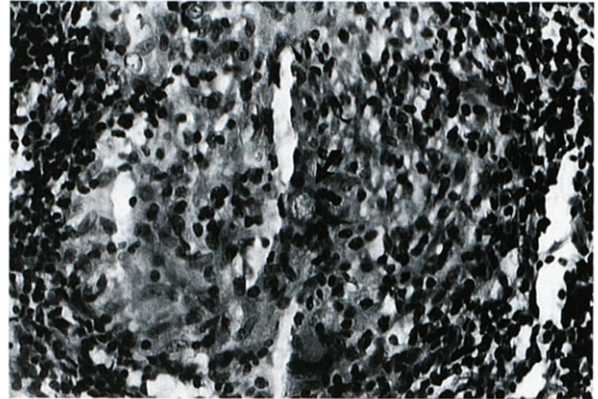


Fig 3 Coccidioidal spherule containing multiple endospores (arrow) (haematoxylin and eosin, original magnification  $\times 200$ ).

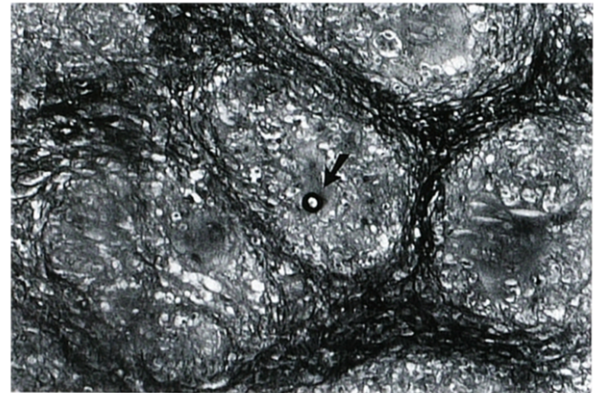


Fig 4 Multiple granulomas, with a spherule of *Coccidioides* showing characteristic doubly refractive walls (arrow) (GMS silver stain, original magnification  $\times 100$ ).

be present (Noble and Lamb, 1974). Although calcification in the matrix is generally diagnostic, not all lesions display this feature (Resnick and Niwayama, 1987). Enchondromas may also present as pathological fractures which are associated with periosteal new bone formation (Noble and Lamb, 1974).

In the patient presented here, the well defined but nonsclerotic margins could have been indicative of an infection or an enchondroma. Both conditions produce lesions that are commonly oval in shape and well margined. Endosteal erosion or scalloping can also be seen with either disorder. Matrix calcification was absent in this case, but this is not uncommon with enchondromas of the hand. Thick, unilaminar periosteal new bone formation is indicative of a benign, subacute process, and can be seen with either infection or a healing pathological fracture. The metaphyseal to metadiaphyseal location of the lesion was also nonspecific.

In the past, the only treatment for the bony lesions of coccidioidomycosis was amputation or wide resection of the affected bone (Winter et al, 1975). Most affected bones and joints can now be salvaged with early surgical curettage followed by long-term antifungal therapy. Despite its many side effects, amphotericin B remains the drug of choice for treating disseminated coccidioidomycosis (Bisla and Taber, 1976). A new class of antifungal agents, imidazoles, has also proven to be effective against coccidioidomycosis, and is associated with fewer adverse effects than amphotericin B.

This case report illustrates the frequent overlap between soft tissue and bone tumours and lesions caused by infections. Even though coccidioidomycosis has only been rarely reported to affect the bones of the hand, a thorough history of recent travel to, or residence in, endemic areas together with associated pulmonary symptoms, fever, malaise, erythema nodosum and eosinophilia, should make the hand surgeon suspicious of an alternative diagnosis of an infection when evaluating a supposedly straightforward benign bone tumour. Immunocompromised patients obviously have an increased susceptibility to systemic fungal disease. Early diagnosis with subsequent surgical curettage and long-term antifungal medication should lead to a successful outcome in coccidioidomycosis of the hand.

## References

- Bisla RS, Taber TH (1976). Coccidioidomycosis of bones and joints. *Clinical Orthopaedics and Related Research*, 121: 196–204.
- Bried JH, Galgani JH (1986). *Coccidioides immitis* infections in bones and joints. *Clinical Orthopaedics and Related Research*, 211: 235–243.
- Carter RA (1934). Infectious granulomas of bones and joints, with special reference to Coccidioidal granuloma. *Radiology*, 23: 1–16.
- Dalinka MK, Dinnenberg S, Greendyke WH, Hopkins R (1971). Roentgenographic features of osseous coccidioidomycosis and differential diagnosis. *Journal of Bone and Joint Surgery*, 53A: 1157–1164.
- Feise MJ. *Coccidioidomycosis*. Springfield, Charles C Thomas, 1958.
- Mazet R (1995). Skeletal lesions in coccidioidomycosis. *Archives of Surgery*, 70: 497–507.
- McGahan JP, Graves DS, Palmer PES, Stadalnik RC, Dublin AB (1981). Classic and contemporary imaging of coccidioidomycosis. *American Journal of Roentgenology*, 136: 393–404.
- Mirra JM. *Bone tumours*. Philadelphia, Lea and Febiger, 1989: 439–690.
- Noble J, Lamb DW (1974). Enchondromata of bones of the hand. A review of 40 cases. *The Hand*, 6: 275–284.
- Resnick D, Niwayama G. *Diagnosis of bone and joint disorders*. Philadelphia, WB Saunders, 1995: 3697–3707.
- Shimizu K, Kotoura Y, Nishijima N, Nakamura T (1997). Enchondroma of the distal phalanx of the hand. *Journal of Bone and Joint Surgery*, 79A: 898–900.
- Winter WG, Larson RK, Honegger MM, Jacobsen DT, Pappagianis D, Huntington RW (1975). Coccidioidal arthritis and its treatment. *Journal of Bone and Joint Surgery*, 57A: 1152–1157.

Received 7 September 1999

Accepted after revision 26 April 2000

Dr Neil F Jones, UCLA Hand Center – Dept of Orthopaedic Surgery, and Division of Plastic and Reconstructive Surgery, 200 Medical Plaza, Suite #140, Los Angeles, CA 90095-6907, USA

© 2000 The British Society for Surgery of the Hand

DOI: 10.1054/jhsb.2000.0424, available online at <http://www.idealibrary.com> on IDEAL<sup>®</sup>