

**UCLA**

**UCLA Radiological Sciences Proceedings**

**Title**

A Rare Aneurysmal Bone Cyst of the Rib in an Infant: A Case Report

**Permalink**

<https://escholarship.org/uc/item/1v28n9cp>

**Journal**

UCLA Radiological Sciences Proceedings, 2(2)

**Authors**

Chen, Iris E

Ghahremani Koureh, Shahnaz

Loo, Jerry T

**Publication Date**

2022-04-16

**DOI**

10.5070/RS42249039

**Copyright Information**

Copyright 2022 by the author(s). This work is made available under the terms of a Creative Commons Attribution License, available at <https://creativecommons.org/licenses/by/4.0/>

Peer reviewed

# A Rare Aneurysmal Bone Cyst of the Rib in an Infant: A Case Report

Chen IE, MD | Ghahremani Koureh S, MD | Loo JT, MD

**Author Affiliation:** Department of Radiological Sciences, David Geffen School of Medicine at UCLA

**Corresponding Author:** I.E.C. ([iechen@mednet.ucla.edu](mailto:iechen@mednet.ucla.edu))

*UCLA Radiol Sci Proc. 2022;2(2):21-24*

**Abstract:** An aneurysmal bone cyst (ABC) is a rare benign expansile lesion of the bone that consists of hemorrhagic cystic spaces separated by fibrous connective tissue containing osteoid and multinucleated giant cells. The lesion may be primary or secondary. We present a case of ABC in a 7-month-old girl who had a growing, antibiotic-refractory mass in the left chest wall. A computed tomography of the chest confirmed the anatomic location of the mass, but a percutaneous image-guided biopsy and video-assisted thoracoscopic surgery performed during work-up were nondiagnostic. The patient ultimately had a partial rib resection via left thoracotomy. On histologic examination, the mass was found to be an ABC. To our knowledge, this is the second case reported on aneurysmal bone cyst of the rib in an infant. The presented case confirms that ABCs can affect any bone and suggests that the inclusion of an expansile osteolytic lesion of the ribs in differential diagnosis is necessary to facilitate timely treatment that warrants excellent results.

**Keywords:** *aneurysmal bone cyst, rib, pediatric radiology, expansile osteolytic lesion*

## Case Presentation

A 7-month-old girl with a chronic lung disease presented for a routine check-up. The patient's medical history included extreme prematurity, bronchopulmonary dysplasia requiring home oxygen therapy, retinopathy of prematurity, congenital hypothyroidism, and multiple hemangiomas. Findings of the patient's physical examination and the results of routine laboratory tests were within normal limits. A radiograph of the chest revealed an opacity resembling pneumonia near the left chest wall. The opacity was initially diagnosed as round pneumonia, and the patient was treated with a course of antibiotics. However, because the opacity did not resolve, computed tomography (CT) of the chest was performed two months later. Chest CT examination revealed a 2.4-cm rounded lesion with soft-tissue density overlying the

## Key Points

- An ABC is a rare benign primary tumor of the bone that consists of hemorrhagic cystic spaces separated by fibrous connective tissue
- On radiographs and CT, ABC presents as a well-defined, expansile, radiolucent lesion with a characteristic "soap bubble" or "honeycomb" appearance and thin sclerotic margins; it can be initially confined within the cortex, but can also elevate the periosteum and extend into adjacent soft tissue.
- Although ABC of the rib is a rare entity, it should be considered in a differential diagnosis of an expansile osteolytic lesion of the rib because early, appropriate management often generates an excellent result.

peripheral left upper lung zone. The lesion had a broad-based contact with pleura and expanded the adjacent posterolateral aspects of the left fourth rib. The result of a subsequent percutaneous image-guided biopsy was nondiagnostic. The examination of surgical pathology removed during the following video-assisted thoracic surgery was negative for malignant tumor but still inconclusive. Because of the concern for the recurrent growth of the lesion, the decision was made to proceed with the left-side thoracotomy, partial resection of the rib, and chest wall reconstruction. The results of postoperative evaluation of surgical pathology was consistent with an aneurysmal bone cyst.

**Figure 1.** Chest Radiograph, Frontal View, of Aneurysmal Bone Cyst of the Fourth Rib in a 7-month-old- Girl

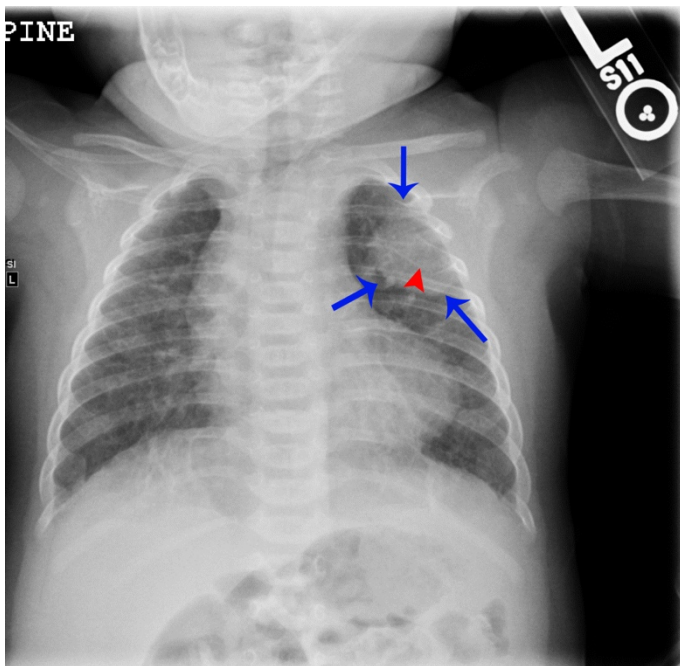


Image shows a soft tissue mass (blue arrows) overlying the left upper lung zone and expanding the posterior aspect of the left fourth rib (red arrowhead)

## Discussion

An aneurysmal bone cyst (ABC) is a rare benign primary tumor of the bone that consists of hemorrhagic cystic spaces separated by fibrous connective tissue.<sup>1,2</sup> The most common occurrence of this disease was reported in the first two

**Figure 2.** Computed Tomography, Axial View, of Aneurysmal Bone Cyst of the Fourth Rib in a 7-month-old Girl

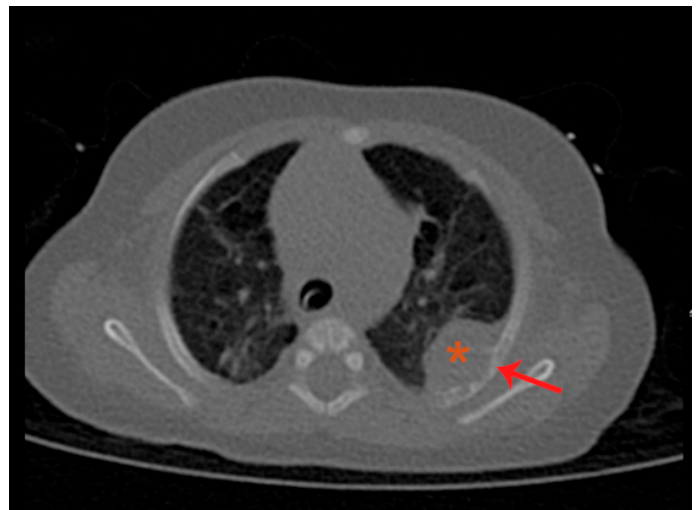


Image shows an irregularly shaped expansile soft-tissue mass (orange asterisk) and bony cortex erosion of the left fourth rib (red arrow)

**Figure 3.** Computed Tomography-guided Needle Biopsy of Aneurysmal Bone Cyst in a 7-month-old Girl

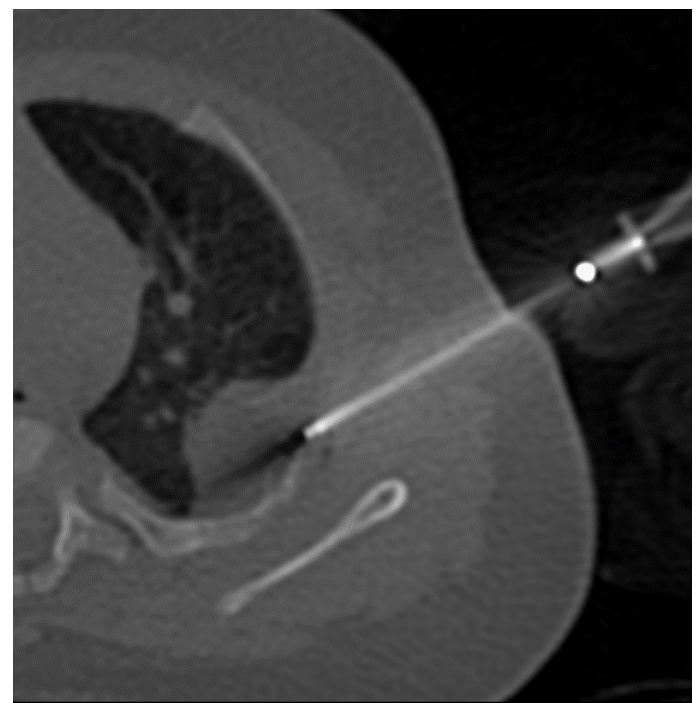


Image shows targeting of the soft tissue portion of the lesion of the left fourth rib

decades of life.<sup>3</sup> Only a few cases of ABC were described in infants.<sup>3-5</sup> To our knowledge, this is the second case reported on aneurysmal bone cyst

of the rib in an infant; Kalkat and Collins<sup>5</sup> reported the first case in 2003. There is no definitive opinion on the etiology of ABC.<sup>1,2</sup> Some hypotheses on the pathogenesis of ABCs explain their development as a consequence of trauma, a hereditary defect, a progression of pre-existing tumors or vascular malformations/disturbances, or de novo tumor formation.<sup>6-8</sup> Rapp et al<sup>6</sup> reviewed classification of ABCs based on the morphology of the lesion as well as on the intensity of its expansion and clinical presentation.

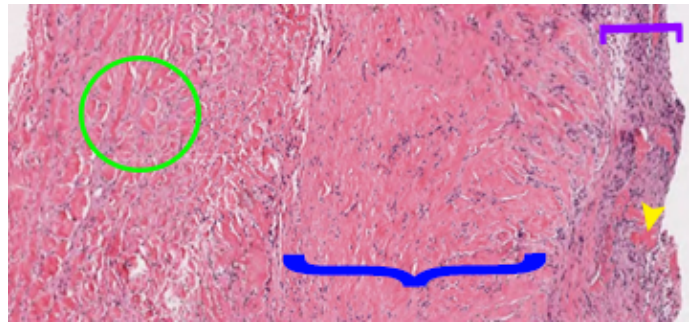
Patients with ABC of the ribs can present with chest pain, palpable chest wall mass, dyspnea, or a pathologic fracture.<sup>1,9,10</sup> However, as it occurred

**Figure 4.** Chest Radiograph, Frontal View, 1 day after En bloc Resection of Aneurysmal Bone Cyst and the Affected part of the Left Fourth Rib in a 7-month-old Girl

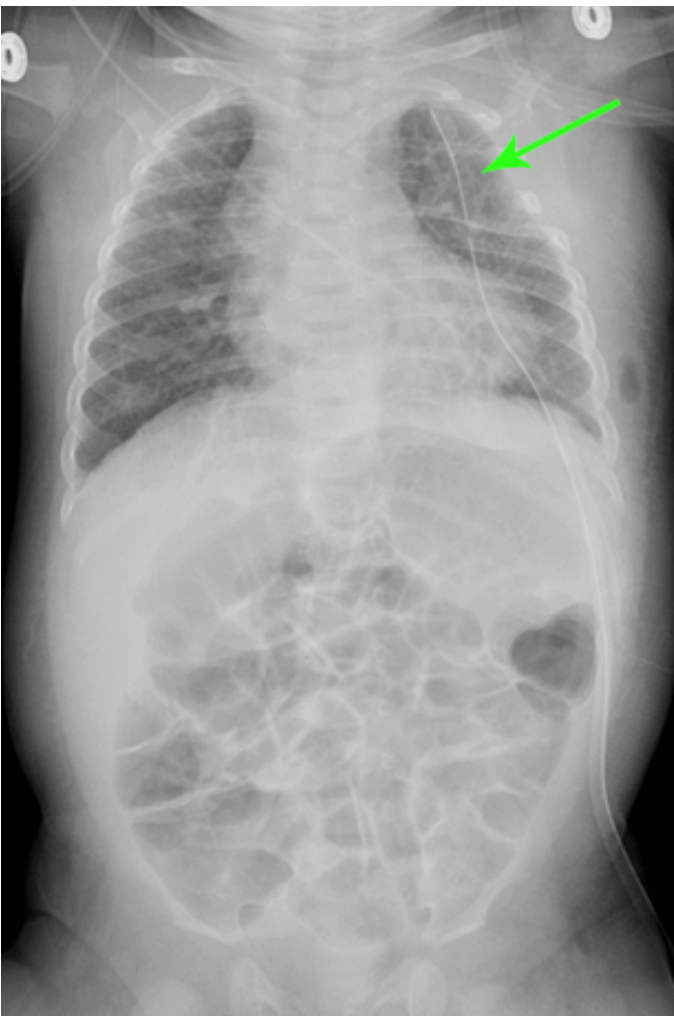

Image shows resolution of the lesion (green arrow)

**Figure 5.** Microscopic Examination, H&E stain, of the Biopsy Specimen of Aneurysmal Bone Cyst in a 7-month-old Girl



Photomicrograph, lower power view, shows dense fibrous tissue with hemosiderin and skeletal muscle (blue curly bracket). A thin layer of periosteal bone is seen (purple square bracket). Small blood-filled cystic spaces with fibrous septa are seen (green circle). Tiny islands of woven bone are seen interspersed in the periosteal layer (yellow arrowhead). Final histopathologic examination of en bloc resected specimen (not shown here) revealed similar findings, in addition to larger dilated cystic spaces, and scattered multinucleated giant cells with woven bone (osteoid) formation, consistent with aneurysmal bone cyst.

in our patient, ABC might be asymptomatic and diagnosed incidentally on chest radiographs.<sup>10</sup> While ABCs typically arise from and are confined to the metaphysis of long bones,<sup>6</sup> they can also develop in other bones, including the ribs.<sup>2,5,9,10</sup> When arising from the ribs, the lesion tends to affect their posterolateral aspects,<sup>9,10</sup> as it was documented in our case. On radiographs and CT, ABC presents as a well-defined, expansile, radiolucent lesion with a characteristic “soap bubble” or “honeycomb” appearance<sup>10</sup> and thin sclerotic margins; the lesion can be initially confined within the cortex, but can also elevate the periosteum and extend into adjacent soft tissue.<sup>6,7</sup> MRI has a higher specificity than conventional radiography for evaluating ABCs and shows suggestive of the lesions lobulations, septations, and fluid-fluid levels on the T1-weighted and the T2-weighted images.<sup>11</sup> Incisional biopsy and histopathologic examination are typically required to diagnose ABC or to validate the diagnosis.<sup>6,7</sup> Differential diagnosis of lytic and expansile bone lesions includes giant cell tumor, chondroblastoma, osteoblastoma, Ewing sarcoma, telangiectatic osteosarcoma, eosinophilic granuloma, chondrosarcoma, and plasmacytoma.<sup>2,6,7,11</sup>

Multiple approaches to the management of ABC, including curettage, en bloc resection, radionuclide ablation, arterial embolization, cryotherapy, and sclerotherapy, do not warrant cure, and decisions about the appropriateness of each of these approaches is made on a case-by-case basis.<sup>6-9</sup> A complete surgical resection with clear margins is associated with the lowest rate of recurrence.<sup>6,12</sup> Although ABC of the rib is a rare entity, it should be considered in a differential diagnosis of an expansile osteolytic lesion of the rib because early, appropriate management often generates an excellent result.

### Author Contributions

Conceptualization, J.T.L., S.G.K. and I.E.C.; Acquisition, analysis, interpretation of data, and writing – original draft preparation, I.E.C.; Review and editing, J.T.L.; Supervision, J.T.L. All authors agree to be accountable for all aspects of the work in ensuring that questions related to the accuracy or integrity of any part of the work are appropriately investigated and resolved. All authors had full access to all the data in the study and take responsibility for the integrity of the data and the accuracy of the data analysis.

### Disclosures

None to report.

### References

- Hughes EK, James SL, Butt S, Davies AM, Saifuddin A. Benign primary tumours of the ribs. *Clin Radiol*. 2006;61(4):314-322. DOI: [10.1016/j.crad.2005.12.005](https://doi.org/10.1016/j.crad.2005.12.005)
- Moraitis S, Moraitis D, Chounti M, Hountis P. Aneurysmal rib cyst. *Monaldi Arch Chest Dis*. 2017;87(3):860. Published 2017 Sep 22. DOI: [10.4081/monaldi.2017.860](https://doi.org/10.4081/monaldi.2017.860)
- Cottalorda J, Kohler R, Sales de Gauzy J, et al. Epidemiology of aneurysmal bone cyst in children: a multicenter study and literature review. *J Pediatr Orthop B*. 2004;13(6):389-394. DOI: [10.1097/01202412-200411000-00008](https://doi.org/10.1097/01202412-200411000-00008)
- Pullan CR, Alexander FW, Halse PC. Aneurysmal bone cyst: A report of three cases. *Arch Dis Child*. 1978;53:899-901. <http://dx.doi.org/10.1136/adc.53.11.899>
- Maninder S, Kalkat, Frank J, Collins. Aneurysmal bone cyst presenting as an intrathoracic mass in an infant. *Interact Cardiovasc Thorac Surg*. 2003;2(4):668-670. [https://doi.org/10.1016/S1569-9293\(03\)00199-3](https://doi.org/10.1016/S1569-9293(03)00199-3)
- Rapp TB, Ward JP, Alaia MJ. Aneurysmal bone cyst. *J Am Acad Orthop Surg*. 2012;20(4):233-241. DOI: [10.5435/JAAOS-20-04-233](https://doi.org/10.5435/JAAOS-20-04-233)
- Mascard E, Gomez-Brouchet A, Lambot K. Bone cysts: unicameral and aneurysmal bone cyst. *Orthop Traumatol Surg Res*. 2015;101(1 Suppl):S119-S127. DOI: [10.1016/j.otsr.2014.06.031](https://doi.org/10.1016/j.otsr.2014.06.031)
- Cottalorda, J., Bouelle, S. Modern concepts of primary aneurysmal bone cyst. *Arch Orthop Trauma Surg* 127, 105-114 (2007). <https://doi.org/10.1007/s00402-006-0223-5>
- Medina M, Paul S. Aneurysmal Bone Cyst Arising from the First Rib: A Rare Cause of Thoracic Outlet Syndrome. *Thorac Cardiovasc Surg Rep*. 2016;5(1):74-76. DOI: [10.1055/s-0035-1569994](https://doi.org/10.1055/s-0035-1569994)
- Sabanathan S, Chen K, Robertson CS, Salama FD. Aneurysmal bone cyst of the rib. *Thorax*. 1984;39(2):125-130. DOI: [10.1136/thx.39.2.125](https://doi.org/10.1136/thx.39.2.125)
- Mahnken AH, Nolte-Ernsting CC, Wildberger JE, et al. Aneurysmal bone cyst: value of MR imaging and conventional radiography. *Eur Radiol*. 2003;13(5):1118-1124. doi: [10.1007/s00330-002-1668-8](https://doi.org/10.1007/s00330-002-1668-8)
- Soyer T, Karnak I, Ciftci AO, Senocak ME, Tanyel FC, Büyükpamukçu N. The results of surgical treatment of chest wall tumors in childhood. *Pediatr Surg Int*. 2006;22(2):135-139. DOI: [10.1007/s00383-005-1537-z](https://doi.org/10.1007/s00383-005-1537-z)