

Diffuse dermal angiomatosis of the breast with adjacent fat necrosis: a case report and review of the literature

Fatma Frikha¹, Sonia Boudaya¹, Najla Abid², Saiida Garbaa¹, Tahya Sellami², Hamida Turki¹

Affiliations: ¹Department of Dermatology, Hedi Chaker Hospital, Sfax, Tunisia²Department of Anatomic Pathology, Habib Bourguiba hospital, Sfax, Tunisia

Corresponding Author: Fatma Frikha, Ain Road, Sfax 3089, Tunisia, Email: frikhafat@gmail.com

Abstract

Diffuse dermal angiomatosis (DDA) is a type of reactive skin angioproliferation. Clinically, this rare disorder presents as red-violet purpuric papules and/or plaques (some with a greater tendency towards necrosis and ulceration), which can be localized in any body area, but is most often seen in the upper and lower extremities. Localization in the breast commonly presents with severe intractable breast pain and characteristic reticular violaceous erythematous plaques with central ulcerations. Histological examination is fundamental for the diagnosis and is characterized by varied patterns of lobular or diffuse hyperplasia of endothelial cells at the extravascular level. The condition is associated with various underlying conditions, many of which result in local tissue ischemia. In this report, we present a patient with DDA with an underlying mass lesion of the breast, which proved to be an adjacent fat necrosis. Various treatments have proven beneficial, including revascularization, oral corticosteroids, smoking cessation, and isotretinoin. In this case, our patient benefited from secondary excision of the affected area.

Keywords: diffuse dermal angiomatosis, reactive cutaneous angioendotheliomatosis, breast

Introduction

Diffuse dermal angiomatosis (DDA) was first described as a rare variant of reactive angioendotheliomatosis (RAE). Since then, it has gained traction as a distinct separate variant of RAE associated with underlying vaso-occlusive

conditions, heavy smoking, surgery/trauma, anticardiolipin antibodies, subclavian artery stenosis, and underlying hypercoagulability [1-3]. It generally involves the extremities of patients with severe vascular disease and other comorbidities [4]. Involvement of the breast is rare. In this report, we present a case of DDA occurring on the breast with an underlying mass lesion that proved to be adjacent fat necrosis.

Case Synopsis

A 71-year-old woman was hospitalized for a 2-month history of painful bilateral breast masses and overlying skin changes. At the time of presentation, she was taking multiple medications including insulin, metformin, nifedipine, carbamazepine, omeprazole, and arginotri-b. She was not on coumadin or heparin. She had no history of renal disease, or of breast cancer or radiation to this area.

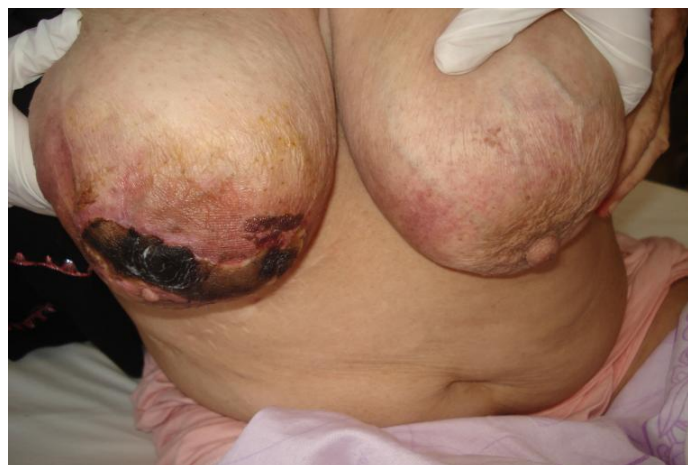

Figure 1. Large and pendulous breasts with livedoid patches.

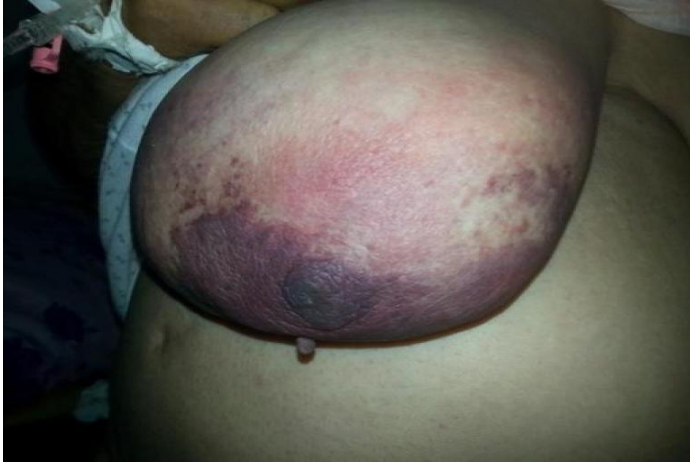

Figure 2. Erythema with violaceous and purpuric patch on the right breast

In addition, she had a history of diabetes, cardiovascular disease (hypertension), and rheumatoid polyarthritis. She had no history of vaso-occlusive disorder or of previous trauma at the site of the disease.

On physical examination, the patient had large, pendulous breasts (**Figure 1**) with 1) a 10×6cm poorly demarcated and erythematous-violaceous plaque with livedo, central necrosis (**Figure 2**), and secondary painful ulceration on the right breast (**Figure 3**); 2) a 10×6cm erythematous-purpuric plaque with livedo on the left breast (**Figure 4**).

These plaques were extending into the upper poles in the vicinity of the areolae, which was dedifferentiated on the right breast. Deep to these lesions, there was firm tender induration with a

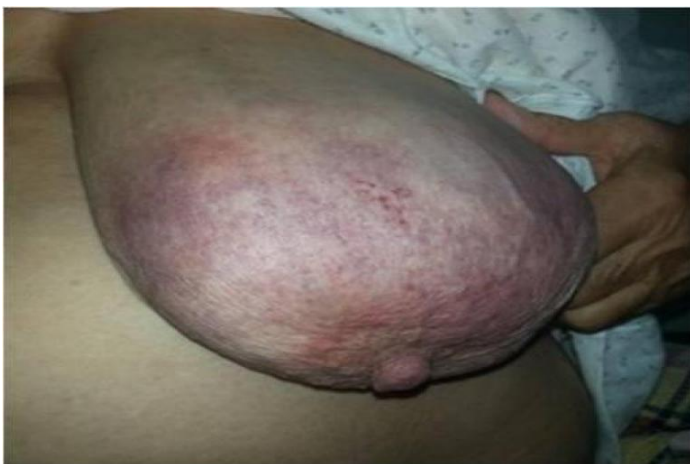

Figure 4. Reticulated erythema on the left breast.

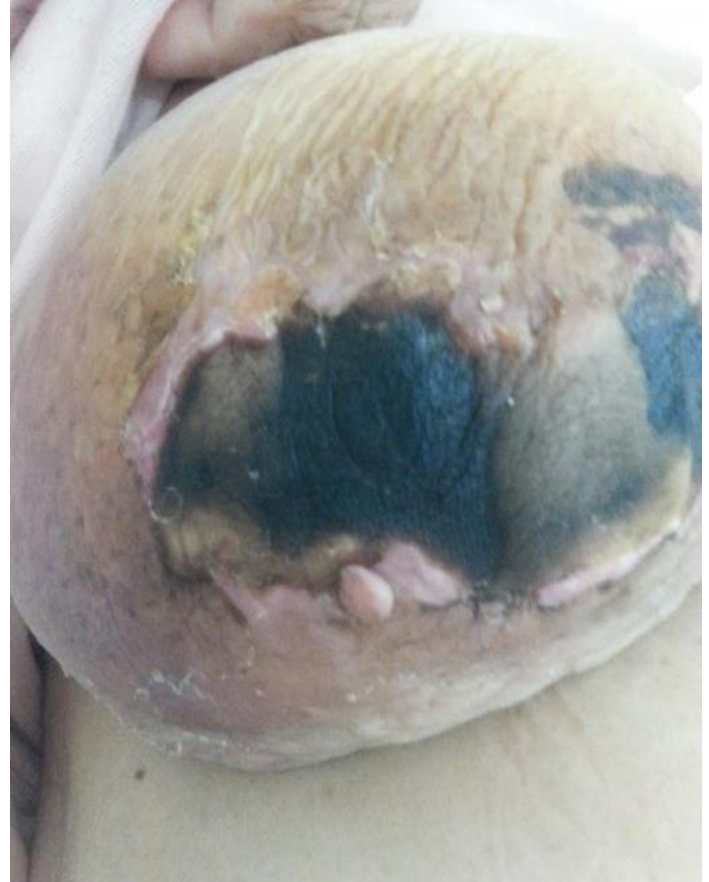

Figure 3. Large ulceration with necrotic patch on the right breast (later stage).

nodular consistency of both breasts. Examination of her axillae revealed no abnormalities.

Initial laboratory tests including a complete blood cell count, blood chemistry panel, and lipid panel showed nonspecific results. Antinuclear, antiphospholipid, and anticardiolipin antibody

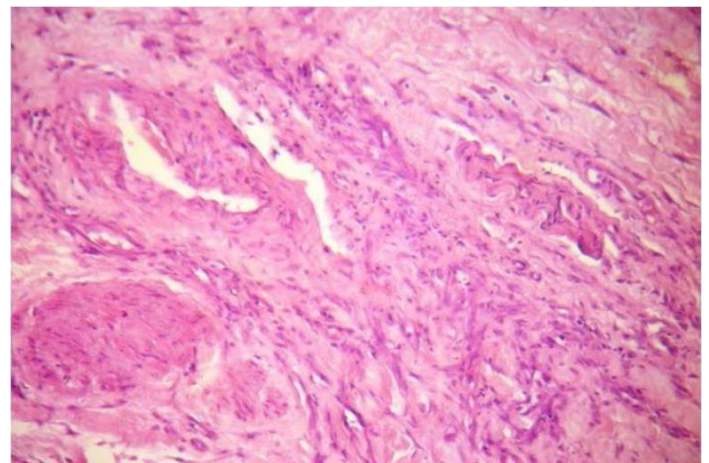


Figure 5. Diffuse regular proliferation of endothelial cells throughout the dermis. H&E, 100x.

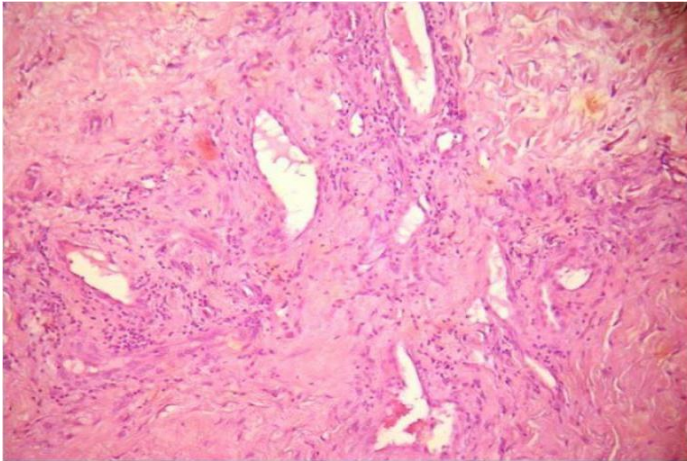


Figure 6. Proliferating endothelial cells and focal small vessel formation without atypia. H&E, 100x.

assays were negative. Factor V Leiden, prothrombin 20210A, protein C, protein S, and antithrombin III assays were also negative. Mammogram and ultrasound revealed no masses or disrupted architecture, but showed calcified vessels, subcutaneous fat infiltration, and hyper echogenic mammary fat. A few days after mammogram, she complained of increased pain and tension of both breasts. Skin biopsy of the right breast, taken near ulcerating lesions and tissue with the red reticular pattern, revealed diffuse proliferation of endothelial cells and small blood vessels occupying the full thickness of the dermis (**Figure 5**). Neither atypia nor mitotic figures were demonstrated (**Figure 6**). Focally, small loops of capillaries formed from the proliferating cells. No vascular calcification or thromboses were seen. No pronounced erythrocyte extravasation or inflammation were noted. The

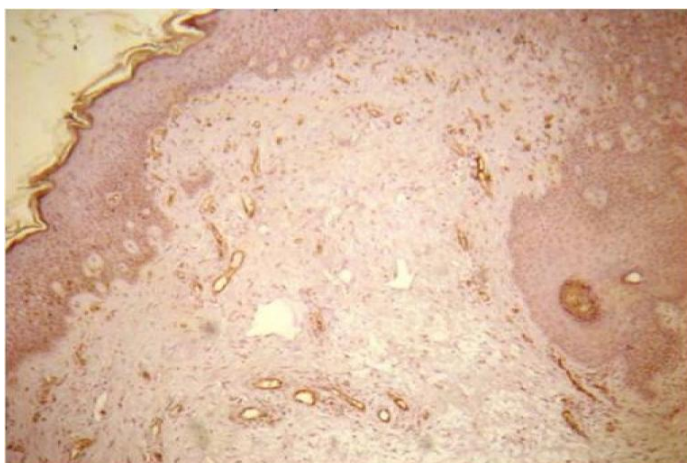


Figure 7. Positive CD31 staining, 100x.

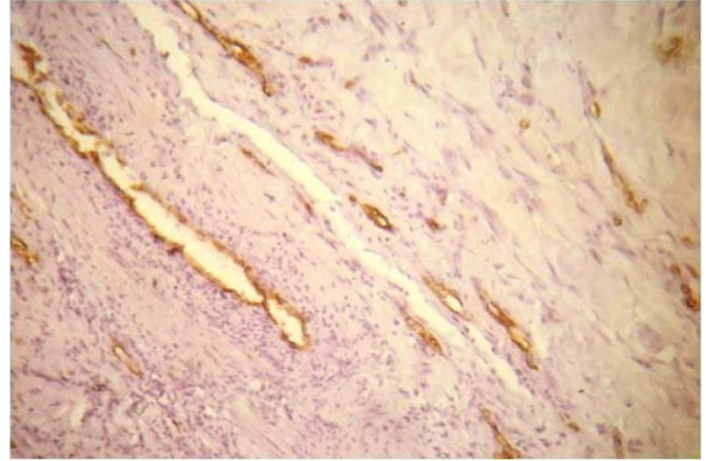


Figure 8. Positive CD34 staining, 100x.

lesions stained diffusely for CD31 (an endothelial-specific marker, further documenting the endothelial nature of the proliferating cells), (**Figure 7**), CD34 (**Figure 8**), and factor VIII. Staining was negative for human herpesvirus 8, keratin 7, CD117, and P53.

On the basis of the histopathologic findings and the patient's history of cardiovascular disease, DDA was diagnosed and isotretinoin therapy (0.5mg/kg/d) was initiated. With isotretinoin therapy, the cutaneous lesions were slightly improved, but nodularity, tenderness, and erythema of the breast have persisted. In addition, she developed a large ulcerated plaque of necrosis with abscess on the right breast.

Owing to worsening and her persistent symptoms, a multi-disciplinary committee recommended deeper surgical excision (right mastectomy and excisional biopsy of the left breast). Anatomopathology demonstrated similar findings to the initial skin biopsy. The mass lesion proved to be adjacent fat necrosis. A dramatic improvement was noted, with complete healing of all ulcers and no recurrence after a follow-up of 30 months.

Case Discussion

DDA, described initially by Krell et al. in 1994 [3-6], was previously considered to be a subtype of RAE [4-6]. However, it is more appropriately classified as a distinct variant of RAE [3, 4, 7]. RAE is a vascular

proliferation that often presents as infiltrated, red, or blue patches and plaques [3]. Other findings can include purpura and, at times, necrosis and ulceration [3, 8]. It is associated with a wide variety of underlying conditions, including coagulopathies and infectious processes [3, 9]. Notably, most cases resolve after the underlying process is corrected [3]. Classically, RAE is characterized by a benign intraluminal proliferation of endothelial cells, which may occlude the vascular lumina [3]. The vessels are typically dilated and there is often a proliferation of vessels in a diffuse, lobular, or mixed pattern [3, 9].

All the reported cases of DDA have involved women (age range, 28-63 years), with most of them in their 50s [4, 8, 9, 10-15]. At presentation, lesions vary from a solitary erythematous patch to an indurated plaque surrounded by dusky erythema [4]. Ulceration and tenderness are common. The sites most affected are the extremities, especially the upper thigh area [4].

The development of this reactive pattern of angiomas on the breast is rare [4]. Descriptions have been limited to case reports [11, 13, 16] and two small case series [10, 17], for a total of 15 published cases in the literature [18]. The first reported case involving the breast was published in 2001 [8, 13]. However, several recent studies have shown that DDA may be more common on the breast than previously appreciated, with 15 cases having now been reported [1, 3, 10, 18].

Clinically DDA is manifested by multiple, persistent skin ulcers, developing on a background of poorly circumscribed, retiform erythematous-violaceous plaques, often arising in non acral areas (trunk, abdomen, proximal aspects of the extremities [12, 13, 19]. The lesions may be asymptomatic or painful and they tend to be persistent or enlarge progressively [20].

DDA of the breast (DDAB) is usually bilateral [1]. Its clinical presentation consists of non-healing, painful, and poorly circumscribed reticular violaceous erythematous plaques on the breasts with prominent vessels surrounding the lesions [13, 17, 18]. A common complication of DDAB is painful

ulceration of the newly developed superficial vessels through the skin [18].

The pathogenesis of DDA remains unclear and several hypotheses have been assessed [10]. At this time no animal studies have been conducted to elucidate a cause of DDA [18]. The current hypothesis is that prolonged ischemia of tissue (from a variety of mechanisms) leads to upregulating of endothelial growth factors and proliferation of new blood vessels [11-14, 17, 18].

Many predisposing risk factors have been previously associated with DDAB, such as middle adulthood (age between 40 and 65 years), [10, 11, 16, 17], active smoking [11-13, 17], elevated BMI [10, 17], large pendulous breasts [11-14, 17], surgery/trauma [1, 2, 11, 12], diabetes mellitus [4, 10], vaso-occlusive conditions [2, 10, 11, 21], coronary artery disease [11], hypertension [10, 11, 17], calciphylaxis [8, 14], and underlying hypercoagulability [1, 2, 10, 11, 21], e.g. antiphospholipid syndrome [16, 18].

Our patient had no history of ischemia but was noted to have large pendulous breasts and a history of cardiovascular disease. Large pendulous breasts may predispose the tissue to local trauma and ischemia and could result in a subsequent neoangiogenesis [3, 4, 13, 22]. Support for this hypothesis is seen in that of the 15 previously reported cases of DDA of the breast, 8 were described to have pendulous breasts and an additional 3 were noted to have reduction mammoplasties in their medical history [1, 10-13, 17]. Reusche et al. suggest that DDA is a condition that may be related to subclinical torsion owing to macromastia, with an inflammatory response exacerbated by obesity (and potential insulin resistance) and smoking [18]. However, other authors propose that smoking is the main cause of this rare vascular proliferation, resulting in an ischemic process with hypoxia that could lead to vessel proliferation [10]. In the present case, it is possible that trauma of fat-rich areas in her large pendulous breasts caused by the mammogram was responsible for an aggravation of DDA and fat necrosis.

Histologically, DDAB is characterized by a diffuse proliferation of small capillaries and endothelial cells interstitially arranged between the collagen bundles

within the full thickness of the dermis [1, 3, 12, 13, 18, 23, 24]. This feature distinguishes DDA from other types of RAE in which proliferation usually occurs within the vascular lumina [1, 3, 12, 25]. It is hypothesized that this cell proliferation occurs secondarily to the vascular deposition of immunoglobulin or cryoprotein [16, 18].

In some areas, the proliferating cells, which may show a spindle-shaped appearance and vacuolated cytoplasm, form small vascular channels [10]. Scattered extravasated erythrocytes with hemosiderin are also present and atypical mitotic figures are absent [3, 10]. The immunohistochemistry is useful to confirm the normal endothelial phenotype of cells lining the vessels [10]. CD31 and CD34 stains are uniformly positive [10-12, 18], highlighting benign dermal endothelial cell proliferation, whereas HHV-8 is negative [1, 10]. D2-40, a marker of lymphatic endothelium, is typically negative [10].

The diagnosis of DDA should be suspected in patients with cardiovascular risk factors (smoking history seems to be a strong risk factor) who present persistent ulcerations in non acral areas. The characteristic histopathological features permit the establishment of the definitive diagnosis.

The differential diagnosis of DDAB includes mainly Kaposi sarcoma (KS), acroangiokeratitis, and angiosarcoma [1, 3, 4]. Immunoperoxidase stains (CD31, CD34, and HHV-8) can aid in the diagnosis [1]. Features mimicking KS have been described, but several histological features, including frank spindling and atypia of cells, a diffuse slit-like lumen formation with the promontory sign, and the inflammatory component, are lacking in DDAB [4, 10]. Immunohistochemical analysis supports the diagnosis of KS, revealing positivity to CD31, CD34, D2-40, and HHV8 [8]. A lobular proliferation of vessels in the dermis is seen in acroangiokeratitis but not in DDA [3]. Cutaneous angiosarcoma could present as vascular lesions on both breasts [10]. However, histological features are a clue to the differentiation of this aggressive cutaneous neoplasia from DDAB. Angiosarcoma histologically shows multiple vascular channels of different sizes, lined by endothelial and atypical cells, and disposed

in one or more layers [10]. Atypical endothelial cells are more pleomorphic, with pale, light, eosinophilic cytoplasm and voluminous hyperchromatic nuclei [10]. These cells normally show a fasciculated pattern and immunohistochemically are CD31, CD34, and D2-40 positive [26].

Management of DDA generally requires improving underlying tissue hypoxia and ischemia [1, 4]. Successful treatment of DDAB has been reported with a variety of therapies. Treatment has been aimed at reducing the size of lesions and preventing ulceration from occurring, thus providing the patients pain relief and improvement of their aesthetic appearance [18]. Current treatment recommendations for DDAB primarily focus on smoking cessation and control of cardiovascular risk factors such as hypertension and hyperlipidemia, if present [10, 18]. Adjunct medical therapy with agents such as isotretinoin [1, 11-14, 16-18], acetylsalicylic acid, pentoxifylline, antiaggregation, anticoagulation [1, 16], and oral corticosteroids [17, 27] have been reported, though with equivocal success [12, 13, 18].

Although isotretinoin is rarely reported to be associated with the formation of excess granulation tissue [13], most evidence suggests that retinoids have a predominantly antiangiogenic effect [13, 28, 29]. Isotretinoin has also been reported to stimulate the production of tissue plasminogen activator [13, 30], and the resulting increase in fibrinolysis may facilitate wound healing [15, 32]. Because DDA is a disorder of hypervascularity and tissue destruction, the mechanisms of isotretinoin lend this drug an advantage to helping attenuate this disease process [13].

In addition to medical therapy, revascularization is the most efficient method, particularly in cases caused by vaso-occlusive disease, it generally results in complete or near-complete lesion resolution [1, 11, 15, 25, 31]. Surgical management of DDAB with reduction mammoplasty or mastectomy was the only effective modality that resulted in resolution of DDAB without recurrence in some case series [12, 18].

It is notable that our patient had no history of smoking, unlike nearly all the others described in the literature. She also had noted poor improvement with isotretinoin therapy, which can be explained by delay of treatment and association with fat necrosis. The patient benefited from secondary mastectomy (or excision of the affected areas) and has shown no signs of recurrence. The antiangiogenic effects of isotretinoin may explain the partial improvement in symptoms in our case [15].

We conclude that reduction mammoplasty appears to be a viable option for the treatment of DDAB [1, 12] in severe cases and should be discussed with patients who fail medical therapy [10]. Mastectomy should be viewed as the last alternative in the treatment algorithm after the more conservative options have failed. However, careful consideration should be given to this option since DDA can develop after reduction mammoplasty [1, 18].

Analysis and comparison of our data with those published in the literature suggest that DDAB should be considered a well-defined entity that must be differentiated from other distinct diseases.

References

1. Tollefson MM, McEvoy MT, Torgerson RR, Bridges AG. Diffuse dermal angiomatosis of the breast: clinicopathologic study of 5 patients. *J Am Acad Dermatol*. 2014 Dec;71(6):1212–7. [PMID: 25264238].
2. Crickx E, Saussine A, Vignon-Pennamen MD, Cordoliani F, Mouly F, Bagot M, et al. Diffuse dermal angiomatosis associated with severe atherosclerosis: two cases and review of the literature. *Clin Exp Dermatol*. 2015 Jul, 40(5):521–4. [PMID: 25639294].
3. Strausburg MB, Gehlhausen J, Ludwig K, Warren S. Diffuse Dermal Angiomatosis of the Breast With an Apparent Etiology of Underlying Calcified Thrombosed Artery With Adjacent Fat Necrosis. *Am J Dermatopathol*. 2016 Apr 19, [PMID: 27097335].
4. Yang H, Ahmed I, Mathew V, Schroeter AL. Diffuse dermal angiomatosis of the breast. *J Cutan Pathol*. 2009, 36(1):130. [PMID:16549710].
5. Krell JM, Sanchez RL, Solomon AR. Diffuse dermal angiomatosis: a variant of reactive cutaneous angioendotheliomatosis. *J Cutan Pathol*. Blackwell Publishing Ltd, 1994 Aug,21(4):363–70. [PMID: 7798394].
6. Mazloom SE, Stallings A, Kyei A. Differentiating Intralymphatic Histiocytosis, Intravascular Histiocytosis, and Subtypes of Reactive Angioendotheliomatosis. *Am J Dermatopathol*. 2017 Jan,39(1):33–9. [PMID: 28027079].
7. Rongioletti F, Rebora A. Cutaneous reactive angiomatoses: patterns and classification of reactive vascular proliferation. *J Am Acad Dermatol*. 2003 Nov,49(5):887–96. [PMID: 14576670].
8. Creamer D, Black MM, Calonje E. Reactive angioendotheliomatosis in association with the antiphospholipid syndrome. *J Am Acad Dermatol*. 2000 May,42(5 Pt 2):903–6. [PMID: 10767702].
9. McMenamin ME, Fletcher CDM. Reactive angioendotheliomatosis: a study of 15 cases demonstrating a wide clinicopathologic spectrum. *Am J Surg Pathol*. 2002 Jun,26(6):685–97. [PMID: 12023572].
10. Sanz-Motilva V, Martorell-Calatayud A, Rongioletti F, Escutia-Muñoz B, López-Gómez S, Rodríguez-Peralto JL, et al. Diffuse dermal angiomatosis of the breast: clinical and histopathological features. *Int J Dermatol*. 2014 Apr,53(4):445–9. [PMID: 23488550].
11. Yang H, Ahmed I, Mathew V, Schroeter AL. Diffuse dermal angiomatosis of the breast. *Arch Dermatol*. 2006 Mar 1,142(3):343–7. [PMID: 16549710].
12. Mark T, Villa MD, Lucile E, White MD, Vesna Petronic-Rosic MD, MSc David H, Song M. The Treatment of Diffuse Dermal Angiomatosis of the Breast With Reduction Mammoplasty. *Arch Dermatol*. 2008,144(5):693–4. [PMID: 18490610].
13. McLaughlin ER, Morris R, Weiss SW, Arbiser JL. Diffuse dermal angiomatosis of the breast: Response to isotretinoin. *J Am Acad Dermatol*. 2001,45(3):462–5. [PMID: 11511849].
14. Prinz Vavricka BM, Barry C, Victor T, Guitart J. Diffuse dermal angiomatosis associated with calciphylaxis. *Am J Dermatopathol*. 2009,31(7):653–7. [PMID: 19652584].
15. Kim S, Elenitsas R, James WD. Diffuse dermal angiomatosis: a variant of reactive angioendotheliomatosis associated with peripheral vascular atherosclerosis. *Arch Dermatol*. 2002 Apr,138(4):456–8. [PMID: 11939805].
16. Pichardo RO, Lu D, Sanguenza OP, Guitart J. What is your diagnosis? Diffuse dermal angiomatosis secondary to antitricardiolipin antibodies.

Conclusion

We present a rare case of DDAB with adjacent fat necrosis and review the clinicopathologic findings of DDAB. It is likely more common than previously believed. Its recognition is important for early successful treatment. Inclusion of DDA in the differential diagnosis is especially warranted in patients with underlying cardiovascular disease. Many comorbid conditions exist in patients with DDA. Multiple therapies have proven successful and should be carefully chosen based on the clinical setting. Surgical treatment should be discussed with the patient as the last alternative after having failed medical therapy. However, further research is warranted to identify the best treatment modality to manage this distressing condition.

An increased awareness of physicians regarding DDA as a potential causative disease of persistent multiple ulcerations is important in order to avoid a diagnostic delay.

- Am J Dermatopathol*. 2002 Dec,24(6):502–3. [PMID: 12454604].
17. Quatresooz P, Fumal I, Willemaers V, Cornil F, Piérard GE. Diffuse dermal angiomatosis: A previously undescribed pattern of immunoglobulin and complement deposits in two cases. *Am J Dermatopathol*. 2006 Apr,28(2):150–4. [PMID: 16625079].
18. Reusche R, Winocour S, Degnim A, Lemaine V. Diffuse dermal angiomatosis of the breast: a series of 22 cases from a single institution. *Gland Surg*. 2015 Dec,4(6):554–60. [PMID: 26645009].
19. Requena L, Sanguenza OP. Cutaneous vascular proliferations. Part III. Malignant neoplasms, other cutaneous neoplasms with significant vascular component, and disorders erroneously considered as vascular neoplasms. *J Am Acad Dermatol*. 1998 Feb,38(2 Pt 1):143–75, quiz 176–8. [PMID: 9486670].
20. García-Colmenero L, Martín-Ezquerria G, Gómez-Martín I, Mellado Joan M, Barranco C, Albero-González R, et al. Persistent cutaneous abdominal ulcerations secondary to diffuse dermal angiomatosis. *Medicine (Baltimore)*. 2016 Jul,95(29):e4212. [PMID: 27442644].
21. Sriphojanart T, Vachiramom V. Diffuse Dermal Angiomatosis: A Clue to the Diagnosis of Atherosclerotic Vascular Disease. *Case Rep Dermatol*. 2015,7(2):100–6. [PMID: 26120304].
22. Kutzner H, Requena L, Mentzel T, Pfau B. Diffuse dermale Angiomatose. *Der Hautarzt*. 2002 Dec 1,53(12):808–12. [PMID: 12444522].
23. Sriphojanart T, Vachiramom V. Diffuse Dermal Angiomatosis: A Clue to the Diagnosis of Atherosclerotic Vascular Disease. *Case Rep Dermatol*. 2015 May 28,7(2):100–6. [PMID: 26120304].
24. Adams BJ, Goldberg S, Massey HD, Takabe K. A cause of unbearably painful breast, diffuse dermal angiomatosis. *Gland Surg*. 2012 Aug 1,1(2):132. [PMID: 24353983].
25. Krell JM, Sanchez RL, Solomon A R. Diffuse dermal angiomatosis: a variant of reactive cutaneous angioendotheliomatosis. *J Cutan Pathol*. 1994,21(4):363–70. [PMID: 7798394].
26. Wang XY, Jakowski J, Tawfik OW, Thomas PA, Fan F. Angiosarcoma of the breast: a clinicopathologic analysis of cases from the last 10 years. *Ann Diagn Pathol*. 2009 Jun,13(3):147–50. [PMID: 19433291].
27. Sommer S, Merchant WJ, Wilson CL. Diffuse dermal angiomatosis due to an iatrogenic arteriovenous fistula. *Acta Derm Venereol*. 2004,84(3):251–2. [PMID: 15202855].
28. Lingen MW, Polverini PJ, Bouck NP. Inhibition of squamous cell carcinoma angiogenesis by direct interaction of retinoic acid with endothelial cells. *Lab Invest*. 1996 Feb,74(2):476–83. [PMID: 8780165].
29. Oikawa T, Hirotsani K, Nakamura O, Shudo K, Hiragun A, Iwaguchi T. A highly potent antiangiogenic activity of retinoids. *Cancer Lett*. 1989 Nov 30,48(2):157–62. [PMID: 2479461].
30. Dootson GM, Keidan J, Harper PL. The influence of isotretinoin upon fibrinolysis in patients with acne. *Br J Dermatol*. 1995 Jul,133(1):66–70. [PMID: 7669643].
31. Draper BK, Boyd AS. Diffuse dermal angiomatosis. *J Cutan Pathol*. 2006 Sep,33(9):646–8. [PMID: 16965341].