

# UC Irvine

## UC Irvine Previously Published Works

### Title

Treatment Failure Among Infected Periprosthetic Patients at a Highly Specialized Revision TKA Referral Practice

### Permalink

<https://escholarship.org/uc/item/1wb3v540>

### Journal

The Open Orthopaedics Journal, 7(1)

### ISSN

1874-3250

### Authors

Schwarzkopf, Ran  
Oh, Daniel  
Wright, Elizabeth  
[et al.](#)

### Publication Date

2013

### DOI

10.2174/1874325001307010264

Peer reviewed

# Treatment Failure Among Infected Periprosthetic Patients at a Highly Specialized Revision TKA Referral Practice

Ran Schwarzkopf<sup>\*1,§</sup>, Daniel Oh<sup>2,§</sup>, Elizabeth Wright<sup>3</sup>, Daniel M Estok<sup>2</sup> and Jeffery N. Katz<sup>3</sup>

<sup>1</sup>Orthopaedic Department, University of California Irvine Medical Center, Orange, CA, USA

<sup>2</sup>Orthopaedic Department, Brigham and Women's Hospital, Harvard Medical School, Boston, MA, USA

<sup>3</sup>Orthopedic and Arthritis Center for Outcomes Research, Brigham and Women's Hospital, Harvard Medical School, Boston, MA, USA

**Abstract:** Deep infection is a serious and costly complication of total knee arthroplasty (TKA), which can increase patient morbidity and compromise functional outcome and satisfaction. Two-stage revision with an interval of parental antibiotics has been shown to be the most successful treatment in eradicating deep infection following TKA.

We report a large series by a single surgeon with a highly specialized revision TKA referral practice.

We identified 84 patients treated by a two-stage revision. We defined "successful two-stage revision" as negative intraoperative cultures and no further infection-related procedure. We defined "eradication of infection" on the basis of negative cultures and clinical diagnosis.

After a mean follow up of 25 months, eradication of the infection was documented in 90.5% of the patients; some had undergone further surgical intervention after the index two-stage procedure. Successful two-stage revision (e.g. no I&D, fusion, amputation) was documented only in 63.5% of the patients. We also observed a trend between presence of resistant staphylococcus (MRSA) ( $p=0.05$ ) as well as pre-revision surgical procedures ( $p=0.08$ ) and a lower likelihood of successfully two-stage revision.

Factors affecting the high failure rate included multiple surgeries prior to the two-stage revision done at our institution, and high prevalence of MRSA present among failed cases.

The relatively high rate of failure to achieve a successful two-stage revision observed in our series may be attributed to the highly specialized referral practice. Thus increasing the prevalence of patients with previous failed attempts at infection eradication and delayed care as well as more fragile and immune compromised hosts.

**Keywords:** Total knee arthroplasty, periprosthetic joint infection, antibiotic impregnated cement, revision total knee arthroplasty, two-stage revision.

## INTRODUCTION

Total knee arthroplasty (TKA) has been shown to be a reliable and cost-effective procedure, with expected survivorship of around 95% at 15 years [1-4]. Deep infection is a serious and costly complication of TKA, which can increase patient morbidity and decrease patient outcome and satisfaction [5-7]. With an incidence of deep infection between 1%-2% of all primary TKA, and even higher in revision cases, thousands of deep infections of TKA occur annually in the United-States [5-8]. Different treatment options have been described in the literature; two-stage revision with an interval of parental antibiotic treatment has been shown to be the most successful treatment in eradicating deep infection following TKA [7, 9-11]. Success rate of two-stage revision protocols has been shown to be

around 90% and have become the standard of care in North America for chronically infected TKAs [9-15].

A variety of techniques to manufacture the intra-articular antibiotic cement spacer have been reported in the literature and good results have been described for both pre-manufactured and intraoperatively fashioned cement spacers [16-18]. Currently both static and articulating cement spacers are used during the interstage period, each with its reported benefits and complications [15, 19-21]. Static and articulating spacers serve as sources of local antibiotic delivery and maintain soft tissue tensioning. Articulating spacers have been described to help patients maintain a specified range of motion during treatment, which has been shown to facilitate the second stage surgery and improve final range of motion. Reports of fractures of static spacers and dislocation of articulating ones have been described as complications of such treatments [15, 19-21].

We report a large series of patients with deep infection following TKA managed by a single surgeon with a highly specialized revision TKA referral practice. The surgeon used a standardized surgical technique and treatment protocol, including an intraoperative fabricated static cement spacer

\*Address correspondence to this author at 101 The City Drive South, Pavilion III, Building 29, Orange, CA, USA; Tel-714-4565759; E-mail: [schwarzk@gmail.com](mailto:schwarzk@gmail.com)

§The two first authors contributed equally to the preparation of the manuscript.

constructed from a custom-made mold. Intraoperative fabrication of the cement spacer with a customized mold allows the surgeon the freedom of utilizing different cement types, choosing the added amount and type of antibiotics, and customizing the mold to the patient's anatomy. We report the rate of infection eradication and successful two-stage revision, patient and infection characteristics that may predict failure or reinfection, and range of motion achieved after reimplantation.

## METHODS AND MATERIALS

### Study Design and Selection Criteria

This retrospective study was performed after institutional IRB approval from Brigham and Women's Hospital investigation research board. The authors reviewed the charts of all patients who had undergone two-stage TKA revision at a single institution by a single surgeon between 2001-2011. All patients who had undergone a two-stage revision TKA for periprosthetic infection were included in the study. A diagnosis of periprosthetic joint infection (PJI) was based on joint fluid cultures, joint fluid cell count and differential, inflammatory markers, presence of a sinus tract, gross purulence observed at the time of surgery, and a positive histological exam for acute infection and inflammation in tissues obtained during surgery (the criteria used is aligned with current literature guidelines for diagnosis of PJI).

We identified 84 patients who were treated by a two-stage TKA revision for periprosthetic infection by the senior author (DE) with a single surgical technique, utilizing a static antibiotic spacer fabricated intraoperatively with a customized mold.

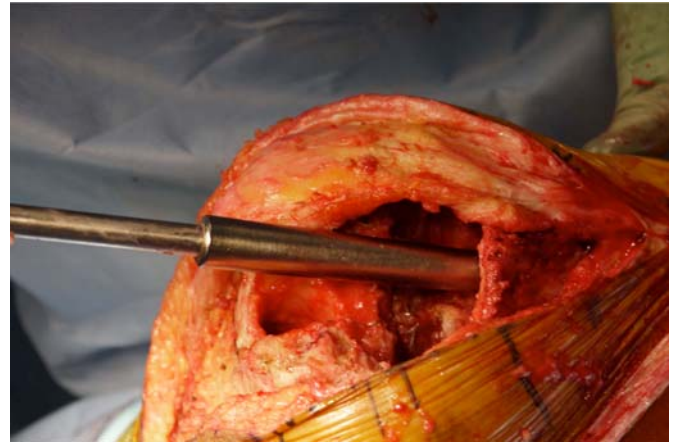
### Data Collection

Demographic and patient data were collected from hospital records for all patients including; BMI, age, gender and infection markers including C-reactive protein (CRP) and erythrocyte sedimentation rate (ESR). Infection data were evaluated by collecting both preoperative and intraoperative cultures, and synovial fluid cell counts and differential. Perioperative complications were recorded from the patients' charts. The overall preoperative medical status of the patients was evaluated by the Charlson comorbidity index [22]. Failure to eradicate infection was diagnosed based on both positive cultures and clinical diagnosis.

### Surgical Technique

A median parapatellar approach was utilized in all cases, with a joint fluid aspiration performed prior to the arthrotomy, followed by an extensive synovectomy and explantation of all implants. Perioperative antibiotics were held until the joint aspiration was completed. Endosteal membrane was removed from both the femoral and tibial medullary canals and was sent for culture and histology.


After verification that entire remaining cement was debrided, a ball tip guide wire was placed down the tibial canal. Sequential flexible reamers were used to ream the tibial and femoral canals until sufficient endosteal chatter was created to remove all retained debris and create a bleeding bony surface. At that point we used our custom-made canal mold seizers (Fig. 1) to measure both the tibial and femoral canal diameters. Then irrigation of both canals was carried out using a pulse lavage device; first three liters of saline solution were used in each



**Fig. (1).** Tibial canal sizing with the costumed tapered canal seizers.

canal, with a long nose tip, followed by one liter of bacitracin solution (33,000 units per liter) in each canal. Subsequently, the entire soft tissue envelope and bony surfaces were irrigated with six liters of saline solution, followed by two liters of bacitracin solution.

To conserve surgical time, we simultaneously fabricated the cement-tapered stems on the back table. Our specialized stem mold (Fig. 2) was used to produce the antibiotic canal spacers. Our protocol includes 80 grams (two packs) of polymethylmethacrylate cement (Simplex P; Stryker, Mahwah, NJ), premixed with 1 gram of tobramycin per 40 grams of cement. To this we added 4.8 grams of tobramycin powder, and 2 grams of vancomycin powder for a total of 4.4 grams of antibiotics per 40 grams of cement powder. For mixing we added a third bottle of monomer due to the added volume of the antibiotics. The cement was mixed and poured into the appropriate size tapered stem molds (Fig. 3). A large threaded Steinmann pin was placed into each cement mold leaving 2 inches protruding beyond the mold (Fig. 4). After full polymerization of the cement, the mold is split and the



**Fig. (2).** Antibiotic cement spacer costume mold.




**Fig. (3).** Antibiotic cement being pored into the costume mold for preparation of an antibiotic spacer.

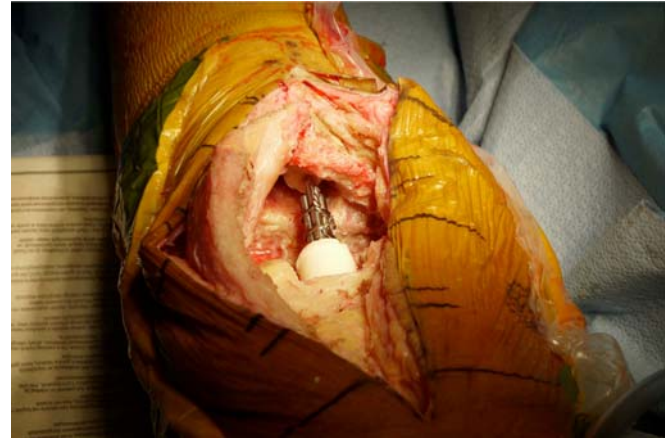

**Fig. (4).** Costume cement spacers curing in the costume mold with Schanz pins inserted as a rebar for spacer strengthening.

stems are removed (Fig. 5). The stems were placed appropriately in the femoral and tibial canals, any excess length of the Steinmann pins was trimmed with a bolt cutter, and the overlapping pins were linked together with an 18-gauge cerclage wire (Fig. 6). The leg was placed in nearly full extension, with physiologic external rotation of the tibia. Three packs of 40 grams of polymethylmethacrylate each

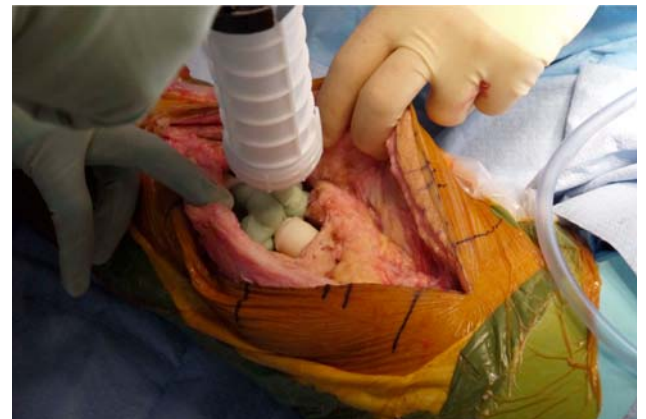

**Fig. (5).** Prepared costume molded cement spacers for the femur and tibia canals.

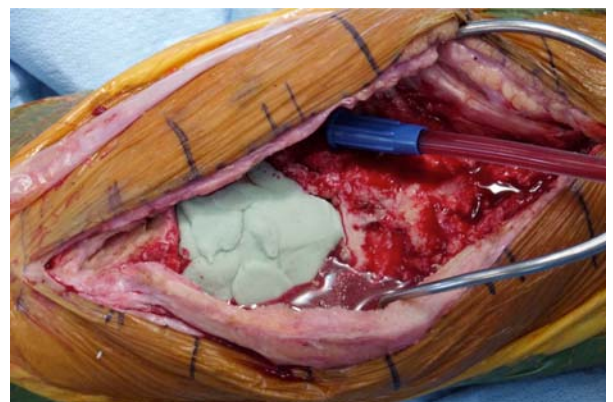


**Fig. (6).** Canal cement spacers placed in the femur and tibia and secured with 18 gage wires.

with premixed 0.5 grams of gentamycin (Palacos R+G; Zimmer, Warsaw, IN) were mixed with 7.2 grams of tobramycin powder, and 3 grams of vancomycin powder for a total of 3.9 grams of antibiotics per 40 grams of cement powder. For mixing we added a fourth bottle of monomer due to the added volume of the antibiotics. The cement was injected into the space created between the distal femur and the proximal tibia overlaying the Steinmann pins (Fig. 7). At this point, during polymerization of the cement, the tourniquet was deflated (Fig. 8).

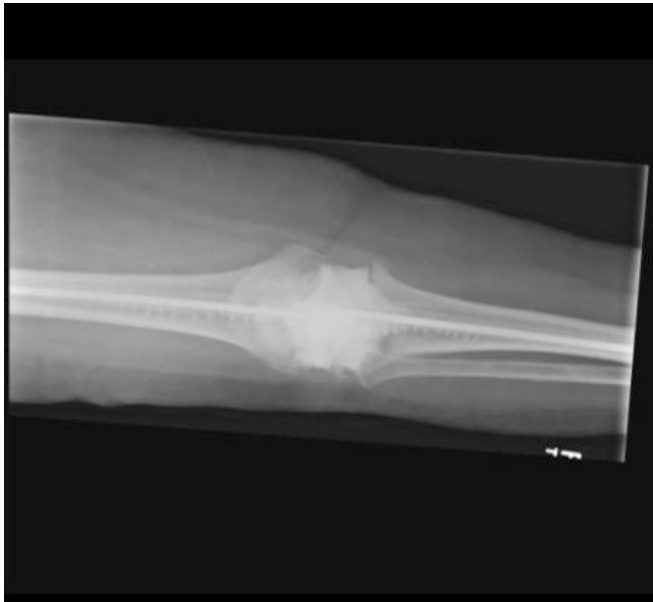

**Fig. (7).** Antibiotic cement added to the knee joint to serve as an intraarticular spacer.



**Fig. (8).** Tourniquet is deflated while the antibiotic cement spacer is hardening.

Patients were allowed to fully weight bear on the operated leg with bilateral upper extremity support as long as the knee immobilizer was in place (Fig. 9). Patients received culture specific intravenous antibiotic treatment for a period of at least 6 weeks under the supervision of an infectious diseases specialist. Patients were followed with serial inflammation markers, CRP and ESR, during this period. Repeat arthrocentesis was done to monitor cell count and cultures after an antibiotic free period of at least 2 weeks. Surgical wound was monitored during office visits at 2 weeks and 6 weeks post operatively, and 1 week prior to the planned 2<sup>nd</sup> stage reimplantation surgery. Patients were monitored for complications related to the procedure and treatment.



**Fig. (9).** Anteroposterior X-ray of the intraarticular antibiotic cement spacer and costume molded canal spacers.

Reimplantation was considered between 3-4 months after the initial procedure if the knee joint aspiration had a negative culture and low cell counts, as well a descending trend of inflammatory markers. Revision surgery was completed with Palacos R+G bone cement (Palacos R+G; Zimmer, Warsaw, IN), and intraoperative tissue and fluid cultures were taken.

We defined “successful two stage revision” if no further surgical procedures were conducted during the follow up period (e.g. irrigation and debridement, explant, fusion, amputation, revision TKA for non infectious etiology); this was our primary outcome. We defined “eradication of infection” if intraoperative cultures at the time of revision surgery were negative and if the patient had no further infection related procedure in the following year; this was our secondary outcome.

#### Data Analysis

Categorical variables were analyzed using chi-square test and Fisher’s exact test. Continuous variables were analyzed using the t-test and Wilcoxon test. All analyses were conducted using SAS software, version 9.1.3 (SAS Institute, Carey, NC).

## RESULTS

Our study cohort consisted of 84 patients who were treated by a two-stage TKA revision for periprosthetic infection. Six patients died and three patients were lost to follow up prior to completing the 2<sup>nd</sup> stage procedure. 75 patients were included in the final analysis, with a mean age of  $67.3 \pm 12.0$  (range 41.4-90.1), 38 males (50.7%), and 37 females (49.3%). Average BMI was  $33.2 \text{ kg/m}^2$  (range 22.6-59.1). A Charlson comorbidities index of 0 or 1 was found in 48% of the patients, 52% had an index of 2 or more. The median length of time between the patient’s primary TKA surgery and the first stage revision surgery was 3.1 years (range: 1 week - 26 years). Sixty of these patients (82%) had more than one surgery on the infected total knee before antibiotic spacer placement. Out of these twenty-two had 2 surgeries prior to antibiotic spacer placement, nineteen had 3, and nineteen had 4 or more surgeries prior to the first stage revision and antibiotic spacer placement at our institution. Two patients had undergone preliminary cement spacer at an outside institution (all of them underwent a repeat 1<sup>st</sup> stage procedure at our institution).

Only 38 of the 75 patients had complete preoperative cultures compared to 67 with complete intraoperative cultures. Staphylococcus species predominated as the organism responsible for the infections, with 34.3% of the preoperative cultures positive for Staphylococcus species (MSSA 21.1%, and MRSA 13.2%), and 41.8% of the intraoperative cultures positive for Staphylococcus species (MSSA 25.4%, and MRSA 16.4%) (Table 1).

**Table 1. Knee Joint Fluid Culture Results Taken in Clinic Before the Patient Underwent Explant and Antibiotic Spacer Placement and During the Procedure Itself**

Microorganism	Preoperative Culture N=38	Intraoperative Culture N=67
	N (%)	N (%)
E. coli	4 (10.5%)	2 (3.0%)
Enterococcus	3 (7.9%)	4 (6.0%)
MSSA	8 (21.1%)	16 (23.9%)
MRSA	5 (13.2%)	11 (16.4%)
Streptococcus (other)	4 (10.5%)	6 (9.0%)
Micrococcus	0	1 (1.5%)
Corynebacterium	0	3 (4.5%)
Peptostreptococcus magnus	0	1 (1.5%)
E.coli/MSSA/P.mirabilis	0	1 (1.5%)
Other	3 (7.9%)	0
No growth	11 (29.0%)	22 (32.8%)
Missing	37 (--)	8 (--)

Joint fluid analysis revealed a median WBC count of 25,650 cells/mcL (range 43-366,000) preoperatively, and 21,400 cells/mcL (range 9-132,000) intraoperatively during the first stage procedure. Prior to reimplantation median

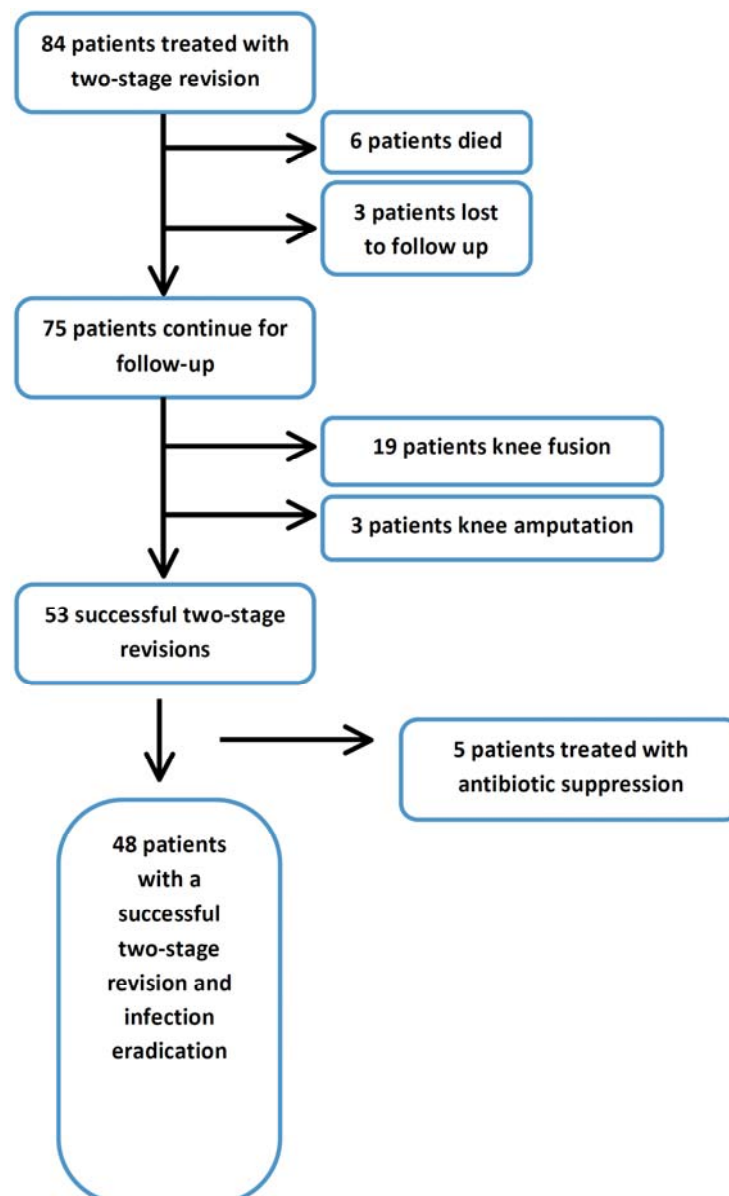
CRP values were 11.8 mm/hr and median ESR values were 50 mg/dL.

Patients' average range of motion in the most recent follow up visit was -2.1 (range: 0 - -15) degrees of extension to 88.7 (range: 0-120) degrees of flexion. Thirty-two (65.3%) of the 49 patients with gait evaluation had a normal gait (evaluated on clinical exam) during their last follow up visit. At final radiographic follow up, none of the reimplanted components were radiographically loose.

After a mean follow up of 25.1 months (range 12 month to 108 months), a successful 2<sup>nd</sup> stage revision procedure was performed on 70.7% of the patients with 5 patients needing continuous antibiotic suppression treatment. Eradication of the infection was documented in 90.7% of the patients, and the presenting infection was eradicated and a successful 2<sup>nd</sup> stage was completed in 64.0% of patients (Table 2). Out of the 75 patient cohort 53 patients had a successful 2<sup>nd</sup> stage reimplantation, 19 underwent further

fusion, and 3 underwent amputation as the final surgical outcome (**Flow Chart**). Criteria for fusion included continued infection as well as compromised extensor mechanism and poor patient medical condition ("Fragile host"). Patients that had an unacceptable risk of persistent infection and poor soft tissue coverage as well as patients that were not candidates of extensor mechanism allograft were offered a knee fusion.

Twelve patients had become reinfected after the two-stage revision; reinfection was documented at an average of 14.6 months after the 2<sup>nd</sup> stage reimplantation procedure. Eight of the patients had the same organism cultured as in the first infection, and 5 patients were infected with a new organism. Six patients were managed with vancomycin, 3 patients were managed with cefazolin, 1 patient with nafcillin, 1 patient with linezolid, and 1 patient with penicillin. Out of the 12 patients that were reinfected, 5 were treated with suppression antibiotics, 4 underwent fusion after



**Flow Chart.**

a subsequent period of antibiotic spacer placement, and 3 underwent amputation after failed attempts of limb salvage.

**Table 2. Patients' Outcomes Among Three End Points: Successful 2-Stage Revision, Eradication of Infection, and Achieving Both a Successful 2-Stage Revision and Eradication of Infection**

Outcome (N=75)	Frequency (N, %)	95% CI
2-stage reimplantation	53 (70.7%)	58.5 - 82.9
Eradication of infection	68 (90.7%)	83.9 - 97.5
2-stage reimplantation + infection eradication	48 (64.0%)	48.7 - 79.3

Out of 75 patients, 8 had a history of a prior infected total joint replacement (in shoulder, hip, or contralateral knee); of these 8 patients, 3 had fusion. Of the 19 patients that underwent knee fusion, 12 were done due to persistent infection and 7 due to extensor mechanism failure in light of previous infection and previous multiple surgeries done in outside hospitals prior to presentation to our center (Table 3).

**Table 3. Association Between Patient Variables, and a Successful 2<sup>nd</sup> Stage Outcome**

Variable	2 <sup>nd</sup> Stage Success (N=53)	2 <sup>nd</sup> Stage Failure (N=22)	p-Value
	N (%)	N (%)	
<b>Sex</b>			
Male	28 (52.8)	10 (45.5)	.56
Female	25 (47.2)	12 (54.6)	
<b>Charlson Score</b>			
0-1	28 (52.8)	8 (36.4)	.19
≥2	25 (47.2)	14 (63.6)	
<b>OR culture*</b>			
None/other	29 (60.4)	10 (52.6)	.56
MSSA/MRSA	19 (39.6)	9 (47.4)	
<b>OR culture*</b>			
None/other	41 (85.4)	15 (79.0)	.49
MRSA	7 (14.6)	4 (21.1)	
<b>Secondary surgery prior to explant</b>			
No	30 (56.6)	8 (36.4)	.11
Yes	23 (43.4)	14 (63.6)	
<b>Other infected joints</b>			
No	48 (90.6)	19 (86.4)	.69
Yes	5 (9.4)	3 (13.6)	

\* < 75 due to missing data.

We found no statistically significant association between successful 2<sup>nd</sup> stage reimplantation and patient Charlson comorbidities index (p=0.19) (Table 3). A trend was noted when we examined the association between the pre-reimplantation levels of ESR and CRP (p=0.09, p=0.06

respectively), and the chance of a successful 2<sup>nd</sup> stage reimplantation (Table 4).

We found a suggestion of an association between any surgical procedure prior to the 1<sup>st</sup> stage procedure and a successful 2<sup>nd</sup> stage procedure with eradication of the infection (Table 3). Although not reaching statistical significance, those without any prior procedures appeared more likely to have a successful outcome with eradication of infection (p=.08). Of those without a prior surgical procedure, 28/38 (74%) had a successful outcome with infection eradication, as contrasted with 20/37 (54%) of those with a prior surgical procedure. In addition, there was a suggestion that those who had a MRSA (resistant staphylococcus) infection were less likely to show infection eradication (p=.05).

## DISCUSSION

Periprosthetic infection after total knee arthroplasty is a devastating complication that increases morbidity for the patient and cost to the medical system. Today, two-stage revision surgery is regarded as the appropriate treatment protocol for chronic periprosthetic infections after TKA. The ultimate goal of two-stage revision surgery is to achieve a lasting eradication of the infection and a durable TKA reconstruction. Eradication of the infection is achieved by implant extraction, debridement and irrigation of the tissues, elution of antibiotics from the polymethylmethacrylate spacer, and systemic, microorganism specific, intravenous antibiotics.

Our study had a few limitations. First we had a relatively small number of patients included in the cohort. Second, due to the small sample size of our study, we were unable to construct a more complex analyses model to examine the multitude of variables among our patients, especially the influence of medical comorbidities. Despite these limitations our study represents a consecutive single surgeon experience with two-stage revision surgery for complicated chronic TKA periprosthetic infection using a single treatment protocol, with most of the patients 82% undergoing multiple surgeries prior to presentation.

Many studies have shown the value of joint fluid analysis for the initial diagnosis of periprosthetic infection [23-25], but few have reported about the predictive value of joint fluid characteristics on the reinfection rate and failure of the two-stage revision surgery [24, 26, 27]. Both Ghanem *et al.* in a study with 109 patients, and Kusuma *et al.* with 76 patients, did not show any predictive value for ESR and CRP lab values taken between the first and second stage procedure in predicting persistent infection [26, 27]. This is in line with the results presented by Mortazavi *et al.* where ESR and CRP were not predictive for the outcome of PJI revisions [28]. However, the study by Mortazai *et al.* attributes this to a possible Type II error. Although all the above studies showed a decrease in both values between the first and second stage procedure in cases where the infection was controlled. In our study we similarly observed a decrease in the levels of ESR and CRP between the first and second stage procedure. We were unable to recommend any cutoff levels due to the small number of patients in our study. In order to achieve significance, a multicenter effort to

**Table 4. Association Between Patients' age, BMI, and Joint Fluid Markers, with 2<sup>nd</sup> Stage Revision Outcome**

Variable	2 <sup>nd</sup> Stage Success		2 <sup>nd</sup> Stage Failure		p-Value
	N	Median (Range)	N	Median (Range)	
Age	53	67.8 (41.4-90.1)	22	69.9 (43.5-85.7)	.50*
BMI	27	30.7 (22.6-48.9)	17	33.7 (23.5-59.1)	.33**
ESR at reimplantation	48	47.5 (4.0-124.0)	19	64.0 (13.0-107.0)	.09**
CRP at reimplantation	50	11.0 (0.4-251.0)	19	14.8 (1.0-193.1)	.06**
WBC at reimplantation	41	19,000 (9-132,000)	12	25,600 (260-99,600)	.37**
PMN (%) at reimplantation	41	86 (2-99)	12	91.5 (16-96)	.27**

\*t-test.

\*\*Wilcoxon test.

create a large patient cohort with comparable treatment protocols is needed in order to achieve these results.

The utility of joint fluid cultures obtained prior to reimplantation is still debated in the literature. Ghanem *et al.* reported a high incidence of both false positive and false negative results. However they still recommended obtaining joint fluid cultures prior to second stage reimplantation [27]. Lonner *et al.* reported that joint fluid cultures taken prior to the second stage reimplantation were not useful in predicting persistent infection [23]. In contrast a study by Kurd *et al.* reported that patients who failed two-stage revision were 3.37 times more likely to have a positive culture for methicillin-resistant bacteria [29]. Tigani *et al.* reported in their study that in the face of positive intraoperative cultures recurrence of infection was 83% compared to 12.5% with negative intraoperative cultures [30]. Similarly, we observed a higher rate of successful two-stage revision in the absence of methicillin-resistant staphylococcus infection.

Patients who undergo an irrigation and debridement procedure prior to a two-stage revision have been shown to have a higher failure rate as demonstrated by Sherrell *et al.* [31]. In their study 34% of the patients who had a previous irrigation and debridement procedure failed a two-stage revision procedure for TKA periprosthetic infection. These data concur with our finding suggesting that patients who had undergone pre-revision surgical procedures had a lower likelihood of a successful two-stage revision.

The higher failure rate of two-stage revision observed in our series may be attributed to the highly specialized referral practice of the senior author, which draws patients that had failed prior interventions for failed and infected TKA as well as poor patient characteristics ("fragile host"). The high rate of knee fusion seen in our cohort can be attributed to the high number of previous surgeries and the condition of the knee and extensor mechanism among our patients upon presentation to our center. Factors affecting the high failure rate may include previous surgical treatment for PJI, 82% of the cohort had multiple surgeries prior to the two-stage revision done at our institution, and high prevalence of MRSA present among failed cases.

Future research in the field should be aimed at finding better diagnostic tools to aid us in our decision process when considering reimplantation for chronic periprosthetic infection.

## CONCLUSION

Patients infected by the staphylococcus organism, and those who have undergone multiple procedures prior to the two-stage revision may have a lower rate of a successful two-stage revision with eradication of the infection.

## CONFLICT OF INTEREST

The authors confirm that this article content has no conflict of interest.

## ACKNOWLEDGEMENTS

Declared none.

## GRANT SUPPORT

- Program for Research Incubation and Development, Dept Orthopedics, BWH.
- NIH P60 AR 47782.

## REFERENCES

- [1] Kelly MA, Clarke HD. Long-term results of posterior cruciate substituting total knee arthroplasty. *Clin Orthop Relat Res* 2002; 404: 51-7.
- [2] Konig A, Kirschner S. Long-term results in total knee arthroplasty [in German]. *Orthopade* 2003; 32: 516-26.
- [3] Ranawat CS, Flynn WF, Saddler S, Hansraj KK, Maynard MJ. Long-term results of the total condylar knee arthroplasty. A 15-year survivorship study. *Clin Orthop Relat Res* 1993; 286: 94-102.
- [4] Gill GS, Joshi AB. Long-term results of cemented, posterior cruciate ligament-retaining total knee arthroplasty in osteoarthritis. *Am J Knee Surg* 2001; 14: 209-14.
- [5] Rand JA, Fitzgerald RH. Diagnosis and management of the infected total knee arthroplasty. *Orthop Clin North Am* 1989; 20: 201-10.
- [6] Spanghel MJ, Hanssen AD. Management of the infected total knee replacement. *Curr Opin Orthop* 2002; 13: 23-9.
- [7] Wilson MG, Kelley K, Thornhill TS. Infection as a complication of total knee-replacement arthroplasty. Risk factors and treatment in sixty-seven cases. *J Bone Joint Surg Am* 1990; 72: 878-83.
- [8] Salvati EA, Robinson RP, Zeno SM, *et al.* Infection rates after 3175 total hip and total knee replacements performed with and without a horizontal unidirectional filtered air-flow system. *J Bone Joint Surg Am* 1982; 64: 525.
- [9] Booth RE Jr, Lotke PA. The results of spacer block technique in revision of infected total knee arthroplasty. *Clin Orthop Relat Res* 1989; 248: 57-60.
- [10] Wilde AH, Ruth JT. Two-stage reimplantation in infected total knee arthroplasty. *Clin Orthop Relat Res* 1988; 236: 23-35.
- [11] Insall JN, Thompson FM, Brause BD. Two-stage reimplantation for the salvage of infected total knee arthroplasty. *J Bone Joint Surg Am* 1983; 65: 1087-98.



- [12] Goldman RT, Scuderi GR, Insall JN. 2-stage reimplantation for infected total knee replacement. *Clin Orthop Relat Res* 1996; 331: 118-24.
- [13] Jacobs MA, Hungerford DS, Krackow KA, Lennox DW. Revision of septic total knee arthroplasty. *Clin Orthop Relat Res* 1989; 238: 159-66.
- [14] Teeny SM, Dorr L, Murata G, Conaty P. Treatment of infected total knee arthroplasty. Irrigation and debridement versus two stage reimplantation. *J Arthroplasty* 1990; 5: 35-9.
- [15] Cohen JC, Hozack WJ, Cucker JM, *et al.* Two-stage reimplantation of septic total knee arthroplasty. Report of three cases using an antibiotic-PMMA spacer block. *J Arthroplasty* 1988; 3: 369.
- [16] Wan Z, Karim A, Incavo SJ, Mathis KB. Preformed Articulating Knee Spacers in 2-Stage Total Knee Revision Arthroplasty: Minimum 2-Year Follow-Up. *J Arthroplasty* 2012; 27(8): 1469-73.
- [17] Van Thiel GS, Berend KR, Klein GR, Gordon AC, Lombardi AV, Della Valle CJ. Intraoperative molds to create an articulating spacer for the infected knee arthroplasty. *Clin Orthop Relat Res* 2011; 469(4): 994-1001.
- [18] Gooding CR, Masri BA, Duncan CP, Greidanus NV, Garbuz DS. Durable infection control and function with the PROSTALAC spacer in two-stage revision for infected knee arthroplasty. *Clin Orthop Relat Res* 2011; 469(4): 985-93.
- [19] Emerson RH Jr, Muncie M, Tarbox TR, Higgins LL. Comparison of a static with a mobile spacer in total knee infection. *Clin Orthop Relat Res* 2002; 404: 132-8.
- [20] Fehring TK, Odum S, Calton TF, Mason JB. Articulating versus static spacers in revision total knee arthroplasty for sepsis. The Ranawat Award. *Clin Orthop Relat Res* 2000; 380: 9-16.
- [21] Huang HT, Su JY, Chen SK. The results of articulating spacer technique for infected total knee arthroplasty. *J Arthroplasty* 2006; 21: 1163-8.
- [22] Charlson ME, Pompei P, Ales KL, MacKenzie CR. A new method of classifying prognostic comorbidity in longitudinal studies: development and validation. *J Chronic Dis* 1987; 40(5): 373-83.
- [23] Lonner JH, Siliski JM, Della Valle C, DiCesare P, Lotke PA. Role of knee aspiration after resection of the infected total knee arthroplasty. *Am J Orthop* 2001; 30: 305-9.
- [24] Trampuz A, Hanssen AD, Osmon DR, Mandrekar J, Steckelberg JM, Patel R. Synovial fluid leukocyte count and differential for the diagnosis of prosthetic knee infection. *Am J Med* 2004; 117: 556-62.
- [25] Della Valle CJ, Sporer SM, Jacobs JJ, Berger RA, Rosenberg AG, Paprosky WG. Preoperative testing for sepsis before revision total knee arthroplasty. *J Arthroplasty* 2007; 22(6 Suppl 2): 90-3.
- [26] Kusuma SK, Ward J, Jacofsky M, Sporer SM, Della Valle CJ. What is the role of serological testing between stages of two-stage reconstruction of the infected prosthetic knee? *Clin Orthop Relat Res* 2011; 469(4): 1002-8.
- [27] Ghanem E, Azzam K, Seeley M, Joshi A, Parvizi J. Staged revision for knee arthroplasty infection: what is the role of serologic tests before reimplantation? *Clin Orthop Relat Res* 2009; 467: 1699-705.
- [28] Mortazavi SM, Vegari D, Ho A, Zmistowski B, Parvizi J. Two-stage exchange arthroplasty for infected total knee arthroplasty: predictors of failure. *Clin Orthop Relat Res* 2011; 469(11): 3049-54.
- [29] Kurd MF, Ghanem E, Steinbrecher J, Parvizi J. Two-stage exchange knee arthroplasty: does resistance of the infecting organism influence the outcome? *Clin Orthop* 2010; 468: 2060-6.
- [30] Tigani D, Trisolino G, Fosco M, Ben Ayad R, Costigliola P. Two-stage reimplantation for periprosthetic knee infection: Influence of host health status and infecting microorganism. *Knee* 2013; 20(1): 9-18.
- [31] Sherrell JC, Fehring TK, Odum S, *et al.* Periprosthetic Infection Consortium. The Chitranjan Ranawat Award: fate of two-stage reimplantation after failed irrigation and débridement for periprosthetic knee infection. *Clin Orthop Relat Res* 2011; 469(1): 18-25.

---

Received: January 7, 2013

Revised: April 13, 2013

Accepted: April 20, 2013

© Schwarzkopf *et al.*; Licensee Bentham Open.This is an open access article licensed under the terms of the Creative Commons Attribution Non-Commercial License (<http://creativecommons.org/licenses/by-nc/3.0/>) which permits unrestricted, non-commercial use, distribution and reproduction in any medium, provided the work is properly cited.