

UC San Diego

UC San Diego Previously Published Works

Title

Continuous Interscalene Brachial Plexus Block for Postoperative Pain Control at Home: A Randomized, Double-Blinded, Placebo-Controlled Study

Permalink

<https://escholarship.org/uc/item/1wh12687>

Journal

Anesthesia & Analgesia, 96(4)

ISSN

0003-2999

Authors

Ilfeld, Brian M
Morey, Timothy E
Wright, Thomas W
[et al.](#)

Publication Date

2003-04-01

DOI

10.1213/01.ane.0000049824.51036.ef

Peer reviewed

Continuous Interscalene Brachial Plexus Block for Postoperative Pain Control at Home: A Randomized, Double-Blinded, Placebo-Controlled Study

Brian M. Ilfeld, MD*, Timothy E. Morey, MD*, Thomas W. Wright, MD†, Larry K. Chidgey, MD†, and F. Kayser Enneking, MD*†

Departments of *Anesthesiology and †Orthopedics and Rehabilitation, University of Florida College of Medicine, Gainesville, Florida

In this study, we investigated the efficacy of patient-controlled regional analgesia for outpatients undergoing moderately painful orthopedic surgery of the shoulder. Preoperatively, patients ($n = 20$) received an interscalene nerve block and perineural catheter. Postoperatively, patients were discharged home with both oral opioids and a portable infusion pump delivering either 0.2% ropivacaine or 0.9% saline, determined randomly in a double-blinded manner. Daily end points included pain scores, opioid use and side effects, sleep quality, and technique complications. Ropivacaine ($n = 10$) infusion significantly reduced pain compared with saline ($n = 10$) infusion. The average pain at rest (scale: 0–10) on postoperative day 1 (median, 25th–75th percentiles) was 4.8 (4.0–5.0) for the saline group, versus

0.0 (0.0–2.0) for the ropivacaine group ($P < 0.001$). Oral opioid use and related side effects were also significantly decreased in the ropivacaine group. On postoperative day 1, median tablet consumption was 8.0 (6.5–9.5) and 0.5 (0.0–1.0) for the saline and ropivacaine groups, respectively ($P < 0.001$). Sleep disturbance scores were nearly threefold greater on the first postoperative night for patients receiving saline ($P = 0.013$). We conclude that after moderately painful orthopedic surgery of the shoulder, ropivacaine infusion using a portable infusion pump and an interscalene perineural catheter at home decreased pain, opioid use and related side effects, and sleep disturbances.

(Anesth Analg 2003;96:1089–95)

More than 40% of ambulatory patients undergoing orthopedic procedures experience moderate-to-severe postoperative pain at home (1). Whereas a single-injection peripheral nerve block provides up to 12–15 h of analgesia after upper extremity procedures, a continuous interscalene perineural infusion of local anesthetic extends analgesia in hospitalized patients for ≤ 5 days (2–4). However, after initial surgical block resolution, ambulatory patients must usually rely on oral opioids that are associated with

undesirable side effects. One placebo-controlled investigation using interscalene perineural catheters demonstrated that their benefits lasted >24 h but exclusively involved hospitalized patients with access to IV opioid patient-controlled analgesia devices (5). At-home interscalene perineural infusion has been reported in three patients (6,7), but the efficacy of this technique has not been investigated in a randomized, double-blinded, placebo-controlled manner. Therefore, this investigation was initiated to determine the efficacy and benefits of local anesthetic infused via an interscalene perineural catheter in ambulatory patients undergoing moderately painful orthopedic surgery of the shoulder.

Methods

After IRB approval, we prospectively enrolled adult patients scheduled for moderately painful ambulatory unilateral orthopedic surgery of the shoulder. Patients were required 1) to be able to understand the possible local anesthetic-related complications, study protocol,

Supported by the Department of Anesthesiology, University of Florida, Gainesville, FL, and the I. Heermann Anesthesia Foundation, Inc., Gainesville, FL.

An abstract of the pilot study for this investigation was presented at the annual meeting of the American Society of Anesthesiologists, October 15, 2001.

Accepted for publication November 18, 2002.

Address correspondence and reprint requests to F. Kayser Enneking, MD, Department of Anesthesiology, PO Box 100254, Gainesville, FL 32610-0254. Address e-mail to enneking@anest2.anest.ufl.edu.

DOI: 10.1213/01.ANE.0000049824.51036.EF

and care of the catheter and infusion pump system; and 2) to have a "caretaker" who would remain with them during the local anesthetic infusion. Exclusion criteria included any contraindication to interscalene nerve block, any known heart or lung disease (with the exception of mild mitral valve prolapse), baseline oxygen saturation of <98% on room air, history of opioid dependence or allergy to study medications, current chronic analgesic therapy, known hepatic or renal insufficiency, peripheral neuropathy, and morbid obesity.

After written, informed consent, patients were placed supine with their head turned slightly away from the operative shoulder. Standard noninvasive monitors were applied, and oxygen was administered via a facemask. Midazolam and fentanyl were titrated IV in divided doses for patient comfort, while ensuring that patients remained responsive to verbal cues. All blocks and catheters were placed by one of the authors. After sterile preparation and draping, a local anesthetic skin wheal was raised over the groove between the anterior and middle scalene muscles, at the cephalad-caudad level of the cricoid cartilage. With the bevel directed anterolaterally, a 3.8-cm, 18-gauge, insulated stimulating needle (Contiplex; B. Braun Medical, Bethlehem, PA) was inserted with the long axis of the needle 45° to both the parasagittal and coronal planes. This was connected to a nerve stimulator (Stimuplex-DIG; B. Braun Medical) initially set at 1.2 mA and 2 Hz. The needle was redirected, as needed, until deltoid, biceps, or more distal muscle group motion was elicited with a minimum current between 0.30 and 0.70 mA.

For the surgical block, 40 mL of anesthetic solution was injected with gentle aspiration between divided doses. The injectate contained mepivacaine 1.5%, sodium bicarbonate 4 mEq, epinephrine 100 µg, and preservative-free clonidine 100 µg. A 20-gauge, multiport, polyamide catheter (B. Braun Medical) was inserted 5 cm past the needle tip. The needle was then removed over the catheter and tunneled as described previously (8). If the catheter could not be advanced past the end of the needle, the needle hub was moved medially, in small increments, until the catheter could be advanced. If the catheter could not be placed after this maneuver, the patient was withdrawn from the study.

After negative aspiration, the catheter was injected with 1 mL of sterile saline 0.9% to ensure patency. The catheter was secured with sterile liquid adhesive, sterile tape, and an occlusive dressing. Patients were withdrawn from the study if a sensory block failed to develop at 15 min or if the catheter was placed in a vessel. Block failure was defined as a lack of any sensory changes to touch from baseline over the deltoid muscle. Specific nerve distributions and degree of

sensory blockade were not formally evaluated. A general anesthetic was administered using propofol, isoflurane, and/or nitrous oxide.

After successful block/catheter placement, patients were randomly assigned in a double-blinded manner to receive 1 of 2 possible postoperative catheter infusions: ropivacaine 0.2% or sterile saline 0.9%, by using a computer-generated randomization table.

Postoperatively, a 3-mL bolus of mepivacaine 1.5%, with 15 µg of epinephrine, was injected incrementally via the catheter as a test for central neuraxial and intravascular positioning after negative aspiration. Three minutes later, 10 mL of study solution was injected incrementally via the catheter. Two portable, disposable, elastomeric, bolus- and basal-capable infusion pumps (Accufuser Plus; McKinley Medical, Wheat Ridge, CO) were connected to a three-way stopcock, which was attached to the catheter. The stopcock would allow flow from only one infusion pump at a time. Each pump had a reservoir containing 275 mL of study solution, and was manufactured to provide a continuous basal infusion of 8 mL/h, with a 2-mL patient-controlled bolus available every 15 min.

The patient and caretaker were given standard postoperative outpatient instructions as well as verbal and written instructions on the use of the pump and catheter. Specific attention was given to signs and symptoms of local anesthetic toxicity, catheter site infection, and catheter migration. Telephone and pager numbers for physicians available at all times were given to each patient. Patients were instructed to keep their operative limb well protected in a sling during the infusion period, unless instructed otherwise by their surgeon or physical therapist. The following supplies were given to patients: a medication log, a prescription for an oral opioid (oxycodone 5 mg) and nonsteroidal antiinflammatory drug (ketorolac 10 mg, taken 3-4 times/d, depending on patient age), 3 additional occlusive dressings, and a pair of nonsterile gloves.

In the event of "break-through" pain, patients were instructed to first use the bolus function of the infusion pump. If the pain had not resolved after 20 min, patients were instructed to use oral opioids and to record this use in their medication log. Before discharge from the ambulatory surgical center, all patients were given oral methadone (5 mg) because approximately half of the enrolled population (patients receiving placebo) would experience resolution of surgical anesthesia without the benefit of a ropivacaine perineural infusion for analgesia.

Patients were telephoned beginning the night of surgery, and each evening thereafter through the night after catheter removal. Information obtained included pain scores (scale: 0-10; 0 = no pain, 10 = worst pain imaginable), oral opioid use, opioid-related

side effects, and sleep quality. Gross sensory and motor function were reviewed. Patients were also questioned about symptoms of local anesthetic toxicity, dyspnea, and the appearance of the catheter site. On the evening of postoperative day (POD) 0, patients were instructed to switch infusion pumps by adjusting the stopcock. Patients were also instructed to contact the physician if they awoke the next morning without any feeling in their shoulder, arm, or hand. If this occurred at any time on or after the morning of POD 1, the patient was instructed to use the stopcock to stop their infusion until they regained feeling in their extremity. In the evening of POD 1, patients were again instructed to switch infusion pumps by adjusting the stopcock.

In the evening of POD 2, patients' caretakers were instructed on removal of the catheter using the pair of nonsterile gloves, with the physician in telephone contact throughout. The presence of a blue catheter tip confirmed complete removal. The infusion pumps, catheter, and any residual infusate were disposed of by the patient. Patients were asked if they would repeat this method of postoperative pain control in the future, and their satisfaction with their postoperative analgesia on a scale of 0–10 (0 = very dissatisfied to 10 = very satisfied). In the evening of POD 3, patients reported their medication log results to the investigator.

Sample-size calculations were centered around our primary hypothesis that local anesthetic infusion via an interscalene perineural catheter decreases postoperative pain. To this end, we chose the outcome variable "average pain at rest" on POD 1 to estimate a probable sample size. We considered a 50% reduction in pain scores to be clinically relevant (mean pain score decrease from 4 to 2 on the scale of 0–10). Based on a standard deviation of each group of 1.5 and assuming a two-sided type I error protection of 0.05 and a power of 0.80, approximately 10 patients in each group were required to reveal a 50% reduction in mean pain scores.

Normality of distribution was determined by using the Kolmogorov-Smirnov test with Lilliefors correction (Sigma Stat 2.03; SPSS, Inc., Chicago, IL). Parametric data were reported as mean \pm SD. Nonparametric data were reported as median with 25th–75th and/or 10th–90th percentiles as indicated in table and figure legends. For normally distributed data, single comparisons were tested by using the *t*-test, whereas multiple comparisons were made by using repeated measures analysis of variance with Tukey *post hoc* pair-wise testing, when appropriate. For nonparametric data, the Mann-Whitney ranked sum test or repeated measures analysis of variance for ranks was used. Nominal data were analyzed by using either χ^2 or the Fisher's exact test, as appropriate. $P < 0.05$ was considered significant. For purposes of data analysis,

patients were always considered a member of their original randomized group.

Results

Of 25 patients enrolled, 2 (8%) had a failed block, and 2 (8%) had catheters that could not be advanced past the needle tip. One patient had an unexpected postoperative admission for social reasons and was excluded. The remaining 20 subjects were randomized to receive either ropivacaine ($n = 10$) or placebo ($n = 10$) infusion. There were no statistically significant differences between these groups before discharge (Tables 1 and 2). All patients were pain free with a dense sensory block (determined grossly) at discharge from the surgical facility.

During the infusion, patients receiving ropivacaine experienced significantly less postoperative pain compared with patients receiving normal saline both on average while resting (Fig. 1A) and worst overall (Fig. 1B). Patients receiving ropivacaine required significantly fewer opioid tablets to achieve this degree of comfort (Fig. 2). Of the 10 patients receiving ropivacaine, 6 (60%) required ≤ 1 opioid tablet during their infusion. In contrast to this, all (100%) patients receiving placebo required ≥ 4 opioid tablets by the evening of POD 0 ($P < 0.001$). Correspondingly, patients receiving ropivacaine experienced almost no opioid-related side effects or sleep disturbances compared with the placebo group (Fig. 3, Table 3).

After initial surgical block resolution, 1 patient experienced a complete lack of sensation in her surgical extremity on POD 2 which resolved after a 1-h discontinuation of local anesthetic infusion. The average satisfaction with postoperative analgesia was scored 8.8 ± 2.7 and 6.5 ± 2.8 by those who received ropivacaine and placebo, respectively ($P = 0.048$). Whereas 90% of patients who received ropivacaine would repeat this analgesic method, only 50% of patients receiving placebo would repeat this technique ($P = 0.141$).

One patient from the saline group had his catheter inadvertently dislodged in the morning of POD 1 while sleeping. One infusion pump was discovered to have failed to discharge when removed from its carrying case on the evening of POD 1 (saline group). It is unclear whether this was a failure of the pump or if the patient had turned the stopcock to an incorrect position because the pump was not subsequently available for examination. Other than these cases, there were no apparent complications during infusion. Patients used the portable, elastomeric infusion pumps without difficulty and caretakers successfully removed all catheters. The main complaint consistently noted by patients (approximately 30%) was leakage of clear fluid from under the occlusive dressing.

Table 1. Population Data for the Two Study Groups

	Ropivacaine (n = 10)	Placebo (n = 10)
Age (yr)	56 ± 7	53 ± 10
Sex (F/M)	8/2	5/5
Height (cm)	166 ± 11	168 ± 16
Weight (kg)	85 ± 13	82 ± 19
IV fentanyl (μg) ^a	124 (95–200)	100 (92.5–200)
IV midazolam (mg) ^a	2.0 (2.0–3.1)	2.0 (2.0–4.0)
Minimum current (mA)	0.53 ± 0.19	0.50 ± 0.13
Surgery duration (min)	87 ± 23	89 ± 38

Values are reported as mean ± sd or median (10th–90th percentiles) for parametric and nonparametric data, respectively.

^a Sedation only for preoperative block placement.

There were no statistically significant differences between the two study groups.

Table 2. Surgical Procedures for Each Study Group

Surgical procedure	Ropivacaine (n = 10)	Placebo (n = 10)
Open rotator cuff repair	4	3
Arthroscopic rotator cuff repair	1	3
Open Mumford/SAD	1	1
Arthroscopic Mumford/SAD	3	2
Arthroscopic acromioplasty	1	1

SAD = subacromial decompression.

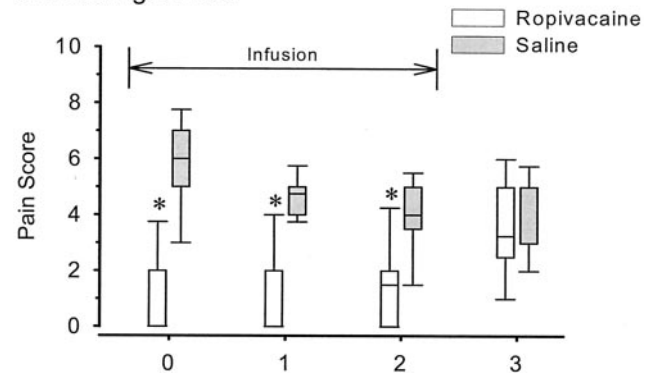
There were no statistically significant differences between the two study groups.

Discussion

This randomized, double-blinded, placebo-controlled study demonstrates that potent analgesia is achievable by using a perineural infusion of ropivacaine via an interscalene perineural catheter after moderately painful shoulder surgery. The local anesthetic infusion provided analgesia so complete that 80% of patients receiving ropivacaine required ≤1 opioid tablet per day during their infusion, and reported average resting pain as <1.5 on a scale of 0–10 (Fig. 1A). This compares with all patients receiving placebo requiring ≥4 opioid tablets per day, beginning the evening of surgery, and reporting average resting pain scores of between 3–4. The worst resting pain scores reflect break-through pain and the difference between treatment groups is even more pronounced (Fig. 1B). Consequently, patients who received ropivacaine experienced a significant decrease in sleep disturbances, oral opioid use, and opioid-related side effects (Figs. 2 and 3, Table 3). These benefits were attained for ambulatory patients with the use of portable, disposable, elastomeric infusion pumps. The degree of analgesia and the relative simplicity of the catheter/pump system led to a very frequent rate of satisfaction for subjects receiving ropivacaine.

Although local anesthetic perineural infusion was clearly shown to provide multiple benefits after moderately painful shoulder surgery when the block and

A. Average Pain



B. Worst Pain

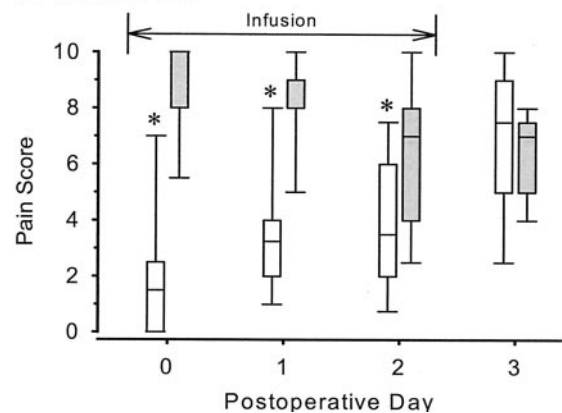


Figure 1. Effects of interscalene perineural infusion of either ropivacaine or placebo on average pain at rest (A) and worst pain overall (B) after moderately painful shoulder surgery (scale: 0–10). Note: the infusion was discontinued after postoperative day 2 as indicated by the horizontal line. Data are expressed as median (horizontal bar) with 25th–75th (box) and 10th–90th (whiskers) percentiles for patients randomly assigned to receive either 0.2% ropivacaine (n = 10) or 0.9% saline placebo (n = 10). For tightly clustered data (e.g., [A], postoperative day 0, ropivacaine group), the median approximated the 10th and 25th percentile values. In this case, the median is 0 and only the 75th and 90th percentiles are clearly noted. *P < 0.05 compared with saline for a given postoperative day.

catheter were correctly placed, we were disappointed by the overall success rate provided by the technique and equipment described above. Of 25 block/catheter attempts, 2 blocks (8%) failed and 2 catheters (8%) could not be inserted. When study group assignments were revealed, it appeared that 2 of the 10 patients receiving ropivacaine had dysfunctional catheters. This resulted in an overall success rate of 76%, less than the success rates previously reported for perineural catheters in other anatomic locations (9–12). The technique and equipment used in this study are nearly identical to those described by previous investigators who initially reported a 100% surgical block and catheter placement success rate in 40 patients with 100% of re-dosed catheters functioning after 24 hours (5). However, these investigators subsequently reported a block failure rate of 12.6% in 143 additional patients, similar to our

Opioid Use

□ Ropivacaine
■ Saline

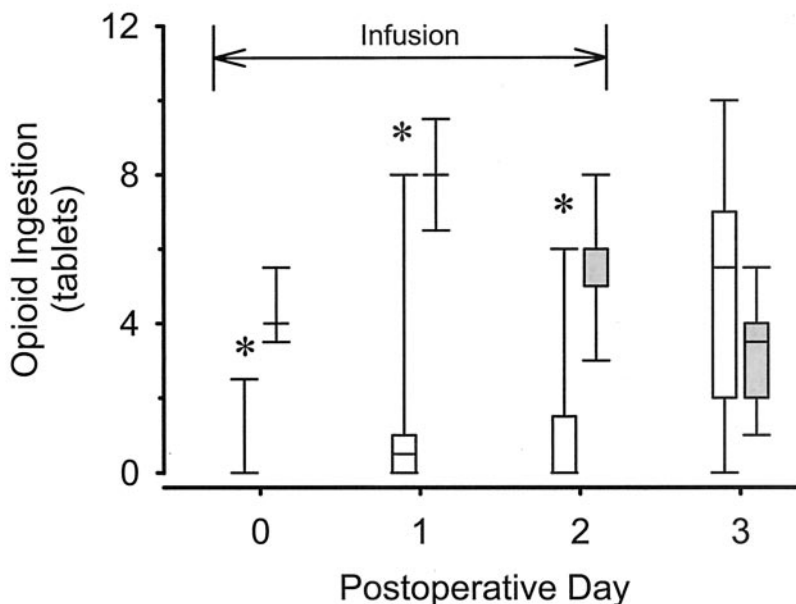


Figure 2. Effects of interscalene perineural infusion of either ropivacaine or placebo on opioid use after moderately painful shoulder surgery. Each tablet consisted of oxycodone 5 mg. Patients recorded opioid use in a daily log. Note: the infusion was discontinued after postoperative day 2 as indicated by the horizontal line. Data are expressed as median (horizontal bar) with 25th–75th (box) and 10th–90th (whiskers) percentiles for patients randomly assigned to receive either 0.2% ropivacaine ($n = 10$) or 0.9% saline placebo ($n = 10$). For tightly clustered data (e.g., postoperative day 0, ropivacaine group), the median approximated the 10th, 25th, and 75th percentile values. In this case, the median is 0 and no box is evident, although the 90th percentile is noted. * $P < 0.05$ compared with placebo for a given postoperative day.

8%, and a 10% catheter failure rate at 24 hours, closer to our 20% (13). An editorial noted that, “because catheter insertion and fixation is technically challenging, continuous ISB [interscalene block] technique has a failure rate of up to 25%” (14). In summary, correctly placed interscalene catheters provide the multiple benefits demonstrated by this investigation, but the methods used for this study provided a relatively small success rate, suggesting that investigations regarding additional techniques (15,16) and equipment (14,16) are warranted.

For interscalene perineural infusions, a pump that provides a basal infusion as well as patient-controlled local anesthetic bolus dosing, also called patient-controlled regional analgesia (PCRA), provides equivalent or superior analgesia with less local anesthetic consumption compared with a continuous infusion or bolus-dosing alone (4). PCRA is important for ambulatory patients because the infusion may be tailored to provide a minimal basal rate to maximize infusion duration, yet allow bolus dosing for break-through pain and before physical therapy. Until recently, portable PCRA-capable pumps allowing both a continuous infusion and patient-controlled bolus have been exclusively electronic, whereas the disposable elastomeric-, spring-, and vacuum-powered infusion pumps offered only one of these functions (5,17).

The infusion pump described in this report is unusual in that it is a nonelectronic/disposable pump that is able to provide both a continuous basal infusion and clinically relevant patient-controlled bolus doses. However, potential benefits of these attributes must be weighed against its fixed infusion rate and bolus

volume/lockout period, which limits infusion flexibility provided by programmable, electronic pumps. The system used in this investigation—a combination of 2 individual 275-mL pumps connected by a stopcock—proved tedious to assemble and somewhat confusing for patients to use. The manufacturer plans to offer a new system with two reservoirs attached to a single bolus button via a Y-connector, which would alleviate these problems.

Although at-home perineural local anesthetic infusion offers significant improvements in pain control after many ambulatory procedures, there are several potential inherent risks involving interscalene catheters, including catheter site infection, nerve injury (2,18), catheter migration (19), local anesthetic toxicity (20), and even epidural/intrathecal anesthesia (21). For this investigation, patients with any known heart (22) or lung disease or a baseline oxygen saturation of <98% on room air were excluded because continuous interscalene local anesthetic infusions have been shown to cause frequent ipsilateral diaphragm paralysis (23). It is not our intention to suggest that inclusion of these patients is an unsafe practice, but rather that we prefer cautious application of this technique until additional investigation of hospitalized, medically supervised patients documents its safety. Related to this, two patients (both receiving ropivacaine) in this study reported mild dyspnea while supine, resolving in the upright position, as has been previously reported in hospitalized patients (5).

In the current investigation, there were no medical complications attributable to the initial regional block,

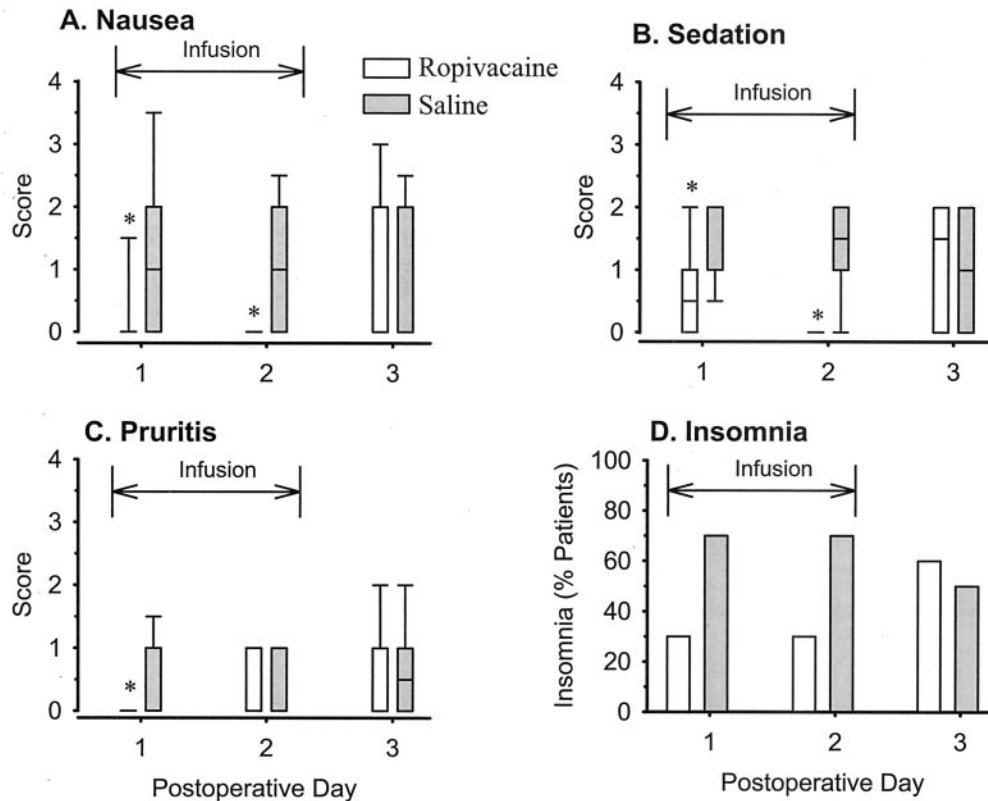


Figure 3. Effects of interscalene perineural infusion of either ropivacaine or placebo on opioid-related side effects and sleep quality after moderately painful shoulder surgery. End points included nausea (A), sedation (B), pruritis (C), and insomnia (D). Note: the infusion was discontinued after postoperative day 2 as indicated by the horizontal line. A–C, Data are expressed as median (horizontal bar) with 25th–75th (box) and 10th–90th (whiskers) percentiles for patients randomly assigned to receive either 0.2% ropivacaine ($n = 10$) or 0.9% saline placebo ($n = 10$). For tightly clustered data (e.g., [A], postoperative day 1, ropivacaine group), the median approximated the 10th, 25th, and 75th percentile values. In this case, the median is 0 and no box is evident, although the 90th percentile is noted. D, Data expressed as fraction of patients reporting insomnia. * $P < 0.05$ compared with placebo for a given postoperative day. See Appendix 1 for side-effects intensity scale. The legend applies to all panels.

Table 3. Number of Awakenings per Night

Postoperative night	Ropivacaine (n = 10)	Placebo (n = 10)	P value
0 (with infusion)	0.0 (0.0–2.4)	2.0 (1.0–4.0)	0.01
1 (with infusion)	0.0 (0.0–4.0)	1.0 (0.9–4.0)	0.13
2 (without infusion)	0.5 (0.0–2.0)	1.0 (0.0–2.0)	1.00

Values are median (10th, 90th percentiles). Responses ≥ 4 were recorded as 4.

catheter placement, or local anesthetic infusion. However, the small number of patients does not permit us to draw definite conclusions about its relative safety. Because not all patients desire, or are capable of accepting, the extra responsibility that comes with the catheter and pump system, appropriate patient selection is crucial for safe ambulatory local anesthetic infusion.

In conclusion, this study demonstrated that ropivacaine infused with a portable infusion pump via an interscalene perineural catheter at home significantly decreased postoperative pain, opioid requirements, and their associated side effects after orthopedic surgery of the shoulder.

McKinley Medical, Wheat Ridge, CO, donated the infusion pumps used in this investigation. The authors thank Jenny Kline Ilfeld, MD, Ocala, FL, for her valuable editorial contributions.

Appendix 1. Nightly Questionnaire

(* Asked POD 1–3; negative responses = 0.)

Pain Scores

“Please answer the following questions regarding your shoulder pain since the last time we spoke using a scale of 0 to 10, 0 being no pain at all and 10 being the worst pain you can imagine.”

1. “What was the worst pain you have felt?”
2. “While you were sitting down resting, what was the average pain you have felt?”

Opioid-Related Side Effects*

"Have you experienced nausea (1-3) or vomiting (4) since the last time we spoke?" If "yes" only to nausea, then: "How would you describe your nausea: minimal (1), moderate (2), or severe (3)?"

"Have you felt unusually sleepy since the last time we spoke?" If "yes", then: "Would you say you were drowsy (1), dosing intermittently (2), mostly asleep (3), or awake only when aroused (4)?"

"Have you experienced unusual itching on any part of your body since the last time we spoke?" If "yes", then: "How would you describe your itching: only under your surgical dressings (1), or on other parts of your body [minimal (2), moderate (3), or severe (4)]?"

Sleep Quality*

"Did you have difficulty sleeping last night because of pain (yes = 1)?"

"Did you awaken last night because of pain?" If "yes," then: "How many times did you awaken last night because of pain (if = \geq 4 awakenings, score = 4)?"

References

1. Rawal N, Hylander J, Nydahl PA, et al. Survey of postoperative analgesia following ambulatory surgery. *Acta Anaesthesiol Scand* 1997;41:1017-22.
2. Borgeat A, Ekatodramis G, Kalberer F, Benz C. Acute and nonacute complications associated with interscalene block and shoulder surgery: a prospective study. *Anesthesiology* 2001;95:875-80.
3. Borgeat A, Schappi B, Biasca N, Gerber C. Patient-controlled analgesia after major shoulder surgery: patient-controlled interscalene analgesia versus patient-controlled analgesia. *Anesthesiology* 1997;87:1343-7.
4. Singelyn FJ, Seguy S, Gouverneur JM. Interscalene brachial plexus analgesia after open shoulder surgery: continuous versus patient-controlled infusion. *Anesth Analg* 1999;89:1216-20.
5. Klein SM, Grant SA, Greengrass RA, et al. Interscalene brachial plexus block with a continuous catheter insertion system and a disposable infusion pump. *Anesth Analg* 2000;91:1473-8.
6. Ilfeld BM, Morey TE, Enneking FK. Patient-controlled analgesia utilizing a portable mechanical pump to infuse local anesthetic via a perineural catheter at home [abstract]. *Anesthesiology* 2001;95:A37.
7. Ilfeld BM, Enneking FK. A portable mechanical pump providing over four days of patient-controlled analgesia by perineural infusion at home. *Reg Anesth Pain Med* 2002;27:100-4.
8. Ekatodramis G, Borgeat A. Subcutaneous tunneling of the interscalene catheter. *Can J Anaesth* 2000;47:716-7.
9. di Benedetto P, Casati A, Bertini L. Continuous subgluteus sciatic nerve block after orthopedic foot and ankle surgery: comparison of two infusion techniques. *Reg Anesth Pain Med* 2002;27:168-72.
10. Capdevila X, Macaire P, Dadure C, et al. Continuous psoas compartment block for postoperative analgesia after total hip arthroplasty: new landmarks, technical guidelines, and clinical evaluation. *Anesth Analg* 2002;94:1606-13, Table.
11. Ilfeld BM, Morey TE, Enneking FK. Continuous infraclavicular brachial plexus block for postoperative pain control at home: a randomized, double-blinded, placebo-controlled study. *Anesthesiology* 2002;96:1297-304.
12. Ilfeld BM, Morey TE, Wang RD, Enneking FK. Continuous popliteal block for postoperative pain control at home: a randomized, double-blinded, placebo-controlled study. *Anesthesiology* 2002;97:959-65.
13. Grant SA, Nielsen KC, Greengrass RA, et al. Continuous peripheral nerve block for ambulatory surgery. *Reg Anesth Pain Med* 2001;26:209-14.
14. Coleman MM, Chan VW. Continuous interscalene brachial plexus block. *Can J Anaesth* 1999;46:209-14.
15. Pham-Dang C, Gunst JP, Gouin F, et al. A novel supraclavicular approach to brachial plexus block. *Anesth Analg* 1997;85:111-6.
16. Boezaart AP, de Beer JF, du Toit C, van Rooyen K. A new technique of continuous interscalene nerve block. *Can J Anaesth* 1999;46:275-81.
17. Ilfeld BM, Morey TE, Enneking FK. The delivery rate accuracy of portable infusion pumps used for continuous regional analgesia. *Anesth Analg* 2002;95:1331-6.
18. Ribeiro FC, Georgousis H, Bertram R, Scheiber G. Plexus irritation caused by interscalene brachial plexus catheter for shoulder surgery. *Anesth Analg* 1996;82:870-2.
19. Hogan Q, Dotson R, Erickson S, et al. Local anesthetic myotoxicity: a case and review. *Anesthesiology* 1994;80:942-7.
20. Tuominen MK, Pere P, Rosenberg PH. Unintentional arterial catheterization and bupivacaine toxicity associated with continuous interscalene brachial plexus block. *Anesthesiology* 1991;75:356-8.
21. Cook LB. Unsuspected extradural catheterization in an interscalene block. *Br J Anaesth* 1991;67:473-5.
22. Smith MP, Tetzlaff JE, Brems JJ. Asymptomatic profound oxygen-hemoglobin desaturation following interscalene block in a geriatric patient. *Reg Anesth Pain Med* 1998;23:210-3.
23. Pere P. The effect of continuous interscalene brachial plexus block with 0.125% bupivacaine plus fentanyl on diaphragmatic motility and ventilatory function. *Reg Anesth* 1993;18:93-7.