

# UCLA

## UCLA Previously Published Works

### Title

Salvage of renal transplant with vacuum-assisted thrombectomy of large ilio caval and allograft venous outflow thrombus

### Permalink

<https://escholarship.org/uc/item/1zc5s42g>

### Journal

Diagnostic and Interventional Radiology, 25(3)

### ISSN

0998-433X

### Authors

Kao, Steven D  
Department of Radiology, Ronald Reagan UCLA Medical Center  
Edwards, Martin P  
et al.

### Publication Date





2019-05-01

### DOI

10.5152/dir.2019.18232

Peer reviewed

# Salvage of renal transplant with vacuum-assisted thrombectomy of large ilio caval and allograft venous outflow thrombus

Steven D. Kao   
Martin P. Edwards   
Stephen T. Kee   
John M. Moriarty 

## ABSTRACT

A 47-year-old male with a remote renal transplant due to pediatric glomerulonephritis on oral anticoagulation for symptomatic deep venous thrombosis and pulmonary emboli presented with sudden hip and groin pain. The patient was found to have a spinal epidural hematoma, underwent reversal of anticoagulation, and subsequently developed worsening renal function. Imaging revealed occlusive ilio caval venous thrombosis with extension to the renal allograft. Given risk of epidural hematoma expansion, the patient was deemed high risk for thrombolysis. The AngioVac system was used for single session thrombus removal. The patient's renal function improved and no focal neurologic sequelae was noted postprocedure. Six-month follow-up showed persistent vessel patency.

Venous thromboembolism has been successfully treated with pharmacologic thrombolysis, pharmaco-mechanical and mechanical thrombectomy. Aspiration thrombectomy is a particularly attractive option when there is a contraindication to anticoagulation or thrombolytic therapy, such as in the setting of trauma, recent major surgery, hemorrhage, or intracranial mass. The AngioVac aspiration thrombectomy system (AngioDynamics Inc.) has demonstrated utility in the evacuation of venous and right atrial thromboembolus, vegetation, foreign body, and tumor mass (1). The large-bore 22 French (F) device provides suction through a venovenous closed-circuit bypass with in-line filtration of autologous blood and outflow via a separate reperfusion catheter. We report a case of an anticoagulation-associated spinal epidural hematoma in which the AngioVac device was successfully used to perform thrombectomy in a patient with extensive ilio caval thrombus causing renal transplant failure secondary to venous obstruction. There was no neurologic sequelae and renal transplant function was salvaged.

## Technique

A 47-year-old male with a history of right iliac fossa renal transplant secondary to pediatric glomerulonephritis presented to an outside hospital with acute onset shortness of breath and posterior right knee pain, with associated erythema and ecchymosis after 6 hours of automobile travel. Imaging revealed deep venous thrombosis (DVT) and pulmonary embolus (PE) for which he was treated with warfarin and discharged home. A week after discharge, the patient experienced acute right hip and groin pain and returned to the outside hospital where magnetic resonance imaging (MRI) of the lumbar spine revealed an L4-S1 epidural hematoma causing severe central canal stenosis and mass effect on the cauda equina (Fig. 1a). The patient's international normalized ratio (INR) was found to be 2.6. Anticoagulation was immediately reversed with prothrombin complex concentrate and a Gunther-Tulip inferior vena cava (IVC) filter placed to prevent further PE. Shortly thereafter, the patient's leg swelling and right hip and groin pain worsened and the serum creatinine level rose to 5.8 mg/dL from a baseline of 1.6 mg/dL. Despite patent transplant renal vasculature on duplex ultrasound, creatinine levels continued to rise over the next several days. Urine analysis and bacterial cultures were unrevealing. The patient was transferred to our institution 8 days after re-admission for advancement of care.

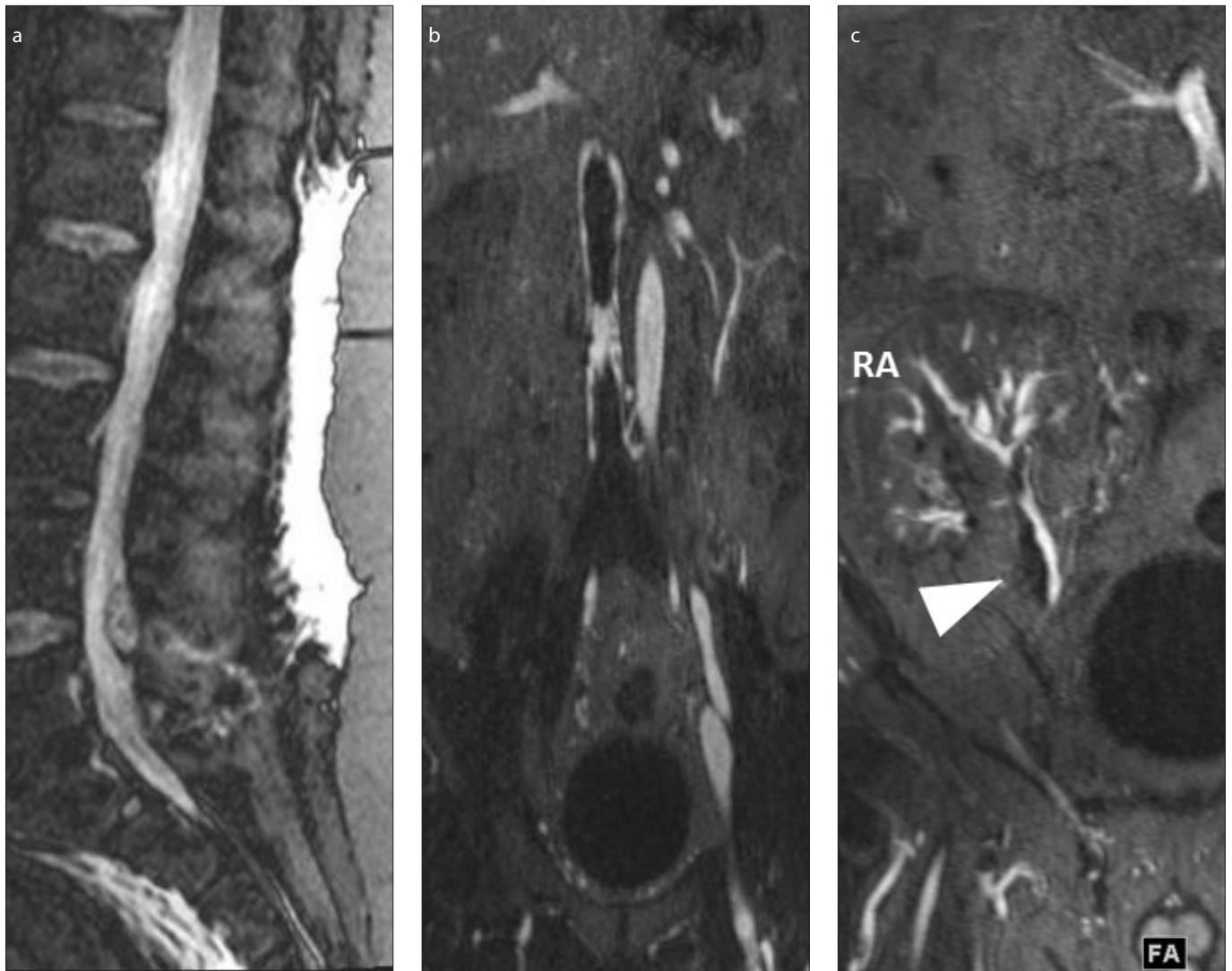
From the Department of Radiology (J.M.M. ✉), [jmoriarty@mednet.ucla.edu](mailto:jmoriarty@mednet.ucla.edu), Ronald Reagan UCLA Medical Center, Los Angeles, CA, USA.

Received 12 May 2018; revision requested 11 July 2018; last revision received 26 July 2018; accepted 15 August 2018.

Published online 28 February 2019.

DOI 10.5152/dir.2019.18232

You may cite this article as: Kao SD, Edwards MP, Kee ST, Moriarty JM. Salvage of renal transplant with vacuum-assisted thrombectomy of large ilio caval and allograft venous outflow thrombus. *Diagn Interv Radiol* 2019; 25:238-241.



**Figure 1.** a–c. Preprocedure sagittal lumbar spine sagittal inversion recovery sequence image (a) demonstrates posterior spinal canal hematoma at level L4–L5. Coronal magnetic resonance venogram (MRV) (b) at the level of the inferior vena cava (IVC) demonstrates extensive ilio caval thrombus about an IVC filter with complete occlusion of the inferior-most IVC and the bilateral common iliac veins. Coronal maximum intensity projection (MIP) image (c) from MRV at the level of the renal allograft (RA). Filling defects (arrowhead) represent non-occlusive thrombus present in the main and lower pole transplant renal veins.

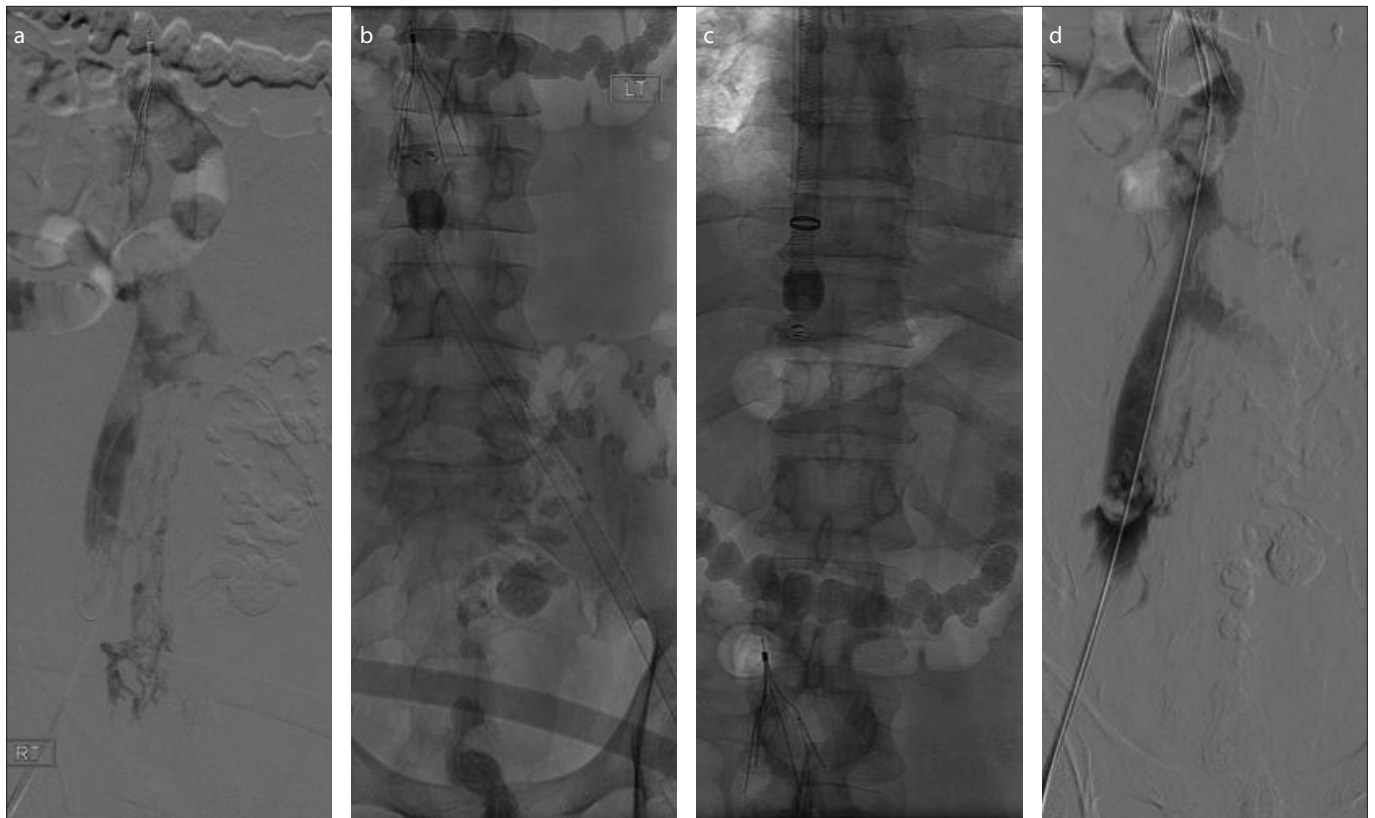
#### Main points

- The AngioVac device allowed for renal transplant function salvage with aspiration and mechanical thrombectomy of extensive ilio caval and transplant renal vein thrombosis in the setting of an epidural hemorrhage precluding pharmacologic anticoagulation.
- Aspiration thrombectomy is a particularly attractive option when there is a contraindication to anticoagulation or thrombolytic therapy, such as in the setting of trauma, recent major surgery, hemorrhage or intracranial mass.
- The AngioVac aspiration thrombectomy system (AngioDynamics Inc.) has demonstrated utility in the evacuation of venous and right atrial thromboembolus, vegetation, foreign body, and tumor mass.

Upon arrival, the patient had right lower extremity swelling and pain. The patient otherwise had a normal neurologic exam and denied shortness of breath or chest pain. Ultrasound demonstrated extensive occlusive thrombus throughout the right lower extremity with extension up to the level of the renal transplant venous anastomosis. Lab values were notable for an INR of 1.1 and activated partial thromboplastin time (aPTT) of 23.3, both within normal range. Ferumoxytol contrast-enhanced magnetic resonance venography (MRV) (2), demonstrated a large infrahepatic caval thrombus extending from the IVC filter down into the bilateral common, external and internal iliac veins and nonocclusive thrombus within the transplant renal vein (Fig. 1b, 1c). Thromboly-

sis was contraindicated due to risk of epidural hematoma expansion. However, given the risk of imminent renal graft loss due to venous outflow occlusion, mechanical thrombectomy using the AngioVac device with administration of tightly controlled short duration intraprocedural anticoagulation was considered the best option. The benefits, risks and alternatives of this off-label use of the AngioVac device were discussed with the patient. The patient understood and consented to the procedure.

Following induction of general anesthesia, a 26 F dry-seal sheath (W.L. Gore) and an 18-F reperfusion catheter were placed to the level of the right atrium and superior vena cava, respectively, in dual right internal jugular vein access sites. Another 26 F dry-seal sheath was



**Figure 2. a–d.** Intraprocedural frontal venogram (a) from right groin sheath demonstrates extensive thrombus within the ilio caval system. In panel (b), the AngioVac aspiration cannula was advanced via left groin sheath and suction thrombectomy performed from the sheath to the IVC filter. In panel (c), the aspiration cannula was placed through the right jugular vein sheath and suction left on while multistation mechanical thrombectomy was performed from the right common femoral sheath. Follow-up angiogram (d) confirmed removal of the majority of ilio caval thrombus.

placed into the left common femoral vein. The occluded right femoral vein was cannulated, a 5 F glide catheter was passed into the IVC and exchanged for an 8 F vascular sheath. Venography confirmed absence of flow within the IVC and bilateral iliac veins. Systemic heparinization was carefully initiated with a target activated clotting time of 200–250 seconds. The extracorporeal circuit was brought to the field, prepared and de-aerated. The aspiration catheter was advanced through the left groin dry-seal sheath to the IVC and continuous aspiration was initiated with reperfusion through the right internal jugular (RIJ) access. Extracorporeal bypass flow was increased up to 1.6 L/min. Multiple passes were made through the thrombosed ilio caval system up to the level of the IVC filter with aspiration of large quantities of thrombus (Fig. 2). The circuit was then reconfigured so that aspiration was subsequently performed from the RIJ access. Multiple passes through the iliac veins and IVC were made with extraction of large volume of thrombus. The aspiration catheter was then advanced to the superior aspect of the IVC filter. With continuous AngioVac suction, we proceeded to macerate the infrarenal ilio caval thrombus with dual

16 mm × 4 cm balloons inserted through the bilateral groin sheaths and a 7 F rotational thrombectomy device (Cleaner, Argon Medical) inserted through the right groin sheath. Subsequent low-dose venography confirmed antegrade flow within the iliac veins and IVC with minimal residual thrombus. Given the desire to limit anticoagulation in the setting of an epidural collection, the procedure was completed with a heparinization duration of 1 hour 10 minutes. Access sites were closed with purse string sutures and hemostasis achieved. Vitals were stable throughout the case.

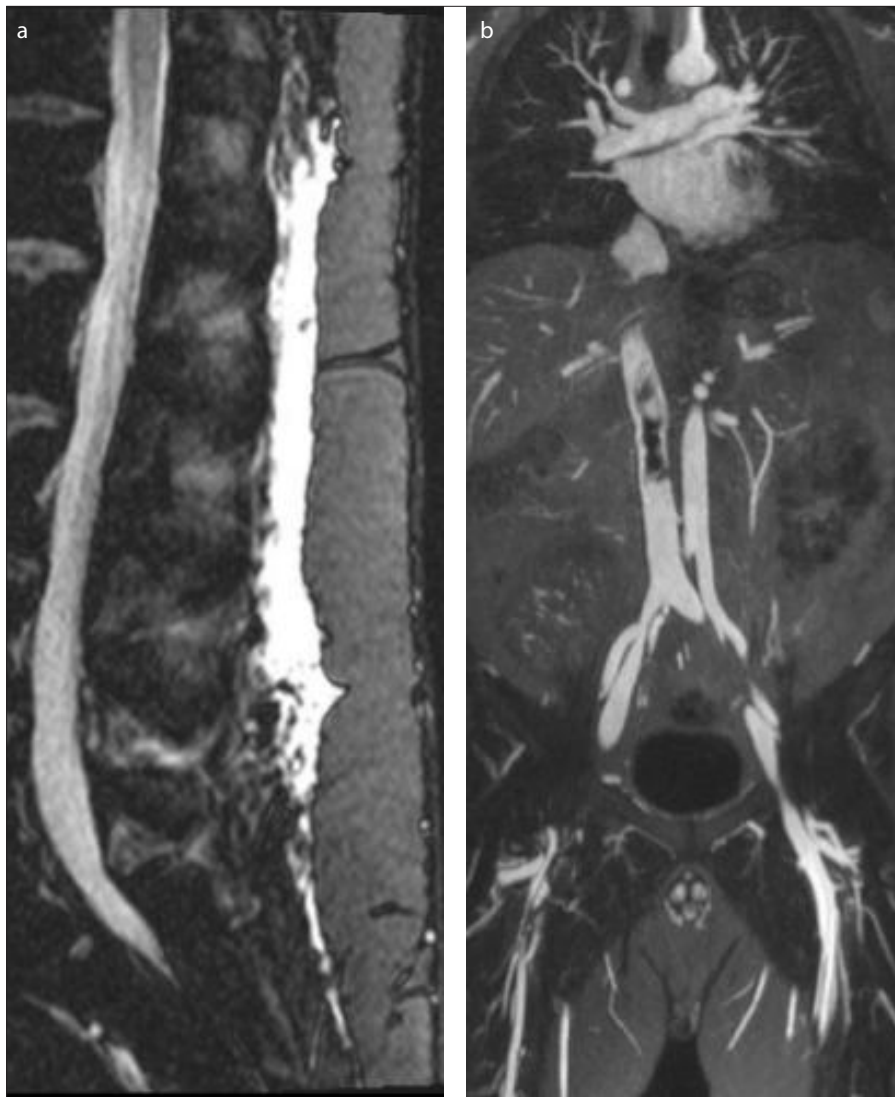
Following the procedure, there was immediate improvement in the patient's urine output and the serum creatinine level returned to baseline over the next 3 days without the need for hemodialysis. There was no focal neurologic sequelae and therapeutic heparin anticoagulation was reintroduced 10 days following onset of epidural hematoma and 2 days post-procedure. The patient's leg swelling and pain improved. Follow-up lumbar MRI and pelvic MRV performed 5 days later demonstrated a decrease in size of the epidural collection (Fig. 3a) and patent infrarenal

IVC and bilateral iliac veins with some residual thrombus about the IVC filter and in the right lower extremity veins distal to the renal allograft vessels (Fig. 3b). Further rheolytic thrombectomy and IVC filter retrieval were performed on postprocedure day 7. Subsequent intravascular ultrasound examination demonstrated widely patent veins without significant residual thrombus. The patient was discharged on coumadin with weekly clinic visits to maintain a target INR of 2–3. At 3-month clinic follow-up, the patient's symptoms were improved with mild residual right lower extremity pain and swelling that was well-controlled with leg elevation and compression stockings. At 6-month clinic follow-up, the patient was asymptomatic and renal function was stable. Renal allograft and right lower extremity ultrasound demonstrated widely patent veins without thrombus and anticoagulation was discontinued at that time.

## Discussion

Organ or limb threatening venous thrombosis requires rapid diagnosis and management, typically involving anticoagulation with additional thrombolysis or thrombectomy.





**Figure 3. a, b.** Postprocedure sagittal lumbar spine sagittal inversion recovery sequence (a) demonstrates reduction in size of posterior spinal canal hematoma at level L4-L5 after minimizing heparin anticoagulation intra- and postprocedurally. Coronal MRV MIP image (b) demonstrates some residual thrombus extending superiorly from the IVC filter and in the infrarenal transplant right lower extremity deep venous system. Angiojet thrombectomy and IVC filter retrieval via a right jugular vein sheath was subsequently performed.

When there are contraindications to thrombolysis and/or anticoagulation, therapeutic options become limited. Thrombolytic therapy was contraindicated in this patient given risk of devastating neurologic sequelae (3). Another option, surgical thrombectomy, involving open groin incisions for direct venotomy, with possible adjunctive creation of an arteriovenous fistula and open abdominal incisions, was considered greater risk (4, 5).

Multiple case series have supported the safety and efficacy of the AngioVac device for suction thrombectomy within the right heart and ilio caval system (6, 7). However, there has been no report to date of its use in transplant kidney salvage, particularly in the setting of spinal epidural hemorrhage. The

AngioVac was a particularly attractive option in this case with extensive clot burden due to the device's large caliber, high suction pressure (up to 80 mm Hg) and repletion of autologous intravascular volume through a reperfusion catheter without the need for blood transfusions. The catheter contains a funnel-shaped tip that can be expanded up to 48 F, which allows for apposition of vessel walls and aspiration of large volume mural thrombus. Newer angled cannulas now offer additional flexibility for targeted thrombectomy. With suction and reperfusion rates of up to 3 L/min, close monitoring of patient hemodynamics and circuit performance by a trained anesthesiologist and perfusionist is essential. Large volumes of thrombus

may be extracted and collected in the filter, which can be replaced intraprocedurally to facilitate en-bloc removal. Combination with other devices such as balloon maceration may aid in thrombus removal.

Normally, an activated clotting time of >300 seconds is targeted for AngioVac thrombectomy (8); however, our goal of 200–250 seconds was established to reduce bleeding risk. Since the patient tolerated the procedure without adverse event, intravenous heparin with bridging to warfarin was initiated 48 hours postprocedurally with close physiologic and biochemical monitoring. It is considered likely that the nidus for his thrombotic progression was due to the IVC filter, hence its removal prior to discharge. Warfarin was chosen for outpatient anticoagulation due to its reversibility in the event of a bleed, a significant factor that is not widely available in more novel agents.

In conclusion, the AngioVac device may be a potentially useful tool in the event of extensive ilio caval thrombosis causing venous obstruction and renal transplant failure.

#### Conflict of interest disclosure

J.M.M. declares research grant funds from Angiodynamics Inc. The remainder of the authors declare that they have no conflict of interest.

#### References

- Moriarty JM, Al-Hakim R, Bansal A, Park JK. Removal of caval and right atrial thrombi and masses using the angiovac device: initial operative experience. *J Vasc Interv Radiol* 2016; 27:1584–1591. [\[CrossRef\]](#)
- Finn JP, Nguyen KL, Ayad I, Hu P. Cardiovascular MRI with ferumoxytol. *Clin Radiol* 2016; 71:796–806. [\[CrossRef\]](#)
- Popuri RK, Vedantham S. The role of thrombolysis in the clinical management of deep vein thrombosis. *Arterioscler Thromb Vasc Biol* 2011; 31:479–484. [\[CrossRef\]](#)
- Meissner MH, Gloviczki P, Comerota AJ, Wakefield TW. Early thrombus removal strategies for acute deep venous thrombosis: clinical practice guidelines of the Society for Vascular Surgery and the American Venous Forum. *J Vasc Surg* 2012; 55:1449–1462. [\[CrossRef\]](#)
- Plate G, Einarsson E, Qvarfordt P, Eklöf B. Thrombectomy with temporary arteriovenous fistula: the treatment of choice in acute iliofemoral venous thrombosis. *J Vasc Surg* 1984; 1:867–876. [\[CrossRef\]](#)
- Smith SJ, Behrens G, Sewall LE, Sichlau MJ. Vacuum-assisted thrombectomy device (AngioVac) in the management of symptomatic ilio caval thrombosis. *J Vasc Interv Radiol* 2014; 25:425–430. [\[CrossRef\]](#)
- Dudiy Y, Kronzon I, Cohen HA, Ruiz CE. Vacuum thrombectomy of large right atrial thrombus. *Catheter Cardiovasc Interv* 2012; 79:344–347. [\[CrossRef\]](#)
- Teo TK, Angle JF, Turba UC, Matsumoto AH. Incidence and management of inferior vena cava filter thrombus detected at time of filter retrieval. *J Vasc Interv Radiol* 2011; 22:1514–1520. [\[CrossRef\]](#)