

UCLA

UCLA Previously Published Works

Title

Anterior Skull Base Osteoradionecrosis in the Age of Intensity-Modulated Radiation Therapy: A Case Series.

Permalink

<https://escholarship.org/uc/item/1zg128cw>

Journal

Journal of Neurological Surgery Reports, 84(3)

ISSN

2193-6358

Authors

Kosaraju, Nikitha

Zhang, Huan

Qi, Sharon

et al.

Publication Date

2023-07-01

DOI

10.1055/a-2164-8637

Peer reviewed



Anterior Skull Base Osteoradionecrosis in the Age of Intensity-Modulated Radiation Therapy: A Case Series

Nikitha Kosaraju¹ Huan Zhang² Sharon Qi³ Robert Chin³ Marilene B. Wang²

¹David Geffen School of Medicine at UCLA, Los Angeles, California, United States

²Department of Head and Neck Surgery, UCLA Medical Center, Los Angeles, California, United States

³Department of Radiation Oncology, UCLA Medical Center, Los Angeles, California, United States

Address for correspondence Marilene B. Wang, MD, Department of Head and Neck Surgery, UCLA Health, 200 Medical Plaza Ste. 550, Los Angeles, CA 90095, United States (e-mail: mbwang@mednet.ucla.edu).

J Neurol Surg Rep 2023;84:e109–e112.

Abstract

Background Despite advances in radiation technology, skull base osteoradionecrosis (ORN) continues to be a rare, devastating, and hard to treat complication of radiotherapy. We present three cases of anterior skull base ORN in a cohort treated with intensity-modulated radiation therapy (IMRT).

Case Series Three patients developed anterior skull base ORN after receiving at least one round of IMRT. ORN was diagnosed through either nasal endoscopy or imaging findings. The first was a 59-year-old woman with a sinonasal squamous cell carcinoma. Her chemoradiation history was notable for reirradiation and a high dose of radiation (143.3 Gy). The second was a 55-year-old man with recurrent nasopharyngeal carcinoma, whose history was notable for a high dose of radiation (~140 Gy) and for being reirradiated. The final patient was a 37-year-old woman with an unremarkable history who received radiotherapy (65.0 Gy) for an esthesioneuroblastoma. One patient was asymptomatic and did not receive ORN-specific therapy. The other two were treated with a combination of medical and surgical intervention with successful short-term outcomes (no evidence of infection).

Conclusion Anterior skull base ORN can be treated through conservative and surgical means to achieve successful short-term outcomes. Further investigation of long-term outcomes is warranted.

Keywords

- ▶ osteoradionecrosis
- ▶ skull base
- ▶ sinonasal tumor
- ▶ nasopharyngeal tumor
- ▶ radiation therapy

Introduction

Osteoradionecrosis (ORN) is a rare, but potentially morbid and costly complication of radiation therapy (XRT) for head and neck tumors.^{1–3} It is defined as irradiated, exposed necrotic bone that does not heal over a period of at least

3 months.^{4,5} Current literature indicates an incidence of 0 to 13% depending on the specific malignancy.^{5–7} ORN most likely develops because XRT causes hypocellularity, hypovascularity, and abnormal osteoblast and osteoclast activity, leading to ischemic necrosis.^{8–10} In otolaryngology, the most common ORN site is the mandible; however, ORN has also

received

August 10, 2023

accepted after revision

August 29, 2023

accepted manuscript online

September 1, 2023

DOI <https://doi.org/10.1055/a-2164-8637>.

ISSN 2193-6358.

© 2023. The Author(s).

This is an open access article published by Thieme under the terms of the Creative Commons Attribution-NonDerivative-NonCommercial-License, permitting copying and reproduction so long as the original work is given appropriate credit. Contents may not be used for commercial purposes, or adapted, remixed, transformed or built upon. (<https://creativecommons.org/licenses/by-nc-nd/4.0/>)

Georg Thieme Verlag KG, Rüdigerstraße 14, 70469 Stuttgart, Germany

Table 1 Skull base osteoradionecrosis patients: clinical histories and radiotherapy metrics

Patient	Clinical summary	Presenting symptoms	XRT type	XRT maximum dose (grays)	Significant components of clinical history
Patient A	59-year-old woman with a history of breast cancer and rheumatoid arthritis treated with methotrexate who received chemoradiation for a sinonasal squamous cell carcinoma. She developed ORN 19 months out from reirradiation	Xerostomia and headache	IMRT	Course 1: 68.4 Course 2: 64.8	History notable for immunosuppression prior to XRT, two courses of XRT to the head and neck, and a high accumulated dose of XRT
Patient B	55-year-old man with a history of tuberculosis and recurrent nasopharyngeal carcinoma who received chemoradiation. He developed ORN within 11 months of being reirradiated	Nasal crusting and foul odor	Course 1: unknown Course 2: IMRT	Course 1: 76.0 Course 2: 69.3	History notable for two courses of XRT and a high accumulated dose of XRT
Patient C	37-year-old woman with no significant past medical history who received XRT for an esthesioneuroblastoma. She developed ORN 15 months out from XRT completion	Dry mouth, epistaxis, and nasal crusting	IMRT	60.0	Unremarkable history

Abbreviations: IMRT, intensity-modulation radiation therapy; ORN, osteoradionecrosis; XRT, radiotherapy.

occurred in the anterior, central, and lateral skull base.^{1,5-7,11-14} Timely diagnosis and treatment of skull base ORN can prevent complications such as internal carotid artery bleeding, meningitis, cerebrospinal fluid leaks, pathologic fractures, and more.^{2,6,15,16} Treatment strategies include antibiotics, hyperbaric oxygen (HBO), pentoxifylline and tocopherol, and surgical intervention.¹⁴ Surgical treatments commonly include sequestrectomy, soft tissue debridement, fistula closure, and flap reconstruction (both local and free flaps).^{2,14}

Here, we present three cases of anterior skull base ORN that developed in patients treated with a newer radiation technique, intensity-modulated radiation therapy (IMRT) (► **Table 1**). Radiation necrosis was identified either by nasal endoscopy or imaging studies conducted for routine surveillance of disease recurrence. Treatment success was defined as no evidence of infection. This series illustrates how symptomatic anterior skull base ORN can be successfully treated in the short term through either medical therapies or surgical intervention. This study was approved by the Institutional Review Board (IRB# 13-000154).

Case Reports

Case #1

Patient A, a 59-year-old woman with a history of breast cancer and rheumatoid arthritis, presented with T4aN0 right ethmoid sinus squamous cell carcinoma. She completed her

first course of XRT in September 2013, consisting of 50.4 grays (Gy) to the right neck with a boost to 68.4 Gy in 38 fractions to the nasal cavity, paranasal sinuses, and frontal bone. The patient experienced a recurrence in the right orbit and completed her second course of XRT in January 2016. Her second course consisted of IMRT of 64.8 Gy in 54 fractions twice a day to the right orbit. In June 2016, she had biopsy-positive dermal metastases for which she started cetuximab and Taxol. The patient then developed a fistula from the nasal bridge to the posterior nasal cavity, which could have been due to either recurrent tumor or a radiation side effect. Computed tomography imaging in August 2017 revealed nonsymptomatic osteolysis in the frontal sinus (► **Fig. 1A**). Given that she was nonsymptomatic and the patient did not develop any further sequelae from her ORN, the patient did not receive any ORN-specific treatment. The patient continued to have recurrent progressive disease with lymph node involvement and passed away from disease complications in December 2017.

Case #2

Patient B, a 55-year-old man with a history of tuberculosis and nasopharyngeal carcinoma (NPC), presented in December 2011 with his magnetic resonance imaging showing recurrence in the right Eustachian tube, the clivus, and the right cavernous sinus with extensive perineural spread involving CN V₂, V₃, and the superficial petrosal nerve. The patient's NPC had previously been treated in China in

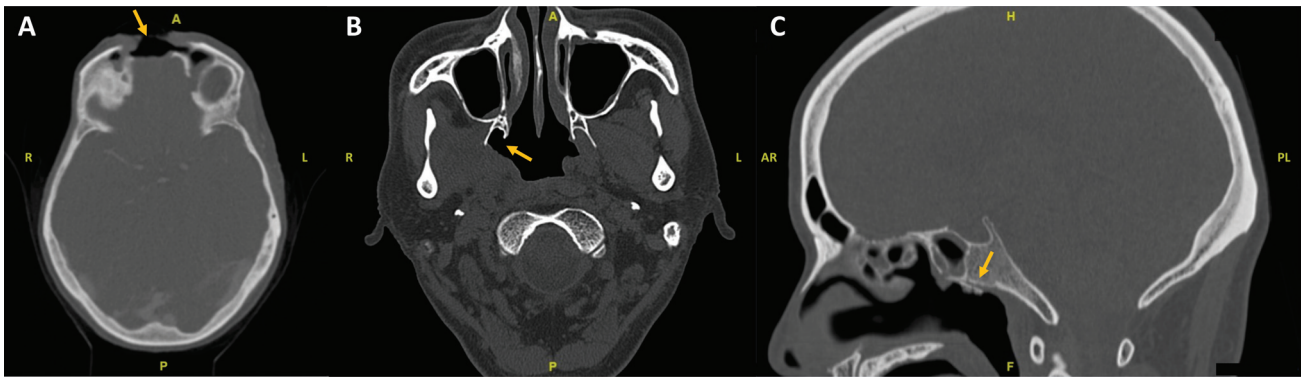


Fig. 1 CT images of ORN findings. (A) Osteolysis of the frontal sinus of patient A. (B) Exposed bone at the right pterygoid plates of patient B. (C) ORN of the clivus of patient B. CT, computed tomography; ORN, osteoradionecrosis.

August 2004 with radiation consisting of 76 Gy to the nasopharynx, 70 Gy to the right neck, and 50 Gy to the rest of the neck. The patient completed his second course of XRT in January 2012, which involved IMRT of 33 fractions consisting of 69.3 Gy to the right-sided tumor with margin, 62.7 Gy to high-risk neighboring sites for local invasion, and 56.1 Gy to moderate risk local disease. Eleven months from completing XRT, he was diagnosed with a nasopharyngeal infection and nasal endoscopy revealed exposed bone on the roof and the right lateral aspect of the nasopharynx. Imaging revealed ORN of the right pterygoid plates (► Fig. 1B) and the clivus (► Fig. 1C). Management of this complication consisted of multiple courses of oral and topical antibiotics, surgical resection of the necrotic clival bone with coverage of exposed bone using a pedicled middle turbinate flap, and intravenous cefepime for 4 weeks. The patient was lost to follow-up from lack of insurance in December 2013. However, at the time of his last visit, the patient did not have an active infection of his paranasal sinuses or nasopharynx and further management recommendations consisted of nasal irrigation, oral antibiotics during flare-ups, and antibiotic washes as needed.

Case #3

Patient C, a 37-year-old woman status-post endoscopic resection and XRT for esthesioneuroblastoma, was found to have infected exposed bone below the sphenoid sinus ostium and in the nasopharynx in October 2015 after completing XRT and carboplatin in July 2014. Her XRT course consisted of IMRT of 30 fractions of 60.0 Gy to the primary tumor with margin, 54.0 Gy to high-risk neighboring sites for local invasion, and 51.9 Gy to moderate risk local disease. ORN management consisted of multiple courses of oral and topical antibiotics and cauterization of the exposed bone, with successful eradication of infection and no known recurrence of infection. The patient was later diagnosed with a recurrence of esthesioneuroblastoma along the anterior falx and underwent a bilateral frontal craniotomy for resection in December 2016. Her disease continued to progress with multifocal disease identified in January 2018 at which time she was referred to neuro-oncology. She passed away in March 2019.

Discussion

In this report, we present three cases of anterior skull base ORN in a patient population with sinonasal or nasopharyngeal tumors that underwent at least one course of IMRT. For the two symptomatic patients, management of ORN was successful to either last follow-up or death through either conservative, in-office means, or surgical intervention.

Risk Factors for Skull Base ORN Development

In our three patients with anterior skull base ORN, we identified significant components of two of their three clinical histories that put them at risk for ORN development. Two patients (patients A and B) were notable for being immunocompromised and for receiving very high accumulated doses of radiation (~140 Gys) to the anterior skull base. High doses of XRT and reirradiation have previously been found to increase the risk of ORN development, indicating that perhaps newer technologies such as IMRT do not seem to change XRT-related risk factors.^{1,4,6} The value of reirradiation must be considered in light of it being a major risk factor for ORN and disease control after salvage radiation is variable as seen in our cohort.^{17,18} Interestingly, for one of our identified ORN patients, we could find no evidence of any known risk factors for ORN development. This patient had an unremarkable past medical history, was immunocompetent, and had only 60.0 Gy of radiation. This patient reinforces that ORN can occur in those without immunosuppression, high accumulated doses, or reirradiation. These results emphasize the importance of discussing ORN as a potential treatment-related complication during initial patient evaluations for XRT and then again during evaluations for salvage XRT. Further investigation with a larger cohort of skull base ORN patients may expose additional risk factors.

Skull Base ORN Treatment and Prevention

Skull base ORN can be treated successfully with either conservative therapy or with surgery as seen in our skull base ORN cohort. Both of our symptomatic patients were first treated with medical management consisting of antibiotics and nasal irrigation. In one patient, this approach plus cauterization resulted in disease control while the other needed surgical debridement followed by a local flap along with intravenous

antibiotics to achieve adequate control. In a systematic review, Shaikh et al analyzed the different treatment options for skull base ORN, finding that 82.6% of patients underwent medical treatment first.¹⁴ Medical treatment options consist of antibiotics, HBO therapy, and pentoxifylline with tocopherol. There is mixed evidence on the effectiveness of HBO therapy, while pentoxifylline with tocopherol has shown promising results for refractory ORN.^{11,12,19,20} Patients who failed medical management proceeded to surgical management where Shaikh et al found that debridement with free flap reconstruction is significantly superior to endoscopic debridement alone or endoscopic debridement with a local flap.¹⁴ Additional studies also endorse the use of microvascular free flap reconstruction in extensive ORN.^{2,10,21–23}

While effective treatments have been identified, given the pain, effect on quality of life, and potential sequelae, prevention and early recognition of skull base ORN is critical. Skull base ORN risk can be lowered by maintaining hygiene of the sinuses and nasopharynx post-XRT, smoking cessation, and other lifestyle modifications.¹⁶ The skull base surgeon's role in prevention is also key given that it is imperative to conduct routine debridement of the nasopharynx postoperatively to reduce risk. Radiation oncologists are also instrumental in helping identify early-stage ORN as they may be the first to identify symptoms that describe the condition such as foul odor.

Conclusion

Given the impact of skull base ORN, it remains important to address this treatment-related complication during the counseling of all patients considering XRT. Skull base ORN can be successfully managed in the short term through either medical or surgical interventions. Preventative measures, including smoking cessation and sinonasal hygiene, as well as recognition and early treatment of ORN, are beneficial for patients receiving radiation for sinonasal and nasopharyngeal malignancies.

Presentation

This study was presented at the AAO-HNSF 2022 Annual Meeting and OTO Experience, Philadelphia, Pennsylvania, September 10–14, 2022.

Conflict of Interest

None declared.

References

- Leonetti JP, Weishaar JR, Gannon D, Harmon GA, Block A, Anderson DE. Osteoradionecrosis of the skull base. *J Neurooncol* 2020; 150(03):477–482
- Habib A, Hanasono MM, DeMonte F, et al. Surgical management of skull base osteoradionecrosis in the cancer population – treatment outcomes and predictors of recurrence: a case series. *Oper Neurosurg (Hagerstown)* 2020; 19(04):364–374
- Frankart AJ, Frankart MJ, Cervenka B, Tang AL, Krishnan DG, Takiar V. Osteoradionecrosis: exposing the evidence not the bone. *Int J Radiat Oncol Biol Phys* 2021; 109(05):1206–1218
- Owosho AA, Tsai CJ, Lee RS, et al. The prevalence and risk factors associated with osteoradionecrosis of the jaw in oral and oropharyngeal cancer patients treated with intensity-modulated radiation therapy (IMRT): the Memorial Sloan Kettering Cancer Center experience. *Oral Oncol* 2017; 64:44–51
- Morrissey D, Grigg R. Incidence of osteoradionecrosis of the temporal bone. *ANZ J Surg* 2011; 81(12):876–879
- Han P, Wang X, Liang F, et al. Osteoradionecrosis of the skull base in nasopharyngeal carcinoma: incidence and risk factors. *Int J Radiat Oncol Biol Phys* 2018; 102(03):552–555
- Leonetti JP, Marzo SJ, Zender CA, Porter RG, Melian E. Temporal bone osteoradionecrosis after surgery and radiotherapy for malignant parotid tumors. *Otol Neurotol* 2010; 31(04):656–659
- Marx RE. A new concept of its pathophysiology. *Growth (Lake-land)* 1983; 41(05):283–288
- Adel M, Chang KP. Using a nasoseptal flap for the reconstruction of osteoradionecrosis in nasopharyngeal carcinoma: a case report. *J Otolaryngol Head Neck Surg* 2016; 45(01):27
- Chapchay K, Weinberger J, Eliashar R, Adler N. Anterior skull base reconstruction following ablative surgery for osteoradionecrosis: case report and review of literature. *Ann Otol Rhinol Laryngol* 2019; 128(12):1134–1140
- Annane D, Depondt J, Aubert P, et al. Hyperbaric oxygen therapy for radionecrosis of the jaw: a randomized, placebo-controlled, double-blind trial from the ORN96 study group. *J Clin Oncol* 2004; 22(24):4893–4900
- Vudiniabola S, Pirone C, Williamson J, Goss AN. Hyperbaric oxygen in the therapeutic management of osteoradionecrosis of the facial bones. *Int J Oral Maxillofac Surg* 2000; 29(06):435–438
- Lovin BD, Hernandez M, Elms H, et al. Temporal bone osteoradionecrosis: an 18-year, single-institution experience. *Laryngoscope* 2021; 131(11):2578–2585
- Shaikh N, Makary CA, Ryan L, Reyes C. Treatment outcomes for osteoradionecrosis of the central skull base: a systematic review. *J Neurol Surg B Skull Base* 2021; 83(Suppl 2):e521–e529
- Spillinger A, Park K, Shenouda K, Folbe AJ. Endoscopic management of postradiation skull base osteoradionecrosis. *Int Forum Allergy Rhinol* 2020; 10(12):1329–1333
- Huang XM, Zheng YQ, Zhang XM, et al. Diagnosis and management of skull base osteoradionecrosis after radiotherapy for nasopharyngeal carcinoma. *Laryngoscope* 2006; 116(09):1626–1631
- Agas RAF, Yu KKL, Sogono PGM, et al. Reirradiation for recurrent nasopharyngeal carcinomas: experience from an academic tertiary center in a low- to middle-income country. *J Glob Oncol* 2019; 5(05):1–14
- Kacorzyc U, Rutkowski TW. The role of salvage in the management of patients with sinonasal squamous cell carcinoma. *Bio-medicines* 2022; 10(06):1266
- Niezgoda JA, Serena TE, Carter MJ. Outcomes of radiation injuries using hyperbaric oxygen therapy: an observational cohort study. *Adv Skin Wound Care* 2016; 29(01):12–19
- Delanian S, Chatel C, Porcher R, Depondt J, Lefaix JL. Complete restoration of refractory mandibular osteoradionecrosis by prolonged treatment with a pentoxifylline-tocopherol-clodronate combination (PENTOCLO): a phase II trial. *Int J Radiat Oncol Biol Phys* 2011; 80(03):832–839
- Hao S-P, Chen HC, Wei F-C, Chen C-Y, Yeh AR-M, Su J-L. Systematic management of osteoradionecrosis in the head and neck. *Laryngoscope* 1999; 109(08):1324–1327, discussion 1327–1328
- Baumann DP, Yu P, Hanasono MM, Skoracki RJ. Free flap reconstruction of osteoradionecrosis of the mandible: a 10-year review and defect classification. *Head Neck* 2011; 33(06):800–807
- Chang DW, Oh HK, Robb GL, Miller MJ. Management of advanced mandibular osteoradionecrosis with free flap reconstruction. *Head Neck* 2001; 23(10):830–835