

UC Davis

UC Davis Previously Published Works

Title

Noncirrhotic Portal Hypertension Secondary to Nodular Regenerative Hyperplasia Postrenal Transplant.

Permalink

<https://escholarship.org/uc/item/20t77060>

Journal

ACG Case Reports Journal, 6(12)

ISSN

2326-3253

Authors

Piao, Cindy

Koul, Abhinav

Gui, Dorina

et al.

Publication Date

2019-12-01

DOI

10.14309/crj.0000000000000257

Peer reviewed

Noncirrhotic Portal Hypertension Secondary to Nodular Regenerative Hyperplasia Postrenal Transplant

Cindy Piao, MD¹, Abhinav Koul, MD^{1,2}, Dorina Gui, MD³, Ling-xin Chen, MD⁴, and Souvik Sarkar, MD^{1,2}

¹Department of Internal Medicine, Sacramento, CA

²Division of Gastroenterology and Hepatology, Sacramento, CA

³Department of Pathology, Sacramento, CA

⁴Transplant Nephrology, University of California Davis, Sacramento, CA

ABSTRACT

Noncirrhotic portal hypertension (NCPH) is a well-known clinical entity, but often underdiagnosed. One of the common causes of NCPH is nodular regenerative hyperplasia (NRH) that presents as nodularity with features of portal hypertension and thus often diagnosed as cirrhosis. Although NRH has no histologic fibrosis, the liver synthetic function remains intact; thus, clinical diagnosis is essential because management may differ from cirrhosis. We were asked to consult in this series of 4 patients who had new-onset ascites after kidney transplantation and were diagnosed with NCPH from NRH.

INTRODUCTION

Nodular regenerative hyperplasia (NRH) is one of the causes of noncirrhotic portal hypertension (NCPH) characterized by hepatic regenerative nodules with the absence of fibrotic tissue.^{1,2} In previous autopsy studies, the incidence of NRH ranged between 0.72% and 2.6%.^{3,4} NRH appears to be adaptive hyperplasia of the hepatocytes in response to physiological or mechanical damage.⁵ Histologically, NRH is comprised of small nodules due to hepatocyte hypertrophy adjacent to atrophic, thin hepatocytes.⁵ Unlike cirrhosis, there are no areas of fibrosis seen between nodules. Patients with NRH are often asymptomatic, although they can present with clinical symptoms of portal hypertension such as hepatosplenomegaly, gastric variceal bleeding, and ascites.¹ By contrast, liver nodules from focal nodular hyperplasia are benign hepatic tumors that often do not have any clinical significance.⁶ Histologically, focal nodular hyperplasia nodules are found to have malformed vessels and proliferation of small bile ducts.⁶ Immunosuppressive medications such as azathioprine have been associated with the development of NCPH in patients after kidney transplantation (KT) because of damage to the endothelial cells of hepatic veins.⁷ We present a series of 4 patients who developed NCPH due to NRH after KT, even without exposure to azathioprine.

CASE REPORT

Four male patients whose ages range from 34 to 69 years with stage V chronic kidney disease of varying etiologies developed new-onset ascites between 3 months and 4 years after undergoing KT. One patient received a kidney from an unrelated living donor. All 4 patients were initially started on tacrolimus and mycophenolate for immune suppression after KT, although one patient developed chronic diarrhea from mycophenolate and was switched to azathioprine. Peritoneal fluid analysis in all patients was notable for a serum-ascites albumin gradient >1.1 consistent with portal hypertensive ascites. Workup for intrinsic liver disease including autoimmune, infiltrative, and infectious causes was unremarkable. Patients did not have any cardiac dysfunction. Abdominal imaging showed evidence of splenomegaly in all patients, with perisplenic varices and a recanalized periumbilical vein seen in one patient. Before KT, the 4 patients did not have imaging that assessed previous liver morphology or vascular abnormalities. Three patients had an elevated hepatic venous pressure gradient ranging from 13 to 17 mm Hg, and one patient had an hepatic venous pressure gradient of 8 mm Hg. Liver biopsies were notable for areas of nodular regeneration bounded by narrowed hepatocellular plates associated with pericentral sinusoidal dilatation. Perisinusoidal and portal fibrosis were noted; however, there were no fibrous septa around the nodules (Figure 1).

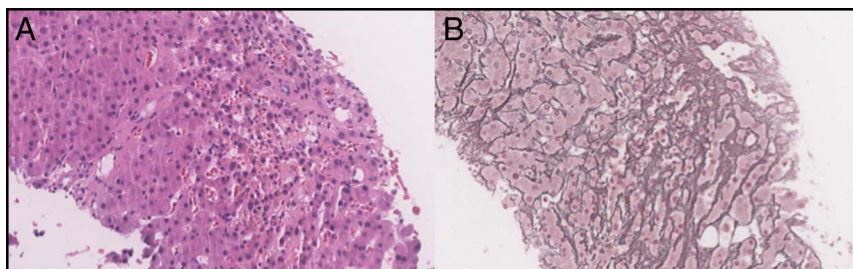


Figure 1. (A) Liver biopsy of patient B showing widened hepatocellular plates alternating with atrophic, narrowed hepatocellular plates associated with pericentral sinusoidal dilatation (hematoxylin & eosin stain) and (B) the condensed reticulin network in the internodular parenchyma (reticulin stain).

All 4 patients were diagnosed with NCPH secondary to NRH. Patient A was initially managed with diuretics; however, he developed refractory ascites requiring frequent therapeutic paracentesis. He ultimately underwent transjugular intrahepatic portosystemic shunt (TIPS) placement with near resolution of ascites without further need for paracentesis. However, his kidney transplant failed because of tubular necrosis in the setting of the recurrent ascites. Patient B also underwent intermittent therapeutic paracentesis for management of his ascites. He stabilized on a diuretic regimen and continues to be managed conservatively. Patient C discontinued his azathioprine; however, he continued to have multiple hospitalizations for volume overload. He underwent the TIPS procedure that controlled his ascites. However, he died because of unclear etiology at home. Patient D also has ascites refractory to diuretics and is currently undergoing evaluation for TIPS placement. Patients B and D have preserved kidney graft function 33 and 11 months after KT; their immunosuppressants have not been changed throughout the course of their liver disease.

DISCUSSION

NRH has been associated with exposure to immunosuppressants, chemotherapy, and antiviral drugs.⁷⁻⁹ There have been documented cases of NCPH developing after KT, almost exclusively in the setting of chronic azathioprine use. In some of those cases, cessation of azathioprine led to improvement and sometimes reversal of NCPH.¹⁰ Development of NRH has also been described after liver transplantation, often times without azathioprine exposure.¹¹ Our case series describes the development of NCPH secondary to NRH in 4 patients who underwent KT, 3 of whom did not have exposure to azathioprine. This suggests an alternate pathophysiology responsible for the development of NRH in this patient population, which has been noted before, but the cause remains unclear.¹² There have not been any reported cases of development of NRH in association with tacrolimus or mycophenolate, which were the immunosuppressants that were used in these 4 patients. Of note, all the patients described were male, liver synthetic function was preserved, and all patients had functioning allograft at first diagnosis of ascites. All the cases described were

initially managed with diuretics and therapeutic paracentesis. However, 3 patients needed TIPS.

To summarize, NRH causing NCPH is an essential clinical entity that needs to be considered in post-KT patients presenting with portal hypertension regardless of choice of immunosuppressive therapy. Although NCPH may be successfully managed with diuretics or portal decompression, it carries significant patient morbidity. Diagnosis may be delayed and wrongly interpreted as cirrhosis, where management can differ. Our case demonstrates that clinicians must maintain a high level of suspicion for NCPH and NRH in noncirrhotic patients with new-onset ascites after renal transplantation.

Further work remains to elucidate the potential causes and risk factors for the occurrence of NCPH in patients after KT.

DISCLOSURES

Author contributions: C. Piao and A. Koul wrote the manuscript. D. Gui, L-x Chen, and S. Sarkar revised the manuscript. S. Sarkar is the article guarantor.

Financial disclosure: None to report.

Informed consent was obtained for this case report.

Received February 8, 2019; Accepted September 20, 2019

REFERENCES

1. Sarin SK, Khanna R. Non-cirrhotic portal hypertension. *Clin Liver Dis*. 2014;18(2):451-76
2. Reshamwala PA, Kleiner DE, Heller T. Nodular regenerative hyperplasia: Not all nodules are created equal. *Hepatology*. 2006;44(1):7-14
3. Wanless IR. Micronodular transformation (nodular regenerative hyperplasia) of the liver: A report of 64 cases among 2,500 autopsies and a new classification of benign hepatocellular nodules. *Hepatology*. 1990;11(5):787-97.
4. Nakanuma Y. Nodular regenerative hyperplasia of the liver: Retrospective survey in autopsy series. *J Clin Gastroenterol*. 1990;12(4):460-5.
5. Hartleb M, Gutkowski K, Milkiewicz P. Nodular regenerative hyperplasia: Evolving concepts on underdiagnosed cause of portal hypertension. *World J Gastroenterol*. 2011;17(11):1400-9
6. Maillette de Buy Wenniger L, Terpstra V, Beuers U. Focal nodular hyperplasia and hepatic adenoma: Epidemiology and pathology. *Dig Surg*. 2010;27(1):24-31
7. Ghabril M, Vuppalanchi R. Drug-induced nodular regenerative hyperplasia. *Semin Liver Dis*. 2014;34(02):240-5

8. Vernier-Massouille G, Cosnes J, Lemann M, et al. Nodular regenerative hyperplasia in patients with inflammatory bowel disease treated with azathioprine. *Gut*. 2007;56(10):1404–9
9. Cotte L, Bénet T, Billioud C, et al. The role of nucleoside and nucleotide analogues in nodular regenerative hyperplasia in HIV-infected patients: A case control study. *J Hepatol*. 2011;54(3):489–96
10. Adler M, Delhay M, Deprez C, et al. Hepatic vascular disease after kidney transplantation: Report of two cases and review of the literature. *Nephrol Dial Transpl*. 1987;2(3):183–8.
11. Devarbhavi H, Abraham S, Kamath PS. Significance of nodular regenerative hyperplasia occurring de novo following liver transplantation. *Liver Transpl*. 2007;13(11):1552–6
12. Gerlag PG, Lobatto S, Driessen WM, et al. Hepatic sinusoidal dilatation with portal hypertension during azathioprine treatment after kidney transplantation. *J Hepatol*. 1985;1(4):339–48.

Copyright: © 2019 The Author(s). Published by Wolters Kluwer Health, Inc. on behalf of The American College of Gastroenterology. This is an open-access article distributed under the terms of the Creative Commons Attribution-Non Commercial-No Derivatives License 4.0 (CCBY-NC-ND), where it is permissible to download and share the work provided it is properly cited. The work cannot be changed in any way or used commercially without permission from the journal.