

UC Davis

Dermatology Online Journal

Title

Alopecia universalis unresponsive to treatment with tofacinitib: report of a case with a brief review of the literature

Permalink

<https://escholarship.org/uc/item/224878kb>

Journal

Dermatology Online Journal, 23(7)

Authors

Salman, Andac
Sarac, Gonca
Ergun, Tulin

Publication Date

2017

DOI

10.5070/D3237035753

Copyright Information

Copyright 2017 by the author(s). This work is made available under the terms of a Creative Commons Attribution-NonCommercial-NoDerivatives License, available at <https://creativecommons.org/licenses/by-nc-nd/4.0/>

Peer reviewed

Alopecia universalis unresponsive to treatment with tofacitinib: report of a case with a brief review of the literature

Andac Salman MD, Gonca Sarac MD, Tulin Ergun MD

Affiliations: Marmara University School of Medicine, Department of Dermatology, Istanbul, Turkey

Corresponding author: Andac Salman, MD; Marmara Universitesi Pendik Egitim ve Arastirma Hastanesi Dermatoloji Anabilim Dali Fevzi Cakmak Mah, Mimar Sinan Cad. No: 10 34899 Pendik, Istanbul, Turkey, Tel: 90 216 657 06 06 extension: 4649; Fax: 90 216 597 00 52; E-mail: asalmanitf@gmail.com, andac.salman@marmara.edu.tr

Abstract

Janus kinase inhibitors are emerging treatment alternatives in various immune-mediated diseases including alopecia universalis. Herein, we report a patient with psoriasis and alopecia universalis in whom treatment with tofacitinib led to remission of psoriasis without improvement in alopecia universalis. Despite the promising potential in alopecia areata treatment, research evaluating the efficacy of different Janus kinase inhibitors and possible prognostic factors related with a more favorable response are warranted.

Keywords: alopecia areata, Janus kinase inhibitors, psoriasis, tofacitinib

Case Synopsis

A 25-year-old man presented with exacerbation of psoriasis for 3 months. His medical history revealed generalized plaque psoriasis for 9 years, previously treated with acitretin and showing partial response. He also had a long-standing alopecia universalis (AU) causing psychosocial impairment. Since topical agents including potent corticosteroids and minoxidil failed to provide any benefit he was wearing a cranial hair prosthetic. Dermatological examination revealed erythematous, scaly, infiltrated plaques on the extremities, upper back, and scalp with a psoriasis area and severity index (PASI) score of 6.5. In addition, there was total loss of body and scalp hair without any growth of vellus hair (**Figure 1a–d**). In view of the recent reports regarding efficacious use of Janus kinase (JAK) inhibitors in AU and psoriasis, off-label treatment with oral tofacitinib (5 mg twice daily) was

commenced following informed consent. By the first month of treatment, despite almost total clearance of psoriasis, there was no hair regrowth. Treatment was continued for a further two months without any improvement in AU and terminated at the end of three months with near complete clearance of psoriasis (**Figure 1e–h**).

Case Discussion

Alopecia areata (AA) is a chronic, autoimmune disease characterized by nonscarring alopecia. Alopecia universalis is a severe variant of AA showing total loss of body and scalp hair. Although not fully elucidated yet, pathogenesis of AA encompasses immune mediated inflammation, genetic predisposition, and environmental factors [1]. In a recent study, Xing et al. have demonstrated that AA is mediated by IFN-gamma releasing CD8+NKG2D+ T cells. IFN-gamma acts through JAK1 and JAK2 to produce IL-15, which further induces CD8+ T cells and boosts IFN-gamma production via JAK1 and JAK3. Based upon these findings, they successfully treated 3 patients with AA using ruxolitinib, an oral JAK1/2 inhibitor [2].

In addition to three patients reported by Xing et al. [2], review of the literature revealed at least 11 patients with AA treated with a JAK inhibitor [tofacitinib (n=8), ruxolitinib (n=5) and baricitinib (n=1)], [3-10]. Twelve of 14 patients have experienced significant hair regrowth after a period ranging from 2 to 10 months. However, in one patient with AU, despite the improvement in AU-associated nail dystrophy, no hair regrowth was seen with tofacitinib [4]. In another patient, there was only a transient hair regrowth despite the ongoing tofacitinib treatment

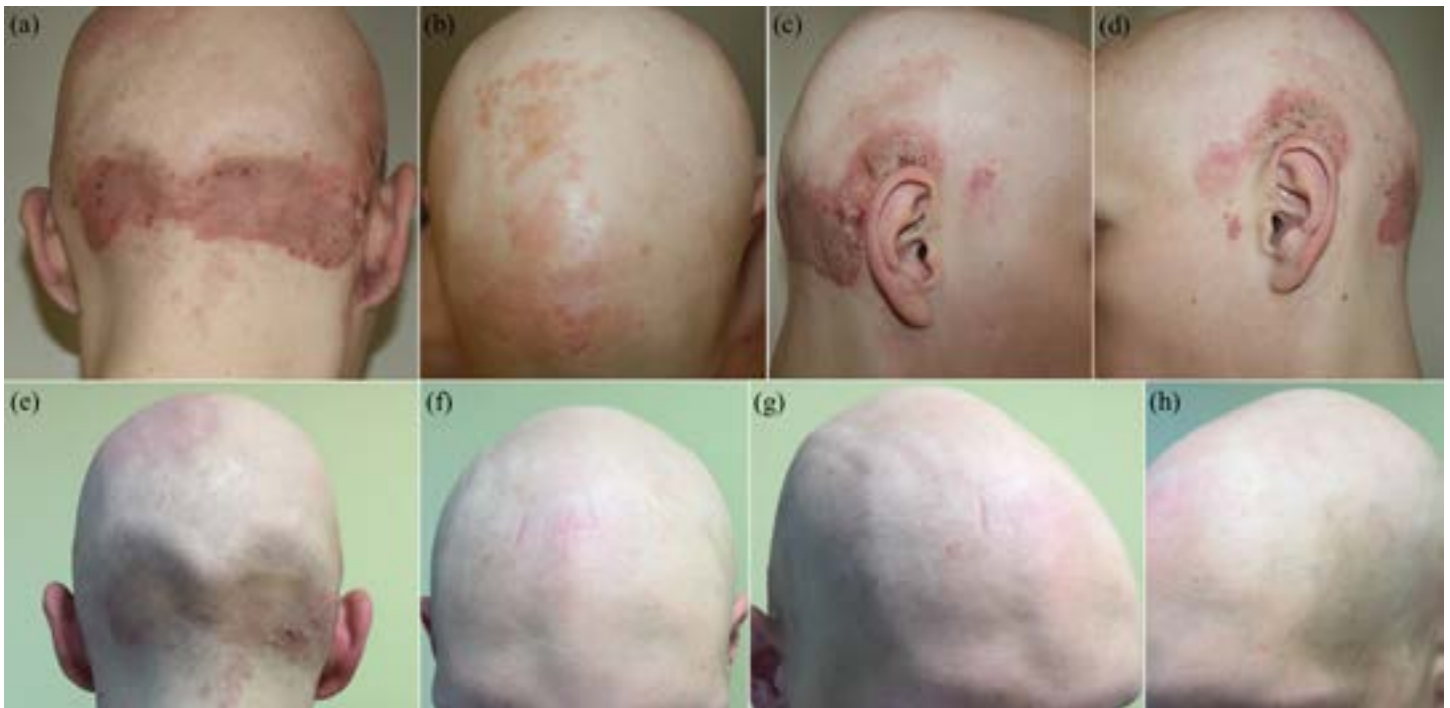


Figure 1. Erythematous, scaly plaques on the scalp with total absence of scalp hair (a–d). Following three months of treatment, almost complete clearance of psoriatic lesions and no re-growth of hair were noted (e–h).

[7]. In responders, significant hair growth occurs within three months of treatment. Unfortunately, in our case there was no improvement following 3 months of treatment.

In 8 patients treated with tofacitinib, the initial dose was 5 mg twice daily, as in our patient [3-7]. In contrast to our case, 6 patients showed at least partial improvement, whereas two patients did not respond. Hence, we believe that dose and duration of treatment in our patient was sufficient to determine efficacy. Clearance of psoriasis lesions with tofacitinib demonstrates the efficacy of JAK1/3 inhibition. Considering the unfavorable response to tofacitinib in two patients including ours, one may speculate JAK1/2 inhibition via ruxolitinib and baricitinib to be potentially more effective than JAK1/3 inhibition with tofacitinib in AA.

Conclusion

In conclusion JAK inhibition may not be effective in every patient with AA. Despite their great potential in AA treatment, further studies focusing on the efficacy of different JAK inhibitors and patient characteristics related to a good response are needed.

References

1. Alkhalifah A, Alsantali A, Wang E, McElwee KJ, Shapiro J. Alopecia areata update. Part I. Clinical picture, histopathology, and pathogenesis. *J Am Acad Dermatol.* 2010;62(2):177-188. [PMID: 115945].
2. Xing L, Dai Z, Jabbari A, Cerise JE, Higgins CA, Gong W, de Jong A, Harel S, DeStefano GM, Rothman L, Singh P, Petukhova L, Mackay-Wiggan J, Christiano AM, Clynes R. Alopecia areata is driven by cytotoxic T lymphocytes and is reversed by JAK inhibition. *Nat Med.* 2014;20(9):1043-1049. [PMID: 25129481].
3. Craiglow BG, King BA. Killing Two Birds with one stone: oral tofacitinib reverses alopecia universalis in a patient with plaque psoriasis. *J Invest Dermatol.* 2014;134(12):2988-2990. [PMID: 24940651].
4. Dhayalan A, King BA. Tofacitinib Citrate for the Treatment of Nail Dystrophy Associated With Alopecia Universalis. *JAMA Dermatol.* 2016;152(4):492-493. [PMID: 26630079].
5. Jabbari A, Nguyen N, Cerise JE, Ulerio G, de Jong A, Clynes R, Christiano AM, Mackay-Wiggan J. Treatment of an alopecia areata patient with tofacitinib results in regrowth of hair and changes in serum and skin biomarkers. *Exp Dermatol.* 2016;25(8):642-643. [PMID: 27119625].
6. Gupta AK, Carviel JL, Abramovits W. Efficacy of tofacitinib in treatment of alopecia universalis in two patients. *J Eur Acad Dermatol Venereol.* 2016;30(8):1373-1378. [PMID: 27306107].
7. Anzengruber F, Maul JT, Kamarachev J, Trüeb RM, French LE, Navarini AA. Transient Efficacy of Tofacitinib in Alopecia Areata Universalis. *Case Rep Dermatol.* 2016;8(1):102-106. [PMID: 27194979].
8. Harris JE, Rashighi M, Nguyen N, Jabbari A, Ulerio G, Clynes R, Christiano AM, Mackay-Wiggan J. Rapid skin repigmentation on oral ruxolitinib in a patient with coexistent vitiligo and alopecia areata (AA). *J Am Acad Dermatol.* 2016;74(2):370-371. [PMID: 26685721].
9. Jabbari A, Dai Z, Xing L, Cerise JE, Ramon Y, Berkun Y, Sanchez GA, Goldbach-Mansky R, Christiano AM, Clynes R, Zlotogorski A.

Reversal of Alopecia Areata Following Treatment With the JAK1/2 Inhibitor Baricitinib. *EBioMedicine*. 2015;2(4):351-355. [PMID: 26137574].

10. Pieri L, Guglielmelli P, Vannucchi AM. Ruxolitinib-induced reversal of alopecia universalis in a patient with essential thrombocythemia. *Am J Hematol*. 2015;90(1):82-83. [PMID: 25307179].