

UCLA

UCLA Previously Published Works

Title

Primary osteosarcoma of the thyroid gland.

Permalink

<https://escholarship.org/uc/item/22b4c1bn>

Journal

Journal of Nuclear Medicine, 33(7)

ISSN

0161-5505

Authors

Nitzsche, EU
Seeger, LL
Klosa, B
[et al.](#)

Publication Date

1992-07-01

Peer reviewed

Primary Osteosarcoma of the Thyroid Gland

Egbert U. Nitzsche, Leanne L. Seeger, Barbara Klosa, Nikolaus Freudenberg, and Ernst A. Moser

Division of Nuclear Medicine and Biophysics, Division of Musculoskeletal Radiology, Department of Radiological Science, UCLA School of Medicine, Los Angeles, California and Departments of Nuclear Medicine and Pathology, Albert-Ludwigs-University, School of Medicine, Freiburg, Germany

Primary extrasosseous osteosarcoma of the thyroid gland is a rare tumor which is associated with a poor prognosis. In this report, we discuss such a tumor and its recurrence in a 78-yr-old female with multinodular goiter, focusing on the imaging evaluation of this unusual tumor.

J Nucl Med 1992; 33:1399-1401

Osteosarcoma is a relatively common primary bone malignancy, second only to myeloma.

Extraskeletal primary osteosarcomas are rare and have been described in breast, thyroid gland, abdominal viscera and soft tissues (1). One percent of thyroid tumors are reported to be sarcomas (2), including fibrosarcoma, hemangio sarcoma, osteosarcoma and osteochondrosarcoma (3-25).

The clinical presentation of thyroid sarcomas (hoarseness, cough, loss of weight and shortness of breath caused by trachea compression), pathological findings and theories on histogenesis have been discussed in these previous papers, but there is little information regarding the role of imaging. The aim of this report is to discuss radiological findings that can assist in the diagnosis of these tumors.

CASE REPORT

A 78-yr-old woman diagnosed with multinodular goiter 30 yr previously presented with a 10 mo history of increasing fullness in the right neck region. When the fullness was first noted, she experienced pressure in her lower neck, but no pain or difficulty swallowing. Progressive swelling was associated with increased pressure, pain on palpation of the mass and dysphagia.

Physical examination at the time of presentation revealed an 8 cm diameter hard mass in the right lower neck which was tender to palpation. The mass was nonmobile, even during swallowing.

Realtime ultrasound showed a well defined inhomogeneous mass which contained extensive calcification. Thyroid gland scintigraphy with [^{99m}Tc]pertechnetate revealed a focal area of photopenia in the right thyroid gland. Laboratory evaluation including complete blood count, erythrocyte sedimentation rate, T₃, T₄, thyroglobulin and alkaline phosphatase were normal.

Needle biopsy was not deemed appropriate because of the extensive calcification, and excision was recommended. A malignant osteoid was found at frozen section, and the patient underwent total thyroidectomy. Final pathology confirmed the diagnosis of osteosarcoma. A postoperative thyroid scintigram showed no residual thyroid tissue, and thyroid replacement therapy was begun.

At follow-up 3 mo later, a hard mass measuring 3 cm was noted in the surgical bed. The patient again complained of low neck pressure and difficulty in swallowing. Laboratory investigations were again within normal range. The ultrasound appearance of the recurrent mass was similar to that of the initial tumor (Fig. 1). Bone scintigraphy using ^{99m}Tc-2,3-dicarboxypropane-1,1-diphosphonate (DPD) showed an intensive uptake of radiotracer in the mass (Fig. 2), but skeletal uptake was normal. CT of the neck and upper thorax revealed an ossified mass which slightly deviated the trachea to the left (Fig. 3). The tumor was separate from the major neck vessels, and there was no infiltration into ribs or spine. A second resection was undertaken, which confirmed the clinical diagnosis of recurrent osteosarcoma of the thyroid gland.

Within 12 mo after first diagnosis of the thyroid gland osteosarcoma, lung metastatic disease developed.

DISCUSSION

Primary extrasosseous osteosarcoma of the thyroid gland is rare, and the infrequency of this lesion is one reason for the difficulty in diagnosis. Clinical symptoms and physical findings are often ambiguous, and the rate of growth is variable. Diagnosis is often delayed until the lesion is quite large.

By combining the current case with 33 previously reported cases of osteosarcoma (n = 21), chondrosarcoma (n = 2) and carcinoosteosarcoma (n = 10) of the thyroid gland, epidemiologic data for primary sarcoma of the thyroid reveals a mean age of 62 yr, ranging from 21 to 97 yr. The female-to-male sex ratio is 1.5:1. Seventeen (50%) of the 34 cases had a long history of a goiter. In the remaining 17 cases, there was either no history of goiter or this information was not included in the report. Thirty-two patients died within 12 mo of diagnosis, primarily as a result of local extension or tumor recurrence. Metastases were noted in 19 cases, most commonly in the lungs (17 cases). In contrast to the thyroid carcinoma in which bony metastatic disease is common, bone metastases were described in two cases (15). Lymph node metastases occurred in four cases (6,15,21). Rare metastases to liver, pancreas,

Received Dec. 16, 1991; revision accepted Feb. 20, 1992.
For reprints contact: Egbert U. Nitzsche, MD, Division of Nuclear Medicine and Biophysics, UCLA School of Medicine, Los Angeles, CA 90024-1721.

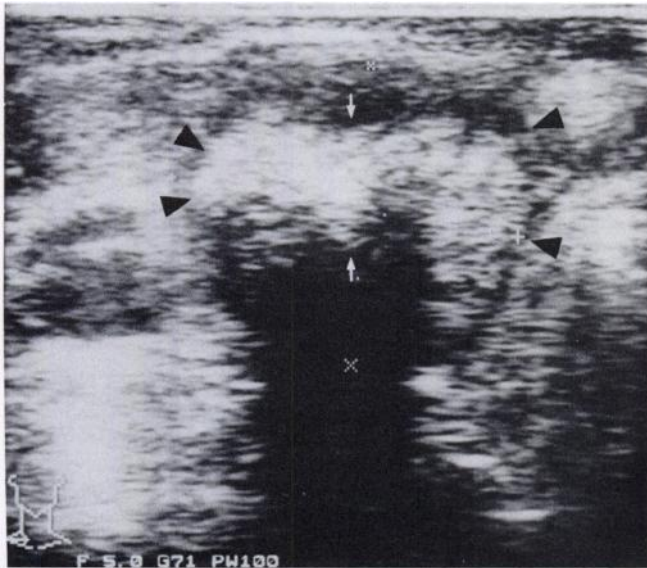


FIGURE 1. Ultrasound of the right lobe of the thyroid gland. The nodule is well demarcated (black arrows) and contains extensive compact calcifications (white arrows).

pleura, retroperitoneum, breast, skin, intestine, meninges, soft palate, stomach and heart have also been described (5,14,15,18,22).

Because of the tumor mineralization associated with primary extrasosseous osteosarcoma of the thyroid gland, the primary alternative differential diagnostic consideration is a calcified cyst. The combination of several imaging modalities will often allow differentiation of these two entities (Table 1).

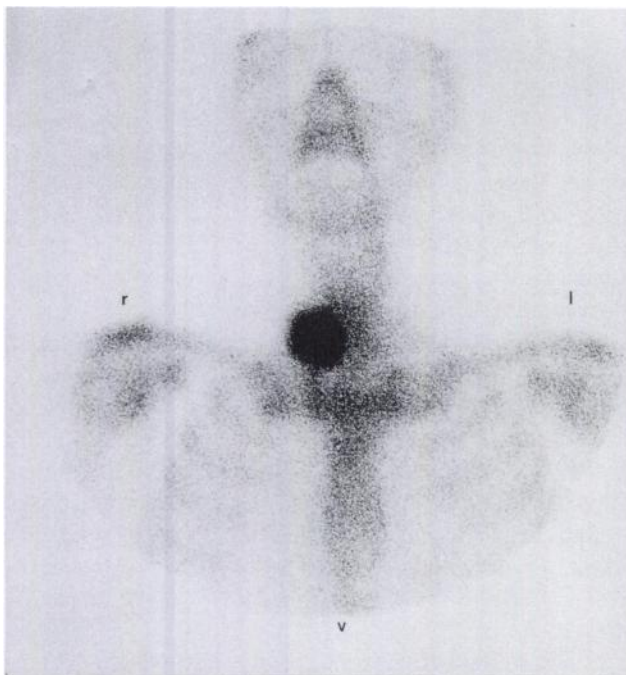

FIGURE 2. Bone scintigraphy with ^{99m}Tc -DPD. There is intense uptake of radiotracer in the mass.

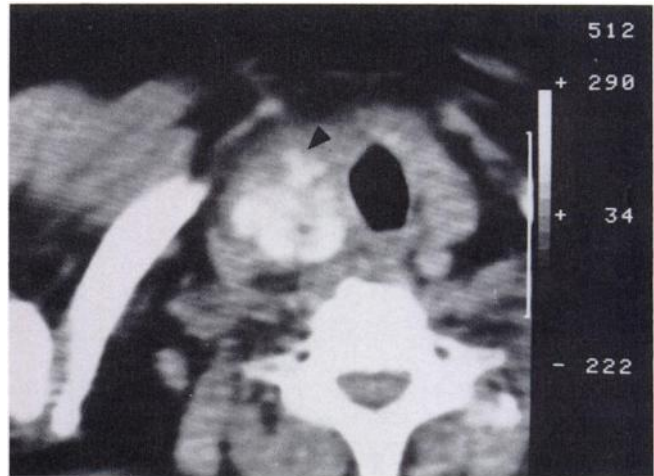

FIGURE 3. CT scan (without intravenous contrast) showing slight deviation of the trachea to the left and extensive calcification throughout the tumor.

Thyroid gland scintigraphy shows both primary extrasosseous osteosarcoma and cyst as a cold nodule. With ultrasound, the tumor is usually well margined but may show infiltration into surrounding tissues. A cyst will be well demarcated. Calcifications are easily identified in both lesions, but differentiation between the two may be possible by characterization of the echo pattern. In primary extrasosseous osteosarcoma, the tumor has a mixed echogenicity throughout, and the calcifications are compact and distributed throughout the tumor. The cyst is anechoic or hypoechoic, and the calcifications are peripheral, coarser, and more irregularly distributed. The compact pattern of calcification as seen with osteosarcoma is unusual in patients without history of a goiter.

If the diagnosis of the calcified cyst cannot be made on the appearance of the ultrasound, bone scintigraphy will allow further differentiation. Osteosarcoma will show intense uptake of the radiotracer, while the uptake in a calcified cyst will be much lower.

With CT, both primary extrasosseous osteosarcoma and cyst show focal enlargement of the gland. CT can assist in characterization of the pattern of calcification and may demonstrate the fluid nature of the cyst by measurement in Hounsfield units. Tumor infiltration into surrounding tissues may be evident with primary extrasosseous osteosarcoma, but is normally not seen with a cyst.

There are no established recommendations for treatment of primary extrasosseous osteosarcoma of the thyroid gland. Radical excision is generally undertaken, however, most patients die within months of diagnosis. The high rate of local recurrence justifies close clinical follow-up (19,26,28). The longest survivor (26) underwent excision and telecurie radiation therapy, but developed local recurrence twice, the first at 1 yr and the second at 3 yr. Eight years after initial presentation, she developed metastases in the retroperitoneum, breast and skin. These were treated

TABLE 1
Differential Diagnosis: Primary Extraosseous Osteosarcoma Versus Cyst of the Thyroid Gland

Imaging modality	Finding/Interpretation	
	Primary extraosseous osteosarcoma	Cyst
Thyroid gland scintigram	Cold nodule	Cold nodule
Bone scintigram	Hot spot	± low uptake
Ultrasound	± good demarcation	Well-demarcated
	Calcification: shadowing, compact, regular	Calcification: shadowing, shelled, irregular
CT	Focal mass	Focal mass
	± infiltration	No infiltration
	No fluid	Fluid
	Calcification: compact, regular	Calcification: shelled, irregular

by a combination of surgery and radiotherapy, but the patient died from metastatic disease 11 yr after diagnosis.

CONCLUSIONS

The differential diagnosis for a rapidly growing nodule in the thyroid gland includes primary or secondary tumor or cyst. If ultrasound and/or CT show compact, regular calcifications throughout the mass without evidence of fluid, primary extraosseous osteosarcoma of the thyroid gland should be included in the differential diagnosis. With primary extraosseous osteosarcoma of the thyroid gland, the bone scintigram will greatly assist in the diagnosis by demonstrating marked increased uptake of tracer due to the malignant bone formation associated with this tumor.

REFERENCES

1. Wilson H. Extraskelatal ossifying tumors. *Ann Surg* 1941;113:95-112.
2. Warren S, Meissner WA. Tumors of the thyroid gland. In: *Atlas of tumor pathology*. Washington: Armed Forces Institute of Pathology; 1969:123.
3. Foerster W. Ueber die Geschwulste der Schilddruese. *Wuerzb Med Ztschr* 1860;24-36.
4. Pick F. Zur Kenntnis der malignen Tumoren der Schilddruese, insbesondere des Sarcoma ossificans. *Ztschr f Heilk* 1892;13:71-86.
5. Funkenstein O. Ueber Osteochondrosarkome der Thyreoidea. *Arch f Path Anat u Physiol* 1903;171:34-79.
6. Saltykow S. Ueber das gleichzeitige Vorkommen des Sarkoms und des Carcinomas in der Schilddruese. *Zentralbl Allg Pathol* 1905;12:561-570.
7. Chavannaz G, Nadal P. Tumeur mixte maligne du corps thyroide. *J Med Bordeaux* 1910;11:817-820.
8. Solaro G. Osteosarcoma della ghiandola tiroide. *Clin Chir* 1913;21:1101-1116.
9. Zeckwer IT. Fibrosarcoma of the thyroid. *Arch Surg* 1926;12:561-570.

10. Arons I. Sarcoma of the thyroid gland. *Ann Surg* 1930;91:44-56.
11. Nimpfer H. Ein Ungewoehnlicher Schilddruesentumor. *Zentralbl Allg Pathol* 1931;53:137.
12. Broders AC, Pemberton JJ. Primary osteogenic sarcoma of the thyroid gland. *Surg Gynecol Obst* 1934;58:100-102.
13. Umeda K. Zwei seltene maligne Geschwulste der Schilddruese. *Virchows Arch Zellpathol* 1938;302:458.
14. Batts M. Osteogenic sarcoma of the thyroid gland. *Am J Surg* 1940;49:390-392.
15. Kirchmair W. Das knochenbildende Sarkom der Schilddruese. *Zentralbl Allg Pathol* 1952;88:188-191.
16. Pinston M. Le sarcome squelettogene du corps thyroide. M.D. thesis no. 29, Lyon France, 1958.
17. Dargent M, Cabanne F, Leclerc F. A propos d'une observation de sarcome osseux squelettogene du corps thyroide. *Mem Acad Chir Paris* 1958;84:1030.
18. Cabanne F, Dargent M, Leclerc F, Pinston M. Le sarcome squelettogene du corps thyroide. *Revue generale. Ann Anat Pathol Paris* 1959;4:136.
19. Livingston DJ, Sandison AT. Osteogenic sarcoma of the thyroid. *Br J Surg* 1962;50:291-293.
20. Cabanne F, Piaget F, Couderc P, Michel M. Carcino-Sarcome osteogenique du corps thyroide chez une malade de 60 ans. *Arch Anat Pathol Paris* 1964;12:280-283.
21. Aream VM, Schildecker WW. Carcinosarcoma of the thyroid gland: report of two cases. *South Med J* 1965;57:446-451.
22. Lira V, Maranhao E. Malignant mixed tumor of the thyroid gland. *J Pathol* 1965;80:377-379.
23. Roberts C. Sarcomata of the thyroid gland: a report of two cases. *J Path Bact* 1968;95:537-540.
24. Hedinger CE. *Thyroid cancer*. New York: Springer Verlag; 1969:47-52.
25. Nowak K, Sznepka Z. Osteochondrosarcoma of the thyroid gland. *Patol Pol* 1971;22:381-385.
26. Trowell JE, Arkell DG. Osteosarcoma of the thyroid gland. Case report. *J Pathol* 1976;119:123-127.
27. Heitz P, Moser H, Staub JJ. Thyroid cancer: a study of 573 thyroid tumors and 161 autopsy cases observed over a 30-year period. *Cancer* 1976;37:2329-2337.
28. Donell CA, Pollock WJ, Sybers WA. Thyroid carcinosarcoma. *Arch Pathol Lab Med* 1987;111:1169-1172.