

UC Irvine

UC Irvine Previously Published Works

Title

Polymicrogyria and deletion 22q11.2 syndrome: Window to the etiology of a common cortical malformation

Permalink

<https://escholarship.org/uc/item/26b750n0>

Journal

American Journal of Medical Genetics Part A, 140A(22)

ISSN

1552-4825

Authors

Robin, Nathaniel H
Taylor, Clare J
McDonald-McGinn, Donna M
[et al.](#)

Publication Date

2006-11-15

DOI

10.1002/ajmg.a.31443

Copyright Information

This work is made available under the terms of a Creative Commons Attribution License, available at <https://creativecommons.org/licenses/by/4.0/>

Peer reviewed

Polymicrogyria and Deletion 22q11.2 Syndrome: Window to the Etiology of a Common Cortical Malformation

Nathaniel H. Robin,¹ Clare J. Taylor,² Donna M. McDonald-McGinn,³ Elaine H. Zackai,³ Peter Bingham,⁵ Kevin J. Collins,⁶ Dawn Earl,⁷ Deepak Gill,⁸ Tiziana Granata,⁹ Renzo Guerrini,¹⁰ Naomi Katz,⁶ Virginia Kimonis,¹¹ Jean-Pierre Lin,¹² David R. Lynch,⁴ Shehla N. Mohammed,¹³ Roger F. Massey,¹⁴ Marie McDonald,¹⁵ R. Curtis Rogers,¹⁶ Miranda Splitt,¹³ Cathy A. Stevens,¹⁷ Marc D. Tischkowitz,¹⁸ Neil Stoodley,¹⁹ Richard J Leventer,⁶ Daniela T. Pilz,² and William B. Dobyns^{20*}

¹Departments of Genetics and Pediatrics, University of Alabama at Birmingham, Birmingham Alabama

²Institute of Medical Genetics, University Hospital of Wales, Cardiff, United Kingdom

³Division of Human Genetics and Molecular Biology, Children's Hospital of Philadelphia, Philadelphia, Pennsylvania

⁴Division of Neurology, Children's Hospital of Philadelphia, Philadelphia, Pennsylvania

⁵Departments of Neurology and Pediatrics, University of Vermont College of Medicine, Burlington, Vermont

⁶Department of Neurology, Royal Children's Hospital, Murdoch Children's Research Institute, University of Melbourne, Melbourne, Australia

⁷Division of Medical Genetics and Developmental Medicine, Children's Hospital Regional Medical Center, Seattle, Washington

⁸T.Y. Nelson Department of Neurology, The Children's Hospital at Westmead, Westmead, Sydney, Australia

⁹Division of Child Neurology, Istituto Nazionale Neurologico "C. Besta," Milan, Italy

¹⁰Division of Child Neurology and Psychiatry, University of Pisa and IRCCS Fondazione Stella Maris, Pisa, Italy

¹¹Division of Genetics and Metabolism, Children's Hospital and Harvard Medical School, Boston, Massachusetts

¹²Department of Paediatric Neurology, Evelina Children's Hospital,

Guy's & St. Thomas' Hospitals NHS Foundation Trust, London, United Kingdom

¹³SE Thames Regional Genetics Service, Guy's Hospital, London, United Kingdom

¹⁴Department of Paediatrics, Hull Royal Infirmary, Hull, United Kingdom

¹⁵Division of Medical Genetics, Duke University Medical Center, Durham, North Carolina

¹⁶Greenwood Genetics Center, Greenwood, South Carolina

¹⁷Department of Pediatrics, Chattanooga Unit, University of Tennessee College of Medicine and T.C. Thompson Children's Hospital, Chattanooga, Tennessee

¹⁸Clinical Genetics Unit, Institute of Child Health, London, United Kingdom

¹⁹Department of Neuroradiology, Frenchay Hospital, Frenchay, Bristol, United Kingdom

²⁰Departments of Human Genetics, Neurology and Pediatrics, The University of Chicago, Chicago, Illinois, USA

Received 18 April 2006; Accepted 18 July 2006

Several brain malformations have been described in rare patients with the deletion 22q11.2 syndrome (DEL22q11) including agenesis of the corpus callosum, pachygyria or polymicrogyria (PMG), cerebellar anomalies and meningo-myelocele, with PMG reported most frequently. In view of our interest in the causes of PMG, we reviewed clinical data including brain-imaging studies on 21 patients with PMG associated with deletion 22q11.2 and another 11 from the literature. We found that the cortical malformation consists of perisylvian PMG of variable severity and frequent asymmetry with a striking predisposition for the right hemisphere ($P=0.008$). This and other observations suggest that the PMG may be a sequela of abnormal embryonic vascular

development rather than a primary brain malformation. We also noted mild cerebellar hypoplasia or mega-cisterna magna in 8 of 24 patients. Although this was not the focus of the present study, mild cerebellar anomalies are probably the most common brain malformation associated with DEL22q11. © 2006 Wiley-Liss, Inc.

Key words: cerebellar hypoplasia; chromosome 22; deletion 22q11.2; perisylvian polymicrogyria

This article contains supplementary material, which may be viewed at the American Journal of Medical Genetics website at <http://www.interscience.wiley.com/jpages/1552-4825/suppmat/index.html>.

Nathaniel H. Robin, Clare J. Taylor, Daniela T. Pilz, and William B. Dobyns contributed equally to this article.

*Correspondence to: William B. Dobyns, M.D., Department of Human Genetics, The University of Chicago, Room 319 CLSC, 920 E. 58th Street, Chicago, IL 60637. E-mail: wbd@genetics.uchicago.edu
DOI 10.1002/ajmg.a.31443

How to cite this article: Robin NH, Taylor CJ, McDonald-McGinn DM, Zackai EH, Bingham P, Collins KJ, Earl D, Gill D, Granata T, Guerrini R, Katz N, Kimonis V, Lin J-P, Lynch DR, Mohammed SN, Massey RF, McDonald M, Rogers RC, Splitt M, Stevens CA, Tischkowitz MD, Stoodley N, Leventer RJ, Pilz DT, Dobyns WB. 2006. Polymicrogyria and deletion 22q11.2 syndrome: Window to the etiology of a common cortical malformation. *Am J Med Genet Part A* 140A:2416–2425.

INTRODUCTION

Deletion 22q11.2 (DEL22q11) is among the most common microdeletion syndromes in humans, with an estimated birth prevalence of 1–2/4,000 [Shprintzen, 2004]. Several hundred papers have documented the great clinical variability that has come to characterize this disorder, with over 180 different manifestations having been reported. Abnormalities of the central nervous system (CNS) are common and prominent, including neurobehavioral and psychiatric disorders such as learning disabilities, attention deficit disorder, and depression. Although much less common, brain malformations have also been described with DEL22q11 involving every level of the CNS including agenesis of the corpus callosum [Kraynack et al., 1999], pachygyria [Ehara et al., 2003; Koolen et al., 2004], polymicrogyria (PMG) [Cramer et al., 1996], cerebellar atrophy [Lynch et al., 1995], and meningomyelocele [Nickel et al., 1994; Forrester et al., 2002]. Of these, the cortical malformation PMG has received the most attention.

While 12 patients with DEL22q11 associated with cortical malformations have now been described in case reports [Cramer et al., 1996; Bingham et al., 1998; Bird and Scambler, 2000; Worthington et al., 2000; Ghariani et al., 2002; Kawame et al., 2000; Ehara et al., 2003; Koolen et al., 2004; Sztriha et al., 2004], the type, location and severity of the cortical malformation, and the presence of associated brain malformations have not been clarified. In a recent trio of Letters to the Editor in this journal, de Wit et al. [2005] suggested that the published images in two recent papers [Ehara et al., 2003; Koolen et al., 2004] showed PMG and not pachygyria or combined pachygyria and PMG as stated. The authors' replies maintained that the malformation was in fact pachygyria, with one stating that "the final diagnosis requires neuropathological findings" [de Vries, 2005; Ehara et al., 2005]. However, many reports have shown that PMG may indeed be recognized by magnetic resonance imaging [Kuzniecky et al., 1994; Barkovich et al., 1999; Guerrini et al., 2003].

To address these questions, we analyzed clinical data on 21 patients with PMG and DEL22q11 from our subject databases, and another 11 from the literature. We found a cortical malformation consistent with perisylvian PMG—each time, every time—that was further associated with frequent asymmetry, a striking predisposition for the right hemisphere,

and often mega-cisterna magna or mild cerebellar vermis hypoplasia.

METHODS

We searched our large brain malformation research databases (D.T.P., R.G., R.J.L., and W.B.D.) and found 21 patients with PMG and DEL22q11 among more than 1,000 patients with PMG of all types. All patients were deleted for the *TUPLE1* probe by FISH, and one had additional molecular genetic studies performed. Many were ascertained after specific requests to colleagues, so that the prevalence of DEL22q11 among patients with PMG cannot be determined from these data. We also obtained additional clinical data for three previously reported patients [Bingham et al., 1998; Sztriha et al., 2004].

We reviewed clinical records, photographs and brain MRI (in 20 patients), or CT scan (in 1 patient) in these 21 patients and another 11 reported in the literature for whom adequate brain imaging figures were available (Table I and see the online Table III at <http://www.interscience.wiley.com/jpages/1552-4825/suppmat/index.html>), with attention to the well-known abnormalities associated with the DEL22q11 syndrome. PMG consists of abnormally small gyri that do not follow the normal gyral pattern, regions of deeply infolded cortex, and shallow partly fused sulci [Crome, 1952; Barth, 1987; Barkovich et al., 2001]. We identified this on MRI by looking for regional loss of the normal gyral pattern, visible microgyri, irregular brain surface and white-gray border, and mildly thick (6–10 mm) cortex [Barkovich et al., 2001]. Pachygyria (one form of lissencephaly) consists of absent or abnormally wide gyri with reduced numbers of gyri and sulci, widely open sulci, and very thick 10–20 mm cortex. We looked for these changes on MRI. The severity of the cortical malformation was assessed using a system we developed for use with perisylvian PMG [Leventer et al., 2001]. Grade 1 PMG involves the entire perisylvian region with extension to other brain regions including one or both poles. Grade 2 involves the entire perisylvian region with extension to other brain regions but not involving either pole. Grade 3 involves the entire perisylvian region, and Grade 4 involves the posterior perisylvian region only. We assessed whether the malformation was more severe in anterior versus posterior, and right versus left-brain regions by visual inspection. The results were analyzed using the Chi-square test.

TABLE I. Brain Imaging in Deletion 22q11.2 With Polymicrogyria

Patient No.	Sex	PMG grade		PMG gradient		Other	Reference
		R	L	AP	RL		
LR01-103	F	1	2	A > P	R > L		Bingham et al. [1998] (#1)
LR01-104	M	1	1	A > P	SYM		Bingham et al. [1998] (#2)
Report	F	—	—	—	L > R	—	Bird and Scambler [2000] (#1)
Report	M	1	4	A > P	R > L	—	Bird and Scambler [2000] (#2)
Report	M	2	N	A > P	R > L	—	Kawame et al. [2000]
Report	M	2	2	A > P	SYM	—	Worthington et al. [2000]
Report	M	1	N	A > P	R > L	—	Ghariani et al. [2002]
Report	M	3	4	—	R > L	—	Ehara et al. [2003]
Report	F	1	2	A > P	R > L	—	Koolen et al. [2004]
LR03-446	M	1	3	A > P	R > L	CVH	Sztriha et al. [2004] (#1)
Report	M	1	1	A = P	SYM	—	Sztriha et al. [2004] (#2)
LR02-091	M	2	2	A > P	SYM	CVH	
LR02-098	M	1	N	A > P	R > L	MCM	
LR02-114	F	4	1	A > P	L > R	MCM	
LR02-219	M	2	4	A > P	R > L		
LR02-252	F	1	1	A = P	SYM	CVH	
LR02-335a2	F	1	1	A > P	SYM		
LR03-319	F	2	2	A > P	SYM	MCM, CSP	
LR04-129	M	2	2	A > P	SYM	CVH	
LR04-300	M	1	1	A > P	SYM	MCM	
LR05-224	F	1	1	A = P	SYM		
LR05-269	M	1	4	A > P	R > L		
LR06-034	M	1	1	A > P	SYM	CSP	
UKMC-01	F	1	N	A > P	R > L	CSP	
UKMC-02	M	N	1	A > P	L > R		
UKMC-03	M	2	N	A > P	R > L		
UKMC-04	F	1	4	A > P	R > L	CSP, RBG	Also LR00-036
UKMC-05	M	2	2	A > P	SYM		
UKMC-06	F	2	2	P > A	SYM		
UKMC-07	M	1	3	A > P	R > L		
UKMC-08	F	1	1	A > P	SYM		
UKMC-09	F	3	3	—	SYM	CSP	

N, normal; A = P, anterior same as posterior; A > P, anterior more severe than posterior; P > A, posterior more severe than anterior (A-P gradients only apply to more severe Grades 1 and 2); L, left; R, right; L > R, left more severe than right; R > L, right more severe than left; SYM, symmetric; CSP, cavum septum pellucidum; CVH, cerebellar vermis hypoplasia; MCM, mega-cisterna magna; RBG, right basal ganglia small; —, data not available. Patient numbers were given to reported patients when additional clinical information and complete brain imaging studies were obtained from the authors.

RESULTS

Our series of 21 patients plus the 11 patients reported in the literature together comprise 13 females and 19 males. While data were not available for all subjects, the types and severity of anomalies and developmental problems were typical for the DEL22q11 syndrome (see the online Table III at <http://www.interscience.wiley.com/jpages/1552-4825/suppmat/index.html>). Conotruncal congenital heart defects were reported in 17 of 31, and typical facies in 21 of 27 patients in which these were noted. Other findings included cleft palate (4), hypocalcemia (2), and low T-cell count (3). Interestingly, 11 of 30 had microcephaly, and 3 of those with a normal OFC were at the 2nd centile. Most had a far greater degree of developmental delay than is typical for DEL22q11: 20 had severe, 6 moderate or mild-moderate, and 6 mild developmental delay or mental retardation, including one with only isolated speech and motor delay. Of the 12 subjects with moderate to mild involvement, 11 had asymmetric neurologic findings. In all, 16 subjects manifest neurologic asym-

metry, and all but 3 had “hard” neurologic signs such as hypertonia or hypotonia.

On review of brain MRI (and a single CT scan), we recognized typical changes of PMG in all 32 patients (Table I). The figures show representative images of four patients with symmetric PMG (Fig. 1) and four with asymmetric PMG (Fig. 2), the latter including three more severe on the right and one more severe on the left. The extent of PMG varied considerably among hemispheres, but was always most severe in the perisylvian region. Among the 31 brains (62 hemispheres) that we were able to assess for severity, we observed severe Grade 1 perisylvian PMG in 28 hemispheres, Grade 2 in 17, Grade 3 in 5, Grade 4 in 6, and no visible PMG in six hemispheres (Table I). When the PMG extended beyond the perisylvian region, the frontal lobes were usually more severely affected than posterior regions. In three patients with severe bilateral Grade 1 perisylvian PMG, all regions appeared similarly involved (A = P gradient). In 26 of the 27 remaining patients with Grade 1 or 2 PMG in at least one hemisphere, the frontal lobes were more severely involved than

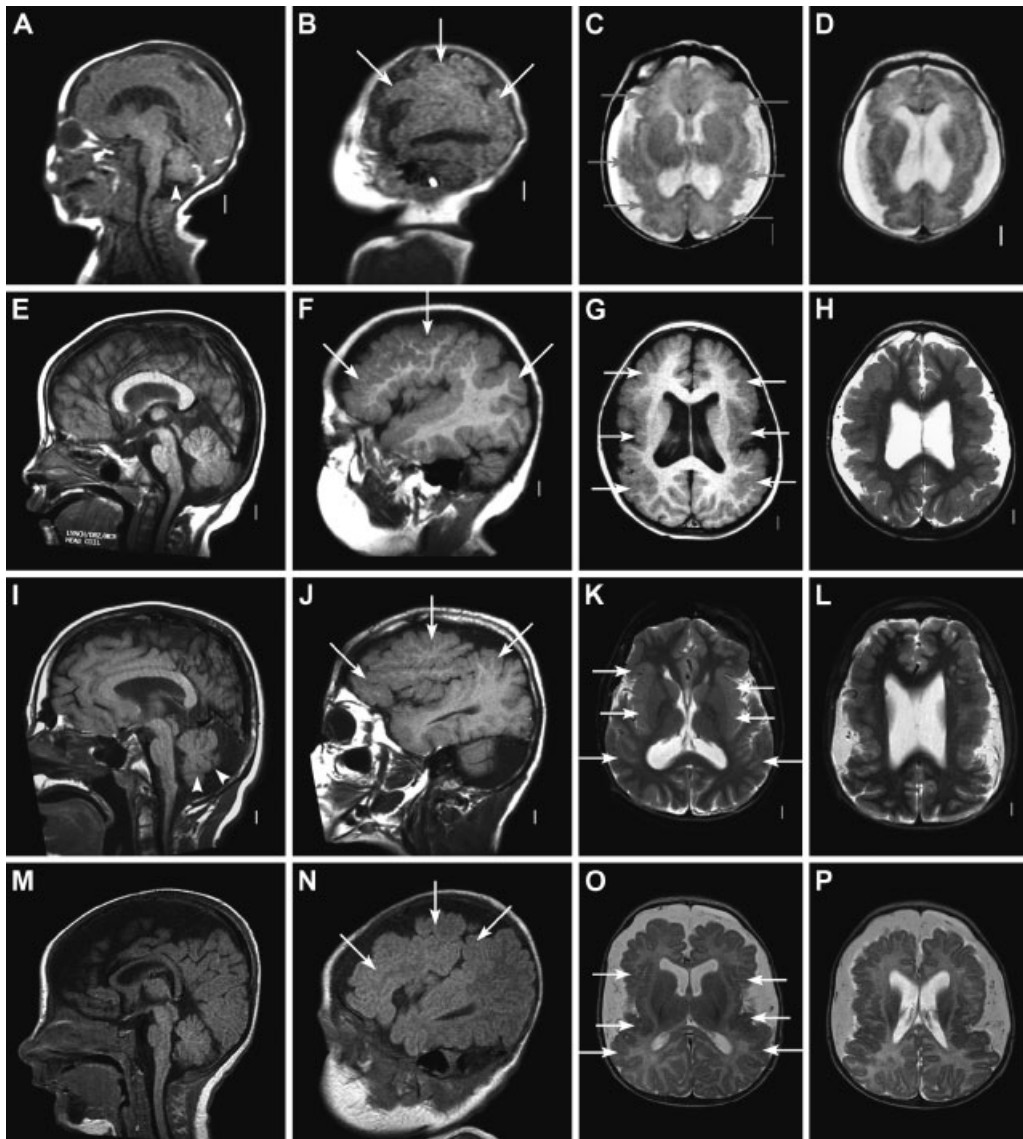


FIG. 1. Brain MRI in four patients with symmetric polymicrogyria (PMG) that appears most severe in the perisylvian regions. Arrows point to selected regions of PMG and arrowheads to the lower edge of the vermis in two patients with mild cerebellar vermis hypoplasia. These images come from patients LR02-252 (A–D), LR01-104 (E–H), LR02-091 (I–L), and LR04-129 (M–P).

the temporal, parietal, or occipital lobes (A > P gradient).

The cortical malformation was symmetric in 15 of the 32 patients. Surprisingly, the PMG was clearly asymmetric in the remaining patients, with the right hemisphere more severely affected than the left in 14 of 17. The right-sided predominance reached statistical significance by Chi-square analysis under the assumption that any asymmetry should involve the two sides equally (Table II). The more severely affected hemisphere had Grade 1 or 2 perisylvian PMG in all but one patient with Grade 3 PMG, while the less affected side had variable Grade 2–4 perisylvian PMG or no visible PMG. We also found mild cerebellar malformations that we classified as mild cerebellar vermis hypoplasia or as mega-

cisterna magna in 8 of the 24 patients whom we were able to assess (the published figures did not include midline sagittal images), and cavum septum pellucidum in 5 patients.

The diagnosis of DEL22q11 syndrome was established by finding a deletion of the *TUPLE1* or *N25* probe by FISH in all patients, and three patients had further studies done. Array comparative genome hybridization using a full coverage chromosome 22 array containing 354 BAC clones demonstrated the common 3 Mb deletion in one patient [Koolen et al., 2004]. The common 3 Mb deletion was documented in patient UKMC-4 (LR00-036) and one reported patient [Ghariani et al., 2002] using a panel of FISH probes within and flanking the DEL22q11 region (data not shown).

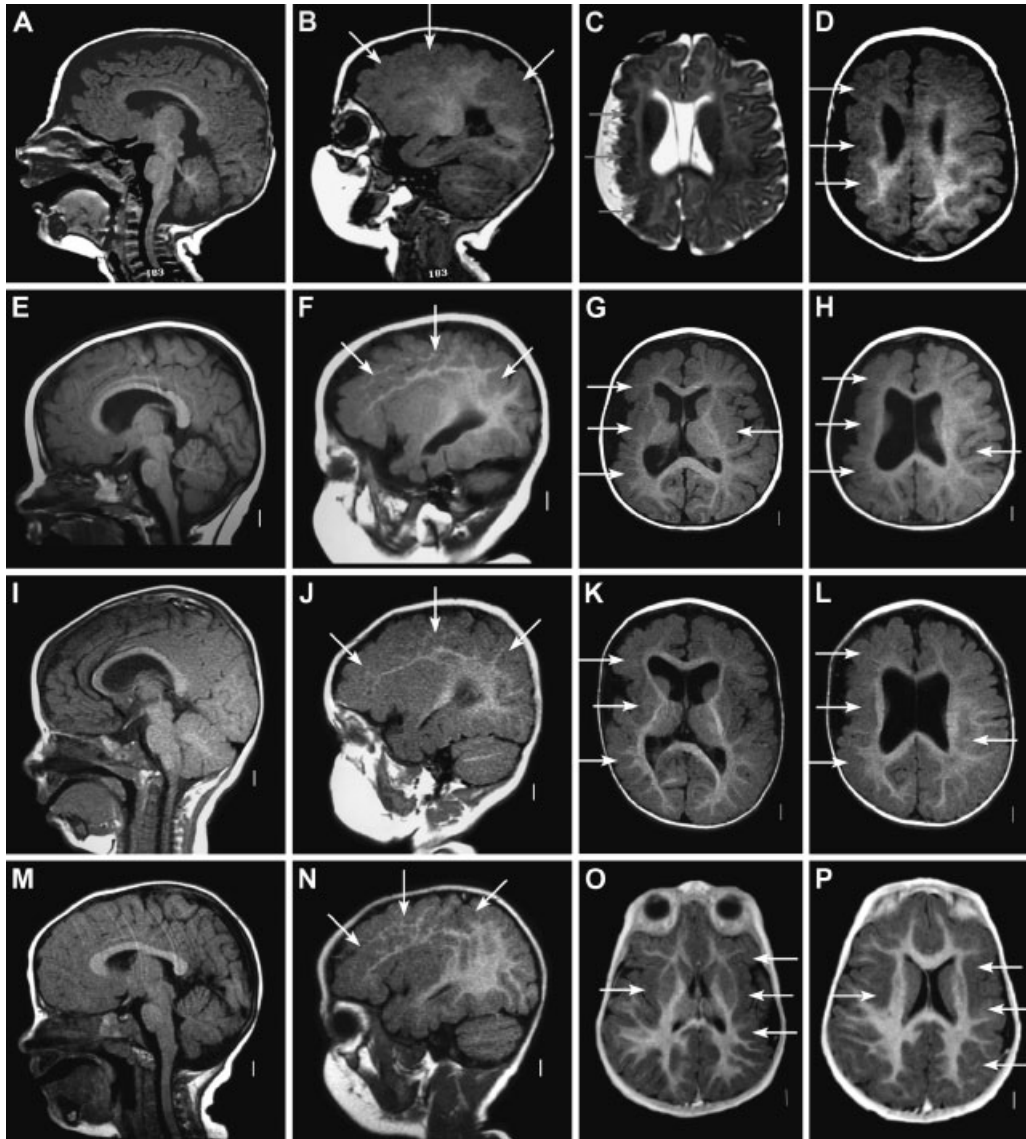


FIG. 2. Brain MRI in four patients with asymmetric polymicrogyria (PMG) that is always most severe in the perisylvian regions, and is more severe on the right in the top three rows and more severe on the left in the bottom row. Arrows point to selected regions of PMG. These images come from patients LR00-036 (A–D), LR02-098 (E–H), LR02-219 (I–L), and LR02-114 (M–P).

DISCUSSION

Our detailed review confirms several prior reports in identifying the cortical malformation in DEL22q11 as PMG, and further demonstrates that the perisylvian area is invariably involved, although this was not specifically mentioned in all published reports. This distribution is by far the most common

type, affecting two-thirds of all patients with PMG [Leventer et al., 2001]. The published images shown in the reports describing the cortical malformation as “pachygyria” [Ehara et al., 2003; Koolen et al., 2004] also have the distinct imaging characteristics of PMG, leading us to conclude that pachygyria (lissencephaly) is not a cortical malformation found in association with the DEL22q11 syndrome.

The characteristic neurological features of perisylvian PMG are cognitive defects, oromotor dysfunction (dyspraxia) consisting of nasal speech, dysarthria, dysphagia and drooling, and other signs of pseudobulbar palsy [Kuzniecky et al., 1993]. This phenotype was described by Worster-Drought long before brain imaging became available as a form of cerebral palsy with pseudobulbar paresis that

TABLE II. Analysis of PMG Gradients

Type	R-L gradient	
	N	P-value
SYM	15	n.a.
R > L	(14)	0.008
L > R	(03)	

he designated “congenital suprabulbar paresis” [Worster-Drought, 1956], so it has also been designated Worster–Drought syndrome. The association between congenital suprabulbar paresis and perisylvian PMG has been noted in several reports [Kuzniecky et al., 1993; Clark et al., 2000; Nevo et al., 2001].

Neurological Abnormalities in DEL22q11 with PMG

Velopharyngeal insufficiency and articulation problems are frequent in DEL22q11, and are usually attributed to structural anomalies of the palate. However, most patients with this syndrome do not have brain imaging performed, so that subtle PMG might be under-ascertained among patients with velopharyngeal insufficiency. All of the children in our series for whom we had adequate information had oromotor dysfunction. One of them (UKMC-03) was actually diagnosed with Worster–Drought syndrome before the diagnoses of asymmetric PMG and DEL22q11 were made, and several others with either unilateral or bilateral PMG had drooling and choking consistent with oromotor dyspraxia. Enlargement of the Sylvian fissures without PMG was reported in 10 of 17 patients with DEL22q11 with oromotor dysfunction, but only two were recognized to have PMG [Bingham et al., 1997, 1998]. This suggests that widening of the Sylvian fissures could be an indication of an underlying cortical abnormality not visible on MRI.

Other neurological problems were also more common in our series. In the European collaborative study of DEL22q11, 21% had seizures that were usually attributed to hypocalcemia, and only 8% had other neurological features [Ryan et al., 1997]. In contrast, over half of our patients presented with neurological problems prior to diagnosis of DEL22q11, with abnormalities consisting of developmental delay, hemiplegia, microcephaly, or seizures. About half (15) of our patients had seizures despite limited follow-up, and none of these were associated with hypocalcemia.

We also found mild cerebellar vermis hypoplasia or mega-cisterna magna in about a third of the patients in our series. Thus, both PMG and the cerebellar malformation exhibit incomplete penetrance and variable expressivity, similar to many other malformations associated with DEL22q11 [Ryan et al., 1997]. In further support of this, two patients with PMG inherited their deletion from a mildly affected parent [Bingham et al., 1998; Worthington et al., 2000].

Volumetric Brain Imaging in DEL22q11

The DEL22q11 syndrome has been associated with subtle abnormalities on volumetric brain imaging including reduction of overall brain volume espe-

cially white matter, decreased volume of parietal and temporal gray matter, abnormalities of midline structures such as the corpus callosum and reduced size of the cerebellum [Bearden et al., 2004; van Amelsvoort et al., 2004; Simon et al., 2005; Zinkstok and van Amelsvoort, 2005]. Both agenesis of the corpus callosum and cerebellar “atrophy” (more likely cerebellar hypoplasia as we found in our series) have been reported in a few patients with DEL22q11 [Lynch et al., 1995; Chow et al., 1999; Krainack et al., 1999], and could represent severe expression of these subtle brain volume abnormalities. However, the PMG is more difficult to explain this way.

Penetrance and Expressivity of PMG

Unfortunately, our data does not allow us to determine either the prevalence of DEL22q11 among patients with PMG, or the prevalence of PMG among patients with DEL22q11. We estimate that the PMG was recognized before the 22q11.2 deletion was found in ~8 of the 32 patients in our series. In contrast, PMG was recognized before the chromosome abnormality was found in ~4 of nine patients with PMG and deletion 1p36.3 and in ~2 of six patients with PMG and deletion 6q26-qter (W.B.D., unpublished data). This suggests that DEL22q11 is the most common of the chromosomal loci associated with PMG. The frequency of PMG among patients with DEL22q11 is probably low as abnormalities of the Sylvian fissure were not seen in a series of ~100 DEL22q11 patients with MRIs available for review [Shprintzen, 2000], although in our experience subtle PMG can be missed.

These observations, particularly the consistent pattern, low penetrance, variable expressivity and asymmetry of the malformation, raise interesting questions regarding the mechanism that we will consider by reviewing other studies of DEL22q11 and PMG.

Presumed Causes of PMG

PMG consists of small, irregular gyri separated by shallow partly fused sulci and frequent areas of infolded cortex, and by loss of neurons in middle cortical layers with reduction from six to four or no recognizable layers [Crome, 1952; Levine et al., 1974]. It can be recognized on MRI from the microgyri, moderately thick cortex (usually 6–10 mm), and irregular or pebbled brain surface and gray-white interface [Barkovich et al., 2001]. Many different types of PMG have been described based on distribution and associated malformations, but the most common by far is centered in the perisylvian regions [Barkovich et al., 1999; Leventer et al., 2001; Barkovich et al., 2005]. Many causes of PMG are known, and include both extrinsic effects on the fetus and genetic disorders. Both PMG and the

related malformation schizencephaly have been associated with conditions proposed to disrupt the fetal vascular supply, such as twinning and intrauterine cytomegalovirus infection [Norman, 1980; Graff-Radford et al., 1986; Hayward et al., 1991; Larroche et al., 1994; Sugama and Kusano, 1994; Baker et al., 1996; Van Bogaert et al., 1996, 1998; Sener, 1998; Hung and Wang, 2003; Curry et al., 2005].

Numerous genetic causes of PMG have been documented, including familial PMG with autosomal dominant, autosomal recessive, or X-linked inheritance [Bartolomei et al., 1999; Borgatti et al., 1999; Caraballo et al., 2000; Guerreiro et al., 2000; Hung and Wang, 2003; Villard et al., 2002]. Several small deletions or duplications have been associated with PMG, most reported only in abstracts, including deletion 1p36, 1q44, 9p24-pter, and 13q14.1-q31.2 [Shapira et al., 1999; Zollino et al., 2003; Callier et al., 2005; Kogan et al., 2005] and duplication 11q12-q13 and 22q11.2 [Dupuy et al., 1999; Callier et al., 2005]. Typical PMG has been seen in several multiple congenital anomaly syndromes, especially Adams-Oliver, Aicardi, Goldberg-Shprintzen, (Warburg) Micro, and oculo-cerebro-cutaneous (Delleman) syndromes [Ferrer et al., 1986; Billette de Villemeur et al., 1992; Amor et al., 2000; Graham et al., 2004; Brooks et al., 2005; Moog et al., 2005; Pascual-Castroviejo et al., 2005]. Two syndromes with atypical PMG resembling the cobblestone cortical malformation of muscle-eye-brain disease have also been described [Chang et al., 2004; Piao et al., 2005; Sprecher et al., 2005], and another variant occurs in patients with thanatophoric dysplasia [Hevner, 2005].

Pathogenesis of PMG in the DEL22q11 Syndrome

While the basis of the infrequent PMG in this syndrome is unknown, enough data has accumulated to consider possible mechanisms. Our most interesting finding is the frequent asymmetry between hemispheres and the striking predisposition for the right hemisphere. This leads us to hypothesize that the gene or genes predisposing to PMG may be asymmetrically expressed between the hemispheres. But which gene or genes?

The existing data suggest several possible mechanisms, the first being haploinsufficiency of a gene expressed in embryonic brain that regulates cortical development. However, mutations of only a few genes have been associated with PMG. The first is *RAB3GAP*, which regulates the Rab3 pathway implicated in exocytic release of neurotransmitters, hormones, and possibly trophic factors, and is mutated in some patients with Micro syndrome [Aligianis et al., 2005]. The next is *KIAA1279*, a gene of unknown function that is mutated in Goldberg-Shprintzen syndrome [Brooks et al., 2005]. In addition, heterozygous and especially homozygous

mutations of *PAX6* have been associated with PMG [Glaser et al., 1994; Mitchell et al., 2003], suggesting that PMG may result from a cortical patterning abnormality such as proliferation defects involving specific subsets of neurons or cortical and thalamic pathfinding defects [Heins et al., 2002; Hevner et al., 2002; Muzio et al., 2002; Muzio and Mallamaci, 2003; Stenman et al., 2003; Englund et al., 2005]. However, no genes in the DiGeorge critical region stand out as strong functional candidates for this mechanism.

Another possible and more intriguing mechanism for PMG involves hypoperfusion of the embryonic brain. Here we hypothesize that haploinsufficiency of a gene expressed in vascular tissue perfusing the embryonic brain, probably in concert with genetic modifying factors, leads to PMG and in particular to asymmetric PMG. Several lines of evidence support this hypothesis. First, disorders that disrupt the fetal vascular supply have been associated with PMG as noted above. Next, haploinsufficiency of *TBX1* (the key cardiovascular patterning gene in the DiGeorge critical region, DGCR) results in a spectrum of distinct vascular and heart defects in both mouse and human that affects formation and growth of the pharyngeal arch arteries and related structures [Lindsay et al., 2001; Vitelli et al., 2002; Yagi et al., 2003]. In mouse mutants, the arterial growth deficiency affects all embryonic day (E) 10.5 mutants, but partial recovery occurs so that only 65% are affected at E11.5 and only 30% at E18.5 [Lindsay and Baldini, 2001]. At all ages studied, the right side is more frequently and severely affected than the left with significant *P* values. This fits well with our observations of PMG in DEL22q11, as we also found that the right side is more frequently and severely affected than the left with a significant *P* value. Little other data are available in humans with DEL22q11, although magnetic resonance arteriograms in 11 patients demonstrated unilateral hypoplasia of the posterior cerebral artery in two patients, both involving the right side [Chow et al., 1999].

These data suggest that the gene or genes predisposing to PMG may be asymmetrically expressed between the hemispheres. Several genes in the DGCR, including *DGCR6*, *DGCR6L*, and *ZNF74* are differentially expressed in 12-week embryonic human cortex [Sun et al., 2005]. The former two are expressed at low levels in brain, while *ZNF74* is expressed in neural crest-derived tissues and so could contribute to the vascular (and brain) phenotype.

Further, studies in mouse, human, and zebrafish have all demonstrated that the *VEGF* gene functions as a modifier of the cardiovascular birth defects in the DEL22q11 syndrome, including data demonstrating that a *VEGF* promoter haplotype is associated with an increased risk for cardiovascular malformations in humans [Stalmans et al., 2003]. Conotruncal heart defects were recently reported in a boy with a

small 6p21 deletion that includes the *VEGF* gene, suggesting that haploinsufficiency of *VEGF* results in cardiovascular defects similar to haploinsufficiency of *TBX1* [Izumi et al., 2006]. Interestingly, *VEGF* is asymmetrically expressed in 19-week human cortex [Sun et al., 2005]. Putting these together, the PMG in the DEL22q11 syndrome could result from a combination of haploinsufficiency of *TBX1* and mutation or unfavorable promoter haplotype of *VEGF* or other modifying genes. These are potentially testable hypotheses.

Two other explanations seem less likely. The PMG could result from large deletions that extend beyond the common 3 Mb DiGeorge critical region, but this has been excluded in three patients. Alternatively, the deletion might uncover mutations in the undelimited homolog of a gene located in this region, as has been observed in the Bernard–Soulier syndrome [Budarf et al., 1995]. But this should be a rare mechanism, and would not easily explain our ascertainment of more than 30 patients.

CONCLUSIONS

This series of patients confirms that PMG is an associated manifestation for the DEL22q11 syndrome. The PMG is characterized by variable severity and frequent asymmetry of PMG, but the perisylvian cortex is always the most severely affected region. The typical DEL22q11 phenotype is difficult to recognize in the presence of PMG, as most patients manifest more severe developmental abnormalities and often have associated neurologic findings. These data suggest that DEL22q11 is a relatively common cause of perisylvian PMG, especially asymmetric PMG. In our series of 32 patients, all manifest either severe developmental delay or “hard” neurologic findings such as asymmetry, pseudobulbar palsy, or hypo/hypertonia. These are atypical for DEL22q11, and should prompt evaluation for PMG. Furthermore, we recommend that all patients with perisylvian PMG be tested for deletion 22q11.2, and that brain imaging be performed in patients with DEL22q11 who have more severe neurological abnormalities than are typical.

ACKNOWLEDGMENTS

The authors thank the families for participating, and Dr. Wajanat Jan for review of imaging studies.

REFERENCES

- Aligianis IA, Johnson CA, Gissen P, Chen D, Hampshire D, Hoffmann K, Maina EN, Morgan NV, Tee L, Morton J, Ainsworth JR, Horn D, Rosser E, Cole TR, Stolte-Dijkstra I, Fieggen K, Clayton-Smith J, Megarbane A, Shield JP, Newbury-Ecob R, Dobyns WB, Graham JM Jr, Kjaer KW, Warburg M, Bond J, Trembath RC, Harris LW, Takai Y, Mundlos S, Tannahill D, Woods CG, Maher ER. 2005. Mutations of the catalytic subunit of *RAB3GAP* cause Warburg Micro syndrome. *Nat Genet* 37:221–223.
- Amor DJ, Leventer RJ, Hayllar S, Bankier A. 2000. Polymicrogyria associated with scalp and limb defects: Variant of Adams–Oliver syndrome. *Am J Med Genet* 93:328–334.
- Baker EM, Khorasgani MG, Gardner-Medwin D, Gholkar A, Griffiths PD. 1996. Arthrogyposis multiplex congenita and bilateral parietal polymicrogyria in association with the intrauterine death of a twin. *Neuropediatrics* 27:54–56.
- Barkovich AJ, Hevner R, Guerrini R. 1999. Syndromes of bilateral symmetrical polymicrogyria. *AJNR Am J Neuroradiol* 20:1814–1821.
- Barkovich AJ, Kuzniecky RI, Jackson GD, Guerrini R, Dobyns WB. 2001. Classification system for malformations of cortical development: Update 2001. *Neurology* 57:2168–2178.
- Barkovich AJ, Kuzniecky RI, Jackson GD, Guerrini R, Dobyns WB. 2005. A developmental and genetic classification for malformations of cortical development. *Neurology* 65:1873–1887.
- Barth PG. 1987. Disorders of neuronal migration. *Can J Neurol Sci* 14:1–16.
- Bartolomei F, Gavaret M, Dravet C, Guerrini R. 1999. Familial epilepsy with unilateral and bilateral malformations of cortical development. *Epilepsia* 40:47–51.
- Bearden CE, van Erp TG, Monterosso JR, Simon TJ, Glahn DC, Saleh PA, Hill NM, McDonald-McGinn DM, Zackai E, Emanuel BS, Cannon TD. 2004. Regional brain abnormalities in 22q11.2 deletion syndrome: Association with cognitive abilities and behavioral symptoms. *Neurocase* 10:198–206.
- Billette de Villemeur T, Chiron C, Robain O. 1992. Unlayered polymicrogyria and agenesis of the corpus callosum: A relevant association? *Acta Neuropathol (Berl)* 83:265–270.
- Bingham PM, Zimmerman RA, McDonald-McGinn D, Driscoll D, Emanuel BS, Zackai E. 1997. Enlarged sylvian fissures in infants with interstitial deletion of chromosome 22q11. *Am J Med Genet* 74:538–543.
- Bingham PM, Lynch D, McDonald-McGinn D, Zackai E. 1998. Polymicrogyria in chromosome 22 deletion syndrome. *Neurology* 51:1500–1502.
- Bird LM, Scambler P. 2000. Cortical dysgenesis in 2 patients with chromosome 22q11 deletion. *Clin Genet* 58:64–68.
- Borgatti R, Triulzi F, Zucca C, Piccinelli P, Balottin U, Carozzo R, Guerrini R. 1999. Bilateral perisylvian polymicrogyria in three generations. *Neurology* 52:1910–1913.
- Brooks AS, Bertoli-Avella AM, Burzynski GM, Breedveld GJ, Osinga J, Boven LG, Hurst JA, Mancini GM, Lequin MH, de Co RF, Matera I, de Graaff E, Meijers C, Willems PJ, Tibboel D, Oostra BA, Hofstra RM. 2005. Homozygous nonsense mutations in *KIAA1279* are associated with malformations of the central and enteric nervous systems. *Am J Hum Genet* 77:120–126.
- Budarf ML, Konkle BA, Ludlow LB, Michaud D, Li M, Yamashiro DJ, McDonald-McGinn D, Zackai EH, Driscoll DA. 1995. Identification of a patient with Bernard–Soulier syndrome and a deletion in the DiGeorge/velo-cardio-facial chromosomal region in 22q11.2. *Hum Mol Genet* 4:763–766.
- Callier P, Faivre L, Marle N, Thauvin-Robinet C, Madinier N, Mosca AL, Ragot S, Huet F, Teyssier JR, Mugneret F. 2005. Polymicrogyria in a child with deletion 9p24-pter and microduplication 22q11.2. American Society of Human Genetics 55th Annual Meeting. American Society of Human Genetics, Salt Lake City, UT, October 25–29, 2005.
- Caraballo RH, Cersosimo RO, Mazza E, Fejerman N. 2000. Focal polymicrogyria in mother and son. *Brain Dev* 22:336–339.
- Chang BS, Piao X, Giannini C, Cascino GD, Scheffer I, Woods CG, Topcu M, Tezcan K, Bodell A, Leventer RJ, Barkovich AJ, Grant PE, Walsh CA. 2004. Bilateral generalized polymicrogyria (BGP): A distinct syndrome of cortical malformation. *Neurology* 62:1722–1728.
- Chow EW, Mikulis DJ, Zipursky RB, Scutt LE, Weksberg R, Bassett AS. 1999. Qualitative MRI findings in adults with 22q11 deletion syndrome and schizophrenia. *Biol Psychiatry* 46:1436–1442.

- Clark M, Carr L, Reilly S, Neville BG. 2000. Worster-Drought syndrome, a mild tetraplegic perisylvian cerebral palsy: Review of 47 cases. *Brain* 123:2160–2170.
- Cramer SC, Schaefer PW, Krishnamoorthy KS. 1996. Microgyria in the distribution of the middle cerebral artery in a patient with DiGeorge syndrome. *J Child Neurol* 11:494–497.
- Crome L. 1952. Microgyria. *J Pathol Bacteriol* 64:479–495.
- Curry CJ, Lammer EJ, Nelson V, Shaw GM. 2005. Schizencephaly: Heterogeneous etiologies in a population of 4 million California births. *Am J Med Genet Part A* 137A:181–189.
- de Vries BA. 2005. Polymicrogyria versus pachygyria in 22q11 microdeletion. *Am J Med Genet Part A* 136A:420.
- de Wit MC, Lequin MH, de Coo RF, Mancini GM. 2005. Re: Polymicrogyria versus pachygyria in 22q11 microdeletion. *Am J Med Genet Part A* 136A:419.
- Dupuy O, Husson I, Wirth J, Wiss J, Nessmann C, Evrard P, Eydoux P. 1999. Pachygyria and polymicrogyria, cranio-facial dysmorphism and atrio-ventricular canal resulting from a duplication of the proximal region of chromosome 11q (11q11-11q12). *Am J Hum Genet* 64:A161 (#878).
- Ehara H, Maegaki Y, Takeshita K. 2003. Pachygyria and polymicrogyria in 22q11 deletion syndrome. *Am J Med Genet Part A* 117A:80–82.
- Ehara H, Maegaki Y, Takeshita K. 2005. Reply to correspondence to the editor by de Wit, et al.—“Re: Polymicrogyria versus pachygyria in 22q11 deletion”. *Am J Med Genet Part A* 136A:421.
- Englund C, Fink A, Lau C, Pham D, Daza RA, Bulfone A, Kowalczyk T, Hevner RF. 2005. Pax6, Tbr2, and Tbr1 are expressed sequentially by radial glia, intermediate progenitor cells, and postmitotic neurons in developing neocortex. *J Neurosci* 25:247–251.
- Ferrer I, Cusi MV, Liarte A, Campistol J. 1986. A golgi study of the polymicrogyric cortex in Aicardi syndrome. *Brain Dev* 8:518–525.
- Forrester S, Kovach MJ, Smith RE, Rimer L, Wesson M, Kimonis VE. 2002. Kousseff syndrome caused by deletion of chromosome 22q. 11–13. *Am J Med Genet* 112:338–342.
- Ghariani S, Dahan K, Saint-Martin C, Kadhim H, Morsomme F, Moniotte S, Verellen-Dumoulin C, Sebire G. 2002. Polymicrogyria in chromosome 22q11 deletion syndrome. *Europ J Paediatr Neurol* 6:73–77.
- Glaser T, Jepeal L, Edwards JG, Young SR, Favor J, Maas RL. 1994. *PAX6* gene dosage effect in a family with congenital cataracts, aniridia, anophthalmia and central nervous system defects. *Nat Genet* 7:463–471.
- Graff-Radford NR, Bosch EP, Stears JC, Tranel D. 1986. Developmental Foix-Chavany-Marie syndrome in identical twins. *Ann Neurol* 20:632–635.
- Graham JM Jr, Hennekam R, Dobyns WB, Roeder E, Busch D. 2004. MICRO syndrome: An entity distinct from COFS syndrome. *Am J Med Genet Part A* 128A:235–245.
- Guerreiro MM, Andermann E, Guerrini R, Dobyns WB, Kuzniecky R, Silver K, Van Bogaert P, Gillain C, David P, Ambrosetto G, Rosati A, Bartolomei F, Parmeggiani A, Paetau R, Salonen O, Ignatius J, Borgatti R, Zucca C, Bastos AC, Palmi A, Fernandes W, Montenegro MA, Cendes F, Andermann F. 2000. Familial perisylvian polymicrogyria: A new familial syndrome of cortical maldevelopment. *Ann Neurol* 48:39–48.
- Guerrini R, Sicca F, Parmeggiani L. 2003. Epilepsy and malformations of the cerebral cortex. *Epileptic Disord* 5:S9–26.
- Hayward JC, Titelbaum DS, Clancy RR, Zimmerman RA. 1991. Lissencephaly-pachygyria associated with congenital cytomegalovirus infection. *J Child Neurol* 6:109–114.
- Heins N, Malatesta P, Cecconi F, Nakafuku M, Tucker KL, Hack MA, Chapouton P, Barde YA, Gotz M. 2002. Glial cells generate neurons: The role of the transcription factor Pax6. *Nat Neurosci* 5:308–315.
- Hevner RF. 2005. The cerebral cortex malformation in thanatophoric dysplasia: Neuropathology and pathogenesis. *Acta Neuropathol (Berl)* 110:208–221.
- Hevner RF, Miyashita-Lin E, Rubenstein JL. 2002. Cortical and thalamic axon pathfinding defects in Tbr1, Gbx2, and Pax6 mutant mice: Evidence that cortical and thalamic axons interact and guide each other. *J Comp Neurol* 447:8–17.
- Hung PC, Wang HS. 2003. Polymicrogyria in monozygous twins and an elder sibling. *Dev Med Child Neurol* 45:494–496.
- Izumi K, Yahagi N, Fujii Y, Higuchi M, Kosaki R, Naito Y, Nishimura G, Hosokai N, Takahashi T, Kosaki K. 2006. Cleidocranial dysplasia plus vascular anomalies with 6p21.2 microdeletion spanning *RUNX2* and *VEGF*. *Am J Med Genet Part A* 140A:398–401.
- Kawame H, Kurosawa K, Akatsuka A, Ochiai Y, Mizuno K. 2000. Polymicrogyria is an uncommon manifestation in 22q11.2 deletion syndrome [letter]. *Am J Med Genet* 94:77–78.
- Kogan JM, Egelhoff JC, Saal HM. 2005. Interstitial deletion of 13q associated with polymicrogyria. American Society of Human Genetics 55th Annual Meeting. American Society of Human Genetics, Salt Lake City, UT.
- Koolen DA, Veltman JA, Renier WO, Droog RP, van Kessel AG, de Vries BB. 2004. Chromosome 22q11 deletion and pachygyria characterized by array-based comparative genomic hybridization. *Am J Med Genet Part A* 131A:322–324.
- Kraynack NC, Hostoffer RW, Robin NH. 1999. Agenesis of the corpus callosum associated with DiGeorge-velocardiofacial syndrome: A case report and review of the literature. *J Child Neurol* 14:754–756.
- Kuzniecky RI, Andermann F, Guerrini R. 1993. The congenital bilateral perisylvian syndrome: Study of 31 patients. The congenital bilateral perisylvian syndrome multicenter collaborative study. *Lancet* 341:608–612.
- Kuzniecky R, Andermann F, Guerrini R. 1994. The epileptic spectrum in the congenital bilateral perisylvian syndrome. CBPS Multicenter Collaborative Study. *Neurology* 44:379–385.
- Larroche JC, Girard N, Narcy F, Fallet C. 1994. Abnormal cortical plate (polymicrogyria), heterotopias and brain damage in monozygous twins. *Biol Neonate* 65:343–352.
- Leventer RJ, Lese CM, Cardoso C, Roseberry J, Weiss A, Stoodley N, Pilz DT, Villard L, Nguyen K, Clark GD, Shaffer LG, Guerrini R, Dobyns WB. 2001. A study of 220 patients with polymicrogyria delineates distinct phenotypes and reveals genetic loci on chromosomes 1p, 2p, 6q, 21q and 22q (abstract). *Am J Hum Genet* 69:177.
- Levine DN, Fisher MA, Caviness VS Jr. 1974. Porencephaly with microgyria: A pathologic study. *Acta Neuropathol* 29:99–113.
- Lindsay EA, Baldini A. 2001. Recovery from arterial growth delay reduces penetrance of cardiovascular defects in mice deleted for the DiGeorge syndrome region. *Hum Mol Genet* 10:997–1002.
- Lindsay EA, Vitelli F, Su H, Morishima M, Huynh T, Pramparo T, Jurecic V, Ogunrinu G, Sutherland HF, Scambler PJ, Bradley A, Baldini A. 2001. Tbx1 haploinsufficiency in the DiGeorge syndrome region causes aortic arch defects in mice. *Nature* 410:97–101.
- Lynch DR, McDonald-McGinn DM, Zackai EH, Emanuel BS, Driscoll DA, Whitaker LA, Fischbeck KH. 1995. Cerebellar atrophy in a patient with velocardiofacial syndrome. *J Med Genet* 32:561–563.
- Mitchell TN, Free SL, Williamson KA, Stevens JM, Churchill AJ, Hanson IM, Shorvon SD, Moore AT, van Heyningen V, Sisodiya SM. 2003. Polymicrogyria and absence of pineal gland due to *PAX6* mutation. *Ann Neurol* 53:658–663.
- Moog U, Jones MC, Bird LM, Dobyns WB. 2005. Oculocerebrocutaneous syndrome: The brain malformation defines a core phenotype. *J Med Genet* 42:913–921.
- Muzio L, Mallamaci A. 2003. Emx1, emx2 and pax6 in specification, regionalization and arealization of the cerebral cortex. *Cereb Cortex* 13:641–647.
- Muzio L, DiBenedetto B, Stoykova A, Boncinelli E, Gruss P, Mallamaci A. 2002. Conversion of cerebral cortex into basal ganglia in Emx2(–/–) Pax6(Sey/Sey) double-mutant mice. *Nat Neurosci* 5:737–745.

- Nevo Y, Segev Y, Gelman Y, Rieder-Grosswasser I, Harel S. 2001. Worster-Drought and congenital perisylvian syndromes—a continuum? *Pediatr Neurol* 24:153–155.
- Nickel RE, Pillers DA, Merckens M, Magenis RE, Driscoll DA, Emanuel BS, Zonana J. 1994. Velo-cardio-facial syndrome and DiGeorge sequence with meningomyelocele and deletions of the 22q11 region. *Am J Med Genet Part A* 52A:445–449.
- Norman MG. 1980. Bilateral encephaloclastic lesions in a 26 week gestation fetus: Effect on neuroblast migration. *Can J Neurol Sci* 7:191–194.
- Pascual-Castroviejo I, Pascual-Pascual SI, Velazquez-Fragua R, Lapunzina P. 2005. Oculocerebrocutaneous (Delleman) syndrome: Report of two cases. *Neuropediatrics* 36:50–54.
- Piao X, Chang BS, Bodell A, Woods K, Benzeev B, Topcu M, Guerrini R, Goldberg-Stern H, Sztriha L, Dobyns WB, Barkovich AJ, Walsh CA. 2005. Genotype-phenotype analysis of human frontoparietal polymicrogyria syndromes. *Ann Neurol* 58:680–687.
- Ryan AK, Goodship JA, Wilson DI, Philip N, Levy A, Seidel H, Schuffenhauer S, Oechsler H, Belohradsky B, Prieur M, Aurias A, Raymond FL, Clayton-Smith J, Hatchwell E, McKeown C, Beemer FA, Dallapiccola B, Novelli G, Hurst JA, Ignatius J, Green AJ, Winter RM, Brueton L, Brondum-Nielsen K, Scambler PJ, et al. 1997. Spectrum of clinical features associated with interstitial chromosome 22q11 deletions: A European collaborative study. *J Med Genet* 34:798–804.
- Sener RN. 1998. Schizencephaly and congenital cytomegalovirus infection. *J Neuroradiol* 25:151–152.
- Shapira SK, Heilstedt HA, Starkey DE, Burgess DL, Chedrawi AK, Anderson AE, Tharp B, Carrol CL, Armstrong D, Wu Y-Q, Noebels JL, Shaffer LG. 1999. Clinical and pathological characterization of epilepsy in patients with monosomy 1p36 and the search for candidate genes (abstract 564). *Am J Hum Genet* 65:A107.
- Shprintzen RJ. 2000. Velo-cardio-facial syndrome: A distinctive behavioral phenotype. *Ment Retard Dev Disabil Res Rev* 6: 142–147.
- Shprintzen RJ. 2004. Velo-cardio-facial syndrome. In: Cassidy SB, Allanson J, editors. *Management of Genetic Syndromes*, 2nd edition. New York: John Wiley & Sons. p 615–632.
- Simon TJ, Ding L, Bish JP, McDonald-McGinn DM, Zackai EH, Gee J. 2005. Volumetric, connective, and morphologic changes in the brains of children with chromosome 22q11.2 deletion syndrome: An integrative study. *Neuroimage* 25: 169–180.
- Sprecher E, Ishida-Yamamoto A, Mizrahi-Koren M, Rapaport D, Goldsher D, Indelman M, Topaz O, Chefetz I, Keren H, O'Brien TJ, Bercovich D, Shalev S, Geiger D, Bergman R, Horowitz M, Mandel H. 2005. A mutation in *SNAP29*, coding for a SNARE protein involved in intracellular trafficking, causes a novel neurocutaneous syndrome characterized by cerebral dysgenesis, neuropathy, ichthyosis, and palmoplantar keratoderma. *Am J Hum Genet* 77:242–251.
- Stalmans I, Lambrechts D, De Smet F, Jansen S, Wang J, Maity S, Kneer P, von der Ohe M, Swillen A, Maes C, Gewillig M, Molin DG, Hellings P, Boetel T, Haardt M, Compennolle V, Dewerchin M, Plaisance S, Vlietinck R, Emanuel B, Gittenberger-de Groot AC, Scambler P, Morrow B, Driscoll DA, Moons L, Esguerra CV, Carmeliet G, Behn-Krappa A, Devriendt K, Collen D, Conway SJ, Carmeliet P. 2003. VEGF: A modifier of the del22q11 (DiGeorge) syndrome? *Nat Med* 9: 173–182.
- Stenman J, Yu RT, Evans RM, Campbell K. 2003. Tlx and Pax6 cooperate genetically to establish the pallio-subpallial boundary in the embryonic mouse telencephalon. *Development* 130: 1113–1122.
- Sugama S, Kusano K. 1994. Monozygous twin with polymicrogyria and normal co-twin. *Pediatr Neurol* 11:62–63.
- Sun T, Patoine C, Abu-Khalil A, Visvader J, Sum E, Cherry TJ, Orkin SH, Geschwind DH, Walsh CA. 2005. Early asymmetry of gene transcription in embryonic human left and right cerebral cortex. *Science* 308:1794–1798.
- Sztriha L, Guerrini R, Harding B, Stewart F, Chelloug N, Johansen JG. 2004. Clinical, MRI, and pathological features of polymicrogyria in chromosome 22q11 deletion syndrome. *Am J Med Genet Part A* 127A:313–317.
- van Amelsvoort T, Daly E, Henry J, Robertson D, Ng V, Owen M, Murphy KC, Murphy DG. 2004. Brain anatomy in adults with velocardiofacial syndrome with and without schizophrenia: Preliminary results of a structural magnetic resonance imaging study. *Arch Gen Psychiatry* 61:1085–1096.
- Van Bogaert P, Donner C, David P, Rodesch F, Avni EF, Sziwowski HB. 1996. Congenital bilateral perisylvian syndrome in a monozygotic twin with intra-uterine death of the co-twin. *Dev Med Child Neurol* 38:166–170.
- Van Bogaert P, David P, Gillain CA, Wikler D, Damhaut P, Scalais E, Nuttin C, Wetzburger C, Sziwowski HB, Metens T, Goldman S. 1998. Perisylvian dysgenesis. Clinical, EEG, MRI and glucose metabolism features in 10 patients. *Brain* 121 2229–2238.
- Villard L, Nguyen K, Cardoso C, Martin CL, Weiss AM, Sifry-Platt M, Grix AW, Graham JM Jr, Winter RM, Leventer RJ, Dobyns WB. 2002. A locus for bilateral perisylvian polymicrogyria maps to Xq28. *Am J Hum Genet* 70:1003–1008.
- Vitelli F, Morishima M, Taddei I, Lindsay EA, Baldini A. 2002. *Tbx1* mutation causes multiple cardiovascular defects and disrupts neural crest and cranial nerve migratory pathways. *Hum Mol Genet* 11:915–922.
- Worster-Drought C. 1956. Congenital suprabulbar paresis. *J Laryngol Otol* 70:453–463.
- Worthington S, Turner A, Elber J, Andrews PI. 2000. 22q11 deletion and polymicrogyria—cause or coincidence? *Clin Dysmorphol* 9:193–197.
- Yagi H, Furutani Y, Hamada H, Sasaki T, Asakawa S, Minoshima S, Ichida F, Joo K, Kimura M, Imamura S, Kamatani N, Momma K, Takao A, Nakazawa M, Shimizu N, Matsuoka R. 2003. Role of *TBX1* in human del22q11.2 syndrome. *Lancet* 362:1366–1373.
- Zinkstok J, van Amelsvoort T. 2005. Neuropsychological profile and neuroimaging in patients with 22q11.2 deletion syndrome: A review. *Neuropsychol Dev Cogn C Child Neuropsychol* 11:21–37.
- Zollino M, Colosimo C, Zuffardi O, Rossi E, Tosolini A, Walsh CA, Neri G. 2003. Cryptic t(1;12)(q44;p13.3) translocation in a previously described syndrome with polymicrogyria, segregating as an apparently X-linked trait. *Am J Med Genet Part A* 117A:65–71.