

UCSF

UC San Francisco Previously Published Works

Title

Extracorporeal life support for acute respiratory distress syndromes.

Permalink

<https://escholarship.org/uc/item/26h7p2qb>

Journal

Annals of Thoracic Medicine, 8(3)

ISSN

1817-1737

Authors

Hayes, Don

Tobias, Joseph

Kukreja, Jasleen

et al.

Publication Date

2013-07-01

DOI

10.4103/1817-1737.114290

Peer reviewed

Extracorporeal life support for acute respiratory distress syndrome

Don Hayes Jr.^{1,4-6}, Joseph D. Tobias^{2,4,7}, Jasleen Kukreja⁹, Thomas J. Preston⁴, Andrew R. Yates³⁻⁵, Stephen Kirkby^{1,4-6}, Bryan A. Whitson⁸

¹Section of Pulmonary Medicine, ²Anesthesiology, and ³Cardiology, Nationwide Children's Hospital, ⁴Heart Center, Nationwide Children's Hospital, Departments of

⁵Pediatrics, ⁶Internal Medicine, ⁷Anesthesiology, and ⁸Surgery, The Ohio State University Wexner Medical Center, Columbus, OH,

⁹Department of Surgery, University of California at San Francisco Medical Center, San Francisco, CA, USA

Address for correspondence:

Dr. Don Hayes, Jr. The Ohio State University, Nationwide Children's Hospital, 700 Children's Drive, Columbus, OH 43205, USA.
E-mail: hayes.705@osu.edu

Submitted: 10-10-2012
Accepted: 10-10-2012

Access this article online

Quick Response Code:



Website:
www.thoracicmedicine.org

DOI:
10.4103/1817-1737.114290

Abstract:

The morbidity and mortality of acute respiratory distress syndrome remain to be high. Over the last 50 years, the clinical management of these patients has undergone vast changes. Significant improvement in the care of these patients involves the development of mechanical ventilation strategies, but the benefits of these strategies remain controversial. With a growing trend of extracorporeal support for critically ill patients, we provide a historical review of extracorporeal membrane oxygenation (ECMO) including its failures and successes as well as discussing extracorporeal devices now available or nearly accessible while examining current clinical indications and trends of ECMO in respiratory failure.

Key words:

Acute respiratory distress syndrome, extracorporeal life support, extracorporeal membrane oxygenation

The initial mortality rates associated with acute respiratory distress syndrome (ARDS) were reported to be as high as 50% in 1967.^[1] Published studies in the early 1990s demonstrated a reduction in mortality that continued to a nadir of 29-38% by the end of the decade.^[2-6] More recently, the mortality associated with ARDS has remained steady at 25-30%.^[7,8] In a recent study, there was no difference in mortality rates between early- and late-onset ARDS.^[9] Although this reduction in ARDS mortality is not universally accepted, there has been some progress in the treatment of acute lung injury (ALI) and ARDS. This progress is directly related to the methods of respiratory support employed in the treatment of critically ill patients with ARDS. In this manuscript, we review the changes in conventional mechanical ventilation before moving onto methods of extracorporeal support. We discuss early failures and more recent success of extracorporeal membrane oxygenation (ECMO), while discussing alternative extracorporeal devices currently available or soon to be accessible. To conclude, we briefly discuss the current clinical applications and recent trends for the use of ECMO.

Conventional Respiratory Support for Acute Respiratory Distress Syndrome

Typically, therapeutic strategies hinge on the knowledge of the underlying disease process, but our understanding of ARDS is very limited. Despite our limited understanding of the pathophysiology, numerous clinical trials, including the ARDS network trial, suggested that specific ventilator management techniques

could lead to superior outcomes.^[10] Lung protective ventilation with adjusted positive end-expiratory pressure (PEEP) remains the most effective respiratory support method. It is now clear that high tidal volumes result in further lung injury and that the use of lower tidal volumes (6 ml/kg) may improve mortality.^[10-14] Mechanical ventilation with lower tidal volumes, resulting in higher than normal CO₂ partial pressures (permissive hypercapnia), is associated with not only a reduction in mortality but also a less number of days requiring ventilator use. The complications and mortality of severe lung injury and ARDS remain very high at 35-45%.^[15]

A major reason for the slow progress in advancement of the treatment of ALI and ARDS is the lack of detailed knowledge of the pathophysiology of ARDS and the impact upon this physiology by the current treatment strategies. The current trend of permissive hypercapnia is constrained by the limits of tolerable respiratory acidosis which may cause substantial changes in hemodynamic function and organ blood flow unless the arterial pH is controlled.^[16,17]

In refractory ARDS with profound hypoxemia or respiratory acidosis, additional non-pharmacological interventions are necessitated, such as positioning maneuvers, nitric oxide, reverse inspiratory:expiratory ratio ventilation strategies, airway pressure ventilation, partial liquid ventilation, or high-frequency ventilation techniques. Additionally, the use of extracorporeal support is now starting to be used more commonly. Extracorporeal technology may benefit this patient population by facilitating

gas exchange without the harm associated with aggressive mechanical ventilation. Extracorporeal life support is a modified form of cardiopulmonary bypass used to provide prolonged gas exchange in patients with respiratory and/or cardiac failure. The devices require fairly large cannulas for continuous pumping of blood from the patient to a membrane oxygenator. In addition to oxygenation, CO₂ can be efficiently removed with extracorporeal technology. A major limitation of this complicated form of intensive care is the need for anticoagulation to prevent blood clotting.

Extracorporeal membrane oxygenation in ARDS

In 1972, Hill *et al.* published the first case report that used ECMO in a patient who suffered from ARDS due to acute post-traumatic respiratory failure. At that time, mortality rates from ARDS were exceedingly high, and the idea of extracorporeal support in this population showed great promise.^[18] However, a randomized controlled trial using ECMO in ARDS demonstrated mortality rates of >90% in both treatment arms.^[19] Although this was a landmark paper by Zapol *et al.*^[19] at that time, it suffered from significant flaws, including the use of only veno-arterial (VA) ECMO, termination of ECMO after 5 days was an option if no improvement occurred, significant problems with bleeding, the lack of “rest” ventilator settings, and the lack of experience of many participating centers. Despite these dismal results, several investigators continued to work in the area of extracorporeal devices and strategies. Extracorporeal CO₂ removal paired with a novel ventilation strategy at that time, low-frequency positive pressure mechanical ventilation, demonstrated some improvement in results.^[20-23] However, a randomized controlled trial failed to demonstrate an actual survival benefit from extracorporeal CO₂ removal in ARDS, although the survival rates were substantially improved as compared to the 1970s.^[24] Survival rates were 33% for the extracorporeal group and 42% for the conventional mechanical ventilation group.^[24] The investigators were unable to show a survival benefit as the cohort study was small ($n = 40$) compared to the ARDS network trial on low tidal volumes that stopped recruitment after enrolling 861 patients.

Early poor outcomes with extracorporeal membrane oxygenation in ARDS

The lack of any substantial impact upon mortality in these early studies with extracorporeal CO₂ removal in ARDS is multifactorial. Early extracorporeal CO₂ devices were limited in their technology. In addition, ventilation strategies differed substantially at that time compared to today where low tidal volumes and airway pressure gradients are now used for protective ventilation.^[10,11,25,26]

Extracorporeal devices continue to be used more frequently than ever before in intensive care units throughout the world. With advancements in technology, the new devices are less prone to complications. In addition to technological progress, there has been improvement related to the clinical application of extracorporeal support devices in individual patients, including early introduction and strategies for changing from devices as clinically indicated.^[27,28]

Recent outcomes with ECMO in ARDS

The recent report of successful ECMO support in older patients inflicted with H1N1 influenza increased interests in

the use of this mode of support in adult patients with severe respiratory failure.^[29] Also that same year, the conventional ventilatory support versus ECMO for severe adult respiratory failure (CESAR) study was published. The investigators used a “pragmatic” study design and were criticized for the inability to standardize mechanical ventilation management in the conventional care group.^[30] Importantly, the CESAR trial demonstrated that protocolized care that included ECMO in an expert center for ARDS care yielded higher survival than the best standard care in tertiary intensive care units in the UK.^[30]

Innovations in ECMO

In the 1960s, a milestone in the technological evolution of ECMO was the development of membrane oxygenators, which began replacing bubble oxygenators. Membrane oxygenators provided gas exchange with the benefits of increased short- and long-term biocompatibility. The recently developed membrane-type oxygenators were less harmful as blood was exposed to oxygen through a gas-permeable membrane, which enhanced gas transfer compared to the bubble oxygenators. At the end of the 1990s, a silicone covering of the microporous polypropylene hollow fibers was used that had a heat exchanger and oxygenating compartment with a polymethylpentene (PMP) membrane in a small polycarbonate shell.^[31] Development of the PMP oxygenator has proven to be an important advancement in ECMO technology as the PMP oxygenators have slowly replaced both the silicone membrane and polypropylene microporous oxygenators.^[32,33] The PMP oxygenators result in a reduction of the need for red blood cell and platelet transfusions, provide better gas exchange, have lower resistance and priming volumes compared to silicone membrane oxygenators, and have less oxygenator failure compared to polypropylene microporous oxygenators.^[34] The development of heparin-coated circuits allows for extracorporeal support with decreased platelet, complement, and granulocyte activation with reduced heparin requirements.^[35,36] New generation centrifugal pumps permit support with essentially no risk of tubing rupture with a smaller priming volume and potentially reduced need for a reservoir.^[37] Yet, another major innovation that has truly enhanced the capability of extracorporeal CO₂ removal was the development of a bicaval dual-lumen catheter (Avalon Laboratories, Rancho Dominguez, CA, USA) that allows respiratory support through a single catheter for application of ECMO.^[38]

Different modes of ECMO

In the setting of complete cardiopulmonary support, conventional VA ECMO is primarily used while primary respiratory failure, including severe oxygenation failure, is treated with veno-venous (VV) ECMO. Hypercapnic respiratory failure can be treated with either a VV or a VA approach. Both VV and VA approaches require a pump that is capable of generating flow rates of 3-5 l/min to assure sufficient organ perfusion and oxygenation in the adult size patient. Figure 1 illustrates the different cannulation strategies for the variable forms of ECMO support (VA, VV, and double lumen VV) currently used in patients. An arterio-venous (AV) approach can be used as well which does not require a pump. In specific circumstances, low-resistance devices can be used which allow sufficient blood flow driven by the systemic blood pressure from the patient. These pumpless extracorporeal lung assist (PECLA) devices achieve flow rates of 0.8-1.5 l/min allowing for sufficient CO₂ removal.

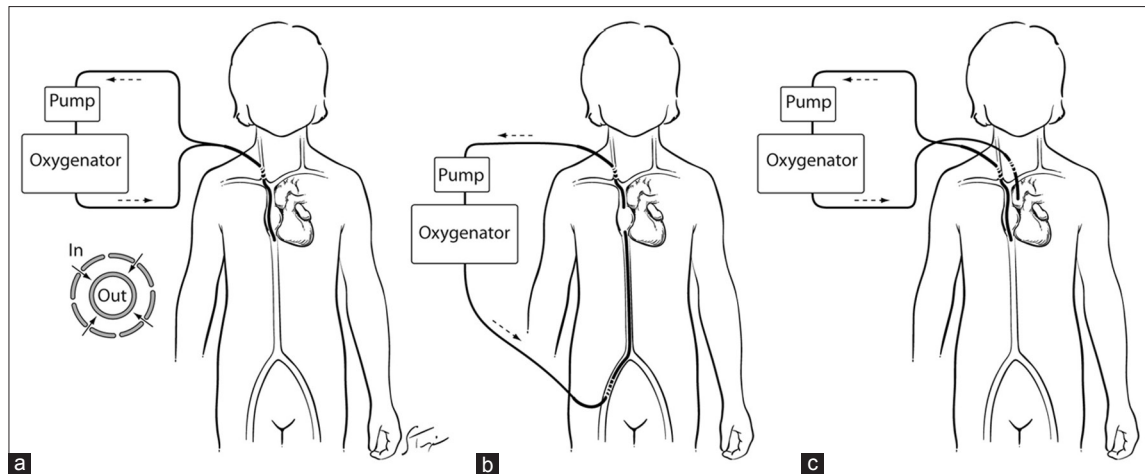


Figure 1: Three configurations of extracorporeal blood flow (a) single-site double lumen veno-venous (VV), (b) two-site VV, and (c) veno-arterial

Alternative extracorporeal devices

Arterio-venous CO_2 removal

An AV shunt for extracorporeal gas exchange can potentially reduce the complexity of conventional ECMO, while allowing for gas exchange to achieve near total removal of CO_2 . The technique of extracorporeal AV CO_2 removal (AV CO_2 R) was developed using a low-resistance, commercially available, hollow fiber gas exchanger to provide lung rest in the setting of severe respiratory failure.^[39] Although AV CO_2 R is efficient in CO_2 removal, it does not provide any substantial oxygen transfer. The initial human study with AV CO_2 R included five adult patients with ARDS and CO_2 retention with percutaneous AV CO_2 R achieving approximately 70% CO_2 removal in the cohort without hemodynamic compromise or instability, while oxygenation was successfully managed with gentle ventilation and near-apneic oxygenation.^[40] All of these patients survived the study period without adverse sequelae and only minor complications.^[40]

PECLA, Novalung®, and interventional lung assist (used interchangeably)

The early success of AV CO_2 R intensified the interest and increased the use of AV CO_2 R in Europe, which is termed PECLA, interventional lung assist (ILA) device, or Novalung® (Novalung GmbH, Talheim, Germany). These devices have a circuit that uses a hollow fiber gas exchanger without the need for a pump.

An *in vivo* study with an ovine model was undertaken to determine the efficacy of the Novalung® circuits in the short-term removal of CO_2 and to assess hemodynamic responses.^[41] The animal was cannulated in the jugular vein and carotid artery for 72 h.^[41] The Novalung® device provided near total CO_2 removal (mean: 119.3 ml/min) with device blood flow rates (Q_b), 1 l/min; sweep gas flow rates (Q_g), 5 l/min; and $P_a\text{CO}_2$, 40-50 mmHg.^[41] The $P_a\text{CO}_2$ level was also found to be directly proportional to the CO_2 clearance for the device.^[41] In another *in vivo* study with a pig model, ILA was studied to determine the device's ability to improve oxygenation with cannulation through both femoral arteries and one femoral vein with the animals anesthetized and mechanically ventilated.^[42] With the application of ILA, the arterial partial

pressure of oxygen was increased from 64 ± 13 mmHg to 71 ± 14 mmHg and 74 ± 17 mmHg with blood flow through one and two femoral arteries, respectively.^[42] The increase in oxygenation was small, but was significant; thus, the results indicated that ILA may not be warranted if oxygenation is the primary therapeutic goal.^[42] Two further studies demonstrated that the Novalung® device provided adequate gas exchange without hemodynamic instability with static ventilation at PEEP pressures ≥ 10 cm H_2O .^[43,44] A third animal study, using an ARDS model, was performed to prospectively evaluate the effects of ILA on hemodynamics and gas exchange in cardiopulmonary resuscitation.^[45] Ventricular fibrillation was induced in the lung injured, mechanically ventilated pig with chest compressions starting immediately and continuing for 30 min in the anesthetized animals.^[45] The experimental group (open ILA system) showed a marked decrease in $P_a\text{CO}_2$ and increase in $P_a\text{O}_2$ without a significant difference in systolic and mean blood pressure compared to the control group (clamped ILA system).^[45]

The Novalung® system has been investigated in Europe since 1996 and has been established as a therapeutic measure for a variety of lung conditions. In one study, the Novalung® was used easily and inexpensively used in 1,800 patients for artificial lung assistance.^[46] Furthermore, the PECLA device was effective at oxygenation and CO_2 removal in 70 patients with severe respiratory failure of various etiologies.^[47] A 10-year-review outlined experience in 159 patients ranging in age from 7 to 78 years who were treated with PECLA for ARDS (70.4%) and pneumonia (28.3%).^[48] The study had a cumulative experience of over 1,300 days.^[48] During the study period, the overall mortality was 48.7%, mostly attributed to multiorgan failure.^[48] Inability to stabilize pulmonary function was noted in only 3% of patients, and the 30-day mortality after PECLA was 13.6%.^[48] Numerous case reports, retrospective analyses, and prospective studies have validated the PECLA for use as a therapeutic measure for CO_2 removal in a wide variety of etiologies of acute respiratory failure including ARDS^[49-67] and as a bridge to lung transplantation.^[52-56] The PECLA system has been proven to be superior to lung assist devices that require a pump because it significantly reduces bleeding, hemolysis, and mechanical trauma to the blood.

A multitude of studies have demonstrated that the Novalung® facilitates the reversal of hypercapnia, while stabilizing oxygenation with the only reported complication being reversible distal limb ischemia.^[68-80] In a large cohort study with 96 patients with severe ARDS, the application of ILA significantly increased the P_aO_2/FiO_2 ratio, while improving the P_aCO_2 and pH within 2 h in all patients.^[81] The ILA eliminated approximately 50% of calculated total CO_2 produced with rapid normalization of respiratory acidosis.^[81]

Despite extensive study, the main disadvantages of ILA are arterial damage, immobilization, and cardiovascular steal. Therefore, newer technology was needed and has continued to evolve with the most device released being ILA activve® (Novalung GmbH, Talheim, Germany).

Intravenacaval (intravascular) oxygenator and CO_2 removal device
Mortensen developed the concept of an intravenacaval (intravascular) oxygenator and CO_2 removal device (IVOX) as an intracorporeal gas exchange device in patients with ARDS.^[82,83] The components of IVOX include multiple hollow fibers, that are silicone coated and heparin bonded, to create a thin membrane, which are then placed in the vena cava to provide blood oxygenation and CO_2 removal, without the need for extracorporeal circulation or blood transfusion. The fibers join together in a manifold that communicates with the dual-lumen gas conduit at both the proximal and distal ends.

In animal models, implantation of the IVOX device did not adversely affect hemodynamic function and there was no evidence of significant hemolysis, thromboembolism, foaming in the blood, catheter migration, or vena caval intimal injury.^[84-87] In the initial design, the IVOX was capable of removing up to 30% of CO_2 production in an ovine model (normal: 150-180 ml/min) of severe smoke inhalation injury.^[84] The IVOX device was easy to use, but generated somewhat variable results, for instance when there were changes in cardiac output, instability in metabolism, or compensation in respiration. The IVOX device has had limited capacity in comparison to natural lungs.^[87] The IVOX device in animal and human studies has demonstrated an average of 40 ml/min of CO_2 removal and oxygen exchange, approximately 25-30% of the metabolic demands of the patients implanted with the device.^[85,86] The end result was that IVOX could not be recommended as an alternative for ECMO or provide total support for patients with acute respiratory failure.

An international multicenter Phase I-II clinical trial of IVOX with a total of 164 IVOX devices used in 160 patients with acute respiratory failure, due to a variety of causes (lung infection, trauma, sepsis, and ARDS), found an immediate improvement in blood gas findings in a majority of patients, which allowed for a reduction in ventilator settings.^[88] The overall survival of patients who were treated with the IVOX device was only 30% and was directly related to the severity of lung injury and patient selection. Device complications included mechanical and/or performance problems and user errors, whereas patient complications included bleeding, thrombosis, infection, venous occlusion, and arrhythmias.^[88] Due to these experiences with IVOX, significant improvements are needed in the design and engineering of the device in order for it to become more clinically applicable.

Intravascular lung assist device

The intravascular lung assist device (ILAD) was designed by placing the membrane fibers into sub-units of rosette-like layers, with a surface area of 0.4-0.6 m² perpendicular to blood flow with the same intravascular placement.^[89] The device achieved 100 ml/min of both oxygen and CO_2 exchange, but the blood pressure gradient required to overcome the resistance of the device to attain this gas exchange was high (23-105 mmHg). Further attempts were unsuccessful with the fibers in a helical form.^[90] Unlike conventional devices which depend on passive bulk blood flow around them, this “pumping” ILAD causes an active driving force for the blood when rotated.

Hattler respiratory assist catheter

The Hattler respiratory assist catheter incorporates a small pulsating balloon into the middle of a hollow fiber bundle. Functioning characteristics of the device have been studied *in vivo* and *in vitro* studies.^[91] The balloon allows for convective mixing of the blood and thus increases gas exchange. A larger balloon volume and higher pulsation rate have been shown to increase both oxygen loading and CO_2 removal in a linear fashion in an *in vitro* model.^[91] In another study, application of a random balloon pulsation did not significantly impact gas exchange within the respiratory assist catheter.^[92] Despite these advances, the clinical use of an intravenous respiratory assist device is impeded by the insertion diameter of the catheter due to the catheter being dependent upon the critical number of hollow fiber membranes necessary to achieve gas exchange. The current catheters being prepared for human clinical trials require an insertion size of 32 Fr, even with optimal gas exchange efficiency of the pulsating balloon. Therefore, efforts are moving forward with the development of an impeller percutaneous respiratory assist catheters (iPRAC) with an insertion size <25 Fr.^[93] The limitation to the clinical application of this sort of a catheter is the ability to protect the vascular endothelium from rotating fibers.

The latest concept in respiratory assist catheters is the development of iPRAC. The new design incorporates rotating impellers within a stationary bundle of hollow fiber membranes. Active mixing by rotating impellers produced 70% higher gas exchange efficiency than pulsating balloon catheters.^[94] The iPRAC catheter has a diameter of 25 Fr and surface area of 0.07 m² with no adverse effects on hemodynamic function in laboratory animals. Even though the CO_2 removal efficiency of the iPRAC is currently the highest of any respiratory assist catheter, improvements are still needed before it can be used as a clinical device. Future studies will need to address optimal blood flow and gas exchange through the catheter and long-term efficacy of CO_2 removal while assessing novel hollow fiber membrane coatings to facilitate additional CO_2 removal.^[94]

Decap and hemolung respiratory assist system®

More recently, the modification of a continuous VV hemodialysis machine was introduced that solely performs decapneization (CO_2 removal) in conjunction with hemofiltration in a system called DECAP/DECAPsmart (Medica S.p.A., Medolla, Italy).^[95] For intravascular access, a single double lumen cannula is inserted into the femoral vein with blood flow achieved by a non-occlusive roller pump with blood circulating through a membrane oxygenator then a hemofilter. Although this system does not allow for total gas exchange, it may augment

CO₂ removal that would further permit reduction of minute ventilation. Extracorporeal CO₂ removal devices have been used in a Phase II study supporting the use of this technology in patients with severe ARDS who fail a trial of protective ventilation.^[96] Similar dialysis-like systems are infiltrating the market now, including the Hemolung Respiratory Assist System® (ALung Technologies, Inc., Pittsburgh, PA, USA).

Clinical indications of ECMO

Figure 2 illustrates three key components of an ECMO circuit: The oxygenator, better bladder (venous compliance chamber) if used, and bubble detector. The oxygenator facilitates gas exchange and the better bladder controls pump flow as a function of inlet pressure, while bubble detection is a vital preventative measure. Guidelines describing indications and the practice of ECMO are published by the Extracorporeal Life Support Organization.^[97] The generally accepted criterion for the initiation of ECMO is either acute severe cardiac or pulmonary failure or combination of both that is potentially reversible and unresponsive to conventional management. Examples of these clinical situations include the following etiologies: Hypoxic respiratory failure with a ratio of arterial oxygen tension to fraction of inspired oxygen (PaO₂/FiO₂) <100 mmHg despite optimal settings on mechanical ventilation, hypercapnic respiratory failure with an arterial pH < 7.20, refractory cardiogenic shock, cardiac arrest, failure to wean from cardiopulmonary bypass after cardiac surgery, and as a bridge to either heart or lung transplantation. Depending on the clinical situation, ECMO can even be implemented at the bedside of a patient [Figure 3].

Clinically, VA ECMO provides complete cardiorespiratory support by extracting blood from the right atrium and returning it to the arterial system, therefore bypassing the heart and lungs. Contrasted to a VV approach, blood is extracted with VV ECMO from the vena cava or right atrium and returned to the right atrium with the patient still dependent on their intrinsic biventricular cardiac performance for hemodynamic support. Characteristically, VA ECMO is used for cardiac or combined cardiopulmonary failure, and VV ECMO is used for respiratory failure. The results of VV ECMO support for respiratory failure are similar to outcomes compared to VA ECMO, but with less morbidity secondary to improved neurological outcomes and preservation of arterial blood vessels.^[98-102]

As discussed earlier, the development of a bicaval dual-lumen catheter (Avalon Laboratories, Rancho Dominguez, CA, USA) allows for respiratory support via application of ECMO through a single catheter site.^[38] The catheter is inserted from the right jugular vein into the superior vena cava, traversing the right atrium to the inferior vena cava where it drains venous blood from both the superior and inferior vena cava and then directs oxygenated blood into the right atrium toward the tricuspid valve. The single site application of this method of VV ECMO in the neck permits ambulation and oral nutrition and has been used in patients as a bridge awaiting lung transplantation.^[103-106] The theory behind this methodology of ambulatory ECMO [Figure 4] in patients with advanced lung disease requiring lung transplantation is to optimize both physical rehabilitation and nutrition prior to lung transplantation. To our knowledge, the use of ambulatory ECMO has not been attempted in ARDS, but the use of a simple circuit with the capability of total or near-total gas exchange

should be considered in this population and may be a potential therapeutic option to liberate ARDS patients from mechanical ventilation.




Figure 2: An extracorporeal membrane oxygenation circuit with the oxygenator, better bladder, and bubble detector

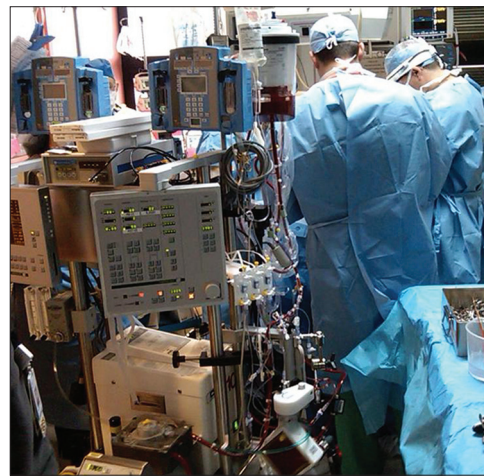


Figure 3: Implementation of veno-arterial extracorporeal membrane oxygenation at the bedside of a patient

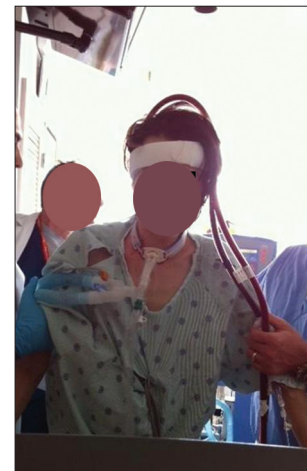

Figure 4: Ambulatory extracorporeal membrane oxygenation with single-site double lumen veno-venous approach being used in a patient as a bridge for lung transplantation

Conclusions

Extracorporeal treatment modalities are showing promise in the management of ARDS and are being increasingly used in intensive care units as rescue therapies in patients with ARDS who fail to respond to conventional mechanical ventilation. Patient selection and timing of the application of the extracorporeal device continue to be very important determining factors in the eventual outcome. The technology of the current devices is slowly evolving into smaller systems and will likely continue to shrink in size. As the risk of these devices decreases, their role in ARDS may increase but continues to not be well defined presently with further research needed in this patient population.

References

- Ashbaugh DG, Bigelow DB, Petty TL, Levine BE. Acute respiratory distress in adults. *Lancet* 1967;2:319-23.
- Rubinfeld GD, Caldwell E, Peabody E, Weaver J, Martin DP, Neff M, et al. Incidence and outcomes of acute lung injury. *N Engl J Med* 2005;353:1685-93.
- Milberg JA, Davis DR, Steinberg KP, Hudson LD. Improved survival of patients with acute respiratory distress syndrome (ARDS): 1983-1993. *JAMA* 1995;273:306-9.
- Stapleton RD, Wang BM, Hudson LD, Rubinfeld GD, Caldwell ES, Steinberg KP. Causes and timing of death in patients with ARDS. *Chest* 2005;128:525-32.
- Zamboni M, Vincent JL. Mortality rates for patients with acute lung injury/ARDS have decreased over time. *Chest* 2008;133:1120-7.
- Erickson SE, Martin GS, Davis JL, Matthay MA, Eisner MD. NIH NHLBI ARDS Network. Recent trends in acute lung injury mortality: 1996-2005. *Crit Care Med* 2009;37:1574-9.
- Wheeler AP, Bernard GR, Thompson BT, Schoenfeld D, Wiedemann HP, deBoisblanc B, et al. National Heart, Lung, and Blood Institute Acute Respiratory Distress Syndrome (ARDS) Clinical Trials Network. Pulmonary-artery versus central venous catheter to guide treatment of acute lung injury. *N Engl J Med* 2006;354:2213-24.
- Wiedemann HP, Wheeler AP, Bernard GR, Thompson BT, Hayden D, deBoisblanc B, et al. National Heart, Lung, and Blood Institute Acute Respiratory Distress Syndrome (ARDS) Clinical Trials Network. Comparison of two fluid-management strategies in acute lung injury. *N Engl J Med* 2006;354:2564-75.
- Vincent JL, Sakr Y, Groeneveld J, Zandstra DF, Hoste E, Malledant Y, et al. ARDS of early or late onset: Does it make a difference? *Chest* 2010;137:81-7.
- Ventilation with lower tidal volumes as compared with traditional tidal volumes for acute lung injury and the acute respiratory distress syndrome. The acute respiratory distress syndrome network. *N Engl J Med* 2000;342:1301-8.
- Amato MB, Barbas CS, Medeiros DM, Magaldi RB, Schettino GP, Lorenzi-Filho G, et al. Effect of a protective-ventilation strategy on mortality in the acute respiratory distress syndrome. *N Engl J Med* 1998;338:347-54.
- Brochard L, Roudot-Thoraval F, Roupie E, Delclaux C, Chastre J, Fernandez-Mondéjar E, et al. Tidal volume reduction for prevention of ventilator-induced lung injury in acute respiratory distress syndrome. The multicenter trial group on tidal volume reduction in ARDS. *Am J Respir Crit Care Med* 1998;158:1831-8.
- Hickling KG, Henderson SJ, Jackson R. Low mortality associated with low volume pressure limited ventilation with permissive hypercapnia in severe adult respiratory distress syndrome. *Intensive Care Med* 1990;16:372-7.
- Stewart TE, Meade MO, Cook DJ, Granton JT, Hodder RV, Lapinsky SE, et al. Evaluation of a ventilation strategy to prevent barotrauma in patients at high risk for acute respiratory distress syndrome. Pressure- and volume-limited ventilation strategy group. *N Engl J Med* 1998;338:355-61.
- Phua J, Badia JR, Adhikari NK, Friedrich JO, Fowler RA, Singh JM, et al. Has mortality from acute respiratory distress syndrome decreased over time?: A systematic review. *Am J Respir Crit Care Med* 2009;179:220-7.
- Bidani A, Tzouanakis AE, Cardenas VJ Jr, Zwischenberger JB. Permissive hypercapnia in acute respiratory failure. *JAMA* 1994;272:957-62.
- Cardenas VJ Jr, Zwischenberger JB, Tao W, Nguyen PD, Schroeder T, Traber LD, et al. Correction of blood pH attenuates changes in hemodynamics and organ blood flow during permissive hypercapnia. *Crit Care Med* 1996;24:827-34.
- Hill JD, O'Brien TG, Murray JJ, Dontigny L, Bramson ML, Osborn JJ, et al. Prolonged extracorporeal oxygenation for acute post-traumatic respiratory failure (shock-lung syndrome). Use of the Bramson membrane lung. *N Engl J Med* 1972;286:629-34.
- Zapol WM, Snider MT, Hill JD, Fallat RJ, Bartlett RH, Edmunds LH, et al. Extracorporeal membrane oxygenation in severe acute respiratory failure. A randomized prospective study. *JAMA* 1979;242:2193-6.
- Gattinoni L, Kolobow T, Tomlinson T, Iapichino G, Samaja M, White D, et al. Low-frequency positive pressure ventilation with extracorporeal carbon dioxide removal (LFPPV-ECCO2R): An experimental study. *Anesth Analg* 1978;57:470-7.
- Gattinoni L, Kolobow T, Agostoni A, Damia G, Pelizzola A, Rossi GP, et al. Clinical application of low frequency positive pressure ventilation with extracorporeal CO2 removal (LFPPV-ECCO2R) in treatment of adult respiratory distress syndrome (ARDS). *Int J Artif Organs* 1979;2:282-3.
- Gattinoni L, Agostoni A, Damia G, Cantaluppi D, Bernasconi C, Tarenzi L, et al. Hemodynamics and renal function during low frequency positive pressure ventilation with extracorporeal CO2 removal. A comparison with continuous positive pressure ventilation. *Intensive Care Med* 1980;6:155-61.
- Gattinoni L, Pesenti A, Pelizzola A, Caspani ML, Iapichino G, Agostoni A, et al. Reversal of terminal acute respiratory failure by low frequency positive pressure ventilation with extracorporeal removal of CO2 (LFPPV-ECCO2R). *Trans Am Soc Artif Intern Organs* 1981;27:289-93.
- Morris AH, Wallace CJ, Menlove RL, Clemmer TP, Orme JF Jr, Weaver LK, et al. Randomized clinical trial of pressure-controlled inverse ratio ventilation and extracorporeal CO2 removal for adult respiratory distress syndrome. *Am J Respir Crit Care Med* 1994;149:295-305.
- Villar J, Kacmarek RM, Pérez-Méndez L, Aguirre-Jaime A. A high positive end-expiratory pressure, low tidal volume ventilatory strategy improves outcome in persistent acute respiratory distress syndrome: A randomized, controlled trial. *Crit Care Med* 2006;34:1311-8.
- Zimmermann M, Bein T, Arlt M, Philipp A, Rupprecht L, Mueller T, et al. Pumpless extracorporeal interventional lung assist in patients with acute respiratory distress syndrome: A prospective pilot study. *Crit Care* 2009;13:R10.
- Oshima K, Kunimoto F, Hinohara H, Okawa M, Mita N, Kanamaru Y, et al. Evaluation of prognosis in patients with respiratory failure requiring venovenous extracorporeal membrane oxygenation (ECMO). *Ann Thorac Cardiovasc Surg* 2010;16:156-62.
- Floerchinger B, Philipp A, Foltan M, Rupprecht L, Klose A, Camboni D, et al. Switch from venoarterial extracorporeal membrane oxygenation to arteriovenous pumpless extracorporeal lung assist. *Ann Thorac Surg* 2010;89:125-31.
- Davies A, Jones D, Bailey M, Beca J, Bellomo R, Blackwell N, et al. Australia and New Zealand Extracorporeal Membrane Oxygenation (ANZ ECMO) Influenza Investigators. Extracorporeal

- membrane oxygenation for 2009 influenza A (H1N1) acute respiratory distress syndrome. *JAMA* 2009;302:1888-95.
30. Peek GJ, Mugford M, Tiruvoipati R, Wilson A, Allen E, Thalanany MM, et al. Efficacy and economic assessment of conventional ventilatory support versus extracorporeal membrane oxygenation for severe adult respiratory failure (CESAR): A multicentre randomised controlled trial. *Lancet* 2009;374:1351-63.
 31. Mueller XM, Marty B, Tevæarai HT, Tozzi P, Jegger D, von Segesser LK. A siliconized hollow fiber membrane oxygenator. *ASAIO J* 2000;46:38-41.
 32. Lawson DS, Lawson AF, Walczak R, McRobb C, McDermott P, Shearer IR, et al. North American neonatal extracorporeal membrane oxygenation (ECMO) devices and team roles: 2008 survey results of Extracorporeal Life Support Organization (ELSO) centers. *J Extra Corpor Technol* 2008;40:166-74.
 33. Peek GJ, Killer HM, Reeves R, Sosnowski AW, Firmin RK. Early experience with a polymethyl pentene oxygenator for adult extracorporeal life support. *ASAIO J* 2002;48:480-2.
 34. Khoshbin E, Roberts N, Harvey C, Machin D, Killer H, Peek GJ, et al. Poly-methyl pentene oxygenators have improved gas exchange capability and reduced transfusion requirements in adult extracorporeal membrane oxygenation. *ASAIO J* 2005;51:281-7.
 35. Moen O, Fosse E, Dregelid E, Brockmeier V, Andersson C, Høgåsen K, et al. Centrifugal pump and heparin coating improves cardiopulmonary bypass biocompatibility. *Ann Thorac Surg* 1996;62:1134-40.
 36. Fosse E, Moen O, Johnson E, Semb G, Brockmeier V, Mollnes TE, et al. Reduced complement and granulocyte activation with heparin-coated cardiopulmonary bypass. *Ann Thorac Surg* 1994;58:472-7.
 37. Lawson DS, Ing R, Cheifetz IM, Walczak R, Craig D, Schulman S, et al. Hemolytic characteristics of three commercially available centrifugal blood pumps. *Pediatr Crit Care Med* 2005;6:573-7.
 38. Bermudez CA, Rocha RV, Sappington PL, Toyoda Y, Murray HN, Boujoukos AJ. Initial experience with single cannulation for venovenous extracorporeal oxygenation in adults. *Ann Thorac Surg* 2010;90:991-5.
 39. Brunston RL Jr, Zwischenberger JB, Tao W, Cardenas VJ Jr, Traber DL, Bidani A. Total arteriovenous CO₂ removal: Simplifying extracorporeal support for respiratory failure. *Ann Thorac Surg* 1997;64:1599-604.
 40. Zwischenberger JB, Conrad SA, Alpard SK, Grier LR, Bidani A. Percutaneous extracorporeal arteriovenous CO₂ removal for severe respiratory failure. *Ann Thorac Surg* 1999;68:181-7.
 41. Zhou X, Loran DB, Wang D, Hyde BR, Lick SD, Zwischenberger JB. Seventy-two hour gas exchange performance and hemodynamic properties of NOVALUNG iLA as a gas exchanger for arteriovenous carbon dioxide removal. *Perfusion* 2005;20:303-8.
 42. Zick G, Frerichs I, Schädler D, Schmitz G, Pulletz S, Cavus E, et al. Oxygenation effect of interventional lung assist in a lavage model of acute lung injury: A prospective experimental study. *Crit Care* 2006;10:R56.
 43. Nielsen ND, Kjaergaard B, Koefoed-Nielsen J, Steensen CO, Larsson A. Apneic oxygenation combined with extracorporeal arteriovenous carbon dioxide removal provides sufficient gas exchange in experimental lung injury. *ASAIO J* 2008;54:401-5.
 44. Jungebluth P, Iglesias M, Go T, Sibila O, Macchiarini P. Optimal positive end-expiratory pressure during pumpless extracorporeal lung membrane support. *Artif Organs* 2008;32:885-90.
 45. Zick G, Schädler D, Elke G, Pulletz S, Bein B, Scholz J, et al. Effects of interventional lung assist on haemodynamics and gas exchange in cardiopulmonary resuscitation: A prospective experimental study on animals with acute respiratory distress syndrome. *Crit Care* 2009;13:R17.
 46. Walles T. Clinical experience with the iLA membrane ventilator pumpless extracorporeal lung-assist device. *Expert Rev Med Devices* 2007;4:297-305.
 47. Liebold A, Philipp A, Kaiser M, Merk J, Schmid FX, Birnbaum DE. Pumpless extracorporeal lung assist using an arterio-venous shunt. Applications and limitations. *Minerva Anestesiol* 2002;68:387-91.
 48. Flörchinger B, Philipp A, Klose A, Hilker M, Kobuch R, Rupprecht L, et al. Pumpless extracorporeal lung assist: A 10-year institutional experience. *Ann Thorac Surg* 2008;86:410-7.
 49. Kopp R, Dembinski R, Kuhlen R. Role of extracorporeal lung assist in the treatment of acute respiratory failure. *Minerva Anestesiol* 2006;72:587-95.
 50. Iglesias M, Martinez E, Badia JR, Macchiarini P. Extrapulmonary ventilation for unresponsive severe acute respiratory distress syndrome after pulmonary resection. *Ann Thorac Surg* 2008;85:237-44.
 51. Iglesias M, Jungebluth P, Petit C, Matute MP, Rovira I, Martínez E, et al. Extracorporeal lung membrane provides better lung protection than conventional treatment for severe postpneumonectomy noncardiogenic acute respiratory distress syndrome. *J Thorac Cardiovasc Surg* 2008;135:1362-71.
 52. Fischer S, Simon AR, Welte T, Hoepfer MM, Meyer A, Tessmann R, et al. Bridge to lung transplantation with the novel pumpless interventional lung assist device NovaLung. *J Thorac Cardiovasc Surg* 2006;131:719-23.
 53. Strueber M, Hoepfer MM, Fischer S, Cypel M, Warnecke G, Gottlieb J, et al. Bridge to thoracic organ transplantation in patients with pulmonary arterial hypertension using a pumpless lung assist device. *Am J Transplant* 2009;9:853-7.
 54. Taylor K, Holtby H. Emergency interventional lung assist for pulmonary hypertension. *Anesth Analg* 2009;109:382-5.
 55. Ricci D, Boffini M, Del Sorbo L, El Qarra S, Comoglio C, Ribezzo M, et al. The use of CO₂ removal devices in patients awaiting lung transplantation: An initial experience. *Transplant Proc* 2010;42:1255-8.
 56. Haneya A, Philipp A, Mueller T, Lubnow M, Pfeifer M, Zink W, et al. Extracorporeal circulatory systems as a bridge to lung transplantation at remote transplant centers. *Ann Thorac Surg* 2011;91:250-5.
 57. Zimmermann M, Bein T, Philipp A, Ittner K, Foltan M, Drescher J, et al. Interhospital transportation of patients with severe lung failure on pumpless extracorporeal lung assist. *Br J Anaesth* 2006;96:63-6.
 58. Elliot SC, Paramasivam K, Oram J, Bodenham AR, Howell SJ, Mallick A. Pumpless extracorporeal carbon dioxide removal for life-threatening asthma. *Crit Care Med* 2007;35:945-8.
 59. Mallick A, Elliot S, McKinlay J, Bodenham A. Extracorporeal carbon dioxide removal using the Novalung in a patient with intracranial bleeding. *Anaesthesia* 2007;62:72-4.
 60. Twigg S, Gibbon GJ, Perris T. The use of extracorporeal carbon dioxide removal in the management of life-threatening bronchospasm due to influenza infection. *Anaesth Intensive Care* 2008;36:579-81.
 61. Renner A, Neukam K, Rösner T, Elert O, Lange V. Pumpless extracorporeal lung assist as supportive therapy in a patient with diffuse alveolar hemorrhage. *Int J Artif Organs* 2008;31:279-81.
 62. McKinlay J, Chapman G, Elliot S, Mallick A. Pre-emptive Novalung-assisted carbon dioxide removal in a patient with chest, head and abdominal injury. *Anaesthesia* 2008;63:767-70.
 63. Haneya A, Philipp A, Foltan M, Mueller T, Camboni D, Rupprecht L, et al. Extracorporeal circulatory systems in the interhospital transfer of critically ill patients: Experience of a single institution. *Ann Saudi Med* 2009;29:110-4.
 64. Freed DH, Henzler D, White CW, Fowler R, Zarychanski R, Hutchison J, et al. Extracorporeal lung support for patients who had severe respiratory failure secondary to influenza A (H1N1) 2009 infection in Canada. *Can J Anaesth* 2010;57:240-7.

65. Meyer AL, Strueber M, Tomaszek S, Goerler A, Simon AR, Haverich A, et al. Temporary cardiac support with a mini-circuit system consisting of a centrifugal pump and a membrane ventilator. *Interact Cardiovasc Thorac Surg* 2009;9:780-3.
66. Wiebe K, Poeling J, Arlt M, Philipp A, Camboni D, Hofmann S, et al. Thoracic surgical procedures supported by a pumpless interventional lung assist. *Ann Thorac Surg* 2010;89:1782-7.
67. Floerchinger B, Philipp A, Foltan M, Rupperecht L, Klose A, Camboni D, et al. Switch from venoarterial extracorporeal membrane oxygenation to arteriovenous pumpless extracorporeal lung assist. *Ann Thorac Surg* 2010;89:125-31.
68. Reng M, Philipp A, Kaiser M, Pfeifer M, Gruene S, Schoelmerich J. Pumpless extracorporeal lung assist and adult respiratory distress syndrome. *Lancet* 2000;356:219-20.
69. Grubitzsch H, Beholz S, Wollert HG, Eckel L. Pumpless arteriovenous extracorporeal lung assist: What is its role? *Perfusion* 2000;15:237-42.
70. Liebold A, Reng CM, Philipp A, Pfeifer M, Birnbaum DE. Pumpless extracorporeal lung assist-Experience with the first 20 cases. *Eur J Cardiothorac Surg* 2000;17:608-13.
71. Bein T, Scherer MN, Philipp A, Weber F, Woertgen C. Pumpless extracorporeal lung assist (pECLA) in patients with acute respiratory distress syndrome and severe brain injury. *J Trauma* 2005;58:1294-7.
72. Ruettimann U, Ummerhofer W, Rueter F, Pargger H. Management of acute respiratory distress syndrome using pumpless extracorporeal lung assist. *Can J Anaesth* 2006;53:101-5.
73. von Mach MA, Kaes J, Omogbehin B, Sagoschen I, Wiechelt J, Kaiser K, et al. An update on interventional lung assist devices and their role in acute respiratory distress syndrome. *Lung* 2006;184:169-75.
74. Zimmermann M, Philipp A, Schmid FX, Dorlac W, Arlt M, Bein T. From Baghdad to Germany: Use of a new pumpless extracorporeal lung assist system in two severely injured US soldiers. *ASAIO J* 2007;53:e4-6.
75. Muellenbach RM, Wunder C, Nuechter DC, Smul T, Trautner H, Kredel M, et al. Early treatment with arteriovenous extracorporeal lung assist and high-frequency oscillatory ventilation in a case of severe acute respiratory distress syndrome. *Acta Anaesthesiol Scand* 2007;51:766-9.
76. Muellenbach RM, Kredel M, Wunder C, Küstermann J, Wurmb T, Schwemmer U, et al. Arteriovenous extracorporeal lung assist as integral part of a multimodal treatment concept: A retrospective analysis of 22 patients with ARDS refractory to standard care. *Eur J Anaesthesiol* 2008;25:897-904.
77. Hommel M, Deja M, von Dossow V, Diemel K, Heidenhain C, Spies C, et al. Bronchial fistulae in ARDS patients: Management with an extracorporeal lung assist device. *Eur Respir J* 2008;32:1652-5.
78. Weber-Carstens S, Bercker S, Hommel M, Deja M, MacGuill M, Dreykluft C, et al. Hypercapnia in late-phase ALI/ARDS: Providing spontaneous breathing using pumpless extracorporeal lung assist. *Intensive Care Med* 2009;35:1100-5.
79. Zimmermann M, Bein T, Arlt M, Philipp A, Rupperecht L, Mueller T, et al. Pumpless extracorporeal interventional lung assist in patients with acute respiratory distress syndrome: A prospective pilot study. *Crit Care* 2009;13:R10.
80. Bein T, Zimmermann M, Hergeth K, Ramming M, Rupperecht L, Schlitt HJ, et al. Pumpless extracorporeal removal of carbon dioxide combined with ventilation using low tidal volume and high positive end-expiratory pressure in a patient with severe acute respiratory distress syndrome. *Anaesthesia* 2009;64:195-8.
81. Müller T, Lubnow M, Philipp A, Bein T, Jeron A, Luchner A, et al. Extracorporeal pumpless interventional lung assist in clinical practice: Determinants of efficacy. *Eur Respir J* 2009;33:551-8.
82. Mortensen JD. An intravenacaval blood gas exchange (IVCBGE) device. A preliminary report. *ASAIO Trans* 1987;33:570-3.
83. Mortensen JD, Berry G. Conceptual and design features of a practical, clinically effective intravenous mechanical blood oxygen/carbon dioxide exchange device (IVOX). *Int J Artif Organs* 1989;12:384-9.
84. Zwischenberger JB, Cox CS, Graves D, Bidani A. Intravascular membrane oxygenation and carbon dioxide removal: A new application for permissive hypercapnia? *Thorac Cardiovasc Surg* 1992;40:115-20.
85. Cox CS Jr, Zwischenberger JB, Traber LD, Traber DL, Herndon DN. Use of an intravascular oxygenator/carbon dioxide removal device in an ovine smoke inhalation injury model. *ASAIO Trans* 1991;37:M411-3.
86. Zwischenberger JB, Cox CS Jr. A new intravascular membrane oxygenator to augment blood gas transfer in patients with acute respiratory failure. *Tex Med* 1991;87:60-3.
87. Cox CS Jr, Zwischenberger JB, Graves DF, Niranjan SC, Bidani A. Intracorporeal CO₂ removal and permissive hypercapnia to reduce airway pressure in acute respiratory failure. The theoretical basis for permissive hypercapnia with IVOX. *ASAIO J* 1993;39:97-102.
88. Conrad SA, Bagley A, Bagley B, Schaap RN. Major findings from the clinical trials of the intravascular oxygenator. *Artif Organs* 1994;18:846-63.
89. Vaslef SN, Mockros LF, Anderson RW. Development of an intravascular lung assist device. *ASAIO Trans* 1989;35:660-4.
90. Makarewicz AJ, Mockros LF, Anderson RW. A pumping intravascular artificial lung with active mixing. *ASAIO J* 1993;39:M466-9.
91. Hattler BG, Lund LW, Golob J, Russian H, Lann MF, Merrill TL, et al. A respiratory gas exchange catheter: *In vitro* and *in vivo* tests in large animals. *J Thorac Cardiovasc Surg* 2002;124:520-30.
92. Eash HJ, Budilarto SG, Hattler BG, Federspiel WJ. Investigating the effects of random balloon pulsation on gas exchange in a respiratory assist catheter. *ASAIO J* 2006;52:192-5.
93. Eash HJ, Mihelc KM, Frankowski BJ, Hattler BG, Federspiel WJ. Evaluation of fiber bundle rotation for enhancing gas exchange in a respiratory assist catheter. *ASAIO J* 2007;53:368-73.
94. Mihelc KM, Frankowski BJ, Lieber SC, Moore ND, Hattler BG, Federspiel WJ. Evaluation of a respiratory assist catheter that uses an impeller within a hollow fiber membrane bundle. *ASAIO J* 2009;55:569-74.
95. Gramaticopolo S, Chronopoulos A, Piccinni P, Nalesso F, Brendolan A, Zanella M, et al. Extracorporeal CO₂ removal: A way to achieve ultraprotective mechanical ventilation and lung support: The missing piece of multiple organ support therapy. *Contrib Nephrol* 2010;165:174-84.
96. Terragni PP, Del Sorbo L, Mascia L, Urbino R, Martin EL, Birocco A, et al. Tidal volume lower than 6 ml/kg enhances lung protection: Role of extracorporeal carbon dioxide removal. *Anesthesiology* 2009;111:826-35.
97. ELSO General Guidelines, 2009. Available from: <http://www.else.med.umich.edu/WordForms/ELSO%20Guidelines%20General%20All%20ECLS%20Version1.1.pdf>. [Last accessed on 2012 Oct 1].
98. Lindén V, Palmér K, Reinhard J, Westman R, Ehrén H, Granholm T, et al. High survival in adult patients with acute respiratory distress syndrome treated by extracorporeal membrane oxygenation, minimal sedation, and pressure supported ventilation. *Intensive Care Med* 2000;26:1630-7.
99. Kugelman A, Gangitano E, Pincros J, Tantivit P, Taschuk R, Durand M. Venovenous versus venoarterial extracorporeal membrane oxygenation in congenital diaphragmatic hernia. *J Pediatr Surg* 2003;38:1131-6.
100. Pettignano R, Fortenberry JD, Heard ML, Labuz MD, Kesser KC, Tanner AJ, et al. Primary use of the venovenous approach for extracorporeal membrane oxygenation in pediatric acute respiratory failure. *Pediatr Crit Care Med* 2003;4:291-8.

101. Guner YS, Khemani RG, Qureshi FG, Wee CP, Austin MT, Dorey F, *et al.* Outcome analysis of neonates with congenital diaphragmatic hernia treated with venovenous vs venoarterial extracorporeal membrane oxygenation. *J Pediatr Surg* 2009;44:1691-701.
102. Turner DA, Rehder KJ, Peterson-Carmichael SL, Ozment CP, Al-Hegelan MS, Williford WL, *et al.* Extracorporeal membrane oxygenation for severe refractory respiratory failure secondary to 2009 H1N1 influenza A. *Respir Care* 2011;56:941-6.
103. Garcia JP, Iacono A, Kon ZN, Griffith BP. Ambulatory extracorporeal membrane oxygenation: A new approach for bridge-to-lung transplantation. *J Thorac Cardiovasc Surg* 2010;139:e137-9.
104. Mangi AA, Mason DP, Yun JJ, Murthy SC, Pettersson GB. Bridge to lung transplantation using short-term ambulatory extracorporeal membrane oxygenation. *J Thorac Cardiovasc Surg* 2010;140:713-5.
105. Turner DA, Cheifetz IM, Rehder KJ, Williford WL, Bonadonna D, Banuelos SJ, *et al.* Active rehabilitation and physical therapy during extracorporeal membrane oxygenation while awaiting lung transplantation: A practical approach. *Crit Care Med* 2011;39:2593-8.
106. Hayes D Jr, Kukreja J, Tobias JD, Ballard HO, Hoopes CW. Ambulatory venovenous extracorporeal respiratory support as a bridge for cystic fibrosis patients to emergent lung transplantation. *J Cyst Fibros* 2012;11:40-5.

How to cite this article: Hayes D, Tobias JD, Kukreja J, Preston TJ, Yates AR, Kirkby S, *et al.* Extracorporeal life support for acute respiratory distress syndrome. *Ann Thorac Med* 2013;8:133-41.

Source of Support: Nil, **Conflict of Interest:** None declared.

Author Help: Reference checking facility

The manuscript system (www.journalonweb.com) allows the authors to check and verify the accuracy and style of references. The tool checks the references with PubMed as per a predefined style. Authors are encouraged to use this facility, before submitting articles to the journal.

- The style as well as bibliographic elements should be 100% accurate, to help get the references verified from the system. Even a single spelling error or addition of issue number/month of publication will lead to an error when verifying the reference.
- Example of a correct style
Sheahan P, O'leary G, Lee G, Fitzgibbon J. Cystic cervical metastases: Incidence and diagnosis using fine needle aspiration biopsy. *Otolaryngol Head Neck Surg* 2002;127:294-8.
- Only the references from journals indexed in PubMed will be checked.
- Enter each reference in new line, without a serial number.
- Add up to a maximum of 15 references at a time.
- If the reference is correct for its bibliographic elements and punctuations, it will be shown as CORRECT and a link to the correct article in PubMed will be given.
- If any of the bibliographic elements are missing, incorrect or extra (such as issue number), it will be shown as INCORRECT and link to possible articles in PubMed will be given.