

UC Davis

UC Davis Previously Published Works

Title

Soluble epoxide hydrolase activity and pharmacologic inhibition in horses with chronic severe laminitis

Permalink

<https://escholarship.org/uc/item/2928q6m9>

Journal

Equine Veterinary Journal, 49(3)

ISSN

0425-1644

Authors

Guedes, A
Galuppo, L
Hood, D
[et al.](#)

Publication Date

2017-05-01

DOI

10.1111/evj.12603

Peer reviewed



Published in final edited form as:

Equine Vet J. 2017 May ; 49(3): 345–351. doi:10.1111/evj.12603.

Soluble epoxide hydrolase activity and pharmacologic inhibition in horses with chronic severe laminitis

A. GUEDES^{*,†,‡}, L. GALUPPO[‡], D. HOOD[§], S. H. HWANG[#], C. MORISSEAU[#], and B. D. HAMMOCK[#]

[†]Department of Veterinary Clinical Sciences, College of Veterinary Medicine, University of Minnesota, St Paul, USA

[‡]Department of Surgical and Radiological Sciences, School of Veterinary Medicine, University of California, Davis, USA

[§]The Hoof Diagnostic and Rehabilitation Clinic, Bryan, TX, USA

[#]Department Entomology and Nematology, and UC Davis Comprehensive Cancer Center, University of California, Davis, USA

Summary

Background—The roles of soluble epoxide hydrolase and lipid mediators in inflammatory and neuropathic pain could be relevant in laminitis pain management.

Objectives—To determine soluble epoxide hydrolase (sEH) activity in the digital laminae, sEH inhibitor potency *in vitro*, and efficacy of a sEH inhibitor as an adjunct analgesic therapy in chronic laminitic horses.

Study design—*In vitro* experiments and *in vivo* case series.

Methods—sEH activity was measured in digital laminae from euthanized healthy and laminitic horses (n=5–6/group). Potency of seven synthetic sEH inhibitors was determined *in vitro* using equine liver cytosol. One of them (*t*-TUCB; 0.1 mg/kg bwt IV every 24 hours) was selected based on potency and stability, and used as adjunct therapy in 10 horses with severe chronic laminitis (Obel grades 2, 1 horse; 3–4, 9 horses). Daily assessments of forelimb lifts, pain scores, physiologic and laboratory examinations were performed before (baseline) and during *t*-TUCB treatment. Data are presented as mean±SD and 95% confidence intervals (CI).

Results—sEH activity in the digital laminae from laminitic horses (0.9±0.6 nmol/min/mg; CI: 0.16–1.55 nmol/min/mg) was significantly higher (P=0.01) than in healthy horses (0.17±0.09 nmol/min/mg; CI: 0.07–0.26 nmol/min/mg). *t*-TUCB as an adjunct analgesic up to 10 days (4.3±3 days) in laminitic horses was associated with significant reduction in forelimb lifts (36 ± 22%; CI: 9–64%) and in pain scores (18±23%; CI: 2–35%) compared to baseline (P=0.04). One horse developed gas colic and another corneal vascularization in a blind eye during treatment. No other significant changes were observed.

Main Limitations—Absence of control group and evaluator blinding in case series.

*Correspondence: guede003@umn.edu.

Conclusions—sEH activity is significantly higher in the digital laminae of actively laminitic compared to healthy horses, and use of a potent inhibitor of equine sEH as adjunct analgesic therapy appears to decrease signs of pathologic pain in laminitic horses.

Keywords

horse; fatty acid; neuropathic pain; hyperalgesia; lameness; hoof

Equine laminitis is a complex, extremely painful and disabling condition [1]. It is associated with local inflammation, up-regulation of pro-inflammatory and pro-nociceptive cytokines such as tumor necrosis factor (TNF)- α [2–4] and neuropathic changes in peripheral neurons [5]. These neuropathic changes are accompanied by behavioral changes indicative of a pathologic pain state encompassing allodynia, hyperalgesia and spontaneous pain [5]. Cells in injured and inflamed tissues produce an array of pro-algesic lipid metabolites that contribute to a peripheral gating mechanism and thus regulate the access of nociceptive information to the central nervous system [6]. As such, blocking the generation of inflammatory mediators from the oxidative metabolism of arachidonic acid (ARA) with cyclooxygenase (COX) inhibitors is commonly used for managing pain in horses, including pain associated with laminitis [1; 7; 8]. However, laminitis pain can be refractory to COX inhibitors and other analgesics [2; 5; 7], a feature in common with neuropathic pain states [1; 9].

Cytochrome P450 epoxygenases mediate another critical yet relatively unexplored pathway of ARA and other polyunsaturated fatty acid metabolism by which endogenous bioactive lipids, known as epoxy-fatty acids (EpFAs), are produced [10; 11]. A downstream enzyme, soluble epoxide hydrolase (sEH), metabolizes the EpFAs into the corresponding diols [11–15]. The diols are less active or inactive in terms of anti-nociception [16]. Extensive evidence in rodent models of inflammatory and neuropathic pain shows that pharmacological inhibition of sEH result in stabilization of EpFAs and anti-nociceptive effects via multiple mechanisms that is significantly greater than COX inhibitors, opioids and gabapentin [9; 17–22]. In the spinal cord, sEH inhibition result in EpFAs-mediated down-regulation of COX-2 transcription, possibly through a nuclear factor-kappa B (NF- κ B)-dependent pathway, and rapid up-regulation of the acute neurosteroid-producing gene in the presence of elevated cAMP levels, which then results in neurosteroid production and analgesia via γ -aminobutyric acid (GABA) channels [19; 22]. The ARA-derived EpFA 14,15 epoxyeicosatrienoic acid also produces analgesia via activation of β -endorphin and Met-enkephalin in the ventrolateral periaqueductal gray (vlPAG) [23]. In peripheral neurons, sEH inhibitors decrease endoplasmic reticulum (ER) stress, resulting in amelioration of neuropathic pain more efficiently than gabapentin [17; 18]. These multiple modes of action are likely to be useful in managing refractory pain in equine laminitis, as suggested in one case report [reference masked for review].

Herein, this potential analgesic role is further explored by asking whether sEH activity in the digital laminae of chronic laminitic horses is changed compared to healthy animals, whether sEH inhibitors designed to block human sEH are also able to inhibit the equine sEH, and

whether sEH inhibition as adjunct analgesic therapy is associated with changes in forelimb lifts and subjective pain scores in horses with severe chronic laminitis.

Material and Methods

Animals

A total of 22 adult horses (2–25 years old males or females from several breeds), 16 affected with laminitis (laminitic) and 6 unaffected (healthy) were used in this study. The source of horses included client-owned animals, the UC Davis Center for Equine Health, The Hoof Project Foundation and an unrelated study evaluating oviductal patency in standing mares [24]. No horses were euthanized for the purpose of the present study. Horses were evaluated for overall health through physical examination, complete blood cell counts and serum biochemical analysis. Owner consent was obtained prior to enrollment of client-owned horses. The “masked for review” Institutional Animal Care and Use Committee reviewed and approved experimental protocols involving live client-owned animals.

Determination of sEH activity in liver and digital laminae

Liver samples were collected from the left liver lobe of four healthy female intact Quarter horses (3–10 years old) immediately after euthanasia for an unrelated study [24]. Laminae tissues were collected from groups of laminitic (17–19 years old; 3 male, 3 female; 4 Quarter horses, 1 Paint horse, 1 Arabian horse) and healthy (2–25 years old; 2 male, 4 female; 5 Quarter horses, 1 Arabian horse) horses that were being euthanized for reasons unrelated to this study (laminitic horses were euthanized because of chronic laminitis). Horse age does not affect sEH activity in lungs and liver [25]. Immediately after euthanasia, the forefeet were quickly removed by sawing through the first phalanx. Subsequently, starting at the hoof's midline, three sagittal cuts were made 1 cm apart and the laminae tissues from the mid portion of the dorsal cut were removed. The tissues were snap-frozen in liquid nitrogen and stored at -80°C until use. Liver samples were homogenized in 15 mL chilled sodium phosphate buffer (20 mM, pH 7.4) containing 5 mM EDTA, 1 mM DTT and 1 mM PMSF. The homogenate was centrifuged at 10,000 g for 20 min at 4°C . The supernatant containing the cytosolic and microsomal fractions (termed S9 fraction) was collected and the pellet (mitochondria/peroxysome/nucleus fraction) was suspended in 3 mL chilled Tris/HCl buffer (20 mM, pH 8.3) containing 5 mM EDTA. The S9 fraction was again centrifuged at 100,000 g for 60 min at 4°C to separate the cytosolic from the microsomal fractions. As such, after centrifugation, the supernatant was collected and used as the cytosolic fraction, and the pellet was suspended in 3 mL chilled sodium phosphate buffer (10 mM, pH 7.4) containing 5 mM EDTA and 20% glycerol to form the microsomal fraction. The digital laminae samples were homogenized in 5 mL chilled sodium phosphate buffer (20 mM, pH 7.4) containing 5 mM EDTA, 1 mM DTT and 1 mM PMSF. The homogenate was centrifuged at 10,000 g for 20 min at 4°C . The supernatant was used as a S9 fraction (i.e., cytosolic and microsomal fractions combined). All fractions were frozen in liquid nitrogen, and kept at -80°C until use. Protein concentrations were measured with the BCA method using bovine serum albumin as standard. Soluble epoxide hydrolase activity was measured in digital laminae and hepatic tissues using [^3H]-*t*-DPPO as substrate with $[\text{S}] = 50\ \mu\text{M}$ and incubation for 10 to 30 min at 30°C [26].

Synthesis and potency of sEH inhibitors

The seven sEH inhibitors used in the current study were synthesized according to procedures described previously [13; 14; 27–29]. Inhibitory activity of the inhibitors was determined for the equine sEH using the hepatic cytosolic fraction of liver tissue from healthy animals (see above). The cytosol extract was diluted 200-fold in sodium phosphate buffer (0.1 M pH 7.4) containing 0.1 mg/mL BSA. In glass tubes (measurements were done in triplicate), to 100 μ L of the protein solution, one microliter of the inhibitor solution in DMSO ($[I]_{\text{final}}$ between 1 and 10,000 nM) was added. The mixture was incubated for 5 min at 30 °C before adding one microliter of a 5 mM solution of [^3H]-*t*-DPPO (8,000 cpm/ μ L; $[S]_{\text{final}} = 50 \mu\text{M}$). The reaction was incubated an additional 10 min at 30°C and then stopped by the addition of 60 μ L of methanol. The remaining substrate was extracted with 250 μ L of iso-octane. The quantity of diol formed was evaluated by measuring the amount of radioactivity present in the aqueous phase using a liquid scintillation counter. The IC_{50} , IC_{90} and IC_{95} values were calculated by nonlinear regression of at least eight datum points using SigmaPlot.

Inhibition of sEH in laminitic horses: Physiologic and anti-nociceptive effects

Ten adult horses diagnosed with laminitis and rotation of the third phalanx in relation to the hoof wall of Obel grades 4 (6 horses), 3 (3 horses) or 2 (1 horse), that were not satisfactorily responding to therapy and/or for which euthanasia was being considered were intravenously treated with 0.1 mg/kg bwt *t*-TUCB every 24 hours for a period of 1–10 days. Drug preparation, administration and outcome assessments were performed as described in detail previously (reference masked for review). Briefly, *t*-TUCB was prepared for each individual horse as a 10 mg/ml solution in dimethyl sulfoxide (DMSO) and filter-sterilized prior to use. The horses were evaluated 3–5 times daily starting one or two days before (baseline) and then during the treatment with *t*-TUCB. Pain was independently assessed in each horse by at least two veterinary professionals (veterinarians and/or veterinary technicians) that were directly involved in patient care with the use of a visual analog scale (VAS; '0' = no pain and '10' = worst possible pain). Forelimb lifts were counted over a 5-minute observation period. While assigning pain scores is subjective and can be biased, increased frequency of forelimb lift is an uncharacteristic equine behavior manifested by laminitic horses that is objectively quantifiable [2; 5]. Increased forelimb lift frequency is indicative of sensory hypersensitivity or a pathologic pain state encompassing allodynia, hyperalgesia and spontaneous pain [5]. Heart rate was assessed with a stethoscope and respiratory rate via direct visualization of thoracoabdominal movements. Blood pressure was measured with a tail cuff in the standing horse and was not corrected for hydrostatic pressure difference between the heart and the base of the tail. Gastrointestinal sounds were assessed and scored as described previously [referenced masked for review and [2]. Blood was collected for complete blood cell count and serum biochemistry (CBC/CHEM) before *t*-TUCB treatment and 24 h after its last dose. Clinically significant behavioral changes or adverse events, which would have led to the discontinuation of the *t*-TUCB treatment, were recorded.

Statistical Analysis

Statistical analyses were performed with commercially available software (GraphPad Prism version 5.0f for MAC, GraphPad Software Inc., San Diego, CA, USA). Continuous data

were analyzed for normality with the D'Agostino & Pearson omnibus or the Shapiro-Wilk normality tests and log-transformed prior to analysis if non-normally distributed. Digital laminae sEH activities were compared between healthy and laminitic horses with unpaired two-tails t-tests. The sEH activities of the different fractions (i.e., cytosol, microsomes and mitochondria/peroxisome/nucleus) from liver tissue were compared using one-way repeated measures analysis of variance and Bonferroni post-test. Daily outcome measurements of each laminitic horse were averaged to form two sets of data: baseline (1–2 days before *t*-TUCB dosing) and treatment (1–10 days during *t*-TUCB dosing) periods. The pain scores and forelimb lifts were also compared between the baseline and the average of responses during the first three days of treatment. Continuous baseline and treatment data were compared using paired two-tails t-tests. Non-continuous data (i.e., gastrointestinal motility scores) were compared using chi-square. A value of $P < 0.05$ was considered statistically significant. Data are shown as mean \pm SD unless otherwise indicated.

Results

sEH activity in hepatic tissues, digital laminae and sEH inhibition in vitro

In hepatic tissue, sEH activity was significantly higher in the cytosolic fraction (22 ± 2 nmol/min/mg; $P < 0.01$) than in the microsomal fraction (6.0 ± 0.5 nmol/min/mg) and in the mitochondria/peroxisome/nuclear fraction (8 ± 2 nmol/min/mg).

The sEH activity was also measured in the S9 fraction (combined cytosolic and microsomal fractions) of the digital laminae from horses with chronic laminitis as well as from healthy horses. One chronic laminitic horse was classified as Obel grade 0 for lameness severity at the time of euthanasia and was not included in the statistical calculations. Remaining horses were classified as Obel grade 2 ($n=1$) or 3 ($n=4$). Horses had been diagnosed with laminitis for several years although exact duration was not known. One laminitic horse was being treated with pergolide for pituitary pars intermedia dysfunction, and most ($n=3$) were receiving phenylbutazone on an “as needed” basis (exact dose and schedule not known). Remaining horses had no known systemic co-morbidities. The sEH activity was variable but significantly ($P = 0.01$) higher in the digital laminae of laminitic horses (0.9 ± 0.6 nmol/min/mg; CI: 0.16–1.55 nmol/min/mg) than of healthy horses (0.17 ± 0.09 nmol/min/mg; CI: 0.07–0.26 nmol/min/mg). The sEH activity in the one chronic laminitic horse classified as Obel grade 0 at time of euthanasia was 0.09 nmol/min/mg.

Inhibitory activity (IC_{50}) of seven inhibitors developed against the human sEH and tested previously in animal models was measured against the equine sEH using horse liver cytosol (Table 1). Based on its potency against the equine sEH, preliminary experience in one laminitic horse [reference masked for review], and its previously reported stability in other animals [9; 30], *t*-TUCB was selected for further usage. The potency of *t*-TUCB was further confirmed by its inhibitory activity against the equine sEH in a concentration-response manner (Figure 1).

sEH inhibition in vivo

Ten laminitic horses aged 15 ± 6 years (range 3–24 years), weighing 498 ± 56 kg (range 408–600 kg) bwt were treated with the sEH inhibitor *t*-TUCB as an adjunct therapy for an average of 4.3 ± 3 days (range 1–10 days). Clinical details of the patient cohort are presented in Table 2. Compared to baseline, addition of *t*-TUCB to the therapy was associated with a statistically significant decrease of $36\pm 22\%$ (95% CI: 9–64%; $P = 0.04$) in forelimb lifts (from 5 ± 1 to 3 ± 1 lifts/minute) and a significant decrease of $18\pm 23\%$ (95% CI: 2–35%; $P = 0.04$) in pain scores (from 6.8 ± 2 to 5.5 ± 2). When the comparison was restricted to the first three days of treatment, addition of *t*-TUCB to therapy was associated with statistically significant decreases of $33\pm 17\%$ (95% CI: 11–54%; $P=0.02$) in forelimb lifts and of $14\pm 15\%$ (95% CI: 2–25%; $P = 0.03$) in pain scores. Figure 2 shows the percent change relative to baseline during the entire treatment period (1–10 days; panel A) or during the first 3 days (panel B) for each horse's pain scores during *t*-TUCB administration. Horse 1 (*) has been published as a case report [reference masked for review]. Data from this horse were not included in the statistical calculations.

Compared to baseline, there were no significant changes in respiratory rate (from 19 ± 5 to 19 ± 3 breaths/minute), heart rate (from 48 ± 10 to 48 ± 11 beats/minute), mean arterial pressure (from 102 ± 37 to 97 ± 28 mmHg) and gastrointestinal motility scores (from 12 ± 4 to 12 ± 3) during adjunct therapy with *t*-TUCB. One horse (horse 5) developed signs of abdominal pain (i.e., colic) on the second day after starting *t*-TUCB treatment, *t*-TUCB was discontinued, and the horse responded promptly to medical treatment. From this horse, two offspring (one male and one female) were born the following year from embryo transfer without any problems. Separately, another horse (horse 3) with unilateral blindness and corneal opacity developed blepharospasm and epiphora (yellow tinge) with evidence of corneal vascularization after the 4th dose of *t*-TUCB. There was no evidence of corneal ulceration suggested by lack of fluorescein uptake and treatment with ophthalmic ointment containing oxytetracycline and polymyxin B was instituted. In this horse, *t*-TUCB was discontinued after the 5th dose due to poor response to treatment and radiographic evidence of septic pedal osteitis and possible pathologic solar margin fractures. The macroscopic ocular changes subsided completely by the fifth day after discontinuing *t*-TUCB administration. There were no significant changes on physical and laboratory variables with the *t*-TUCB treatment (Tables S1 and S2 in Supplemental Information).

Discussion

The main findings of this study are that sEH activity is significantly increased in digital laminae from laminitic horses compared to healthy horses and adjunct analgesic therapy with *t*-TUCB, a potent inhibitor of equine sEH, was associated with a statistically significant improvement in forelimb lifts, a pain-associated behavior of equine laminitis [5], and subjectively-assigned pain scores with negligible negative side effects. These results are consistent with reports showing significant decrease in neuropathic and inflammatory pain with sEH inhibitors or EpFAs in rodent models [9; 16; 17; 22], and confirm earlier observations in one laminitic horse [reference masked for review].

The effects of sEH inhibition in laminitis pain likely involve both peripheral and central mechanisms [6; 11]. The findings of increased sEH activity in digital laminae and decrease in pain measures with sEH inhibition in laminitic horses corroborate with a peripheral mechanism of action. It is well recognized that a host of lipid metabolites produced by injured cells in inflamed tissues play a central role in gating peripheral nociception [6]. Peripheral application of EpFAs, especially those derived from the omega-3 fatty acid docosahexaenoic acid (DHA), result in anti-hyperalgesia [16]. Inhibition of sEH could also decrease the hyperalgesic state in laminitis via modulation of peripheral neuropathy [5] since sEH inhibition significantly ameliorates neuropathic pain via decreasing ER stress in peripheral neurons [17]. A central effect is also possible because sEH inhibitors penetrate the central nervous system where sEH is present and metabolically active [18; 31; 32] and EpFAs can also produce central anti-hyperalgesia or analgesia [16; 23]. Specific mechanisms include down-regulation of COX-2 transcription and up-regulation of neurosteroid synthesis in the spinal cord, up-regulation of endogenous opioid peptides in vIPAG, amelioration of ER stress in peripheral neurons, down-regulation of pro-inflammatory cytokines [17–19; 22; 23]. Inhibition of sEH appears to be a mechanistically sound strategy for multimodal pain management in equine laminitis [1; 7].

Two of the horses studied continued to display refractory pain during sEH inhibitor treatment.

There are at least three plausible explanations for this finding. First, underlying pain mechanisms could have been sEH-independent. For example, linoleic acid-derived EpFAs in the lipoxigenase pathway can be algogenic via activation of transient receptor potential (TRP) channels [33]. Second, post-translational modifications and polymorphisms of some equine CYP450 epoxygenases [34; 35] could favor the production of EpFA that may not be good sEH substrates thereby being insensitive or poorly sensitive to sEH inhibitors, even if sEH activity is increased. The EpFAs from arachidonic acid can be algogenic or analgesic depending on the dose studied [20], and are less preferred substrates for sEH [16]. Arachidonic acid-derived EpFAs are also involved in angiogenesis [36–38] and, coincidentally, one of the refractory horses also developed prominent corneal vascularization. Third, *l*-TUCB displays a near-bell shaped dose-response curve at a dose range between 0.1 and 100 mg/kg bwt in rodent models of inflammatory and neuropathic pain [9]. If this is also the case in horses, it is possible that the dose of *l*-TUCB was either too low or too high for these two horses. Current research efforts are being made to elucidate these possibilities and refine therapy.

At present, there are no validated methods for pain assessment in laminitic horses [39]. The VAS used in the present study was considered reliable for assessing lameness in equine laminitis [40]. Reliability tended to be lower for inexperienced observers, but overall reliability was high, especially intra-rater reliability [40]. Accordingly, experienced observers used the VAS and the same observers assessed each individual horse during treatment in the current study. Another concern when managing laminitis pain is that pain has a critical adaptive component that if extinguished may lead to further damage to the digital laminae. Pain elimination may also complicate monitoring of disease progression as well as response to treatment [41]. The precise minimum amount of pain required for these

adaptive/therapeutic components is difficult to know. The goal of laminitis pain therapy should be to strike the best possible balance in the spectrum spanning from the maladaptive to the adaptive components of pain and thus require an individualized approach. A modest reduction from high pain levels is probably safe provided that other aspects of the disease are being adequately monitored and managed [reference masked for review and [2; 41; 42]. On average, the level of improvement obtained with *t*-TUCB in the laminitic horses of the current study is consistent with this notion.

No overt adverse effects that could be directly linked to the sEH inhibitor were observed on extensive physical and laboratory examinations. The unexpected corneal vascularization in one horse that had long-term blindness and corneal opacity prior to enrollment in the study was intriguing but not too surprising. Studies in mice show that EpFAs derived from omega-6 arachidonic acid are pro-angiogenic [36] whereas EpFAs from the omega-3 fatty acid DHA, the preferred substrates for sEH [16], are anti-angiogenic [38]. These EpFAs also have opposing effects in tumor growth and metastasis formation in mice [36; 38], a finding that could be relevant in horses with oncologic disorders. In agreement with findings in other species [19; 22; 27; 30; 43] and in one case report of one horse [reference masked for review] no signs of central nervous system depression or excitation or motor impairment were observed. The one horse that developed medical colic had other significant risk factors (i.e., Arabian breed, potentially decreased water intake) that could predispose to colic [44]. Exposure to the sEH inhibitor did not prevent the same horse from donating two viable embryos. Apart from horse 2 who already had gastrointestinal disease and motility problems, there were no significant changes in gastrointestinal motility during *t*-TUCB treatment in the remaining horses. It is highly unlikely that there would be toxic increases in EpFAs by sEH inhibition since they are endogenously generated, although off-target effects of the sEH inhibitor cannot be completely ruled out. To date, no obvious adverse effects associated with sEH inhibition have been observed in rodents [16; 20–22; 45], dogs [27], non-human primates [30], and humans [43]. All but one horse in the present study were being treated with a COX inhibitor. Studies in mice show that sEH inhibitors synergize with COX inhibitors for anti-nociception [45] but antagonize COX inhibitor-induced gastrointestinal ulcer formation [46]. There is no evidence that the current clinically available COX inhibitors directly affect sEH activity.

The relatively small number of horses in the *in vivo* part of the current study, the lack of blinding and the absence of a control group could be considered limitations of the current study. Without a control group, treatment data was compared to baseline (i.e., before treatment), and hence it is not possible to precisely quantify the relative contribution of sEH inhibition to the changes in forelimb lift frequency and pain scores. It is conceivable that at least some of the changes in forelimb lifts and pain levels could be a manifestation of the normal progression of the condition independent of sEH inhibition. A previous report showed that frequency of forelimb lift and other behavioral changes fluctuates over time even in healthy horses, but laminitic horses consistently display increased forelimb lifts over a three-day period compared to healthy horses [5]. For this reason, forelimb lift and pain scores were also compared between baseline and the first three days of *t*-TUCB treatment. This comparison was again statistically significant for both outcomes, suggesting that sEH inhibition indeed had a significant contribution to the changes observed. Lack of blinding

could have influenced pain scores, which are subjectively assigned, but not limb lifts, which are objectively quantified. The use of DMSO as vehicle and the severity and advanced nature of the condition could be considered additional limitations. It is unlikely that DMSO was a significant confounding factor despite its possible anti-inflammatory and free radical scavenging actions. Its efficacy in the treatment of laminitis is highly questionable [47], the quantity that each horse received (~500 mg/horse/day) is well below the recommended dose (up to 1600 g/horse/day) [47] and the *in vitro* experiments showed that DMSO has no sEH inhibitory effects.

In conclusion, sEH activity is significantly increased in horses with active chronic laminitis compared to healthy horses. Several sEH inhibitors initially designed to inhibit the human enzyme are also active against equine sEH. Adjunct therapy with ϵ -TUCB, a potent pharmacological sEH inhibitor, in horses with severe chronic laminitis resulted in mild to moderate, statistically significant, decreases in forelimb lifts and pain scores, suggesting that ϵ -TUCB helped control pathologic pain associated with laminitis [5]. The current results argue for a role of endogenous bioactive lipids in laminitis pain signaling and support further exploration into manipulating these molecules, via sEH inhibition or other strategies, as an additional therapeutic approach for laminitis.

Supplementary Material

Refer to Web version on PubMed Central for supplementary material.

References

1. Driessen B, Bauquier SH, Zarucco L. Neuropathic pain management in chronic laminitis. *Vet Clin N Am: Equine Pract.* 2010; 26:315–337.
2. Guedes AG, Matthews NS, Hood DM. Effect of ketamine hydrochloride on the analgesic effects of tramadol hydrochloride in horses with signs of chronic laminitis-associated pain. *Am J Vet Res.* 2012; 73:610–619. [PubMed: 22533391]
3. Treiber K, Carter R, Gay L, Williams C, Geor R. Inflammatory and redox status of ponies with a history of pasture-associated laminitis. *Vet Immunol Immunopathol.* 2009; 129:216–220. [PubMed: 19108899]
4. Steelman SM, Johnson D, Wagner B, Stokes A, Chowdhary BP. Cellular and humoral immunity in chronic equine laminitis. *Vet Immunol Immunopathol.* 2013; 153:217–226. [PubMed: 23521925]
5. Jones E, Vinuela-Fernandez I, Eager RA, Delaney A, Anderson H, Patel A, Robertson DC, Allchorne A, Sirinathsinghji EC, Milne EM, MacIntyre N, Shaw DJ, Waran NK, Mayhew J, Fleetwood-Walker SM. Neuropathic changes in equine laminitis pain. *Pain.* 2007; 132:321–331. [PubMed: 17935886]
6. Piomelli D, Hohmann AG, Seybold V, Hammock BD. A lipid gate for the peripheral control of pain. *J Neurosci.* 2014; 34:15184–15191. [PubMed: 25392487]
7. Sanchez LC, Robertson SA. Pain control in horses: what do we really know? *Equine Vet J.* 2014; 46:517–523. [PubMed: 24645799]
8. Owens JG, Kamerling SG, Stanton SR, Keowen ML. Effects of ketoprofen and phenylbutazone on chronic hoof pain and lameness in the horse. *Equine Vet J.* 1995; 27:296–300. [PubMed: 8536666]
9. Wagner K, Inceoglu B, Dong H, Yang J, Hwang SH, Jones P, Morisseau C, Hammock BD. Comparative efficacy of 3 soluble epoxide hydrolase inhibitors in rat neuropathic and inflammatory pain models. *Eur J Pharmacol.* 2013; 700:93–101. [PubMed: 23276668]
10. Wagner K, Inceoglu B, Hammock BD. Soluble epoxide hydrolase inhibition, epoxygenated fatty acids and nociception. *Prostaglandins Other Lipid Mediat.* 2011; 96:76–83. [PubMed: 21854866]

11. Spector AA, Kim HY. Cytochrome P450 epoxygenase pathway of polyunsaturated fatty acid metabolism. *Biochim Biophys Acta*. 2015; 1851:356–365. [PubMed: 25093613]
12. Wagner K, Inceoglu B, Gill SS, Hammock BD. Epoxygenated fatty acids and soluble epoxide hydrolase inhibition: novel mediators of pain reduction. *J Agric Food Chem*. 2011; 59:2816–2824. [PubMed: 20958046]
13. Hwang SH, Tsai HJ, Liu JY, Morisseau C, Hammock BD. Orally bioavailable potent soluble epoxide hydrolase inhibitors. *J Med Chem*. 2007; 50:3825–3840. [PubMed: 17616115]
14. Morisseau C, Newman JW, Tsai HJ, Baecker PA, Hammock BD. Peptidyl-urea based inhibitors of soluble epoxide hydrolases. *Bioorg Med Chem Lett*. 2006; 16:5439–5444. [PubMed: 16908134]
15. Chacos N, Capdevila J, Falck JR, Manna S, Martin-Wixtrom C, Gill SS, Hammock BD, Estabrook RW. The reaction of arachidonic acid epoxides (epoxyeicosatrienoic acids) with a cytosolic epoxide hydrolase. *Arch Biochem Biophys*. 1983; 223:639–648. [PubMed: 6859878]
16. Morisseau C, Inceoglu B, Schmelzer K, Tsai HJ, Jinks SL, Hegedus CM, Hammock BD. Naturally occurring monoepoxides of eicosapentaenoic acid and docosahexaenoic acid are bioactive antihyperalgesic lipids. *J Lipid Res*. 2010; 51:3481–3490. [PubMed: 20664072]
17. Inceoglu B, Bettaieb A, Trindade da Silva CA, Lee KS, Haj FG, Hammock BD. Endoplasmic reticulum stress in the peripheral nervous system is a significant driver of neuropathic pain. *Proc Natl Acad Sci USA*. 2015; 112:9082–9087. [PubMed: 26150506]
18. Inceoglu B, Wagner KM, Yang J, Bettaieb A, Schebb NH, Hwang SH, Morisseau C, Haj FG, Hammock BD. Acute augmentation of epoxygenated fatty acid levels rapidly reduces pain-related behavior in a rat model of type I diabetes. *Proc Natl Acad Sci USA*. 2012; 109:11390–11395. [PubMed: 22733772]
19. Inceoglu B, Wagner K, Schebb NH, Morisseau C, Jinks SL, Ulu A, Hegedus C, Rose T, Brosnan R, Hammock BD. Analgesia mediated by soluble epoxide hydrolase inhibitors is dependent on cAMP. *Proc Natl Acad Sci USA*. 2011; 108:5093–5097. [PubMed: 21383170]
20. Inceoglu B, Jinks SL, Schmelzer KR, Waite T, Kim IH, Hammock BD. Inhibition of soluble epoxide hydrolase reduces LPS-induced thermal hyperalgesia and mechanical allodynia in a rat model of inflammatory pain. *Life Sci*. 2006; 79:2311–2319. [PubMed: 16962614]
21. Inceoglu B, Schmelzer KR, Morisseau C, Jinks SL, Hammock BD. Soluble epoxide hydrolase inhibition reveals novel biological functions of epoxyeicosatrienoic acids (EETs). *Prostaglandins Other Lipid Mediat*. 2007; 82:42–49. [PubMed: 17164131]
22. Inceoglu B, Jinks SL, Ulu A, Hegedus CM, Georgi K, Schmelzer KR, Wagner K, Jones PD, Morisseau C, Hammock BD. Soluble epoxide hydrolase and epoxyeicosatrienoic acids modulate two distinct analgesic pathways. *Proc Natl Acad Sci USA*. 2008; 105:18901–18906. [PubMed: 19028872]
23. Terashvili M, Tseng LF, Wu HE, Narayanan J, Hart LM, Falck JR, Pratt PF, Harder DR. Antinociception produced by 14,15-epoxyeicosatrienoic acid is mediated by the activation of beta-endorphin and met-enkephalin in the rat ventrolateral periaqueductal gray. *J Pharmacol Exp Ther*. 2008; 326:614–622. [PubMed: 18492947]
24. Guedes AG, Morisseau C, Sole A, Soares JH, Ulu A, Dong H, Hammock BD. Use of a soluble epoxide hydrolase inhibitor as an adjunctive analgesic in a horse with laminitis. *Vet Anaesth Analg*. 2013; 40:440–448. [PubMed: 23463912]
25. Arnold CE, Love CC. Laparoscopic evaluation of oviductal patency in the standing mare. *Theriogenology*. 2013; 79:905–910. [PubMed: 23427938]
26. Lakritz J, Winder BS, Noorouz-Zadeh J, Huang TL, Buckpitt AR, Hammock BD, Plopper CG. Hepatic and pulmonary enzyme activities in horses. *Am J Vet Res*. 2000; 61:152–157. [PubMed: 10685686]
27. Morisseau C, Hammock BD. Measurement of soluble epoxide hydrolase (sEH) activity. *Curr Protoc Toxicol*. 2007 Chapter 4, Unit 4.23.
28. Tsai HJ, Hwang SH, Morisseau C, Yang J, Jones PD, Kasagami T, Kim IH, Hammock BD. Pharmacokinetic screening of soluble epoxide hydrolase inhibitors in dogs. *Eur J Pharm Sci*. 2010; 40:222–238. [PubMed: 20359531]
29. Rose TE, Morisseau C, Liu JY, Inceoglu B, Jones PD, Sanborn JR, Hammock BD. 1-Aryl-3-(1-acylpiperidin-4-yl)urea inhibitors of human and murine soluble epoxide hydrolase: structure-

- activity relationships, pharmacokinetics, and reduction of inflammatory pain. *J Med Chem.* 2010; 53:7067–7075. [PubMed: 20812725]
30. Jones PD, Tsai HJ, Do ZN, Morisseau C, Hammock BD. Synthesis and SAR of conformationally restricted inhibitors of soluble epoxide hydrolase. *Bioorg Med Chem Lett.* 2006; 16:5212–5216. [PubMed: 16870439]
31. Ulu A, Appt S, Morisseau C, Hwang S, Jones P, Rose T, Dong H, Lango J, Yang J, Tsai H, Miyabe C, Fortenbach C, Adams M, Hammock B. Pharmacokinetics and in vivo potency of soluble epoxide hydrolase inhibitors in cynomolgus monkeys. *Br J Pharmacol.* 2011; 165:1401–1412.
32. Sura P, Sura R, Enayetallah AE, Grant DF. Distribution and expression of soluble epoxide hydrolase in human brain. *J Histochem Cytochem.* 2008; 56:551–559. [PubMed: 18319271]
33. Marowsky A, Burgener J, Falck JR, Fritschy JM, Arand M. Distribution of soluble and microsomal epoxide hydrolase in the mouse brain and its contribution to cerebral epoxyeicosatrienoic acid metabolism. *Neuroscience.* 2009; 163:646–661. [PubMed: 19540314]
34. Patwardhan AM, Akopian AN, Ruparel NB, Diogenes A, Weintraub ST, Uhlson C, Murphy RC, Hargreaves KM. Heat generates oxidized linoleic acid metabolites that activate TRPV1 and produce pain in rodents. *J Clin Invest.* 2010; 120:1617–1626. [PubMed: 20424317]
35. Corado CR, McKemie DS, Young A, Knych HK. Evidence for polymorphism in the cytochrome P450 2D50 gene in horses. *J Vet Pharmacol Ther.* 2015; 39:245–254. [PubMed: 26441153]
36. Knych HK, McKemie DS, Stanley SD. Molecular cloning, expression, and initial characterization of members of the CYP3A family in horses. *Drug Metab Dispos.* 2010; 38:1820–1827. [PubMed: 20587621]
37. Panigrahy D, Edin ML, Lee CR, Huang S, Bielenberg DR, Butterfield CE, Barnes CM, Mammoto A, Mammoto T, Luria A, Benny O, Chaponis DM, Dudley AC, Greene ER, Vergilio JA, Pietramaggiore G, Scherer-Pietramaggiore SS, Short SM, Seth M, Lih FB, Tomer KB, Yang J, Schwendener RA, Hammock BD, Falck JR, Manthathi VL, Ingber DE, Kaipainen A, D'Amore PA, Kieran MW, Zeldin DC. Epoxyeicosanoids stimulate multiorgan metastasis and tumor dormancy escape in mice. *J Clin Invest.* 2012; 122:178–191. [PubMed: 22182838]
38. Panigrahy D, Kalish BT, Huang S, Bielenberg DR, Le HD, Yang J, Edin ML, Lee CR, Benny O, Mudge DK, Butterfield CE, Mammoto A, Mammoto T, Inceoglu B, Jenkins RL, Simpson MA, Akino T, Lih FB, Tomer KB, Ingber DE, Hammock BD, Falck JR, Manthathi VL, Kaipainen A, D'Amore PA, Puder M, Zeldin DC, Kieran MW. Epoxyeicosanoids promote organ and tissue regeneration. *Proc Natl Acad Sci USA.* 2013; 110:13528–13533. [PubMed: 23898174]
39. Zhang G, Panigrahy D, Mahakian LM, Yang J, Liu JY, Stephen Lee KS, Wettersten HI, Ulu A, Hu X, Tam S, Hwang SH, Ingham ES, Kieran MW, Weiss RH, Ferrara KW, Hammock BD. Epoxy metabolites of docosahexaenoic acid (DHA) inhibit angiogenesis, tumor growth, and metastasis. *Proc Natl Acad Sci USA.* 2013; 110:6530–6535. [PubMed: 23553837]
40. de Grauw JC, van Loon JP. Systematic pain assessment in horses. *Vet J.* 2016; 209:14–22. [PubMed: 26831169]
41. Vinuela-Fernandez I, Jones E, Chase-Topping ME, Price J. Comparison of subjective scoring systems used to evaluate equine laminitis. *Vet J.* 2011; 188:171–177. [PubMed: 20541956]
42. Parks A, O'Grady SE. Chronic laminitis: current treatment strategies. *Vet Clin N Am: Equine Pract.* 2003; 19:393–416.
43. Guedes A, Knych H, Hood D. Plasma concentrations, analgesic and physiological assessments in horses with chronic laminitis treated with two doses of oral tramadol. *Equine Vet J.* 2015; 48:528–531. [PubMed: 25832551]
44. Chen D, Whitcomb R, MacIntyre E, Tran V, Do ZN, Sabry J, Patel DV, Anandan SK, Gless R, Webb HK. Pharmacokinetics and pharmacodynamics of AR9281, an inhibitor of soluble epoxide hydrolase, in single- and multiple-dose studies in healthy human subjects. *J Clin Pharmacol.* 2012; 52:319–328. [PubMed: 21422238]
45. Reeves MJ, Salman MD, Smith G. Risk factors for equine acute abdominal disease (colic): results from a multi-center case-control study. *Prev Vet Med.* 1996; 26:285–301.
46. Schmelzer KR, Inceoglu B, Kubala L, Kim IH, Jinks SL, Eiserich JP, Hammock BD. Enhancement of antinociception by coadministration of nonsteroidal anti-inflammatory drugs and soluble

- epoxide hydrolase inhibitors. *Proc Natl Acad Sci USA*. 2006; 103:13646–13651. [PubMed: 16950874]
47. Goswami SK, Wan D, Yang J, Trindade da Silva CA, Morisseau C, Kodani SD, Yang GY, Inceoglu B, Hammock BD. Anti-ulcer efficacy of soluble epoxide hydrolase inhibitor TPPU on diclofenac sodium induced intestinal ulcers. *J Pharmacol Exp Ther*. 2016; 357:529–536. [PubMed: 26989141]
 48. Pollitt, C., Dyson, S. Laminitis. In: Ross, M., Dyson, S., editors. *Diagnosis and Management of Lameness in the Horse*. 2nd. Elsevier Inc; St. Louis: 2011. p. 366-386.
 49. Obel, N. Dissertation. Swedish University of Agricultural Sciences; Uppsala, Sweden: 1948. Studies on the histopathology of acute laminitis.

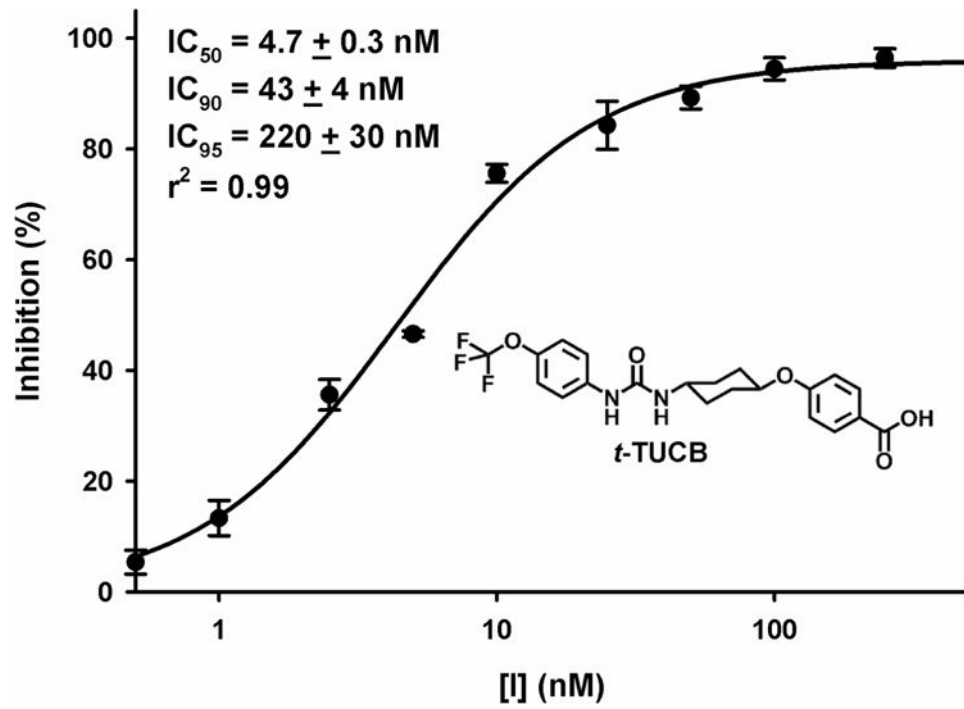


Figure 1.
In vitro concentration-inhibitory responses of the synthetic inhibitor of soluble epoxide hydrolase (sEH), t-TUCB, using equine liver cytosol extract.

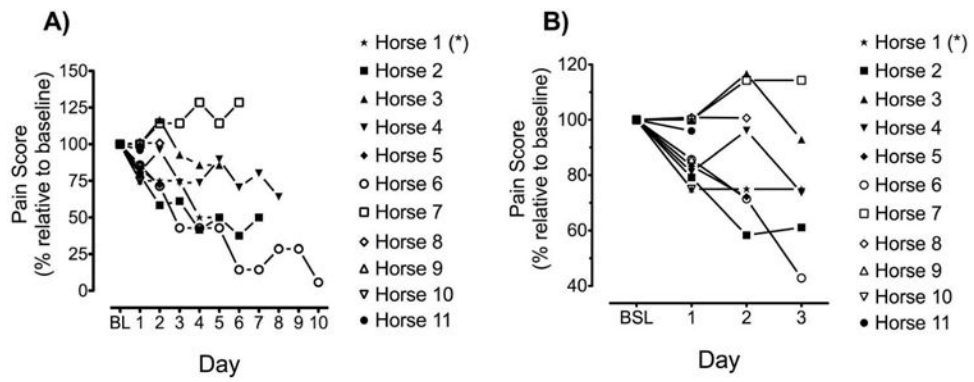


Figure 2. Percent change relative to baseline (BL) in individual pain scores during adjunct therapy with 0.1 mg/kg bwt *t*-TUCB intravenously every 24 hours in horses with severe chronic laminitis. Horse 1 (*) has been published as a case report (referenced removed for blinding). Panels depict the entire treatment period (A) or the first three days of treatment (B).

Table 1

Chemical structures and half-maximal inhibitory concentration (IC₅₀) values of equine sEH inhibitors.

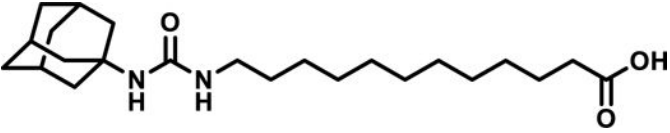
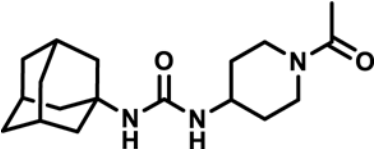
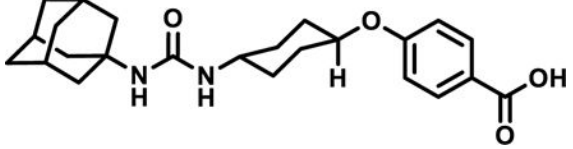
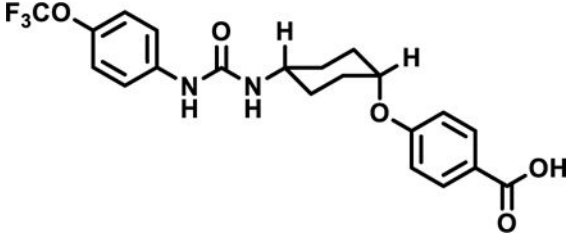
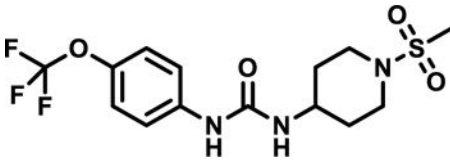
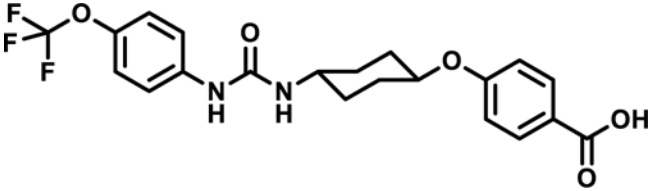
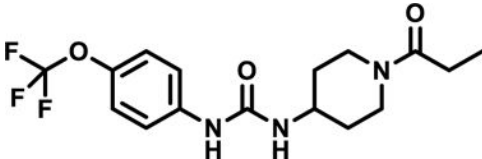
Structure	Acronym	Equine sEH IC ₅₀ (nM)
	AUDA	8
	APAU	50
	<i>t</i> -AUCB	5
	<i>c</i> -TUCB	4
	TUPS	16
	<i>t</i> -TUCB	6
	TPAU	19

TABLE 2

Clinical characteristics of the patient cohort that received adjunct therapy with 0.1 mg/kg ϵ -TUCB, a soluble epoxide hydrolase inhibitor, every 24 h intravenously. Horse 1 has previously been published as a case report [24]

Horse No.	Breed	Sex	Age	Type	Onset (days) ^a	Affected limb	Severity ^b , rotation	Precipitating factor	Concomitancies	Medications ^c	ϵ -TUCB (days)	Laminitis outcome ^d
2	TB	G	3	Single episode >1 year	6	Both front	4, yes	Colitis	Pharyngomyiasis, <i>C. difficile</i> /colitis, large colon impaction, jugular thrombophlebitis	PBZ, PTX, FM, BTF, GABA, ICE, ACE, LIDO, ASP, KET	7	++
3	STB	F	16	Recurrent >1 year	21	Left front	4, yes	Unknown, Possible WLD	Pedal osteitis	PBZ, PTX	5	+
4	Arab	G	14	Recurrent >6 months	90	Both front	4, yes	Unknown	None	PBZ, GABA, ACE	8	+
5	Arab	F	12	Recurrent >1 year	180	Both front	4, yes	Unknown	None	PBZ, GABA, ACE, LIDO, SIL	2	+
6	TB	F	Unknown	Recurrent >1 year	7	Both front	4, yes	Unknown	None	PBZ	10	+++
7	Arab	G	17	Recurrent >1 year	9	Both front	3, yes	Front limb laceration	None	PBZ	6	±
8	TB	F	13	Single episode	1	All four	4, yes	Large colon torsion and surgery	Post-surgery, Large colon resection-anastomosis	LIDO, DMSO, ICE, FM, ACE, BTF, ASP	2	±
9	QH	FX	22	Recurrent >1 year	30	Both front	3, yes	Unknown	Pedal osteitis, navicular disease	FCX	1	+++
10	PH	FX	13	Recurrent >1 year	17	Both front	3, yes	Surgery for ovariectomy	Post-ovariectomy, navicular disease	PBZ	1	++
11	QH	F	24	Recurrent >1 year	30	Both front	2, yes	Unknown	None	None	1	++

Breed abbreviations: Arab, Arabian horse; PH, Paint horse; QH, Quarter horse; STB, Standardbred; TB, Thoroughbred. Sex abbreviations: F, intact female; G, neutered male; FX, neutered female. Other abbreviations: WLD, white line disease.

^a Onset: time since onset of current episode and prior to treatment with ϵ -TUCB.

^b Severity: The Obel system [49] was used to categorise lameness severity: Grade 1: horses shift weight from one foot to the other or incessantly lift feet. Lameness is not evident at a walk, but at the trot horses will have a shortened stride. Grade 2: horses move willingly at a walk and trot but with a noticeably shortened and stabbing stride. A foot can be lifted off the ground without difficulty. Grade 3: horses move reluctantly and resist attempts to lift affected or contralateral feet. Grade 4: horses express marked reluctance or absolute refusal to move.

^c Medications: Medications used during episode and prior to adding ϵ -TUCB to treatment. ACE, acepromazine; ASP, aspirin; BTF, butorphanol; FCX, firocoxib; FM, flunixin meglumine; GABA, gabapentin; ICE, ice; KET, ketamine; LIDO, lidocaine; LIDO, lidocaine patch; PBZ, phenylbutazone, PTX, pentoxifylline.

^d Laminitis outcome: greatly improved, ++++; moderately improved, +++; slightly improved, ++; no change, ±.