

UCLA

UCLA Previously Published Works

Title

An 80-Year-Old Woman With Progressive Shortness of Breath and a Mediastinal Mass

Permalink

<https://escholarship.org/uc/item/2bf3v3vs>

Journal

CHEST Journal, 150(1)

ISSN

0012-3692

Authors

Zider, Alexander
Kamangar, Nader

Publication Date

2016-07-01

DOI

10.1016/j.chest.2016.01.025

Peer reviewed

An 80-Year-Old Woman With Progressive Shortness of Breath and a Mediastinal Mass



Alexander Zider, MD; and Nader Kamangar, MD, FCCP

An 80-year-old woman from Iran presented to our institution for evaluation of insidious onset of dyspnea and progressive hypoxemia. She had a history of hypertension, COPD attributed to secondhand smoke, and an unprovoked pulmonary embolus that was treated with lifelong anticoagulation. In addition, she had a history of latent TB status posttreatment with isoniazid 10 years prior. One year ago, home oxygen therapy was started at 4 L/min via nasal cannula, and because of her decline, her son had brought her to the United States 3 months earlier for medical help. After a contrast-enhanced thoracic CT scan followed by a nondiagnostic thoracentesis, another hospital informed her that she likely had inoperable lung cancer. She presented to our institution for a second opinion.

CHEST 2016; 150(1):e19–e22

At the time of presentation, the patient could only walk 15 m on oxygen; 5 years ago she could walk for several hours without difficulty. Additional symptoms included orthopnea, which required her to sleep with two to three pillows or in a recliner, and which was better in either left or right decubitus. She denied fevers, chills, night sweats, weight change, lower-extremity edema, paroxysmal nocturnal dyspnea, dysphagia, cough, hemoptysis, or any other symptoms. Home medications included atenolol, spironolactone, and warfarin. She had no smoking history but she did have 30 years of exposure to secondhand smoke. She had no pets at home, and prior to this trip she had never previously traveled outside Iran.

Physical Examination Findings

The patient appeared to be her stated age, well-nourished, and comfortable at rest on 4 L oxygen. Her vital signs were as follows: temperature, 36.4°C; pulse, 81

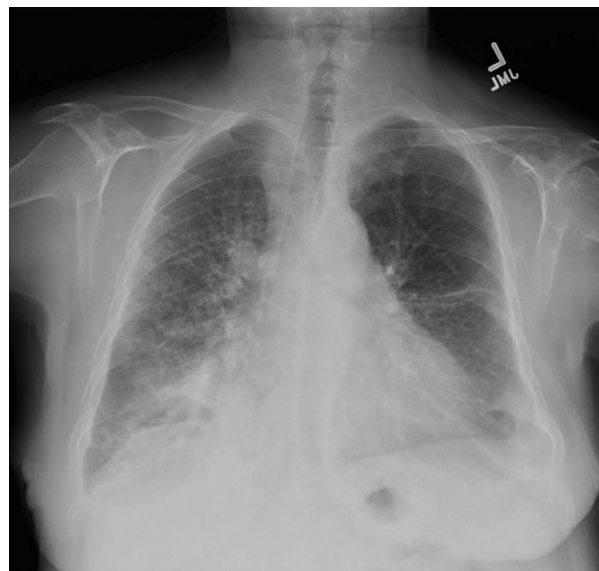

Figure 1 – Chest radiograph shows an ill-defined right peri or infra-hilar density, a right-sided reticulonodular opacities, and a bilateral small pleural effusions.

AFFILIATIONS: From the Division of Pulmonary and Critical Care Medicine (Drs Zider and Kamangar) and the UCLA-Olive View Medical Center (Dr Kamangar), David Geffen School of Medicine at UCLA, University of California, Los Angeles, Sylmar, CA.

CORRESPONDENCE TO: Nader Kamangar, MD, FCCP, Division of Pulmonary and Critical Care Medicine, Department of Medicine, UCLA-Olive View Medical Center, David Geffen School of Medicine at

UCLA, 14445 Olive View Dr, Rm 2B-182, Sylmar, CA 91342; e-mail: kamangar@ucla.edu

Copyright © 2016 American College of Chest Physicians. Published by Elsevier Inc. All rights reserved.

DOI: <http://dx.doi.org/10.1016/j.chest.2016.01.025>

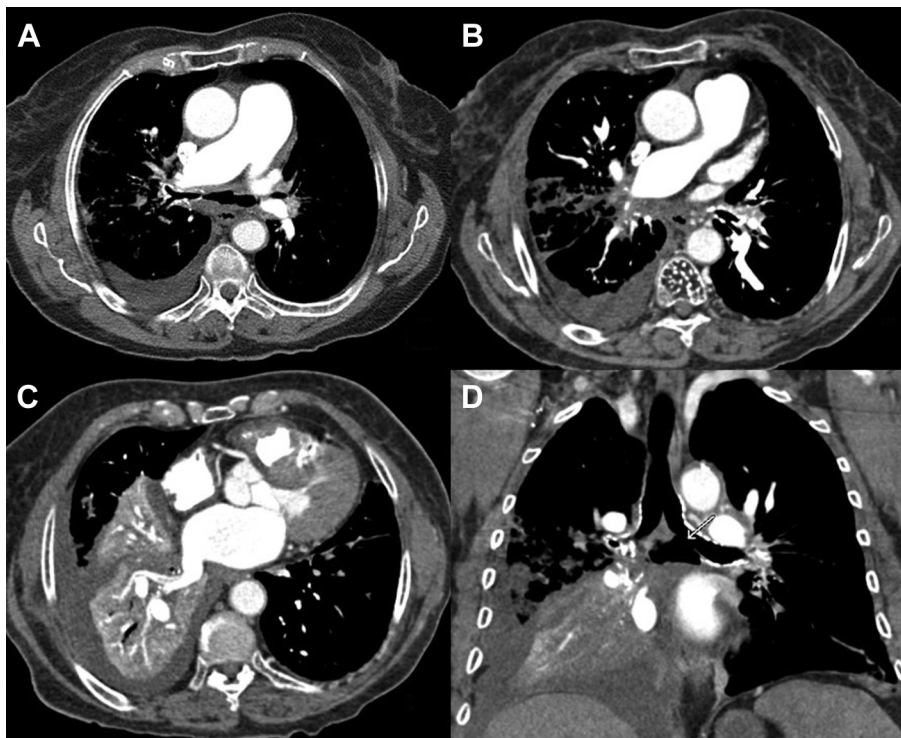


Figure 2 – Soft tissue window chest CT scan shows significant narrowing and diffuse calcification of the right mainstem and an enlarged main pulmonary artery (A), an infiltrative ill-defined right hilar density with compression of the right pulmonary artery (B), narrowing of the right inferior pulmonary, right lower and middle lobe atelectasis, and a generous sized left atrium (C), and a large-sized left mainstem broncho-mediastinal fistula with gas in the subcarinal space (D).

beats/min; BP, 132/66 mm Hg; respiratory rate, 18 breaths/min; and oxygen saturation, 95% while on 4 L oxygen via nasal cannula. Significant physical examination findings included decreased breath sounds at the posterior right lower lung field. Cardiovascular, oropharyngeal, abdominal, lymphatic, and genitourinary examinations were unremarkable.

Diagnostic Studies

Laboratory data on presentation were as follows: WBC count, $10^3/\mu\text{L}$; hemoglobin count, 14.3 g/dL. Liver function test and basic chemistry values were unremarkable. Chest radiograph image was notable for an enlarged cardiac silhouette; an ill-defined right perihilar density; right-sided reticulonodular opacities; and bilateral small pleural effusions (Fig 1). Contrast-enhanced thoracic CT scan demonstrated the following: (1) an infiltrative right hilar soft tissue mass-like density with narrowing of the right mainstem bronchus and partial collapse of the right middle and lower lobes; (2) extensive mediastinal and hilar calcifications; (3) narrowing of the pulmonary veins, and narrowing and irregularity of the proximal mainstem bronchi; (4) large-sized fistula between the left mainstem

bronchus and subcarinal space; (5) extensive collaterals involving the intercostal and bronchial arteries; (6) postobstructive changes in the right lung as evidenced by consolidation, interlobular septal thickening, and centrilobular micronodules; and (7) small right-sided pleural effusion (Fig 2A-D). Sputa were positive for acid-fast bacilli (AFB) smear (4+; >90 AFB/field at $\times 200$ magnification); nucleic acid amplification was positive for *Mycobacterium tuberculosis*. AFB cultures subsequently grew a pansensitive strain of *M. tuberculosis*.

Question: What is the cause of this patient's shortness of breath and CT scan findings?

Answer: Fibrosing mediastinitis caused by TB.

Discussion

Fibrosing mediastinitis, also known as sclerosing mediastinitis and mediastinal fibrosis, is a rare disorder characterized by chronic inflammation and fibrosis of mediastinal soft tissues most commonly caused by granulomatous infections such as histoplasmosis and TB. The cause is likely an abnormal fibroproliferative response to an inflammatory stimulus that leads to encasement of mediastinal structures within a dense fibrotic mass. The condition is often progressive and can occur either focally or diffusely throughout the mediastinum.

Fibrosing mediastinitis was first described in the medical literature more than 100 years ago. In one of the earliest reports, Keefer described seven patients with chronic mediastinitis largely caused by syphilis, resulting in tracheal stenosis, aortic aneurysm, and thrombosis of major vessels. Although in more recent literature histoplasmosis is the most frequently noted cause of fibrosing mediastinitis, it has also been reported in the setting of other granulomatous disease such as TB and sarcoidosis, as well as Behçet disease, Hodgkin disease, trauma, and drug therapy with methysergide maleate. Patients with idiopathic immune-mediated fibrosing mediastinitis frequently have other disease manifestations such as retroperitoneal fibrosis or thyroiditis, all of which have been associated with the immunoglobulin (Ig)G4-related disease spectrum. Furthermore, recent studies have shown that up to one-third of granulomatous disease-associated fibrosing mediastinitis demonstrates histopathologic features of the IgG4-related disease spectrum. Among patients with TB, tuberculous lymphadenitis represents a more common extrapulmonary manifestation of the disease which is distinctly different from fibrosing mediastinitis, in that it involves enlargement of lymph nodes that remain discrete and encapsulated. Unlike tuberculous fibrosing mediastinitis, lymphadenitis—which does not involve irreversible proliferation of dense fibrous tissue—responds to antimycobacterial therapy.

The clinical presentation of fibrosing mediastinitis depends on the structures of the mediastinum that are affected. The most common clinical manifestations resulting from involvement of the central airways are dyspnea, cough, and hemoptysis. Esophageal involvement may result in dysphagia and chest pain.

Entrapment and compression of the recurrent laryngeal nerve can cause hoarseness. Superior vena cava (SVC) involvement is another common cause of clinical abnormalities, however, symptoms can be subtle since the obstruction develops gradually, which allows the collateral veins to form and divert much of the collateral flow. Obstruction of the main pulmonary arteries may result in pulmonary hypertension and cor pulmonale. Stenosis of the large central pulmonary veins can cause pulmonary venous hypertension and edema in a clinical setting similar to severe valvular mitral stenosis.

Chest radiographs are usually nonspecific and often underestimate the extent of mediastinal disease. Contrast-enhanced thoracic CT allows excellent evaluation of the extent of mediastinal soft tissue infiltration and calcification, and can identify narrowing of the tracheobronchial tree. Obliteration of fat planes of the mediastinum and the presence of discrete masses and/or extensive calcified paratracheal, hilar, and subcarinal lymphadenopathy causing circumferential encasement of the mediastinal structures are strongly suggestive of fibrosing mediastinitis. Bronchial narrowing most commonly affects the right mainstem bronchus and frequently is associated with obstructive pneumonitis, atelectasis, or both. Prior case series reported that bronchial obstruction occurred in up to 29% of patients, with pathology showing invasion of fibrous tissue (rather than compression by a mass) leading to constriction of a bronchus. As was seen in this patient before her evaluation at our institution, it can be challenging to distinguish a discrete mass from a malignant process such as bronchogenic carcinoma, despite enhanced imaging modalities.

In adult TB patients, bronchomediastinal fistula has been rarely reported whereas bronchoesophageal and esophagomediastinal fistulae have been described, especially in patients with HIV. We suspect that the patient's mediastinitis led to chronic bronchial inflammation, with eventual erosion of the airway. We also suspect that this patient's bronchomediastinal fistula significantly contributed to the high mycobacterial burden noted in the sputum. Previous case series have demonstrated growth of *M. tuberculosis* from fine-needle aspirates of lymph nodes as well as excisional lymph node biopsies, via mediastinoscopy or thoracotomy, demonstrating typical histological findings. Previous reports have described healing of bronchoesophageal fistulae with antituberculous therapy.

There is no proven effective medical therapy for fibrosing mediastinitis. Most available data are based on case reports or small case series of patients with fibrosing mediastinitis caused by histoplasmosis. Although controlled trials have not been performed, glucocorticoids do not appear to be beneficial. The only exception, which is currently being investigated, may be the treatment effects of glucocorticoids and/or other immunosuppressive agents in patients with fibrosing mediastinitis who have diagnostic features of IgG4-related disease. The prognosis of fibrosing mediastinitis caused by TB is generally favorable, particularly in patients whose initial symptoms can be relieved surgically or via bronchoscopically placed airway stents in cases of airway or esophageal obstruction, or via percutaneous vascular stents for treatment of SVC obstruction.

Clinical Course

The patient was transferred to the TB ward and started on rifampin, isoniazid, pyrazinamide, and ethambutol. After 6 weeks of hospitalization, she became negative for AFB smear and was discharged home. After 8 weeks of rifampin, isoniazid, pyrazinamide, and ethambutol, she was transitioned to rifampin and isoniazid alone. As the bronchomediastinal fistula was asymptomatic, and because of the infectious risks, we elected to defer bronchoscopic evaluation until she had been fully treated for TB. A follow-up chest CT scan 3 months after discharge showed a significant decrease in the size of the bronchomediastinal fistula and subcarinal gas.

Clinical Pearls

1. *Fibrosing mediastinitis is a potential complication of Histoplasma and M. tuberculosis infections.*
2. *The signs and symptoms of fibrosing mediastinitis depend on the structures of the mediastinum that are involved and the extent to which they are compromised. Most patients typically present with signs and symptoms of obstruction or compression of the central airways and/or SVC.*
3. *In patients with clinical findings suggesting fibrosing mediastinitis, the presence of a localized calcified*

mediastinal soft tissue mass can be diagnostic of fibrosing mediastinitis caused by previous histoplasmosis or TB.

4. *Fibrosing mediastinitis can mimic a bronchogenic carcinoma and should be kept in the differential diagnosis of mediastinal mass lesions of unknown cause.*
5. *Fibrosing mediastinitis can lead to fistulae, including bronchomediastinal fistulae, which may heal with treatment of the underlying cause.*

Acknowledgments

Financial/nonfinancial disclosures: None declared.

Other contributions: CHEST worked with the authors to ensure that the Journal policies on patient consent to report information were met.

Suggested Readings

Keefe CS. Acute and chronic mediastinitis: a study of sixty cases. *Arch Intern Med.* 1938;62:109.

Goodwin RA, Nickell JA, Des Prez RM. Mediastinal fibrosis complicating healed primary histoplasmosis and tuberculosis. *Medicine (Baltimore).* 1972;51(3):227-246.

Dines DE, Payne WS, Bernatz PE, et al. Mediastinal granuloma and fibrosing mediastinitis. *Chest.* 1979;75(3):320-324.

Loyd JE, Tillman BF, Atkinson JB, et al. Mediastinal fibrosis complicating histoplasmosis. *Medicine (Baltimore).* 1988;67(5):295-310.

Porter JC, Friedland JS, Freedman AR. Tuberculous bronchoesophageal fistulae in patients infected with the human immunodeficiency virus: three case reports and review. *Clin Infect Dis.* 1994;19(5):954-957.

Mole TM, Glover J, Sheppard MN. Sclerosing mediastinitis: a report on 18 cases. *Thorax.* 1995;50(3):280-283.

Kawamoto H, Kambe M, Takahashi H, et al. A case of cervical-mediastinal lymph node tuberculosis progressed to pulmonary lesion through a bronchial fistula. *Nihon Kokyuki Gakkai Zasshi.* 1998;36(12):1053-1057.

Geldmacher H, Taube C, Kroeger C, et al. Assessment of lymph node tuberculosis in northern Germany: a clinical review. *Chest.* 2002;121(4):1177-1182.

Peikert T, Colby TV, Midthun DE, et al. Fibrosing mediastinitis: clinical presentation, therapeutic outcomes, and adaptive immune response. *Medicine (Baltimore).* 2011;90(6):412-423.

Peikert T, Shrestha B, Aubry MC, et al. Histopathologic overlap between fibrosing mediastinitis and IgG4-related disease. *Int J Rheumatol.* 2012;2012:207056.

Ryu JH, Sekiguchi H, Yi ES. Pulmonary manifestations of immunoglobulin G4-related sclerosing disease. *Eur Respir J.* 2012;39(1):180-186.

Koksai D, Bayiz H, Mutluay N, et al. Fibrosing mediastinitis mimicking bronchogenic carcinoma. *J Thorac Dis.* 2013;5(1):E5-E7.