

# UCLA

## UCLA Previously Published Works

### Title

Closed Sagittal Band Injury from a Low-Energy Impact: A case report

### Permalink

<https://escholarship.org/uc/item/2cm1h7w1>

### Journal

The UCLA Radiological Sciences Proceedings, 1(1)

### Authors

Lin, Jonathan, MD

Chen, Johnathan, MD

### Publication Date

2020-10-01

### Data Availability

The data associated with this publication are within the manuscript.

Peer reviewed

# Closed Sagittal Band Injury from a Low-Energy Impact: A case report

Lin J, MD | Chen J, MD

**Author Affiliation:** Department of Radiological Sciences, UCLA David Geffen School of Medicine

**Corresponding Author:** JL ([jolin@mednet.ucla.edu](mailto:jolin@mednet.ucla.edu))

*The UCLA Radiol Sci Proc.* 2020;1(1):6-8.

**Abstract:** One of the three components of the dorsal extensor hood, the sagittal band is a sheet of connective tissue that provides lateral stability to the extensor digitorum tendon at the metacarpophalangeal joint. Rupture of one of the two portions of the sagittal band can lead to contralateral subluxation or dislocation of the extensor tendon. Closed sagittal band injury is commonly associated with high-energy impact or inflammatory conditions, such as rheumatoid arthritis. In cases of high-energy impact, a closed sagittal band injury may co-occur with a “boxer’s knuckle,” the metacarpophalangeal joint and the extensor mechanism injury that has been historically reported in boxers after blunt impact to the joint in forceful flexion. In this case report, we present a 64-year-old woman with no known history of rheumatoid arthritis and with a closed sagittal band injury received while using the fists to support changing her body position in bed. Ultrasonography and MRI are useful in the evaluation of a sagittal band injury. The use of dynamic ultrasound imaging can help visualize the extensor tendon subluxation with metacarpophalangeal joint flexion and confirm the diagnosis of sagittal band injury.

**Keywords:** sagittal band; extensor tendon injury; boxer’s knuckle; metacarpophalangeal joint

## Case Presentation

A 64-year-old woman with no known history of rheumatoid arthritis or other inflammatory disease developed pain in the left long finger while using the fists to support changing her body position in bed. The patient experienced a popping sensation and then intermittent pain that was worse with finger flexion. On physical examination, there was swelling of the metacarpophalangeal (MCP) joint and tenderness at the site of the radial portion of the sagittal band (SB). The examination also revealed subluxation of the extensor tendon (ET) upon third MCP joint flexion. Radiographs showed soft tissue swelling along the dorsum of the third MCP joint without evidence of a fracture. Dynamic ultrasound imaging demonstrated normal echogenicity of the ET and its ulnar subluxation at

## Key Points

Although commonly associated with high-energy impact and inflammatory conditions, sagittal band injuries can also be caused by low-energy impact in patients with no history of rheumatoid arthritis. Dynamic ultrasonography is useful in the diagnosis of sagittal band injury.

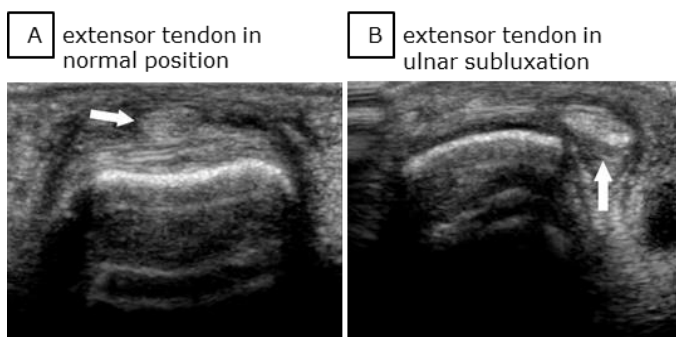
the third MCP joint during the joint flexion (Figure 1). The patient was managed non-operatively, with an appropriate splint, until near resolution of the symptoms.

## Discussion

The extensor tendon courses over the MCP joint and inserts its middle and lateral tendon slips onto

the bases of the middle and distal phalanxes, respectively. In its course through the phalanx, the ET is stabilized by the dorsal extensor hood, a fibrous tissue that is composed of the transverse, the oblique, and the sagittal bands. The SB originates from the volar plate of the metacarpal neck and intermetacarpal ligament and courses

**Figure 1.** Transverse US Images of the Third Extensor Digitorum Tendon at the Distal Third Metacarpal Bone.



A, B. The extensor digitorum tendon (A, arrow) is in normal position relative to the dorsal metacarpal bone (A). Ulnar subluxation of the tendon (B, arrow) with flexion of the metacarpophalangeal joint (B).

dorsally to either side of the ET to provide its lateral stability (Figure 2). The SB consists of a thin superficial and a thick deep layers that form a tunnel to house the ET.

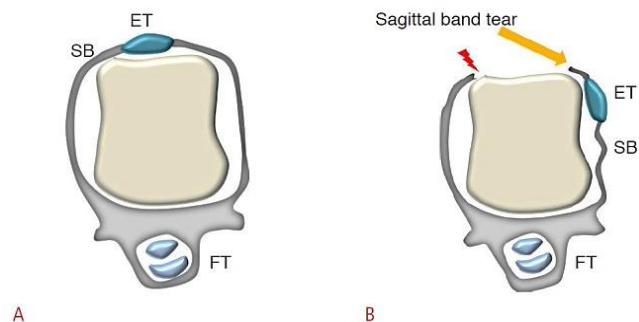
Sagittal band injuries are commonly due to high-energy impact or chronic inflammation associated with rheumatoid arthritis.<sup>1</sup> Extensor tendon instability, in these cases, is typically a result of disruption of the radial portion of the sagittal band at the level of the MCP joint and most commonly involves the long finger.<sup>1-3</sup> The mechanism of injury is thought to be caused by blunt or compressive force resulting in extreme MCP joint flexion while the wrist is in palmar flexion and ulnar deviation.<sup>1</sup> The unopposed lateral force from the intact ulnar portion of the SB leads to ulnar subluxation or dislocation of ET on finger flexion. In cases of high-energy impact, a closed SB injury may co-occur with a "boxer's knuckle," the MCP joint and the extensor mechanism injury that has been historically reported in boxers after blunt impact to the joint in forceful flexion.<sup>1</sup>

In addition, as it was described in our case presentation, sagittal band injuries might be a result of low-energy impact, such as weight bearing with the fists. These are less common,

spontaneous injuries.<sup>4,5</sup> The mechanism of this type of injuries is attributed to excessive traction stress on flexed fingers forced ulnarward, exertion of torsional force on extended MCP joint, or forceful pushing fingers into ulnar deviation with the wrist in palmar flexion and ulnar deviation.<sup>6-8</sup> Following this traumatic injury, patients commonly present with a painful and swollen MCP joint. Most of these cases can be managed with splinting, while surgery is indicated for chronic persistent painful subluxation or dislocation, when conservative treatment fails.<sup>1,7,9</sup>

Ultrasonography and MRI are useful in the evaluation of SB injuries.<sup>10</sup> Both modalities can be used to assess the signs of injury as well as the positioning and integrity of the extensor tendon. Subluxation may be difficult to appreciate on

**Figure 2.** Schematic Images of the Sagittal Band and Sagittal Band Tears.



A, B. At the metacarpophalangeal joint, the extensor tendons are stabilized by the extensor hood and particularly by the sagittal band (A). Subluxation or dislocation of the extensor tendon (ET) occurs because of a tear (arrow and lightning bolt icon) in the sagittal band (B). (ET, extensor tendon; FT, flexor tendon; SB, sagittal band).<sup>11</sup>

Republished under the Creative Commons Attribution (CC BY-NC 3.0). (<https://creativecommons.org/licenses/by-nc/3.0/legalcode>)

physical examination if there is significant swelling. The use of dynamic ultrasound imaging can help visualize the ET subluxation with MCP flexion and confirm the diagnosis of SB injury.<sup>10,11</sup>

### Author Contributions

Conceptualization, J.C. and J.L.; Writing – original draft preparation, J.L.; Review and editing, J.C. and J.L.; Supervision, J.C. All authors agree to be accountable for all aspects of the work in ensuring that questions related to the accuracy or integrity of any part of the work are appropriately investigated and resolved. All authors had full access to all the

data in the study and take responsibility for the integrity of the data and the accuracy of the data analysis.

## Disclosures

None to report.

## References

1. Kleinhenz BP, Adams BD. Closed sagittal band injury of the metacarpophalangeal joint. *J Am Acad Orthop Surg.* 2015;23(7):415-423. DOI: [10.5435/JAAOS-D-13-00203](https://doi.org/10.5435/JAAOS-D-13-00203)
2. Young CM, Rayan GM. The sagittal band: anatomic and biomechanical study. *J Hand Surg Am.* 2000;25(6):1107-1113. DOI: [10.1053/jhsu.2000.18495](https://doi.org/10.1053/jhsu.2000.18495)
3. Inoue G, Tamura Y. Dislocation of the extensor tendons over the metacarpophalangeal joints. *J Hand Surg Am.* 1996; 21(3):464-469. DOI: [10.1016/S0363-5023\(96\)80364-9](https://doi.org/10.1016/S0363-5023(96)80364-9)
4. Capo JT, Shamian B, Rossy W, Hashem J. Closed sagittal band injury due to low energy trauma. *Am J Orthop.* (Belle Mead NJ). 2012 Aug;41(8):374-7. PMID: 22900250. <https://www.researchgate.net/publication/230686656>
5. Ishizuki M. Traumatic and spontaneous dislocation of extensor tendon of the long finger. *J Hand Surg Am.* 1990 Nov;15(6):967-72. DOI: [10.1016/0363-5023\(90\)90025-m](https://doi.org/10.1016/0363-5023(90)90025-m)
6. Kamiya M, Sasaki G, Ikuta K, Miyamoto H, Kimura M, Kawano H. Extensor tendon dislocation at the metacarpophalangeal joint of both ring fingers caused by a specific hand posture in a shiatsu therapist. *Case Rep Orthop.* 2020;ID6842986. Published online September 23, 2020. <https://doi.org/10.1155/2020/6842986>
7. Rayan GM, Murray D. Classification and treatment of closed sagittal band injuries. *J Hand Surg Am.* 1994;19(4):590-594. DOI: [10.1016/0363-5023\(94\)90261-5](https://doi.org/10.1016/0363-5023(94)90261-5)
8. Boyes JH, ed. *Bunnell's Surgery of the Hand.* 5th ed. Philadelphia: JB Lippincot; 1970:444.
9. Grandizio LC, Klena JC. Sagittal band, boutonniere, and pulley injuries in the athlete. *Curr Rev Musculoskelet Med.* 2017;10(1):17-22. DOI: [10.1007/s12178-017-9379-6](https://doi.org/10.1007/s12178-017-9379-6)
10. Lopez-Ben R, Lee DH, Nicolodi DJ. Boxer knuckle (injury of the extensor hood with extensor tendon subluxation): diagnosis with dynamic US – report of three cases. *Radiology.* 2003;228(3):642-646. DOI: [10.1148/radiol.2283020833](https://doi.org/10.1148/radiol.2283020833)
11. Lee SA, Kim BH, Kim SJ, Kim JN, Park SY, Choi K. Current status of ultrasonography of the finger. *Ultrasonography.* 2016;35(2):110-123. DOI: [10.14366/usq.15051](https://doi.org/10.14366/usq.15051)