

UCLA

UCLA Previously Published Works

Title

A Fatal Case of Penile Calciphylaxis.

Permalink

<https://escholarship.org/uc/item/2cx6807j>

Authors

D'Assumpcao, Carlos
Sharma, Rupam
Bugas, Addie
[et al.](#)

Publication Date

2022

DOI

10.1177/23247096221076275

Copyright Information

This work is made available under the terms of a Creative Commons Attribution-NonCommercial License, available at <https://creativecommons.org/licenses/by-nc/4.0/>

Peer reviewed

A Fatal Case of Penile Calciphylaxis

Journal of Investigative Medicine High
Impact Case Reports
Volume 10: 1–8
© 2022 American Federation for
Medical Research
DOI: 10.1177/23247096221076275
journals.sagepub.com/home/hic



Carlos D'Assumpcao, MD¹ , Rupam Sharma, MD¹ ,
Addie Bugas, MD¹, Arash Heidari, MD¹ ,
Rick A. McPheeters, DO¹, and Shahab Hillyer, MD¹

Abstract

Calciphylaxis is a rare and serious complication of chronic renal failure characterized by vascular calcium overload. It has a high mortality rate. Penile calciphylaxis is an extremely rare condition of penile necrosis due to calciphylaxis of the penile arterioles. Presented here is a severe case of systemic calciphylaxis initially presented as penile necrosis treated with sodium thiosulfate and amputation.

Keywords

penile calciphylaxis, calcific uremic arteriolopathy, sodium thiosulfate, penectomy, coccidioidomycosis, pneumonectomy, epididymitis

Introduction

Penile calciphylaxis, or calcific uremic arteriolopathy of penile arteries, is a rare but devastating presentation of calciphylaxis, a condition predominantly seen in chronic kidney failure patients treated with dialysis. Morbidity is related to severe pain, nonhealing wounds, recurrent hospitalizations, and adverse effects of treatments.¹ Sodium thiosulfate has had reported success in case reports.² This case report presents a challenging case of penile calciphylaxis associated with end-stage renal disease (ESRD) and diabetes mellitus type 2 resulting in necrosis of the glans penis with eventual penectomy.

Case Report

A 38-year-old Latin male with uncontrolled diabetes mellitus, hypertension, and left pneumonectomy secondary to thoracic gunshot wound 12 years prior presented to our institution with a 2-week history of dyspnea and productive cough. In addition, he also complained of 2-week history of dysuria and bilateral lower extremity edema.

On physical examination, severe tenderness was noted upon palpation of the penis and scrotum along with yellow-white discharge from the penile stump. Examination of the upper and lower extremities revealed multiple diffuse brown lesions including medial aspect of thighs bilaterally and left lower leg.

Laboratory markers at admission included albumin 1.8 g/dL (3.4–5.0 g/dL), corrected serum calcium 8.6 mg/dL (normal 8.5–10.1 mg/dL), serum phosphate 12.1 mg/dL (normal

2.5–4.9 mg/dL), serum magnesium intact parathyroid hormone 1403 pg/mL (normal 14–72 pg/mL), blood urea nitrogen 140 mg/dL (7–18 mg/dL), serum creatinine of 18.5 mg/dL from baseline of 6 mg/dL (normal 0.8–1.3 mg/dL), white blood cell count 20×10^3 cells/ μ L (normal $4\text{--}11 \times 10^3$ cells/ μ L) (Image 1A–F).

Chlamydia and gonorrhoeae ribonucleic acid polymerase chain reaction, qualitative syphilis antibody, and human immunodeficiency virus antigen/antibody assays were all negative. Initial diagnosis was sepsis of unknown source and congestive heart failure secondary to acute chronic renal failure. Cardiopulmonary evaluation incidentally revealed cardiomegaly involving the entire left pulmonary potential space (Image 2A), pulmonary hypertension (estimated right ventricular systolic pressure 82.1 mm Hg [35–50 mm Hg] on transthoracic echocardiogram), and a large coronary sinus.

In following hospital days his dyspnea improved with administration of furosemide and initiation of dialysis. Calcitriol, sevelamer carbonate, and cinacalcet were started with appropriate response in parathyroid hormone and

¹Kern Medical, Bakersfield, CA, USA

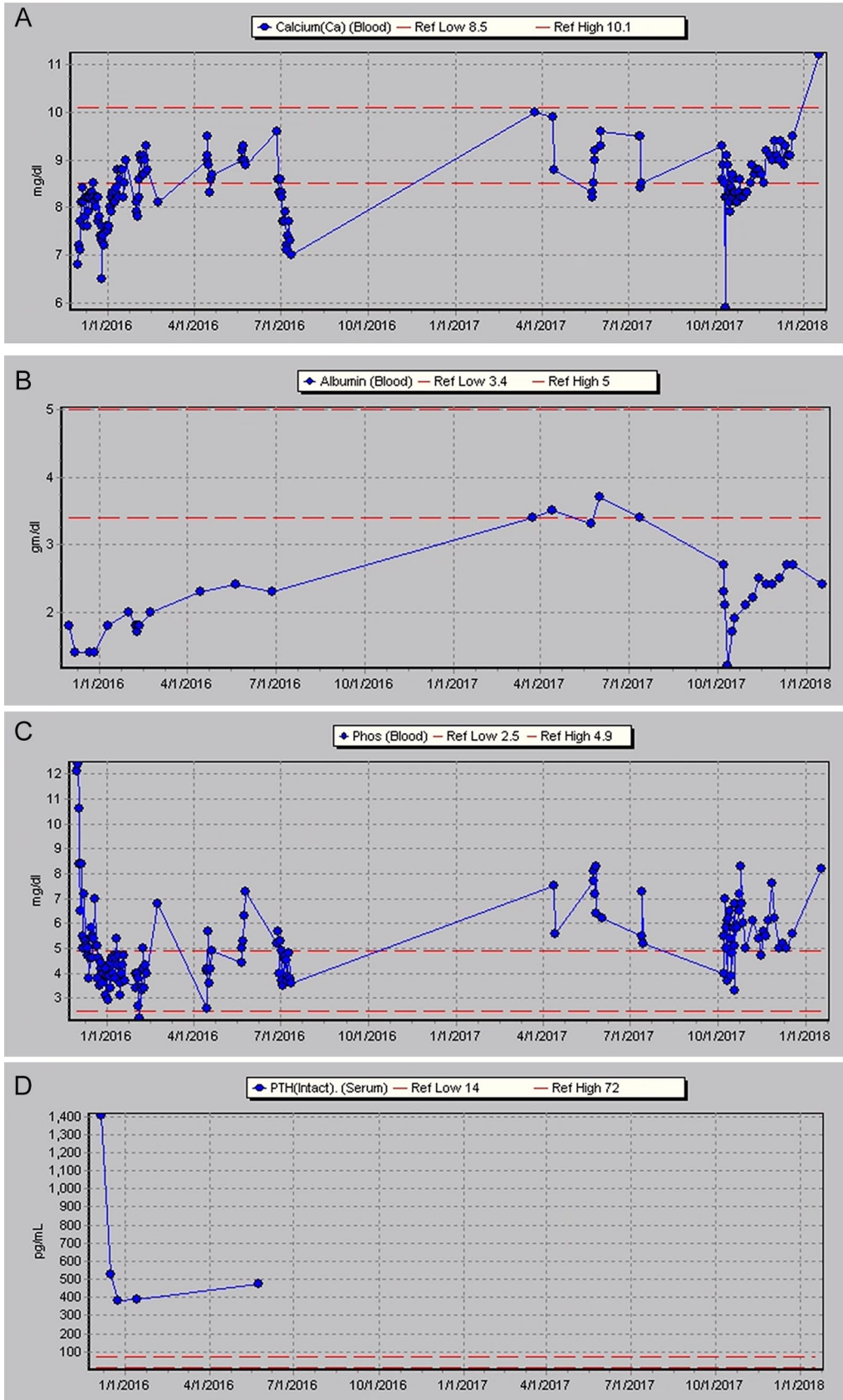
Received September 9, 2021. Revised January 7, 2022. Accepted January 9, 2022.

Corresponding Author:

Carlos D'Assumpcao, MD, Division of Infectious Diseases, Department of Medicine, Kern Medical, 1700 Mount Vernon Avenue, Bakersfield, CA 93306, USA.

Email: cdassumpcao@gmail.com





(continued)

Image I. (continued)

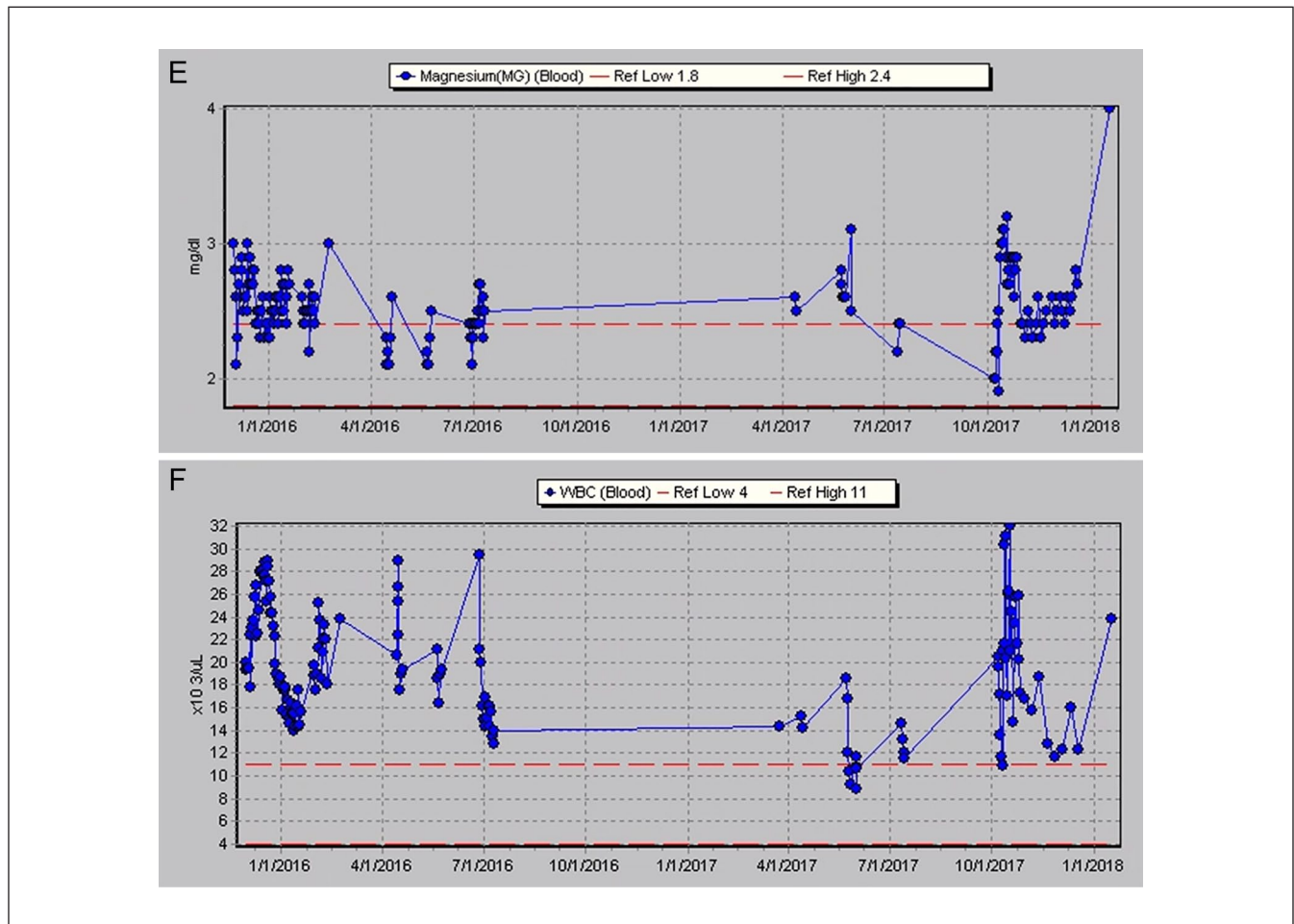


Image I. (A) Serum calcium from initial presentation until patient's death. These absolute values are not adjusted for serum albumin. (B) Serum albumin from initial presentation until patient's death. After calciphylaxis treatment, patient's nutritional status did improve over time as evident by his normalized albumin. However, severe pulmonary coccidioidomycosis in 2017 severely affected his overall health. (C) Serum phosphate levels from patient's initial presentation to death. Calcium phosphate product at presentation, adjusted for albumin, was 104. Sevelamer initiation helped with normalizing serum phosphate levels. At discharge, calcium phosphate product, adjusted for albumin, was 47. (D) Serum intact parathyroid hormone at initial presentation was 1403 pg/mL. After cinacalcet, calcitriol, and sevelamer initiation, hormone levels improved to more acceptable range for secondary hyperparathyroidism in end-stage renal disease patients. (E) Serum magnesium levels from initial presentation until patient's death. (F) White blood cell counts from initial presentation until patient's death. Persistent leukocytosis at presentation did not improve until after sodium thiosulfate initiation despite ICU resuscitation and broad-spectrum antibiotics.

calcium phosphate product. On hospital day 12, skin rashes progressed to necrotic eschars (Image 3C and D). He developed severe pain in his lower extremities, hindering his ability to participate with physical therapy. Imaging of his lower extremities revealed calcification of bilateral quadriceps, circumferential calcification of bilateral femoral and external and internal iliac arteries as well as the penile arteries in the cavernosum (Images 4A-C and 5).

Penile pain did not improve, developing paraphimosis that was reduced at bedside but then developed into phimosis. A diagnosis of penile uremic calciphylaxis was made by physical examination. No debridement was recommended

due to concern for poor wound healing postoperatively. Sodium thiosulfate was administered during the last hour of each hemodialysis session. Calcitriol was held due to concern for increasing serum calcium that may further cause precipitation of calciphylactic lesions. He reported decrease in pain and increase in mobility. Leukocytosis improved. Skin lesions began to heal. Unfortunately, the necrosis of the glans penis progressed wet-gangrene requiring a partial penectomy. Penile stump demonstrated poor healing due to lack of blood flow with areas of necrosis developing. Discussion was held with patient about the use of leeches over penile stump which he adamantly refused. A Foley remained in

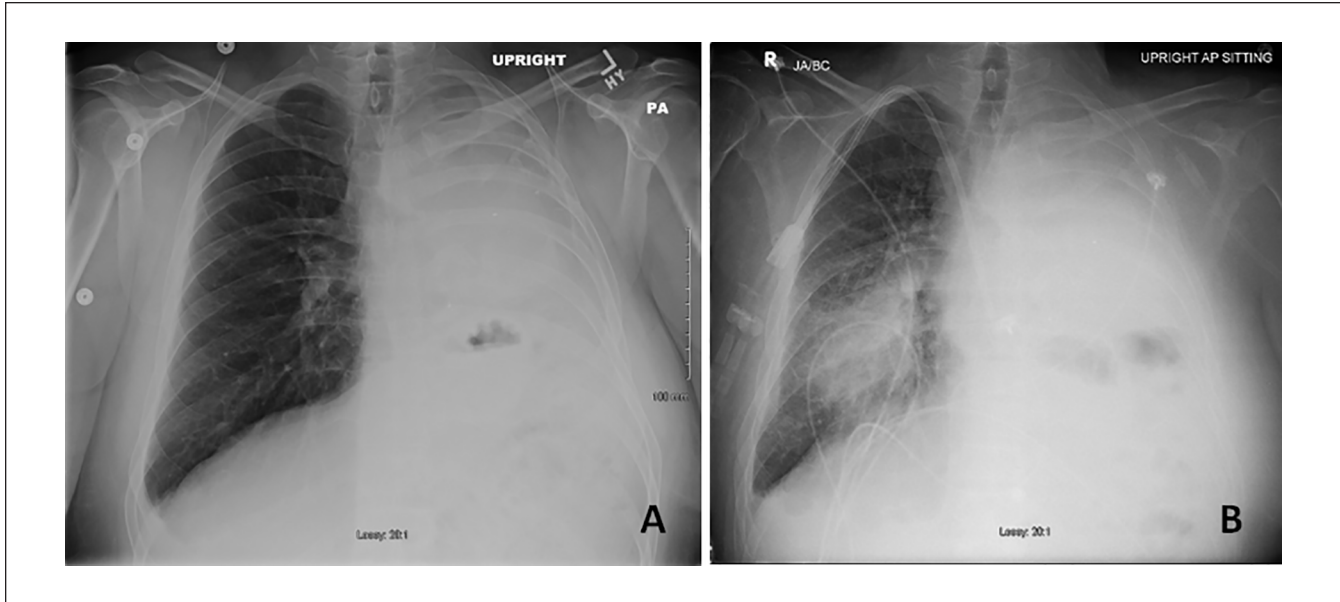


Image 2. (A) Presenting chest x-ray showing pneumonectomy. (B) Follow-up chest x-ray about 1 year later demonstrating location of severe primary pulmonary coccidioidomycosis for which he tolerated 12 weeks of liposomal amphotericin B.

place with catheter changes every 4 weeks due to meatal stricture from lack of blood flow. Forty-five days post hospital course he was discharged with continued outpatient hemodialysis.

After discharge, he had multiple hospital admissions for skin and soft-tissue infections of lower extremity and dyspnea that resolved with antibiotics, dialysis, and sodium thiosulfate administration. He developed gangrenous soft-tissue infection overlying right fifth metatarsal osteomyelitis requiring a below-the-knee amputation due to severe peripheral vascular disease. He developed *Escherichia coli* and *Pseudomonas aeruginosa* epididymitis secondary to chronic Foley placement (Image 3B) and so a suprapubic catheter was placed. Intravenous (IV) antibiotics were given post hemodialysis. He was eventually stable on sevelamer carbonate as outpatient and lesions healed completely with residual scarring. Hypertension and fluid volume were managed with hemodialysis. He developed severe pulmonary coccidioidomycosis in his remaining right lung with hypoxemia (Image 2B) and received IV liposomal amphotericin B therapy with prednisone taper. Further complications included vision loss.

Two years post initial calciphylaxis diagnosis, he suffered a cardiac arrest. Diagnostic cardiac catheterization performed after return of spontaneous circulation found heavily calcified left main, circumflex (100% occluded with extensive collaterals), left anterior descending (85%-90% proximal occlusion), and right coronary artery (60%-75% occlusions). He was transferred for percutaneous coronary intervention (PCI) however did not recover from repeated cardiac arrests despite maximal resuscitative attempts made after transfer at PCI center.

Discussion

Rudolf Virchow first described an association between renal failure and soft-tissue calcification.³ Bryant and White in 1898 showed an association between cutaneous necrosis and vascular calcification in a 6-month-old child.⁴ In 1962, Janos Hugo Bruno “Hans” Selye defined calciphylaxis as a biological process in which selective calcification may be produced experimentally in areas of body of a “sensitized” animal by the administration of a “challenger.”⁵ In 1969, in communication with Selye, Rees found that intramuscular iron dextran injections had precipitated calciphylaxis in the injection sites on the thighs of a patient with refractory glomerulonephritis renal failure.⁶ Modern understanding of the calciphylaxis does not typically follow the sensitized/challenger model of tissue phylaxis with calcium deposits as described by Selye anymore, but the calciphylaxis name stuck. Ever since, the number of case reports reporting calciphylaxis in different tissues in uremic and nonuremic patients has been growing. Sagar Nigwaker et al summarized the risk factors, diagnosis, and treatment of calciphylaxis well in 2015; were involved in several clinical trials with sodium thiosulfate; and even established the calciphylaxis program at Massachusetts General Hospital. However, penile calciphylaxis is still rarely reported.

The diagnosis of penile calciphylaxis was made due to matching histopathophysiology. Calcification and fibrointimal hyperplasia of the medial layer of small arteries and arterioles with microthrombosis leading to tissue ischemia are common findings on skin biopsies.¹ Having this pathophysiology occur in the vascular rich structures of the penis causing progressive ischemia of the penile tissues can explain the

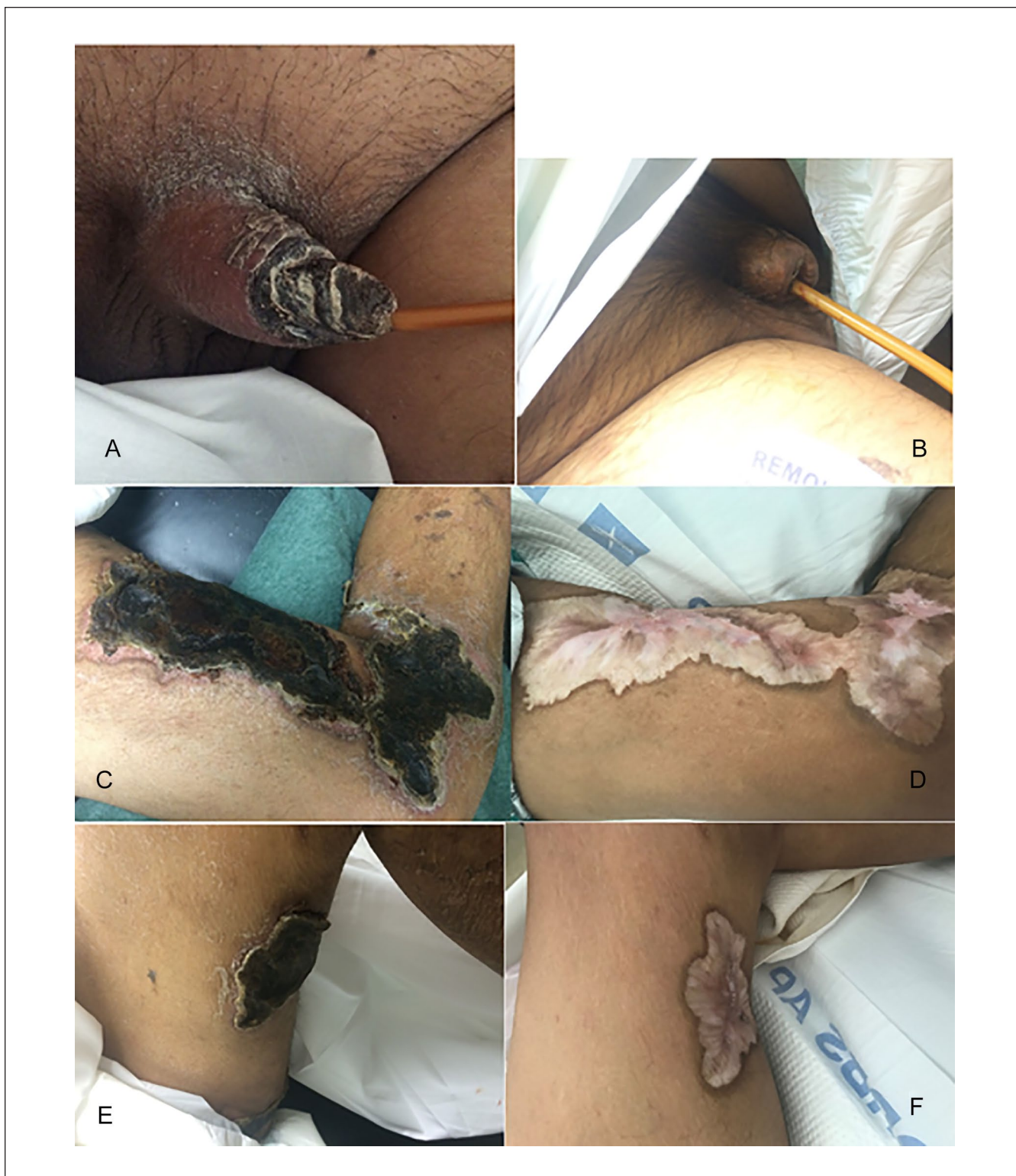


Image 3. (A) Penis after penectomy and after sodium thiosulfate while inpatient. (B) Penis at time of epididymitis diagnosis after penectomy and after repeated sodium thiosulfate therapy as outpatient showing well-healed remnant of distal penis. (C) Right medial thigh before sodium thiosulfate showing black eschar overlying necrotic tissue. (D) Right medial thigh after sodium thiosulfate course showing epithelized scar without debridement. (E) Left medial thigh before sodium thiosulfate showing black eschar overlying necrotic tissue. (F) Left medial thigh after sodium thiosulfate course showing epithelized scar without debridement.

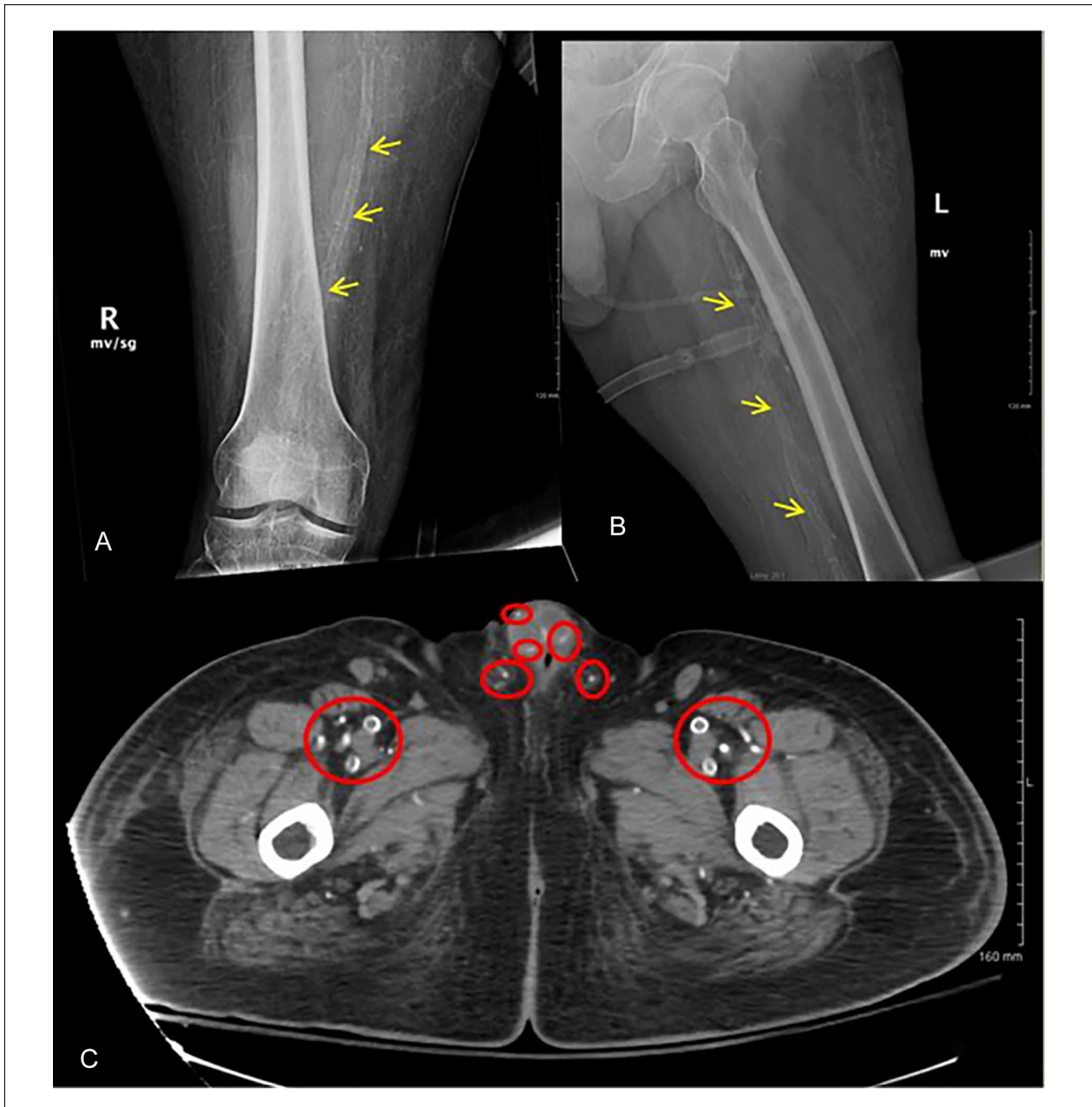


Image 4. (A) Right distal femur plain radiograph showing medial calcification of right femoral artery (arrows). Subtle subcutaneous calcifications can be appreciated. (B) Left proximal femur plain radiograph showing medial calcification of left femoral artery (arrows). Subtle subcutaneous calcifications can be appreciated. (C) Axial view of pelvic computed tomographic scan without intravenous contrast showing medial artery calcification of femoral arteries as well as penile arteries.

paraphimosis and phimosis seen early on in our patient's disease process as well as the progression to glans penis necrosis.⁷ Computed tomography captured the calcified penile artery media (Image 4C). Cinacalcet, sevelamer, and sodium thiosulfate did not stop the progression of the ischemia into

necrosis. Although parathyroidectomy and revascularization were entertained, necrosis progressed quickly requiring repeated debridement, resulting in partial penectomy with continued necrosis of penile stump due to poor wound healing. Histopathology showed gangrene and diffuse necrosis

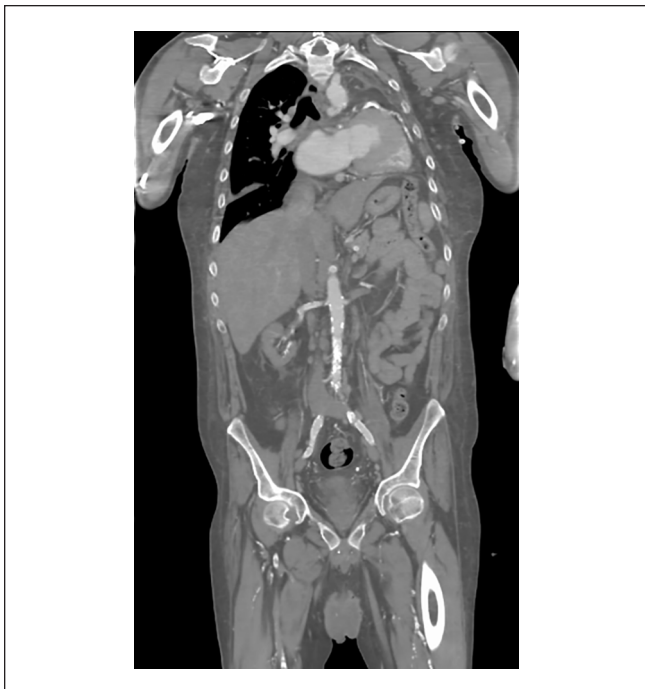

Image 5. Coronal chest, abdomen, and pelvis computed tomographic scan with intravenous iodinated contrast demonstrating diffuse arterial calcification of descending thoracic aorta, iliac arteries, and distal femoral arteries bilaterally. Note the calcification of pericardial sac and the position of the post-pneumonectomy cardiomegaly.

with acute inflammation without prototypical calcified arteries. His poor wound healing over the penile stump resulted in a persistent meatal stricture necessitating a chronic Foley catheter. This was later complicated by *E coli* and *P aeruginosa* epididymitis from chronic Foley placement (Image 3B) ultimately requiring placement of a suprapubic catheter.

Patient's skin lesions initially presented as painful livedo reticularis. Livedo reticularis eventually coalesced into skin lesions typical of calciphylaxis (Image 3C and E). Radiographic imaging of lower extremity lesions found more prominent arterial media calcification in his femoral arteries (Images 4A-C and 5). Penile pain and lesion which developed prior to lower extremity lesions were suspected as calciphylaxis but no debridement was recommended initially due to concern for poor healing postoperatively. As lower-extremity lesions did not worsen until later, skin biopsy was not considered until after sodium thiosulfate was initiated. Initiation of sodium thiosulfate was based on clinical, laboratory, and radiographic data. Given the concern of poor healing after debridement, additional skin biopsy was also questioned. Diagnosis was confirmed when penis lesions and skin lesions began to heal after sodium thiosulfate treatment.

Sodium thiosulfate had reported off-label success in uremic and nonuremic calciphylaxis cases at the time of

diagnosis. First reported use in calciphylaxis was in 2004 where Ciccone reported dramatic improvement in clinical signs and symptoms of calciphylaxis after initiation of thrice-weekly therapy.² Many case reports also discovered similar success and clinical trials are ongoing.¹ Our patient had similar success after initiation of sodium thiosulfate (Image 3B, D, and F).

Unfortunately, the patient was not adherent with dialysis or medical therapies. Frequent rehospitalizations required restabilization with hemodialysis and sodium thiosulfate. Severe peripheral vascular disease secondary to arterial calciphylaxis in addition to uncontrolled diabetes and impaired wound healing led to eventual loss of his right foot with a below-the-knee amputation.

Living in an endemic area for coccidioidomycosis, the patient did continue to survive to develop severe hypoxic primary pulmonary coccidioidomycosis in his remaining right lung. He was started on therapy with IV liposomal amphotericin B and prednisone taper as per Valley Fever Institute protocol.⁸ He was successfully transitioned to fluconazole oral therapy after 12 weeks of IV liposomal amphotericin B therapy.

Conclusion

In conclusion, this case report describes a severe case of penile calciphylaxis associated with ESRD and diabetes mellitus type 2 with poor outcome. Sodium thiosulfate has been reported as the treatment of choice in previous case reports. The patient responded well to penectomy in combination with sodium thiosulfate, cinacalcet, and sevelamer therapy initially but eventually demised from atherosclerotic complications of his extensive comorbidities.

Acknowledgments

This case report was presented as an oral presentation at the American Federation for Medical Research Western Medical Research Conference in Carmel, California, on January 2018.

Declaration of Conflicting Interests

The author(s) declared no potential conflicts of interest with respect to the research, authorship, and/or publication of this article.

Funding

The author(s) received no financial support for the research, authorship, and/or publication of this article.

Ethics Approval

Ethical approval to report this case was obtained from Kern Medical Institutional Review Board #17046.

Informed Consent

Informed consent for patient information to be published in this article was not obtained because patient was deceased and multiple

attempts were made to contact legal representatives. Waiver of consent was requested and was approved.

ORCID iDs

Carlos D'Assumpcao  <https://orcid.org/0000-0001-9967-9612>

Rupam Sharma  <https://orcid.org/0000-0003-3457-4371>

Arash Heidari  <https://orcid.org/0000-0003-1091-348X>

References

1. Nigwekar SU, Kroshinsky D, Nazarian RM, et al. Calciphylaxis: risk factors, diagnosis, and treatment. *Am J Kidney Dis.* 2015;66(1):133-146. doi:10.1053/j.ajkd.2015.01.034.
2. Cicone JS, Petronis JB, Embert CD, et al. Successful treatment of calciphylaxis with intravenous sodium thiosulfate. *Am J Kidney Dis.* 2004;43(6):1104-1108. doi:10.1053/j.ajkd.2004.03.018.
3. Virchow R. Virchows Archiv für Pathologische Anatomie und Physiologie. *Eur J Pathol.* 1855;479:8103. <https://www.springer.com/journal/428>.
4. Bryant JH, White WH. No A case of calcification of the arteries and obliterative endarteritis, associated with hydronephrosis, in a child aged six months. *R Coll Surg Engl.* 1899;55:18-28.
5. Selye H. *Calciphylaxis*. Chicago, IL: The University of Chicago Press, 1962.
6. Rees JKH, Coles GA. Calciphylaxis in man. *BMJ.* 1969;2(5658):670-672. doi:10.1136/bmj.2.5658.670.
7. Campbell RA, Alzweri LM, Sopko NA, Macura KJ, Burnett AL. Penile calciphylaxis: the use of radiological investigations in the management of a rare and challenging condition. *Urol Case Rep.* 2017;13:113-116. doi:10.1016/j.eucr.2017.03.008.
8. Johnson RH, Sharma R, Kuran R, et al. Coccidioidomycosis: a review. *J Investig Med.* 2021;69(2):316-323. doi:10.1136/jim-2020-001655.