

UC Davis

UC Davis Previously Published Works

Title

Radiation dermatitis in the hairless mouse model mimics human radiation dermatitis.

Permalink

<https://escholarship.org/uc/item/2d6131kn>

Journal

Scientific Reports, 14(1)

Authors

Lawrence, Jessica

Seelig, Davis

Demos-Davies, Kimberly

et al.

Publication Date

2024-10-22

DOI

10.1038/s41598-024-76021-9

Peer reviewed



OPEN Radiation dermatitis in the hairless mouse model mimics human radiation dermatitis

Jessica Lawrence^{1,2,3,4}✉, Davis Seelig^{1,2}, Kimberly Demos-Davies¹, Clara Ferreira³, Yanan Ren^{5,6}, Li Wang⁵, Sk. Kayum Alam⁵, Rendong Yang^{5,6}, Alonso Guedes¹, Angela Craig^{1,2,7} & Luke H. Hoepfner^{2,5}✉

Over half of all people diagnosed with cancer receive radiation therapy. Moderate to severe radiation dermatitis occurs in most human radiation patients, causing pain, aesthetic distress, and a negative impact on tumor control. No effective prevention or treatment for radiation dermatitis exists. The lack of well-characterized, clinically relevant animal models of human radiation dermatitis contributes to the absence of strategies to mitigate radiation dermatitis. Here, we establish and characterize a hairless SKH-1 mouse model of human radiation dermatitis by correlating temporal stages of clinical and pathological skin injury. We demonstrate that a single ionizing radiation treatment of 30 Gy using 6 MeV electrons induces severe clinical grade 3 peak toxicity at 12 days, defined by marked erythema, desquamation and partial ulceration, with resolution occurring by 25 days. Histopathology reveals that radiation-induced skin injury features temporally unique inflammatory changes. Upregulation of epidermal and dermal TGF- β 1 and COX-2 protein expression occurs at peak dermatitis, with sustained epidermal TGF- β 1 expression beyond resolution. Specific histopathological variables that remain substantially high at peak toxicity and early clinical resolution, including epidermal thickening, hyperkeratosis and dermal fibroplasia/fibrosis, serve as specific measurable parameters for in vivo interventional preclinical studies that seek to mitigate radiation-induced skin injury.

Keywords Translational, Dermatitis, Radiation, Skin, Inflammation, TGF- β 1

Radiation therapy is integral for control of many tumors and is prescribed for more than 50% of cancer patients in the United States^{1–3}. Approximately 95% of cancer patients receiving radiation therapy will develop moderate to severe radiation-induced dermatitis or “radiation burn”, with effects ranging from dry desquamation and erythema to moist desquamation and full thickness ulceration^{4–9}. Not only does it cause pain, anxiety, and disruption of quality of life during and following treatment, its severity correlates to the likelihood of the development of chronic effects like fibrosis, telangiectasia, ulceration, and necrosis^{6,9}. In some patients, radiation dermatitis is sufficiently severe to limit the therapeutic dose administered for tumor control or will lead to a break in treatment, which compromises local control and survival^{8–12}. Each day that radiation is delayed decreases tumor control and increases mortality, thus it is prudent for patients to remain on schedule without interruptions^{13–15}. With the combination of radiation therapy and targeted drugs like cetuximab that cause a skin rash, moderate to severe radiation dermatitis occurs at a higher incidence and for a longer duration compared to radiation therapy alone^{16–19}. Even with routine adoption of advanced radiotherapy techniques like intensity modulated radiation therapy (IMRT), radiation dermatitis remains common and causes treatment delays in up to 50% of patients^{20,21}.

There is no effective prevention or treatment for radiation dermatitis^{7,11,22–31}. The most widely adopted recommendation is for patients with dermatitis to keep the site clean using dilute soap and water and allow wound healing to occur^{9,16,32}. The molecular pathogenesis of radiation dermatitis is incompletely understood,

¹Department of Veterinary Clinical Sciences, College of Veterinary Medicine, University of Minnesota, 1365 Gortner Ave, St Paul, MN 55108, USA. ²Masonic Cancer Center, University of Minnesota, 425 East River Parkway, Minneapolis, MN 55455, USA. ³Department of Radiation Oncology, Medical School, University of Minnesota, 516 Delaware St SE, Minneapolis, MN 55455, USA. ⁴Department of Surgical and Radiological Sciences, School of Veterinary Medicine, University of California, Davis, Davis, CA 95616, USA. ⁵The Hormel Institute, University of Minnesota, 801 16th Ave NE, Austin, MN 55912, USA. ⁶Department of Urology, Northwestern University, 303 E Superior Street, Chicago, IL 60611, USA. ⁷Hennepin Healthcare Research Institute, 701 Park Ave, Suite S3, Minneapolis, MN 55415, USA. ✉email: jlawrence@ucdavis.edu; hoepfner005@umn.edu

and irradiated skin is rarely sampled repeatedly to evaluate signaling pathways. A major factor contributing to our limited molecular understanding is the lack of an optimized animal model of radiation dermatitis that provides comprehensive information regarding the spectrum of inflammation and pain that occurs. Animal models are essential for the advancement of novel agents targeted for use in the human cancer patient, thus it is prudent to have a well-defined model that translates favorably to the clinic. Previous rodent radiation dermatitis studies have suffered significant shortcomings, including variations in mouse strain, anatomical site and field size irradiated, radiation dosing details, radiation equipment, monitoring, and output measures^{33–37}. These factors contribute to an inability to effectively repeat, improve upon, or compare experimental approaches. Outbred SKH-1 mice are the most commonly used mouse strain for dermatologic studies³⁸ and have been widely used to study cutaneous effects of UVB irradiation^{39–45}. This strain represents an emerging model to evaluate dermatitis following ionizing radiation used for therapeutic purposes in oncology^{33,46,47}. Hairless mice are ideal because their wound healing has been well characterized, and their skin mimics human sebaceous skin most affected by radiation dermatitis^{38,48}. The objective of this study was therefore to characterize development of radiation-induced skin injury in an SKH-1 mouse model, highlighting distinct temporal stages of clinical and/or pathologic injury. The findings reported here provide a platform on which to objectively evaluate cellular signals contributing to these distinct stages, such that effective mitigators can be developed to reduce the severity, duration, and/or discomfort associated with radiation dermatitis.

Results

Radiation-induced clinical dermatitis occurs following 30 Gy irradiation

An initial pilot dose escalation study was performed to optimize the 30 Gy radiation dose used to induce dermatitis. SKH-1 mice were initially treated and evaluated for the development of acute dermatitis following a single dose of 15 Gy, 20 Gy, 25 Gy and 30 Gy (Supplementary Fig. 1). A single treatment of 30 Gy using 6 MeV electrons was sufficient to induce severe (grade 3) toxicity 12 days (d) with resolution by 28d. A single fraction of 30 Gy radiation delivered with 6 MeV electrons induced severe clinical radiation skin injury (Fig. 1), defined by marked erythema, desquamation and partial ulceration. Radiation dermatitis grade significantly ($p < 0.0001$) increased until peak toxicity with partial resolution by the end of the study period. Mean grade at peak toxicity on day 12 (2.56 ± 0.18) was significantly higher ($p < 0.0001$) than all other timepoints evaluated (Table 1). Mean grade at resolution at day 22 (0.56 ± 0.24) was not significantly different than mean grade at baseline, 2 h, and 5 days.

Temporally unique histopathologic skin inflammatory changes, including epidermal thickening, hyperkeratosis, and dermal fibroplasia/fibrosis contribute to radiation-induced injury

There were distinct histopathological changes over time with increasing total inflammatory score by day 12 that partially resolved by day 22 (Fig. 2). Histopathologic scores at 12 days and 22 days after irradiation were significantly higher than scores within unirradiated skin and within irradiated skin at 2 h and 5 days (Table 2).

Significant changes in almost all histopathologic measures of inflammation were observed 12 days following irradiation, compared to control and subacute (2 h) samples (Fig. 3). Scores for epidermal ulceration, epidermal thickening, hyperkeratosis, glandular loss, dermal fibroplasia/fibrosis, dermal mononuclear, mastocytic, and neutrophilic inflammation, and hypodermal inflammation were significantly increased. Scores for hyperkeratosis (Fig. 3C), glandular loss (Fig. 3D), and dermal fibroplasia/fibrosis (Fig. 3E) remained significantly increased compared to unirradiated control 22d after irradiation. While specific inflammatory changes at 5d were not significantly different than control skin samples, increased glandular loss along with dermal mononuclear and neutrophilic inflammation were observed at 5d relative to unirradiated controls. Except for dermal pyogranulomatous inflammation, inflammatory scores significantly correlated to clinical grade (Table 3). Total inflammatory score, epidermal thickening, hyperkeratosis, and dermal fibroplasia/fibrosis strongly ($r > 0.80$) and positively correlated to clinical grade.

Increased epidermal and dermal TGF- β 1 and COX-2 protein expression occur at peak dermatitis, with sustained epidermal TGF- β 1 expression beyond clinical resolution of peak toxicity

TGF- β 1 plays roles in mediation and regulation of acute skin injury, cutaneous wound healing, and chronic fibrosis^{49,50}. Therefore, we evaluated epidermal and dermal TGF- β 1 expression in unirradiated ($N=8$) and irradiated ($N=4–6$ per time point) skin samples. Mean epidermal and dermal TGF- β 1 immunoreactivity scores significantly increased at day 12 compared to unirradiated samples (Fig. 4A–C). Increased epidermal TGF- β 1 protein expression was sustained until at least 22 days following irradiation (Fig. 4A). Mean dermal TGF- β 1 protein expression (3.75) at day 12 was similar to mean expression at day 22 (3.50). However, day 22 was not significantly different than mean control TGF- β 1 protein expression ($p=0.0506$). To support these findings, TGF- β 1 gene expression increased after irradiation, with a peak in expression at day 12 (Supplementary Fig. 2A). Using linear regression, mean TGF- β 1 immunoreactivity scores calculated from epidermal and dermal samples were significantly ($R^2=0.9$; $p=0.007$) related to TGF- β 1 gene expression.

Because COX-2 plays a central role in a broad range of inflammatory processes in the skin, including hyperalgesia and edema⁵¹, we evaluated COX-2 expression with the dermis and epidermis in irradiated ($N=4–6$ per time point) and control samples ($N=6$) (Fig. 5A–C). Epidermal and dermal COX-2 immunoreactivity scores were significantly higher at day 12 compared to unirradiated samples (Fig. 5A–B). In support of these findings, PTGS2 gene expression increased after irradiation, with a peak in expression at day 12 (Supplementary Fig. 2B). Mean COX-2 immunoreactivity scores calculated from epidermal and dermal samples were moderately

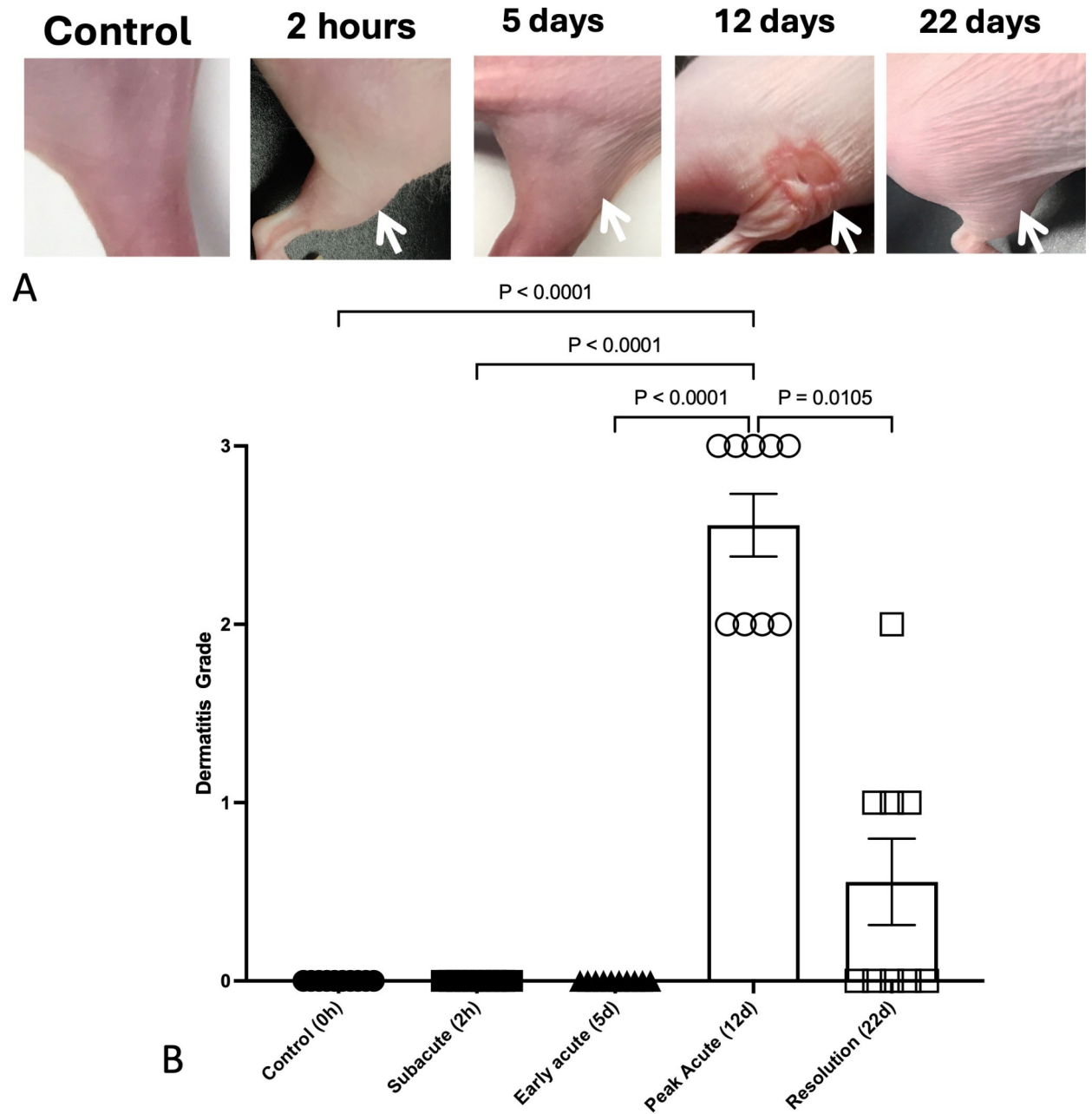


Fig. 1. Temporal development of radiation-induced dermatitis in SKH-1 mice. Radiation dermatitis significantly ($p < 0.0001$) increases in severity following 30 Gy single fraction irradiation to the right hindlimb skin in 11–12 week old SKH-1 mice ($N = 9–10$ /group). Representative photos of the right hindlimb (A) are shown following 30 Gy radiation delivered with 6 MeV electrons in comparison to unirradiated skin. Mean grade significantly increased at peak toxicity on day 12 (B) with partial resolution by day 22. Data are presented as the mean \pm SEM at each defined timepoint following irradiation. Significant ($p < 0.05$) differences are shown following Kruskal-Wallis with Dunn's multiple comparison analysis.

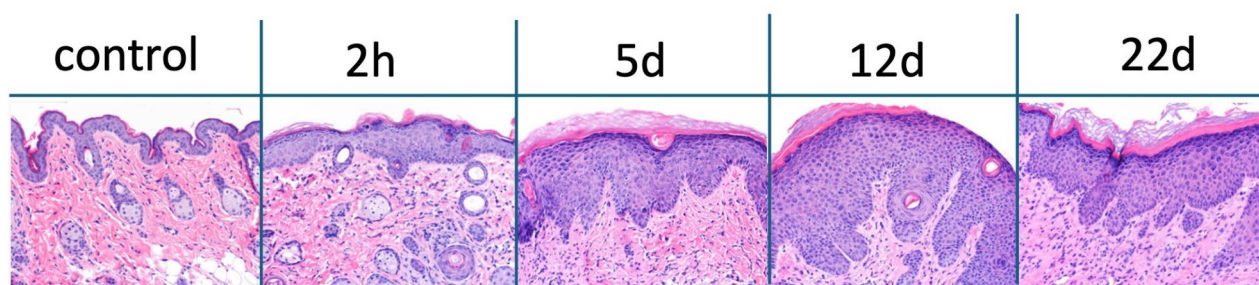
associated with PTGS2 gene expression fold changes, but this did not reach statistical significance ($R^2 = 0.59$; $p = 0.124$).

Discussion

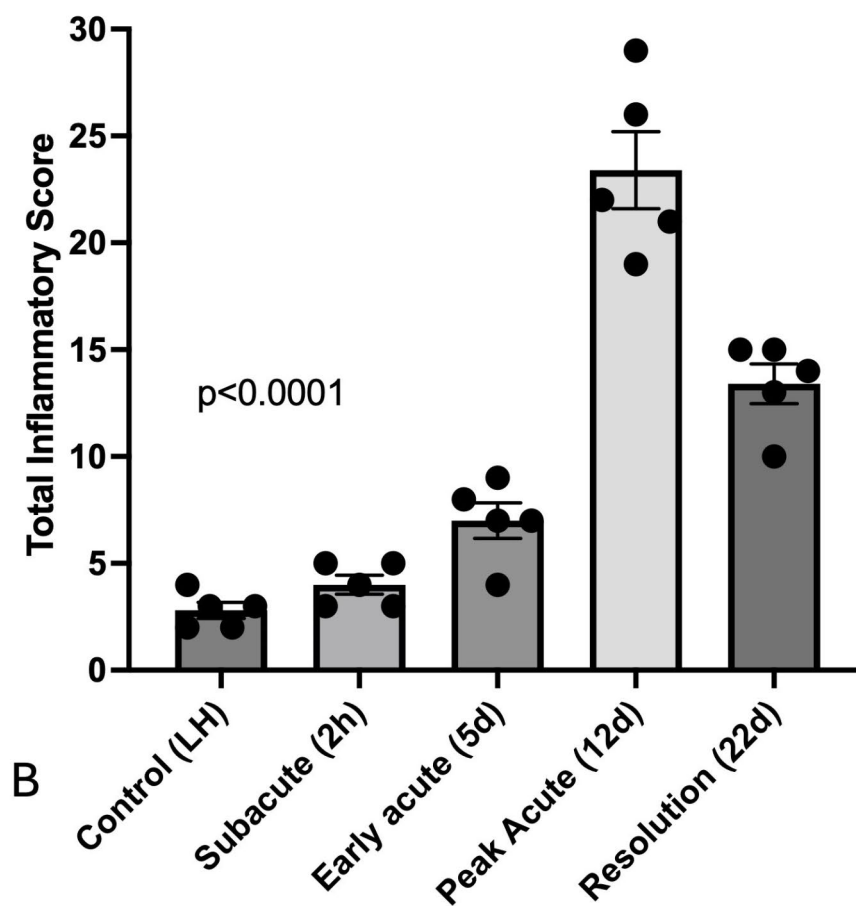
The hairless SKH-1 mouse strain is commonly used in translational dermatologic studies, and it is an ideal model for use in interventional studies where observations of inflammatory skin changes may be obscured by hair and pigment^{33,38,46,48}. The findings presented here describe a method of inducing robust radiation-induced dermatitis in the SKH-1 mouse, and the results highlight distinct temporal epidermal and dermal histopathologic changes that correlate to clinical radiation dermatitis grade. Clinical grading schemes, such

Time	Mean grade \pm SEM
0 h	0.00 \pm 0
2 h	0.00 \pm 0
5d	0.00 \pm 0
12d	2.56 \pm 0.18
22d	0.56 \pm 0.24

Table 1. Radiation dermatitis grade over time in 11–12 week old SKH-1 mice ($N=9-10$ per time point) following 30 Gy radiation to the skin of the right proximal hindlimb.



A



B

Fig. 2. Radiation-induced dermatitis is characterized by measurable inflammatory changes over time. (A) Representative H&E images of radiation-induced skin pathology over time following irradiation 30 Gy single fraction irradiation prescribed to the skin of the right hindlimb/hip. (B) Total inflammatory score is represented as individual values and mean \pm SEM for control skin from the left hindlimb (LH) and for irradiated skin from the right hindlimb ($N=5$ per time point) at designated time points following irradiation. The p value was calculated following one-way ANOVA.

	2 h	5d	12d	22d
0 h	ns	ns	<0.0001	<0.0001
2 h		ns	<0.0001	<0.0001
5d			<0.0001	0.0020
12d				<0.0001

Table 2. Significant differences in total inflammatory score in skin of SKH-1 mice at designated time points ($N=5$ per group) following 30 Gy radiation. *ns* represents “not significant” with p value >0.05 .

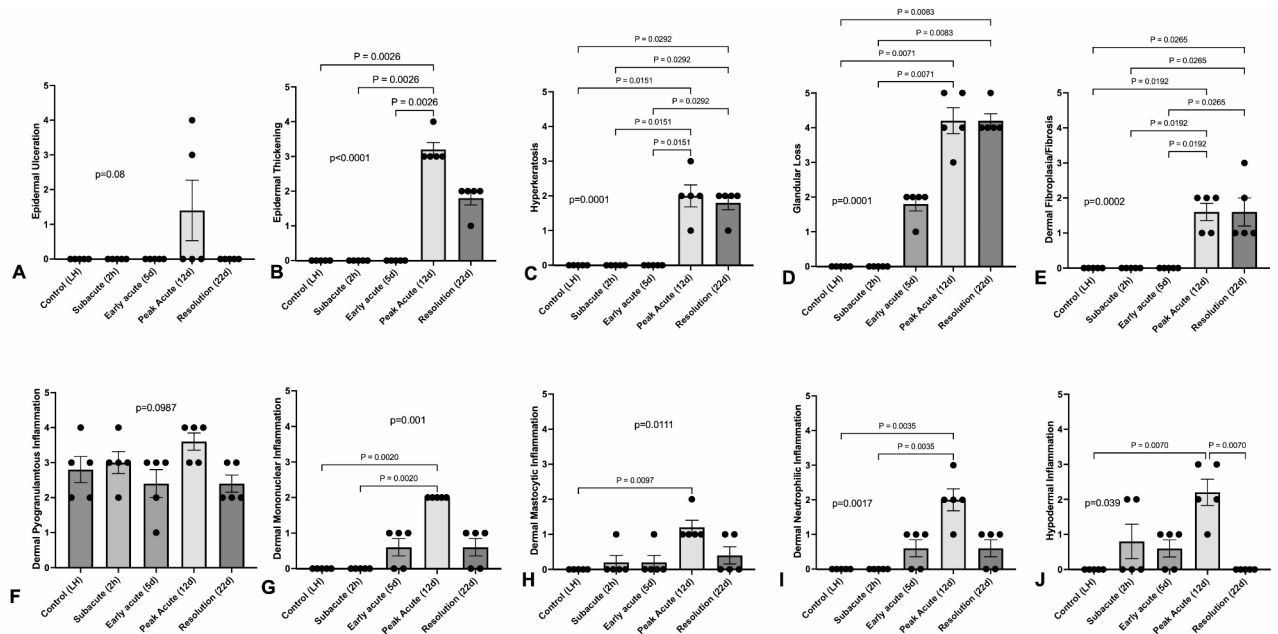


Fig. 3. Radiation induced significant changes in most histopathologic measures of inflammation at the time of peak clinical toxicity on day 12. Mean scores for measured histopathologic variables, including epidermal ulceration (A), epidermal thickening (B), hyperkeratosis (C), glandular loss (D), dermal fibroplasia/fibrosis (E), dermal pyogranulomatous inflammation (F), dermal mononuclear inflammation (G), dermal mastocytic inflammation (H), dermal neutrophilic inflammation (I) and hypodermal inflammation (J), and shown from the unirradiated control left hindlimb (LH) skin and from irradiated skin over time. Data are presented as individual values and mean \pm SEM, with p values in lowercase on the graph representing Kruskal-Wallis analysis. Comparative p values in uppercase between bars were calculated by performing Dunn’s multiple variable post-test analysis ($N=5$ per timepoint). Significant values between timepoints are highlighted with the bar; p values represent Kruskal-Wallis results while P values represent Dunn’s post-hoc results.

as our modified CTCAE v5.0, provide a standardized approach to treatment-related adverse events and are important endpoint measures for studies that impact radiation-induced toxicity⁵². Clinical grading is derived through standard, manual observations over time. The histopathologic changes that occur after irradiated skin are variable, may occur prior to clinical changes, and may be present despite apparent resolution. Understanding the specific inflammatory tissue changes underlying increasing clinical grade may improve the use and importance placed on clinical grade. In this study, nearly all histopathologic variables assessed significantly correlated to clinical dermatitis grade, which was highest at day 12 and 22. We examined a total inflammatory score that was comprised of discrete histopathologic insults to skin, as well as the individual histopathologic changes within the total score. Increased epidermal thickening, hyperkeratosis, and dermal fibroplasia/fibrosis most strongly correlated to increased clinical grade. Of these, hyperkeratosis and dermal fibroplasia/fibrosis were also significantly higher at day 12 and day 22 compared to unirradiated skin. Glandular deficiency was an additional histopathologic measure of radiation-induced injury that remained significantly high at day 22. Although not significantly different than baseline, early histopathologic changes were observed 5 days after irradiation, including glandular loss, monocytic and neutrophilic inflammation.

The skin barrier acts as a critical protector for the body against external environmental hazards. Recent data has shown that up to 66% of cancer patients have at least one non-cancer related co-morbidity, while 50% have multiple co-morbidities⁵³, with the highest prevalence in lower socio-economic groups^{53–55}. Common co-morbidities like hypertension, diabetes and heart disease are associated with unique skin conditions that

Variable	r_s	p value
Total inflammatory score	0.7988	< 0.0001
Epidermal ulceration	0.4605	0.0205
Epidermal thickening	0.9612	< 0.0001
Hyperkeratosis	0.8356	< 0.0001
Glandular loss	0.7636	< 0.0001
Dermal fibroplasia/fibrosis	0.8477	< 0.0001
Dermal mononuclear inflammation	0.7643	< 0.0001
Dermal mastocytic inflammation	0.6382	0.0006
Dermal neutrophilic inflammation	0.7303	< 0.0001
Hypodermal inflammation	0.5015	0.0107

Table 3. Clinical dermatitis grade significantly ($p < 0.05$) and positively correlated to the total inflammatory score as well as to most individual histopathological features assessed.

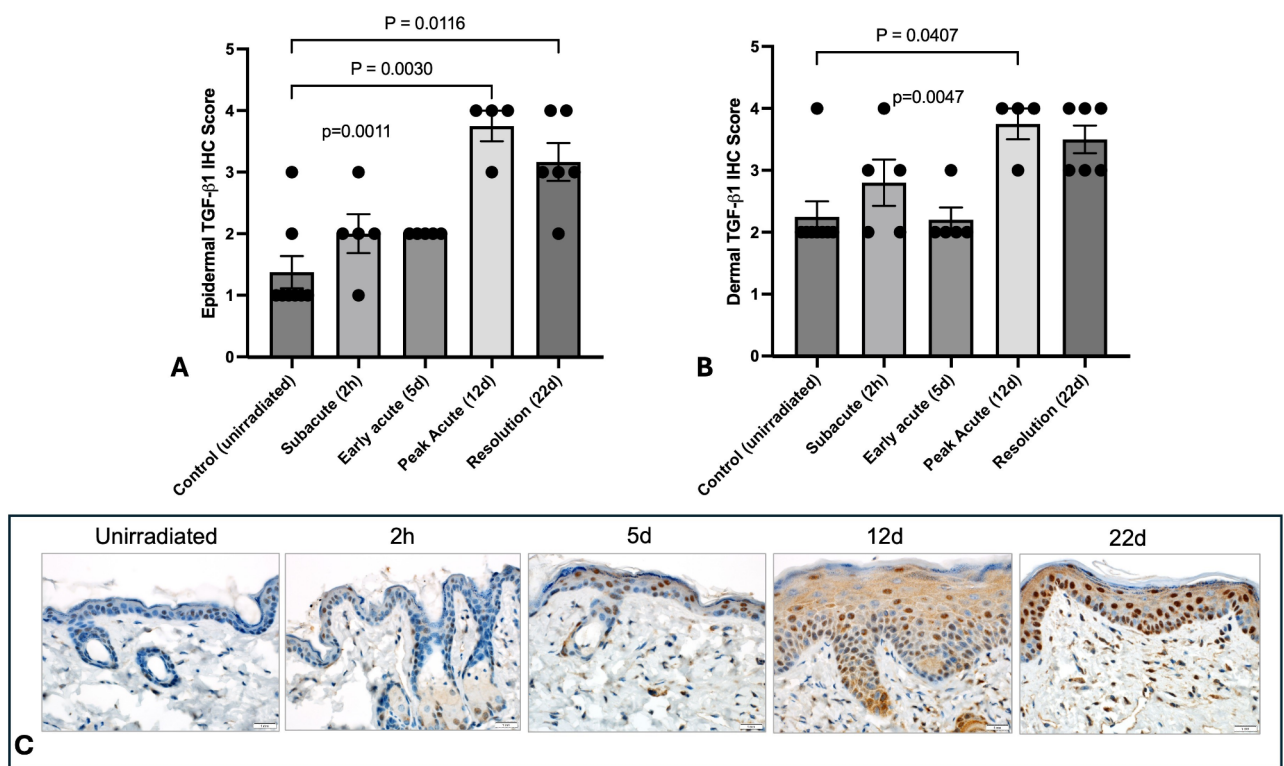


Fig. 4. TGF- β 1 immunoreactivity in irradiated skin from SKH-1 mice. Mean epidermal (A) and dermal (B) TGF- β 1 immunoreactivity scores in unirradiated control skin ($N = 8$) and irradiated skin ($N = 4-6$) at designated time points after treatment. Data are presented as individual values and mean \pm SEM, with p values in lowercase on the graph representing Kruskal-Wallis analysis. Comparative p values in uppercase between bars were calculated by performing Dunn's multiple variable post-test analysis ($N = 5$ per timepoint). Significant values between timepoints are highlighted with the bar; p values represent Kruskal-Wallis results while P values represent Dunn's post-hoc results. (C) Representative tissue samples show normal positive TGF- β 1 immunohistochemical staining, represented as brown staining within the cellular cytoplasm, within the unirradiated dermis and epidermis. Progressively increased TGF- β 1 expression is demonstrated over time, with peak staining at day 12 and 22.

affect skin integrity and healing^{56,57}. Maintenance of skin integrity and barrier function is therefore of incredible importance, because the skin is the first line of protection against microbes, toxins, sunlight and other external exposures⁵⁸. Glandular loss has been recently shown to impair the skin barrier in SKH-1 mice treated with 20–40 Gy to the hindlimb^{46,47}. Glandular loss was seen as early as 4 days following 40 Gy, and within 6 days following 20–30 Gy⁴⁶. Our findings of glandular loss prior to clinical dermatitis, although not significantly different than unirradiated skin when assessed by our 5-point histopathologic scale, align with these prior reports. Importantly,

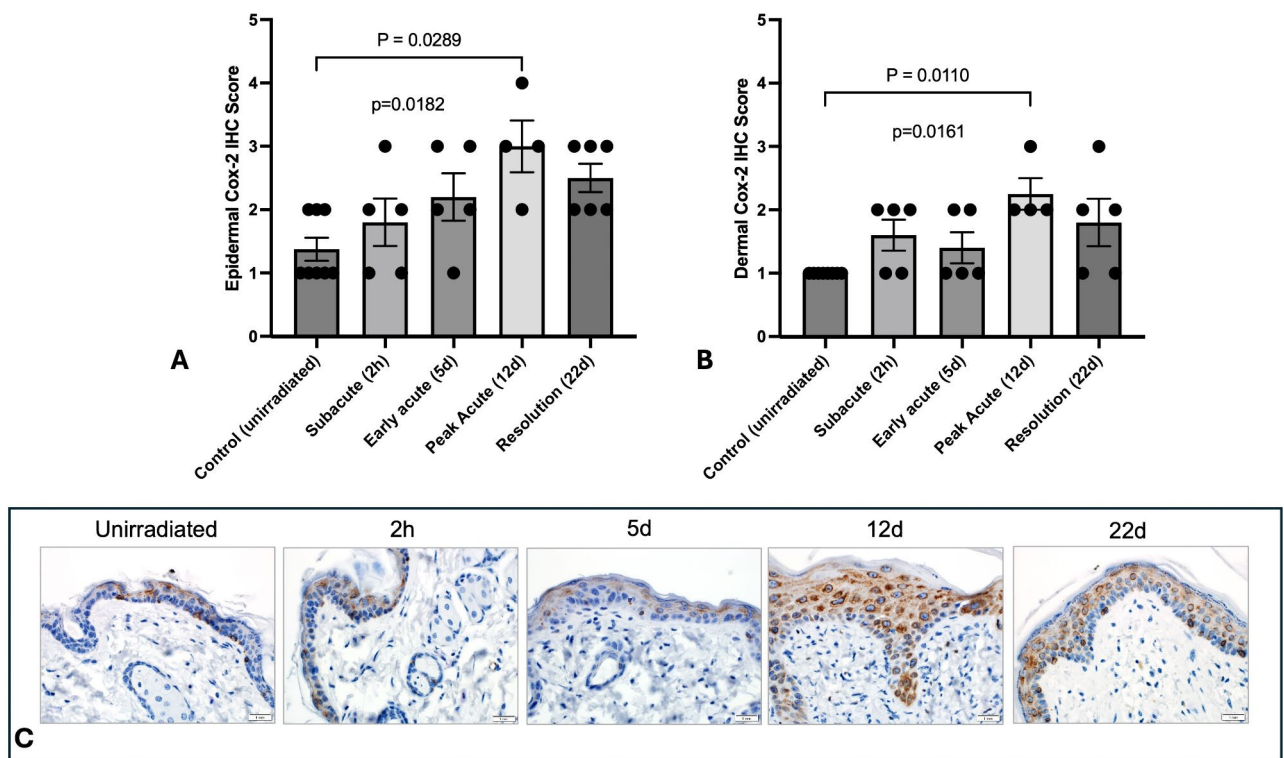


Fig. 5. COX-2 immunoreactivity in irradiated skin from SKH-1 mice. Mean epidermal (A) and dermal (B) COX-2 immunoreactivity scores in unirradiated control skin ($N=8$) and irradiated skin ($N=4-6$) at defined time points. Data are presented as individual values and mean \pm SEM, with p values in lowercase on the graph representing Kruskal-Wallis analysis. Comparative p values in uppercase between bars were calculated by performing Dunn's multiple variable post-test analysis ($N=5$ per timepoint). Significant values between timepoints are highlighted with the bar; p values represent Kruskal-Wallis results while P values represent Dunn's post-hoc results. (C) Representative tissue samples show normal positive COX-2 immunohistochemical staining, represented as brown staining within the cellular cytoplasm, within the unirradiated dermis and epidermis. Progressively increased COX-2 expression is demonstrated over time, with peak staining at day 12 and 22.

our data show that glandular loss develops early and remains significantly impacted beyond initial clinical recovery of dermatitis. Potential therapeutic interventions that preserve dermal sebaceous glands during and after irradiation may improve skin integrity and promote healing. Clinical grade moderately correlated with glandular loss, and additional measures may be beneficial for amelioration of pre-clinical changes.

Increasing epidermal thickening and hyperkeratosis were strongly correlated to increasing clinical grade in our SKH-1 model. These epidermal changes occur secondary to the inflammatory cascade that occurs following irradiation, and they are well recognized in the irradiated skin of cancer patients^{6,8}. Epidermal damage and structural keratin changes, together with the preceding inflammatory signals, disrupt the skin barrier and can foster dysbiosis and chronic inflammation that further perpetuates skin injury⁵⁹. Interestingly, a recent study identified early epidermal thickening and hyperkeratosis in human skin-equivalent tissue models following single fractions of either 2–10 Gy delivered with 6 MeV electrons, similar to our radiation delivery method⁶⁰. This study utilized optical coherence tomography with subsequent histology to confirm visual findings and may provide a non-invasive means of measuring these two features in future radiation studies seeking to mitigate radiation dermatitis.

Because TGF- β 1 is a key mediator of tissue repair following injury and subsequent tissue fibrosis after irradiation, studies have suggested considering TGF- β 1 in the evaluation of early radiation dermatitis and its healing process⁶¹⁻⁶³. In our SKH-1 radiation dermatitis model, dermal fibroplasia and fibrosis strongly correlated to clinical grade. Our data also demonstrated an early increase in TGF- β 1 expression within the epidermis and dermis, with sustained high expression in the former at the end of the study period, when the mean clinical dermatitis grade was close to baseline (mean 0.56). This sustained TGF- β 1 expression in SKH-1 mice is similar to prior reports in other murine strains to describe early, robust and long-term TGF- β 1 mRNA expression following 50 Gy irradiation^{64,65}. This also mirrors data in humans demonstrating significantly upregulated TGF- β 1 mRNA expression following preoperative radiation treatment⁶⁶. TGF- β 1 signaling regulates wound repair in irradiated skin by stimulating fibroblast, neutrophil and macrophage infiltration, which our 5 day histopathologic data support. Of note, recent studies have shown that Smad3-null mice have faster healing, reduced inflammation, and reduced early scarring within irradiated skin compared to mice with intact

Smad3^{62,67}. Smad3 is a critical downstream mediator of TGF- β 1 signaling that mediates several repair processes in skin, including inflammation, induction of epithelial-to-mesenchymal transdifferentiation, keratinocyte migration, and granulation tissue formation^{62,63,67}. Data supports use of SKH-1 mice as an appealing model for preclinical investigation of inhibitors of TGF- β 1-Smad3 signaling to reduce dermatitis severity and duration. Inhibiting this pathway may have dual benefit, as TGF- β 1-Smad3 signaling is implicated in the induction and maintenance of therapeutic resistance for some breast cancers⁶⁸.

The role of COX-2 within the skin and its inflammatory responses is varied. COX-2 has received attention as a therapeutic target by which to mitigate dermatitis in the past because it is pro-inflammatory, pro-angiogenic and associated with pain⁶⁹. Several studies investigating SKH-1 mice have highlighted that COX-2 mediates UVB-irradiation induced inflammatory responses in the skin^{39–42,70}. One study reported reduced skin damage following irradiation in female C3H/He mice following treatment with a highly selective COX-2 inhibitor⁷¹. A randomized controlled trial failed to demonstrate reduced radiation dermatitis with the use of highly COX-2 selective drugs⁷². Increased epidermal and dermal COX-2 expression was noted at the time of severe dermatitis (day 12) compared to unirradiated skin samples. It is important to note that mice evaluated in our studies received 1–4 doses of carprofen, a COX-2 inhibitor, beginning on day 11 or 12 once daily to reduce lameness and pain associated with limb dermatitis. This was an ethical decision that aligned with our institutional policies to maintain animal welfare. It is possible that epidermal and dermal COX-2 protein expression from the day 12 and day 22 skin samples were dampened by systemic administration of carprofen, and expression may have been higher in its absence. Because COX-2 mediates a host of pro-inflammatory and pro-nociceptive signals, evaluation of COX-2 within SKH-1 skin in future studies may be beneficial. More work is needed to confirm that the temporal changes in TGF- β 1 and COX-2 protein expression in epidermis and dermis of mice correlates to that of humans. Temporal protein changes in irradiated human skin are lacking (Table 4), in part because nondiagnostic research biopsies are not routinely performed⁷³.

Radiation therapy is prescribed for more than 50% of the 1.8 million cancer patients in the US^{1,2,74,75}. Clinical signs of radiation dermatitis range from dry desquamation and erythema to moist desquamation and full thickness ulceration^{4–9}. Its severity correlates with chronic effects like fibrosis, telangiectasia, hyperpigmentation, and necrosis^{6,9}. Acute dermatitis causes pain and anxiety, while disrupting quality of life⁷⁶. In people of color, the severity of acute dermatitis⁷⁷ and the impact of chronic skin changes like hyperpigmentation are particularly detrimental to quality of life⁷⁸. Severe radiation dermatitis leads to cancer treatment interruptions in some patients, which significantly reduces tumor control and survival^{18–15}. Despite technological advances, such as intensity modulated radiation therapy, dermatitis causes treatment delays in up to 50% of patients^{20,21}. Management of radiation dermatitis is costly and often requires specialty symptom management due to skin effects^{79,80}. Data suggests that nursing encounters, cost of wound care consumables, and direct nursing costs could all be significantly reduced with implementation of strategies to reduce acute radiation skin toxicities⁸¹. There is no effective prevention or treatment for radiation dermatitis^{7,22–31}. Despite prior studies, the most widely adopted recommendation is to keep irradiated skin clean and allow wound healing to occur^{9,16,32,82,83}.

Our data describing radiation-induced skin injury in the SKH-1 model is also useful beyond the context of therapeutic exposures. Cutaneous injuries can develop in normal human skin following a wide variety of radiation exposures, including nuclear device fallout, nuclear energy accidents, nuclear testing, medical exposures, and industrial overexposures^{84–87}. Indeed, skin damage is the most common radiation injury in humans⁸⁸. Important lessons from victims of nuclear disasters (i.e., atomic bombings of Hiroshima and Nagasaki, the Chernobyl nuclear accident) highlight the array of clinical manifestations of skin injury, the lack of effective treatment or pain management for resulting dermatitis, and the negative impact of injured skin on the likelihood of fatal systemic complications^{89,90}. Additionally, medical exposures can result from diagnostic procedures or therapeutic exposures for treatment^{80,86,91,92}. Over one million cases of diagnostic fluoroscopy-guided interventions occur annually in the US, and the frequency of complex interventional procedures that require longer radiation exposures have increased⁹³.

Additional studies are needed to build upon work here to further validate the SKH-1 mouse as a good model for human radiation dermatitis. Our study utilized female mice, for several scientific and practical considerations. Female mice display less variability in skin thickness and immune response compared to male mice, increasing the likelihood for consistent experimental responses in each group^{38,94}. Indeed, the use of female SKH-1 mice aligns well with a substantial body of previous dermatitis research, thus allowing comparability of results^{38,41,43}. Future, larger studies should verify if differences exist in male SKH-1 skin.

There is a clear clinical need to effectively mitigate radiation dermatitis, with implications for human health beyond medical and therapeutic radiation exposures. Our studies support the inclusion of the SKH-1 mouse as a preclinical model for radiation-induced dermatitis, as histopathologic features like glandular loss and

Species	TGF- β 1		COX-2	
	Possible Induction	Increase (Possible Peak)	Possible Induction	Increase (Possible Peak)
SKH-1 mouse	2 h	12 days	5 days	12 days
Human*	6 h	>90 days	<30 days	unknown

Table 4. Comparison between TGF- β 1 and COX-2 immunohistochemical or gene expression in irradiated SKH-1 murine skin and reported changes in irradiated human tissue^{66,72,100,101}. *specific induction and peak TGF- β 1 and COX-2 protein or mRNA expression in irradiated human skin is not known.

TGF- β 1 protein expression may serve as endpoint measures following intervention. Clinical dermatitis grading in SKH-1 mice correlates well to histopathologic variables associated with epidermal and dermal injury. Specific histopathologic measures that remained significantly high at peak toxicity and at early resolution, namely epidermal thickening, hyperkeratosis and dermal fibroplasia/fibrosis, may be used as distinct target variables to evaluate in future studies using SKH-1 mice to mitigate radiation-induced skin injury.

Methods

Mice

11–12 week old female SKH-1 mice were purchased (Charles River Laboratories) and used for all experiments. All experiments were approved by and performed in accordance with the University of Minnesota Institutional Animal Care and Use Committee (IACUC Protocol #1808–36331 A); study reporting was in accordance to ARRIVE guidelines⁹³. Mice were housed in a group of 4 or 5 animals and were randomly assigned to housing upon arrival at the University of Minnesota by Research Animal Resources staff. Mice were euthanized by carbon dioxide preceded by exsanguination following the University of Minnesota IACUC Criteria for Carbon Dioxide Euthanasia Guidelines.

Radiation

Mice were immobilized with ketamine (100 mg/kg) and xylazine (2 mg/kg) administered intraperitoneally 2–5 min prior to irradiation. All anesthetic events were overseen or carried out by a veterinarian with laboratory animal expertise. An initial pilot dose escalation study was performed to determine the target radiation dose to induce significant grade 3 dermatitis. Upon heavy sedation, mice were treated with a single dose of 15 Gy, 20 Gy, 25–30 Gy. Following determination of 30 Gy as the target dose for all experiments, mice were treated with 30 Gy radiation to the skin surface using 6 MeV electrons with a custom 2×2 cm cutout (Varian iX, Varian Medical Systems, Inc, Palo Alto CA). Skin over the right proximal hindlimb was targeted in all mice. Skin over the left hindlimb served as a control. Tissue equivalent bolus (1 cm) was placed on the surface of the skin to provide sufficient dose build-up to the level of the skin with source-to-surface distance of 100 cm. Dose delivered to irradiated (right hindlimb) and unirradiated skin (left hindlimb) was verified via radiochromic film dosimetry (GAFchromic™) to ensure the dose was delivered as prescribed⁹⁵. Following irradiation, dermatitis was graded daily using a modified Common Toxicity Criteria for Adverse Events (CTCAE v5.0) (Supplementary Table 1)⁵². Because dermatitis was associated with pain and lameness, and pain was not an endpoint tested, we adhered to our institutional policy to maintain animal welfare and mice were treated with subcutaneous (Zoetis, Kalamazoo, MI) at a dosage of 5 mg/kg every 24 h for 1–4 days beginning on day 11–12.

Histopathology

To characterize pathologic changes over time, skin and subcutaneous histopathology were evaluated in unirradiated (control) skin from the left hindlimb and at 2 h (h), 5 days (d), 12d, and 22d post irradiation. These time points were considered representative of acute injury (2 h) early induction (5d), peak toxicity (12d), and initial resolution (22d) of radiation dermatitis. Skin from unirradiated and irradiated sites from each mouse was collected immediately following euthanasia. Skin was fixed in 10% neutral buffered formalin for 24 h and subsequently embedded in paraffin wax. Four-micron tissue sections were deparaffinized in xylene and subsequently rehydrated in graded alcohol. Slides were stained with Harris Modified Hematoxylin with acetic acid (EXPREDIA, Kalamazoo, MI, Cat# 7221). The slides were dipped first into acid water (0.15% HCL, Acros Organics, Fair Lawn, Cat# NJAC124210010), followed by running tap water, and finally in ammonium water (2.8% of ammonium hydroxide 28–30%, Newcomer Supply, Middleton, WI, Cat# 1006 A). The slides were counterstained with Eosin (Leica Biosystems, Deer Park, IL, Cat# 3801600). The slides were dehydrated in graded alcohol and xylene before coverslip-mounted using permount mounting media (Leica Biosystems, Deer Park, IL, Cat# 3801731). Hematoxylin and eosin (H&E)-stained sections were evaluated by a board-certified veterinary pathologist [American College of Veterinary Pathologists (ACVP)] on a 5-point scale for epidermal ulceration, epidermal thickening, hyperkeratosis, glandular loss, dermal fibrosis / fibroplasia, dermal inflammation (including pyogranulomatous inflammation, monocytic inflammation, mastocytic inflammation, and neutrophilic inflammation) and hypodermal inflammation according to a modified version of a previous publication⁹⁶. For each parameter, severity was defined as: 1 = minimally detectible, 2 = mild, 3 = moderate, 4 = marked and 5 = severe. A total inflammatory score comprised the sum of each histopathologic parameter score, with a maximum score of 50. Treatment-associated dermal inflammation was considered against the background of strain-associated follicle-centric inflammation in the control, unirradiated skin samples. The pathologist was not blinded to the tissue collection time points.

Immunohistochemistry

To further characterize inflammatory pathways activated after radiation, sections of irradiated and unirradiated skin were immunostained for cyclooxygenase-2 (COX-2) and transforming growth factor- β 1 (TGF- β 1). For both COX-2 and TGF- β 1 IHC, 4 μ m formalin-fixed, paraffin-embedded tissue sections were deparaffinized and rehydrated, followed by antigen retrieval using either a high pH EDTA solution (COX-2) or a low pH citrate buffer (TGF- β 1). After quenching endogenous peroxidase, immunohistochemistry was performed using one of two rabbit polyclonal primary antibodies (COX-2, Biocare, CRM-306 and TGF- β 1, Invitrogen, PA1-29032) that were incubated for 30 min at room temperature. The antibodies were diluted at 1:200 and 1:100, respectively. Antibody binding was detected using the Rabbit Envision (Dako) secondary antibody kit. Diaminobenzidine was used as the chromogen and Mayer's Hematoxylin (Dako) was used as the counterstain. Primary antibodies were substituted with appropriate negative control IgG for negative control slides. Samples, which comprised a single section per antibody and animal, were evaluated by a single pathologist and given a

quantitative immunoreactivity score based on percentage of keratinocytes (epidermal samples) or nucleated cells (dermal samples) staining positive. Immunoreactivity scores were defined as: 0=no staining detected, 1=0–25% cells (keratinocytes or nucleated cells) with positive immunostaining, 2=26–50% of cells with positive immunostaining, 3=51–75% of cells with positive immunostaining, and 4=76–100% of cells with positive immunostaining.

RNA sequencing and differential gene expression

Skin samples from 4 mice per time point were collected immediately after euthanasia and stored in RNA Later. RNA was subsequently extracted using the RNeasy Plus Universal Mini kit (Qiagen, Germantown, MD, Cat# 73404) according to manufacturer's instructions. Extracted RNA was submitted to U of MN Genomics Center for quality control, library creation, and RNA sequencing entailing ~350 M raw paired-end reads/sample & 150 bp read lengths using a stranded library on Illumina's HiSeq 2500. These parameters were sufficient to detect a 2-fold change in the highest 80% of expressed transcripts at 95% confidence. Differential gene expression analysis was performed with R packages, edgeR⁹⁷ and limma⁹⁸, as previously described⁹⁹. The differentially expressed genes with an absolute value of $\log_2FC \geq 0$ and $FDR \leq 0.05$ were considered for future analysis. We have reported the differential gene expression for TGF- β 1 and PTGS2, the gene that encodes COX-2, in skin specimens obtained from irradiated mice in Supplementary Fig. 2 to support the TGF- β 1 and COX-2 protein expression findings.

Statistical analysis

Commercially available software (Prism v10; GraphPad Software, Inc., San Diego CA) was used to evaluate data. Descriptive data was reported as mean \pm standard error of the mean (SEM). Grade and histopathological variables were assessed for normality differences in grade and histopathological variables over time was determined using one-way analysis of variance (ANOVA) with Tukey's multiple comparison test or Kruskal Wallis with Dunn's multiple comparison test. Correlations between grade and histopathological variables were assessed using Spearman rank-order correlation coefficient (r_s). Correlations were categorized as strong if $r_s = 0.8$ –1.0, moderate if $r_s = 0.4$ –0.8 and weak if $r_s = 0.1$ –0.4. Mean TGF- β 1 and COX-2 immunoreactivity scores were calculated from combined epidermal and dermal TGF- β 1 or COX-2 immunoreactivity scores. Mean immunoreactivity scores were associated with TGF- β 1 and PTGS2 (murine gene for COX-2) using simple linear regression. The coefficient of determination (R^2) was considered strong if $R^2 = 0.8$ –1.0, moderate if $R^2 = 0.4$ –0.8 and weak if $R^2 = 0.1$ –0.4. Statistical significance was set at $p < 0.05$.

Data availability

All data generated or analyzed during this study are included in this published article and its Supplementary Information files.

Received: 20 May 2024; Accepted: 9 October 2024

Published online: 22 October 2024

References

- DeVita, V. T. Jr. Progress in cancer management. Keynote address. *Cancer*. **51**, 2401–2409 (1983).
- Miller, K. D. et al. Cancer treatment and survivorship statistics, 2016. *CA Cancer J. Clin.* **66**, 271–289. <https://doi.org/10.3322/caac.21349> (2016).
- Siegel, R. L., Miller, K. D. & Jemal, A. Cancer statistics, 2019. *CA Cancer J. Clin.* **69**, 7–34. <https://doi.org/10.3322/caac.21551> (2019).
- Elliott, E. A. et al. Phase III trial of an emulsion containing trolamine for the prevention of radiation dermatitis in patients with advanced squamous cell carcinoma of the head and neck: results of Radiation Therapy Oncology Group Trial 99–13. *J. Clin. Oncol.* **24**, 2092–2097. <https://doi.org/10.1200/JCO.2005.04.9148> (2006).
- Hickok, J. T., Morrow, G. R., Roscoe, J. A., Mustian, K. & Okunieff, P. Occurrence, severity, and longitudinal course of twelve common symptoms in 1129 consecutive patients during radiotherapy for cancer. *J. Pain Symptom Manag.* **30**, 433–442. <https://doi.org/10.1016/j.jpainsymman.2005.04.012> (2005).
- Hymes, S. R., Strom, E. A. & Fife, C. Radiation dermatitis: clinical presentation, pathophysiology, and treatment 2006. *J. Am. Acad. Dermatol.* **54**, 28–46. <https://doi.org/10.1016/j.jaad.2005.08.054> (2006).
- Rosenthal, A., Israilevich, R. & Moy, R. Management of acute radiation dermatitis: a review of the literature and proposal for treatment algorithm. *J. Am. Acad. Dermatol.* <https://doi.org/10.1016/j.jaad.2019.02.047> (2019).
- Ryan, J. L. Ionizing radiation: the good, the bad, and the ugly. *J. Invest. Dermatol.* **132**, 985–993. <https://doi.org/10.1038/jid.2011.411> (2012).
- Singh, M., Alavi, A., Wong, R. & Akita, S. Radiodermatitis: a review of our current understanding. *Am. J. Clin. Dermatol.* **17**, 277–292. <https://doi.org/10.1007/s40257-016-0186-4> (2016).
- Dorr, W. & Hendry, J. H. Consequential late effects in normal tissues. *Radiother Oncol.* **61**, 223–231 (2001).
- McQuestion, M. Evidence-based skin care management in radiation therapy: clinical update. *Semin Oncol. Nurs.* **27**, e1–17. <https://doi.org/10.1016/j.soncn.2011.02.009> (2011).
- Salvo, N. et al. Prophylaxis and management of acute radiation-induced skin reactions: a systematic review of the literature. *Curr. Oncol.* **17**, 94–112 (2010).
- Ho, A. S. et al. Quantitative survival impact of composite treatment delays in head and neck cancer. *Cancer*. **124**, 3154–3162. <https://doi.org/10.1002/cncr.31533> (2018).
- Withers, H. R., Taylor, J. M. & Maciejewski, B. The hazard of accelerated tumor clonogen repopulation during radiotherapy. *Acta Oncol.* **27**, 131–146 (1988).
- Graboyes, E. M. et al. Association of treatment delays with survival for patients with head and neck cancer: a systematic review. *JAMA Otolaryngol. Head Neck Surg.* <https://doi.org/10.1001/jamaoto.2018.2716> (2018).
- Bernier, J. et al. Consensus guidelines for the management of radiation dermatitis and coexisting acne-like rash in patients receiving radiotherapy plus EGFR inhibitors for the treatment of squamous cell carcinoma of the head and neck. *Ann. Oncol. Off. J. Eur. Soc. Med. Oncol/ESMO.* **19**, 142–149. <https://doi.org/10.1093/annonc/mdm400> (2008).

17. Giro, C. et al. High rate of severe radiation dermatitis during radiation therapy with concurrent cetuximab in head and neck cancer: results of a survey in EORTC institutes. *Radiother. Oncol. J. Eur. Soc. Ther. Radiol. Oncol.* **90**, 166–171. <https://doi.org/10.1016/j.radonc.2008.09.007> (2009).
18. Pryor, D. I. et al. Enhanced toxicity with concurrent cetuximab and radiotherapy in head and neck cancer. *Radiother. Oncol. J. Eur. Soc. Ther. Radiol. Oncol.* **90**, 172–176. <https://doi.org/10.1016/j.radonc.2008.09.018> (2009).
19. Walsh, L. et al. Toxicity of cetuximab versus cisplatin concurrent with radiotherapy in locally advanced head and neck squamous cell cancer (LAHNSCC). *Radiother. Oncol. J. Eur. Soc. Ther. Radiol. Oncol.* **98**, 38–41. <https://doi.org/10.1016/j.radonc.2010.11.009> (2011).
20. Bonomo, P. et al. Management of severe bio-radiation dermatitis induced by radiotherapy and cetuximab in patients with head and neck cancer: emphasizing the role of calcium alginate dressings. *Support. Care Cancer Off J. Multinatl Assoc. Support. Care Cancer.* <https://doi.org/10.1007/s00520-018-4606-2> (2018).
21. Kawamura, M. et al. A scoring system predicting acute radiation dermatitis in patients with head and neck cancer treated with intensity-modulated radiotherapy. *Radiat. Oncol.* **14**, 14. <https://doi.org/10.1186/s13014-019-1215-2> (2019).
22. Bostrom, A., Lindman, H., Swartling, C., Berne, B. & Bergh, J. Potent corticosteroid cream (mometasone furoate) significantly reduces acute radiation dermatitis: results from a double-blind, randomized study. *Radiother. Oncol. J. Eur. Soc. Ther. Radiol. Oncol.* **59**, 257–265 (2001).
23. Fisher, J. et al. Randomized phase III study comparing best supportive care to Biafine as a prophylactic agent for radiation-induced skin toxicity for women undergoing breast irradiation: Radiation Therapy Oncology Group (RTOG) 97–13. *Int. J. Radiat. Oncol. Biol. Phys.* **48**, 1307–1310 (2000).
24. Heggie, S. et al. A phase III study on the efficacy of topical aloe vera gel on irradiated breast tissue. *Cancer Nurs.* **25**, 442–451 (2002).
25. Hemati, S. et al. Topical silver sulfadiazine for the prevention of acute dermatitis during irradiation for breast cancer. *Support. Care Cancer Off J. Multinatl Assoc. Support. Care Cancer.* **20**, 1613–1618. <https://doi.org/10.1007/s00520-011-1250-5> (2012).
26. Liguori, V., Guillemin, C., Pesce, G. F., Mirimanoff, R. O. & Bernier, J. Double-blind, randomized clinical study comparing hyaluronic acid cream to placebo in patients treated with radiotherapy. *Radiother. Oncol. J. Eur. Soc. Ther. Radiol. Oncol.* **42**, 155–161 (1997).
27. Maddocks-Jennings, W., Wilkinson, J. M. & Shillington, D. Novel approaches to radiotherapy-induced skin reactions: a literature review. *Complement. Ther. Clin. Pract.* **11**, 224–231. <https://doi.org/10.1016/j.ctcp.2005.02.001> (2005).
28. Miller, R. C. et al. Mometasone furoate effect on acute skin toxicity in breast cancer patients receiving radiotherapy: a phase III double-blind, randomized trial from the North Central Cancer Treatment Group N06C4. *Int. J. Radiat. Oncol. Biol. Phys.* **79**, 1460–1466. <https://doi.org/10.1016/j.ijrobp.2010.01.031> (2011).
29. Roy, I., Fortin, A. & Larochelle, M. The impact of skin washing with water and soap during breast irradiation: a randomized study. *Radiother. Oncol.* **58**, 333–339 (2001).
30. Wells, M. et al. Does aqueous or sucralfate cream affect the severity of erythematous radiation skin reactions? A randomised controlled trial. *Radiother. Oncol. J. Eur. Soc. Ther. Radiol. Oncol.* **73**, 153–162. <https://doi.org/10.1016/j.radonc.2004.07.032> (2004).
31. Williams, M. S. et al. Phase III double-blind evaluation of an aloe vera gel as a prophylactic agent for radiation-induced skin toxicity. *Int. J. Radiat. Oncol. Biol. Phys.* **36**, 345–349 (1996).
32. Bensadoun, R. J. et al. Daily baseline skin care in the prevention, treatment, and supportive care of skin toxicity in oncology patients: recommendations from a multinational expert panel. *Cancer Manag. Res.* **5**, 401–408. <https://doi.org/10.2147/CMAR.S52256> (2013).
33. Hu, J. J. et al. Complementary and alternative medicine in reducing radiation-induced skin toxicity. *Radiat. Environ. Biophys.* **53**, 621–626. <https://doi.org/10.1007/s00411-014-0540-y> (2014).
34. Meimeti, E. et al. Topical treatment of skin injury inflicted in mice by X-Ray irradiation. *Skin. Pharmacol. Physiol.* **31**, 175–183. <https://doi.org/10.1159/000487404> (2018).
35. Nakagami, Y. & Masuda, K. A novel Nrf2 activator from microbial transformation inhibits radiation-induced dermatitis in mice. *J. Radiat. Res.* **57**, 567–571. <https://doi.org/10.1093/jrr/rtrw039> (2016).
36. Ning, S. et al. Mitigation of radiation-induced dermatitis by activation of aldehyde dehydrogenase 2 using topical alda-1 in mice. *Radiat. Res.* **178**, 69–74 (2012).
37. Park, J. H. et al. Effect of photobiomodulation therapy on radiodermatitis in a mouse model: an experimental animal study. *Lasers Med. Sci.* **36**, 843–853. <https://doi.org/10.1007/s10103-020-03123-x> (2021).
38. Benavides, F., Oberyszyn, T. M., VanBuskirk, A. M., Reeve, V. E. & Kusewitt, D. F. The hairless mouse in skin research. *J. Dermatol. Sci.* **53**, 10–18. <https://doi.org/10.1016/j.jdermsci.2008.08.012> (2009).
39. Athar, M. et al. Ultraviolet B(UVB)-induced cox-2 expression in murine skin: an immunohistochemical study. *Biochem. Biophys. Res. Commun.* **280**, 1042–1047. <https://doi.org/10.1006/bbrc.2000.4201> (2001).
40. Byun, S. et al. Src kinase is a direct target of apigenin against UVB-induced skin inflammation. *Carcinogenesis.* **34**, 397–405. <https://doi.org/10.1093/carcin/bgs358> (2013).
41. Pal, H. C., Athar, M., Elmets, C. A. & Afaq, F. Fisetin inhibits UVB-induced cutaneous inflammation and activation of PI3K/AKT/NFkappaB signaling pathways in SKH-1 hairless mice. *Photochem. Photobiol.* **91**, 225–234. <https://doi.org/10.1111/php.12337> (2015).
42. Ruzicka, T., Walter, J. F. & Printz, M. P. Changes in arachidonic acid metabolism in UV-irradiated hairless mouse skin. *J. Investig. Dermatol.* **81**, 300–303. <https://doi.org/10.1111/1523-1747.ep12519287> (1983).
43. Singh, A., Willems, E., Singh, A., Ong, I. M. & Verma, A. K. Ultraviolet radiation-induced differential microRNA expression in the skin of hairless SKH1 mice, a widely used mouse model for dermatology research. *Oncotarget.* **7**, 84924–84937. <https://doi.org/10.18632/oncotarget.12913> (2016).
44. Voigt, A. Y. et al. Microbiome modulates immunotherapy response in cutaneous squamous cell carcinoma. *Exp. Dermatol.* **32**, 1624–1632. <https://doi.org/10.1111/exd.14864> (2023).
45. Hartono, S. P. et al. Vascular endothelial growth factor as an immediate-early activator of ultraviolet-Induced skin injury. *Mayo Clin. Proc.* **97**, 154–164. <https://doi.org/10.1016/j.mayocp.2021.08.018> (2022).
46. Jang, W. H. et al. In vivo characterization of early-stage radiation skin injury in a mouse model by two-photon microscopy. *Sci. Rep.* **6**, 19216. <https://doi.org/10.1038/srep19216> (2016).
47. Jang, H. et al. Impaired skin barrier due to sebaceous gland atrophy in the latent stage of radiation-induced skin injury: application of non-invasive diagnostic methods. *Int. J. Mol. Sci.* **19**. <https://doi.org/10.3390/ijms19010185> (2018).
48. Avci, P. et al. Animal models of skin disease for drug discovery. *Expert Opin. Drug Discov.* **8**, 331–355. <https://doi.org/10.1517/17460441.2013.761202> (2013).
49. de Andrade, C. B. V. et al. Radiotherapy-induced skin reactions induce fibrosis mediated by TGF-beta1 cytokine. *Dose Response.* **15**, 1559325817705019. <https://doi.org/10.1177/1559325817705019> (2017).
50. Yu, Z. et al. Tissue fibrosis induced by radiotherapy: current understanding of the molecular mechanisms, diagnosis and therapeutic advances. *J. Transl. Med.* **21**, 708. <https://doi.org/10.1186/s12967-023-04554-0> (2023).
51. Lee, J. L., Mukhtar, H., Bickers, D. R., Kopelovich, L. & Athar, M. Cyclooxygenases in the skin: pharmacological and toxicological implications. *Toxicol. Appl. Pharmacol.* **192**, 294–306. [https://doi.org/10.1016/s0041-008x\(03\)00301-6](https://doi.org/10.1016/s0041-008x(03)00301-6) (2003).
52. Institute, N. C. (ed) (ed DCTD Division of Cancer Treatment & Diagnosis) (2017).

53. Fowler, H. et al. Comorbidity prevalence among cancer patients: a population-based cohort study of four cancers. *BMC Cancer*. **20**, 2. <https://doi.org/10.1186/s12885-019-6472-9> (2020).
54. Simon, M. S. et al. A review of research on disparities in the care of black and white patients with cancer in detroit. *Front. Oncol.* **11**, 690390. <https://doi.org/10.3389/fonc.2021.690390> (2021).
55. Afshar, N., English, D. R. & Milne, R. L. Factors explaining socio-economic inequalities in cancer survival: a systematic review. *Cancer Control*. **28**, 10732748211011956. <https://doi.org/10.1177/10732748211011956> (2021).
56. Hojman, L. & Karsulovic, C. Cardiovascular disease-associated skin conditions. *Vasc. Health Risk Manag.* **18**, 43–53. <https://doi.org/10.2147/VHRM.S343319> (2022).
57. Mendes, A. L., Miot, H. A. & Haddad, V. J. Diabetes mellitus and the skin. *Bras. Dermatol.* **92**, 8–20. <https://doi.org/10.1590/abd1806-4841.20175514> (2017).
58. Bryant, R. A. & Rolstad, B. S. Examining threats to skin integrity. *Ostomy Wound Manag.* **47**, 18–27 (2001).
59. Beck, L. A. et al. Type 2 inflammation contributes to skin barrier dysfunction in atopic dermatitis. *JID Innov.* **2**, 100131. <https://doi.org/10.1016/j.xjidi.2022.100131> (2022).
60. Bromberger, L. et al. Radiation-induced alterations in multi-layered, in-vitro skin models detected by optical coherence tomography and histological methods. *PLoS One*. **18**, e0281662. <https://doi.org/10.1371/journal.pone.0281662> (2023).
61. Ewan, K. B. et al. Transforming growth factor-beta1 mediates cellular response to DNA damage in situ. *Cancer Res.* **62**, 5627–5631 (2002).
62. Flanders, K. C. et al. Interference with transforming growth factor-beta/Smad3 signaling results in accelerated healing of wounds in previously irradiated skin. *Am. J. Pathol.* **163**, 2247–2257. [https://doi.org/10.1016/s0002-9440\(10\)63582-1](https://doi.org/10.1016/s0002-9440(10)63582-1) (2003).
63. Flanders, K. C. Smad3 as a mediator of the fibrotic response. *Int. J. Exp. Pathol.* **85**, 47–64. <https://doi.org/10.1111/j.0959-9673.2004.00377.x> (2004).
64. Randall, K. & Coggle, J. E. Expression of transforming growth factor-beta 1 in mouse skin during the acute phase of radiation damage. *Int. J. Radiat. Biol.* **68**, 301–309. <https://doi.org/10.1080/09553009514551231> (1995).
65. Randall, K. & Coggle, J. E. Long-term expression of transforming growth factor TGF beta 1 in mouse skin after localized beta-irradiation. *Int. J. Radiat. Biol.* **70**, 351–360. <https://doi.org/10.1080/095530096145085> (1996).
66. Koerdts, S. et al. An expression analysis of markers of radiation-induced skin fibrosis and angiogenesis in wound healing disorders of the head and neck. *Radiat. Oncol.* **10**, 202. <https://doi.org/10.1186/s13014-015-0508-3> (2015).
67. Flanders, K. C. et al. Mice lacking Smad3 are protected against cutaneous injury induced by ionizing radiation. *Am. J. Pathol.* **160**, 1057–1068. [https://doi.org/10.1016/S0002-9440\(10\)64926-7](https://doi.org/10.1016/S0002-9440(10)64926-7) (2002).
68. Chihara, Y. et al. A small-molecule inhibitor of SMAD3 attenuates resistance to anti-HER2 drugs in HER2-positive breast cancer cells. *Breast Cancer Res. Treat.* **166**, 55–68. <https://doi.org/10.1007/s10549-017-4382-6> (2017).
69. Toloczko-Iwaniuk, N., Dziemianczyk-Pakiela, D., Nowaszewska, B. K., Celinska-Janowicz, K. & Milyk, W. Celecoxib in cancer therapy and prevention—review. *Curr. Drug Targets*. **20**, 302–315. <https://doi.org/10.2174/1389450119666180803121737> (2019).
70. An, K. P. et al. Cyclooxygenase-2 expression in murine and human nonmelanoma skin cancers: implications for therapeutic approaches. *Photochem. Photobiol.* **76**, 73–80. [https://doi.org/10.1562/0031-8655\(2002\)076%3C0073:ceimah%3E2.0.co;2](https://doi.org/10.1562/0031-8655(2002)076%3C0073:ceimah%3E2.0.co;2) (2002).
71. Liang, L. et al. Celecoxib reduces skin damage after radiation: selective reduction of chemokine and receptor mRNA expression in irradiated skin but not in irradiated mammary tumor. *Am. J. Clin. Oncol.* **26**, 114–121. <https://doi.org/10.1097/O1.COC.0000074149.95710.40> (2003).
72. Ghasemi, A., Danesh, B., Yazdani-Charati, J. & Hosseinimehr, S. J. Randomized double-blind placebo-controlled trial of celecoxib for the prevention of skin toxicity in patients receiving radiation therapy for breast cancer. *Antinflamm. Antiallergy Agents Med. Chem.* **17**, 57–67. <https://doi.org/10.2174/187152301766618041162114> (2018).
73. Brown, A. P., Wendler, D. S., Camphausen, K. A., Miller, F. G. & Citrin, D. Performing nondiagnostic research biopsies in irradiated tissue: a review of scientific, clinical, and ethical considerations. *J. Clin. Oncol. Off. J. Am. Soc. Clin. Oncol.* **26**, 3987–3994. <https://doi.org/10.1200/JCO.2008.16.9896> (2008).
74. Siegel, R. L., Miller, K. D. & Jemal, A. Cancer statistics, 2017. *CA Cancer J. Clin.* **67**, 7–30. <https://doi.org/10.3322/caac.21387> (2017).
75. Siegel, R. L., Miller, K. D., Fuchs, H. E. & Jemal, A. Cancer statistics, 2021. *CA Cancer J. Clin.* **71**, 7–33. <https://doi.org/10.3322/caac.21654> (2021).
76. Fuzissaki, M. A., Paiva, C. E., de Oliveira, M. A., Canto, P. P. L. & Maia, Y. C. The impact of radiodermatitis on breast cancer patients' quality of life during treatment: a prospective cohort study. *J. Pain Symptom Manag.* <https://doi.org/10.1016/j.jpainsymman.2019.03.017> (2019).
77. Wright, J. L. et al. Racial variations in radiation-induced skin toxicity severity: data from a prospective cohort receiving postmastectomy radiation. *Int. J. Radiat. Oncol. Biol. Phys.* **90**, 335–343. <https://doi.org/10.1016/j.ijrobp.2014.06.042> (2014).
78. Maymone, M. B. C. et al. The impact of skin hyperpigmentation and hyperchromia on quality of life: a cross-sectional study. *J. Am. Acad. Dermatol.* **77**, 775–778. <https://doi.org/10.1016/j.jaad.2017.05.009> (2017).
79. Lee, J. et al. Patient-reported symptoms of radiation dermatitis during breast cancer radiotherapy: a pilot study. *Qual. Life Res.* **26**, 1713–1719. <https://doi.org/10.1007/s11136-017-1526-4> (2017).
80. Balter, S. & Miller, D. L. Patient skin reactions from interventional fluoroscopy procedures. *AJR Am. J. Roentgenol.* **202**, W335–342. <https://doi.org/10.2214/AJR.13.12029> (2014).
81. Blades, R., Chan, R., Yates, P. & McPhail, S. in *Oncology Nursing Society (ONS) Annual Congress*.
82. Haruna, F., Lipsett, A. & Marignol, L. Topical management of acute radiation dermatitis in breast cancer patients: a systematic review and meta-analysis. *Anticancer Res.* **37**, 5343–5353. <https://doi.org/10.21873/anticancer.11960> (2017).
83. Lucey, P. et al. Practice patterns for the prophylaxis and treatment of acute radiation dermatitis in the United States. *Support Care Cancer.* **25**, 2857–2862. <https://doi.org/10.1007/s00520-017-3701-0> (2017).
84. Iddins, C. J., DiCarlo, A. L., Ervin, M. D., Herrera-Reyes, E. & Goans, R. E. Cutaneous and local radiation injuries. *J. Radiol. Prot.* **42**. <https://doi.org/10.1088/1361-6498/ac241a> (2022).
85. Christensen, D. M., Parillo, S. J., Glassman, E. S. & Sugarman, S. L. Management of ionizing radiation injuries and illnesses, part 2: nontherapeutic radiologic/nuclear incidents. *J. Am. Osteopath. Assoc.* **114**, 383–389. <https://doi.org/10.7556/jaoa.2014.075> (2014).
86. Balter, S., Hopewell, J. W., Miller, D. L., Wagner, L. K. & Zelefsky, M. J. Fluoroscopically guided interventional procedures: a review of radiation effects on patients' skin and hair. *Radiology.* **254**, 326–341. <https://doi.org/10.1148/radiol.2542082312> (2010).
87. Fisher, R. F. et al. AAPM medical physics practice guideline 12.A: Fluoroscopy dose management. *J. Appl. Clin. Med. Phys.* **23**, e13526. <https://doi.org/10.1002/acm2.13526> (2022).
88. Wei, K. C. et al. An innovative targeted therapy for fluoroscopy-induced chronic radiation dermatitis. *J. Mol. Med. (Berl)*. **100**, 135–146. <https://doi.org/10.1007/s00109-021-02146-3> (2022).
89. Gottlob, P. et al. The outcome of local radiation injuries: 14 years of follow-up after the Chernobyl accident. *Radiat. Res.* **155**, 409–416. [https://doi.org/10.1667/0033-7587\(2001\)155\[0409:toolri\]2.0.co;2](https://doi.org/10.1667/0033-7587(2001)155[0409:toolri]2.0.co;2) (2001).
90. Kiang, J. G. & Ledney, G. D. Skin injuries reduce survival and modulate corticosterone, C-reactive protein, complement component 3, IgM, and prostaglandin E 2 after whole-body reactor-produced mixed field (n + gamma-photons) irradiation. *Oxid Med Cell Longev* 821541 (2013). <https://doi.org/10.1155/2013/821541>
91. Bray, F. N., Simmons, B. J., Wolfson, A. H. & Nouri, K. Acute and chronic cutaneous reactions to ionizing radiation therapy. *Dermatol. Ther. (Heidelb)*. **6**, 185–206. <https://doi.org/10.1007/s13555-016-0120-y> (2016).

92. Denham, J. W. & Hauer-Jensen, M. The radiotherapeutic injury—a complex ‘wound’. *Radiother Oncol.* **63**, 129–145 (2002).
93. Benjamin, E. J. et al. Heart disease and stroke statistics-2019 update: a report from the American Heart Association. *Circulation.* **139**, e56–e528. <https://doi.org/10.1161/CIR.0000000000000659> (2019).
94. Kim, T. H., Ananthaswamy, H. N., Kripke, M. L. & Ullrich, S. E. Advantages of using hairless mice versus haired mice to test sunscreen efficacy against photoimmune suppressions. *Photochem. Photobiol.* **78**, 37–42 (2003).
95. Baghani, H. R. et al. Dosimetric evaluation of gafchromic EBT2 film for breast intraoperative electron radiotherapy verification. *Phys. Med.* **31**, 37–42. <https://doi.org/10.1016/j.ejmp.2014.08.005> (2015).
96. Reisman, S. A. et al. Topical application of RTA 408 lotion activates Nrf2 in human skin and is well-tolerated by healthy human volunteers. *BMC Dermatol.* **15**, 10. <https://doi.org/10.1186/s12895-015-0029-7> (2015).
97. Robinson, M. D. & Smyth, G. K. Moderated statistical tests for assessing differences in tag abundance. *Bioinformatics.* **23**, 2881–2887. <https://doi.org/10.1093/bioinformatics/btm453> (2007).
98. Ritchie, M. E. et al. Limma powers differential expression analyses for RNA-sequencing and microarray studies. *Nucleic Acids Res.* **43**, e47. <https://doi.org/10.1093/nar/gkv007> (2015).
99. Alam, S. K. et al. ASCL1-regulated DARPP-32 and t-DARPP stimulate small cell lung cancer growth and neuroendocrine tumour cell proliferation. *Br. J. Cancer.* **123**, 819–832. <https://doi.org/10.1038/s41416-020-0923-6> (2020).
100. Martin, M., Lefaix, J. & Delanian, S. TGF-beta1 and radiation fibrosis: a master switch and a specific therapeutic target? *Int. J. Radiat. Oncol. Biol. Phys.* **47**, 277–290. [https://doi.org/10.1016/s0360-3016\(00\)00435-1](https://doi.org/10.1016/s0360-3016(00)00435-1) (2000).
101. Cheki, M. et al. COX-2 in radiotherapy: a potential target for Radioprotection and Radiosensitization. *Curr. Mol. Pharmacol.* **11**, 173–183. <https://doi.org/10.2174/1874467211666180219102520> (2018).

Acknowledgements

The authors would like to thank Jessica Coffey and Amy Morgan for their support for data acquisition.

Author contributions

Author contributions Conceptualization and design: JL, DS, LH Development of methodology: JL, DS, AC, CF, AG, LH Data acquisition: JL, DS, AC, CF, KDD Data analysis: JL, DS, AC, CF, YR, LW, SKA, RY, LH Writing and primary revision: JL, DS, AG, LH Review & secondary revision: all authors (JL, DS, AC, CF, KDD, AG, YR, LW, SKA, RY, LH) read, provided secondary revision, and approved the submitted manuscript.

Declarations

Competing interests

The authors declare no competing interests.

The authors declare no competing interests.

Additional information

Supplementary Information The online version contains supplementary material available at <https://doi.org/10.1038/s41598-024-76021-9>.

Correspondence and requests for materials should be addressed to J.L. or L.H.H.

Reprints and permissions information is available at www.nature.com/reprints.

Publisher’s note Springer Nature remains neutral with regard to jurisdictional claims in published maps and institutional affiliations.

Open Access This article is licensed under a Creative Commons Attribution 4.0 International License, which permits use, sharing, adaptation, distribution and reproduction in any medium or format, as long as you give appropriate credit to the original author(s) and the source, provide a link to the Creative Commons licence, and indicate if changes were made. The images or other third party material in this article are included in the article’s Creative Commons licence, unless indicated otherwise in a credit line to the material. If material is not included in the article’s Creative Commons licence and your intended use is not permitted by statutory regulation or exceeds the permitted use, you will need to obtain permission directly from the copyright holder. To view a copy of this licence, visit <http://creativecommons.org/licenses/by/4.0/>.

© The Author(s) 2024