UC Irvine
Clinical Practice and Cases in Emergency Medicine

Title
Confirmation of Sengstaken-Blakemore Tube Placement Using POCUS During Life-Threatening Upper Gastrointestinal Bleed: A Case Report

Permalink
https://escholarship.org/uc/item/2dm121bp

Journal
Clinical Practice and Cases in Emergency Medicine, 0(0)

Authors
Sawhney, Preet
Dopazo, Heleina
Lee, Yonghoon
et al.

Publication Date
2026-11-24

DOI
10.5811/cpcem.65067

Copyright Information
This work is made available under the terms of a Creative Commons Attribution License, available at https://creativecommons.org/licenses/by/4.0/

Peer reviewed

eScholarship.org Powered by the California Digital Library
University of California

Confirmation of Sengstaken-Blakemore Tube Placement Using POCUS During Life-Threatening Upper Gastrointestinal Bleed: A Case Report

Preet Sawhney, DO*
Heleina Dopazo, MD*
Yonghoon Lee, MD*
Davis Kinas, DO*
Eric Boccio, MD, MPH*†
Michael Dalley, DO*

*Mount Sinai Medical Center of Florida, Department of Emergency Medicine, Miami Beach, Florida
†New York Medical College, Department of Emergency Medicine, Valhalla, New York

Section Editor: Shadi Lahham, MD
Submission history: Submitted May 5, 2026; Revision received September 1, 2026; Accepted September 2, 2026
Electronically published November 24, 2026
Full text available through open access at http://escholarship.org/uc/uciem_cpcem
DOI: 10.5811/cpcem.65067

Introduction: Acute gastroesophageal variceal hemorrhage is a life-threatening emergency requiring rapid hemostasis. Sengstaken-Blakemore tube placement remains an important temporizing intervention in patients with refractory bleeding; however, improper positioning, particularly inflation of the gastric balloon within the esophagus, can result in catastrophic complications including esophageal rupture. Radiographic confirmation is traditionally recommended but may delay intervention in unstable patients. Point-of-care ultrasound (POCUS) has emerged as a potential alternative for real-time confirmation of balloon placement. Our case demonstrates how POCUS can be used to rapidly and safely confirm intragastric Sengstaken-Blakemore tube placement prior to balloon inflation in an unstable patient with massive variceal hemorrhage and hemorrhagic shock.

Case Report: We describe a 62-year-old woman with severe alcohol use disorder who presented with massive hematemesis and hemorrhagic shock. Despite administration of ceftriaxone, octreotide, pantoprazole, vasopressors, and activation of massive transfusion protocol, the patient remained hemodynamically unstable with ongoing large-volume hematemesis. After endotracheal intubation, a Sengstaken-Blakemore tube was placed. Point-of-care ultrasound using a curvilinear probe was performed prior to full balloon inflation, demonstrating the gastric balloon within the stomach through dynamic visualization of balloon movement and intragastric air. Following confirmation, the gastric balloon was fully inflated and traction applied, resulting in effective tamponade and improved hemodynamics. Subsequent endoscopy confirmed bleeding esophageal and gastroesophageal varices, which were successfully banded, and the patient was ultimately discharged from the hospital.

Conclusion: Point-of-care ultrasound is a tool that can be rapidly employed at the bedside to confirm intragastric placement of Sengstaken-Blakemore tubes, potentially improving time to tamponade and minimizing the risk of catastrophic malposition-related complications in patients with massive variceal hemorrhage. [Clin Pract Cases Emerg Med. 2026;X(X):XXX–XXX.]

Keywords: *Sengstaken–Blakemore tube; point-of-care ultrasound; gastroesophageal varices; gastrointestinal bleeding; case report*.

INTRODUCTION

Acute gastroesophageal variceal hemorrhage is a life-threatening emergency associated with substantial morbidity and mortality in patients with portal hypertension and cirrhosis. Historically, mortality from a single episode of gastroesophageal variceal bleeding has been reported between 30% to 50%, particularly in patients with advanced liver disease.[1] Despite advances in pharmacologic therapy, endoscopic band ligation, and critical care management, 6-week mortality remains as high as 15% to 25%.[2-3] Current standards of care include early resuscitation, initiation of vasoactive agents, antibiotic prophylaxis, and urgent endoscopy; however, profound hemodynamic instability frequently delays definitive endoscopic intervention. In such settings, balloon tamponade using devices such as the Sengstaken-Blakemore tube remains an essential temporizing measure when first-line therapies are unavailable or ineffective.

Although balloon tamponade is effective in rapidly controlling hemorrhage, improper positioning, particularly inflation of the gastric balloon within the esophagus, can result in catastrophic complications including esophageal rupture, mediastinitis, airway compromise, and cardiovascular collapse in 10% to 20% of cases.[4] Radiographic confirmation of balloon placement prior to full inflation is traditionally recommended to mitigate these risks, but obtaining imaging can delay hemostasis in unstable patients. Alternative confirmation strategies such as endoscopic-guided placement and point-of-care ultrasound (POCUS) have been explored.[5-7] Point-of-care ultrasound has demonstrated the ability to visualize intragastric balloon placement at the bedside and to mitigate complications related to ectopic placement; however, its use remains largely limited to case reports and small observational studies. This report describes the use of POCUS to confirm intragastric Sengstaken–Blakemore tube placement prior to balloon inflation in a patient with massive variceal hemorrhage and hemorrhagic shock.

CPC-EM Capsule

What do we already know about this clinical entity?
Gastroesophageal balloon tamponade controls refractory variceal hemorrhage, but malposition causes esophageal rupture in up to 6% of cases.

What makes this presentation of disease reportable?
Point-of-care ultrasound (POCUS) confirmed intragastric balloon placement at bedside before full inflation in an unstable variceal bleed patient.

What is the major learning point?
Dynamic POCUS findings (balloon movement with tube manipulation, air injection) can reliably confirm intragastric Sengstaken-Blakemore placement in real time.

How might this improve emergency medicine practice?
POCUS may let emergency clinicians confirm balloon tamponade placement faster than radiographs, reducing time to hemostasis and risk of catastrophic malposition.

CASE REPORT

A 62-year-old woman was brought to the emergency department after being found at work vomiting blood into a bucket. She reported one day of hematemesis and five days of melena, accompanied by severe abdominal pain. She denied fever, chest pain, or dyspnea. She had no known history of gastrointestinal bleeding or cirrhosis and lacked established primary care. According to her daughter, she had consumed more than one bottle of wine daily in addition to beer for several decades.

On arrival, her vitals were as follows: heart rate, 73 beats per minute; blood pressure, 93/35 mm Hg; respiratory rate, 22 breaths per minute; temperature, 36.1 °C; and SpO_2, 99% on room air. She appeared acutely ill and continued to have repeated episodes of bright-red hematemesis. Physical examination was notable for epigastric tenderness and bilateral lower-extremity edema.

Laboratory studies revealed: hemoglobin level, 9.3 g/dL (reference range, 12-16 g/dL); platelet count, 142 × 10^3 cells/μL (150-450 × 10^3/μL); international normalized ratio, 1.7 (0.1-1.1), and fibrinogen level, 181 mg/dL (200-400 mg/dL). The lactate was elevated to 8.7 mmol/L (0.4-2 mmol/L). Additional abnormalities included hypokalemia, potassium of 1.12 mg/dL (0.55-1.02 mg/dL), and abnormal hepatic function tests, including elevated aminotransferases, hyperbilirubinemia, and hypoalbuminemia.

Shortly after arrival, the patient became profoundly hypotensive with a persistently low mean arterial pressure despite ongoing resuscitation and continued hematemesis. Variceal hemorrhage was suspected. Intravenous ceftriaxone, octreotide, and pantoprazole were administered, and a massive transfusion protocol was initiated. A large-bore femoral venous introducer catheter was placed to facilitate rapid transfusion. During initial resuscitation, the patient received 16 units of packed red blood cells, 8 units of fresh frozen plasma, and 2 units of cryoprecipitate. Norepinephrine was initiated for hemodynamic support. Despite aggressive resuscitation efforts, hemorrhage persisted. Gastroenterology was consulted with plans for emergent endoscopy following

airway protection and stabilization.

Given ongoing massive bleeding and hemodynamic instability, the patient was endotracheally intubated for airway protection, and a Sengstaken–Blakemore tube was placed as a temporizing measure to achieve hemorrhage control prior to endoscopy. After esophageal placement was confirmed with the video laryngoscope used during intubation, the tube was advanced to a standard depth of 50 cm and the gastric balloon was partially inflated with 50 mL of air.

Before full inflation, intragastric placement of the balloon was confirmed using POCUS due to the patient's continued hemorrhagic shock and the need for immediate confirmation. A curvilinear transducer was placed transversely over the epigastrium. The air-filled gastric balloon was visualized as a hyperechoic crescent-shaped structure with posterior anechoic shadow within the gastric lumen (Images 1 and 2). Correct positioning was confirmed by advancing and retracting the tube slightly while observing corresponding movement of the balloon on ultrasound. The presence of intragastric blood provided an acoustic window that improved visualization. Injection of air through the gastric port corresponded with the presence of bubbles within the stomach, and inflation and deflation of the gastric balloon resulted in observable changes in the size of the hyperechoic structure visualized in real time. These dynamic findings were considered sufficient to confirm intragastric placement.

Following ultrasound confirmation, the gastric balloon was fully inflated to a total volume of 200 mL. Gentle traction was applied until resistance was felt at the gastroesophageal junction and maintained using a 1-L normal saline bag as counterweight. The tube was secured at the mouth at 50 cm depth, and continuous suction was applied to the gastric aspiration port. Owing to substantial reduction in bleeding after gastric balloon inflation and traction, the esophageal balloon was not subsequently inflated.

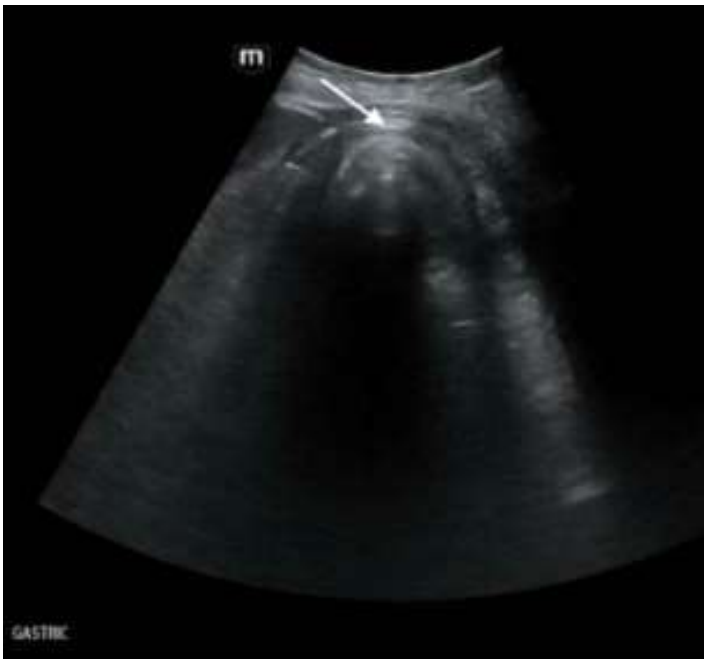

Image 1. Transverse curvilinear ultrasound of the epigastric region immediately after partial inflation of the gastric balloon with 50 milliliters of air. The gastric balloon (arrow) appears as a hyperechoic structure within the gastric lumen.



Image 2. Ultrasound view from the same examination with slight probe angulation. The gastric balloon (arrow) appears as a hyperechoic crescent-shaped structure with posterior acoustic shadowing adjacent to intragastric contents (star), confirming intragastric placement prior to full inflation and traction.

Following placement, hemostasis was achieved and hemodynamics improved, and the patient was weaned off vasopressors. Emergent esophagogastroduodenoscopy confirmed bleeding esophageal and gastroesophageal varices, which were successfully banded, and the Sengstaken-Blakemore tube was subsequently removed.

The patient was subsequently admitted to the medical intensive care unit with hemorrhagic shock secondary to massive variceal hemorrhage in the setting of newly recognized alcohol-associated cirrhosis and portal hypertension, confirmed on cross-sectional imaging. Her hospital course was complicated by recurrent bleeding episodes requiring repeat endoscopic band ligation and hemostatic intervention. She was ultimately extubated, weaned from vasopressors, and discharged after 38 days.

DISCUSSION

Acute gastroesophageal variceal hemorrhage remains a major cause of morbidity and mortality in patients with cirrhosis and portal hypertension. Although modern

management has reduced short-term mortality, outcomes remain poor (20% to 45% mortality) in patients presenting with hemodynamic shock, advanced liver disease, or failure of initial hemostasis.[2] Gastroesophageal balloon tamponade remains an important rescue therapy when hemorrhage is refractory to medical management or when definitive interventions are delayed. Current guidelines recommend endoscopy within 6–12 hours following initial resuscitation and stabilization. Real-world practice reveals only approximately 50% to 60% of patients undergo early endoscopy within this timeframe with delays due to hemodynamic instability, airway compromise, or ongoing massive bleeding.[1,4]

Despite its efficacy, gastroesophageal balloon tamponade carries significant risk, with reported complication rates of 10% to 20%. Esophageal rupture, which occurs in up to 6% of cases, is among the most devastating complications and is strongly associated with improper balloon positioning and delayed recognition.[8] Standard practice recommends radiographic confirmation of balloon position prior to full inflation; however, this step may introduce delays in critically unstable patients and may be limited by image quality or accessibility.

Point-of-care ultrasound offers several theoretical advantages in this context. It allows for real-time, bedside confirmation of intragastric balloon placement without interrupting resuscitation efforts. In patients with active upper gastrointestinal bleeding, the presence of blood and fluid in the stomach often enhances sonographic visualization of intragastric structures.[9] Point-of-care ultrasound has also been shown to identify malposition-related complications, including cardiovascular compression from misplaced balloons.[7] Limitations include operator dependence and suboptimal imaging windows in patients with obesity, excessive bowel gas, or large-volume ascites.[6]

In this case, POCUS enabled rapid confirmation of correct intragastric balloon position prior to full inflation, facilitating immediate tamponade in the setting of ongoing massive hemorrhage and shock. The ability to dynamically visualize balloon position and movement provided reassurance against esophageal malposition and likely reduced the risk of complications related to ectopic placement and delays in care. This approach highlights the potential role of POCUS as a valuable adjunct to traditional radiographic imaging.

CONCLUSION

Point-of-care ultrasound represents a rapid, bedside adjunct for confirming intragastric placement of Sengstaken-Blakemore tubes in patients with massive esophageal variceal hemorrhage. In this case, POCUS allowed immediate confirmation of correct gastroesophageal balloon position prior to inflation, facilitating timely tamponade and hemostasis while avoiding delays associated with radiographic imaging. Given the potentially catastrophic consequences of ectopic balloon positioning, including esophageal rupture, the ability to directly visualize balloon location in real time may enhance procedural safety. Although operator-dependent and limited by patient factors affecting image acquisition, POCUS-guided confirmation offers a practical alternative when rapid intervention is required. Broader adoption and further study may help define its role in improving safety and reducing time to hemostasis in critically ill patients.

Patient consent has been obtained and filed for the publication of this case report.

Address for Correspondence: Eric Boccio, MD, MPH, Mount Sinai Medical Center of Florida, Department of Emergency Medicine, 4300 Alton Road, Miami Beach, FL 33140. Email: Eric.Boccio@msmc.com.

Conflicts of Interest: By the *CPC-EM* article submission agreement, all authors are required to disclose all affiliations, funding sources and financial or management relationships that could be perceived as potential sources of bias. The authors disclosed none.

Copyright: © 2026 Sawhney et al. This is an open access article distributed in accordance with the terms of the Creative Commons Attribution (CC BY 4.0) License. See: http://creativecommons.org/licenses/by/4.0/

REFERENCES

1. Hearnshaw SA, Logan RFA, Lowe D, et al. Acute upper gastrointestinal bleeding in the UK: patient characteristics, diagnoses and outcomes in the 2007 UK audit. *Gut*. 2011;60(10):1327–1335.
2. Diaz-Soto MP and Garcia-Tsao G. Management of varices and variceal hemorrhage in liver cirrhosis: a recent update. *Ther Adv Gastroenterol*. 2022;15:17562848221101712.
3. Kamath PS and Mookerjee RP. Individualized care for portal hypertension: not quite yet. *J Hepatol*. 2015;63(3):543–545.
4. Stanley AJ and Laine L. Management of acute upper gastrointestinal bleeding. *BMJ*. 2019;364:l536.
5. Lin TC, Bilir BM, Powis ME. Endoscopic placement of Sengstaken-Blakemore tube. *J Clin Gastroenterol*. 2000;31(1):29–32.
6. Lin AC, Hsu YH, Wang TL, et al. Placement confirmation of Sengstaken-Blakemore tube by ultrasound. *Emerg Med J*. 2006;23(6):487.
7. Ren J. An unusual cause of left atrium compression by ultrasound: a case report. *Medicine* (Baltimore). 2025;104(32):e42625
8. Powell M and Journey JD. Sengstaken-Blakemore tube. 2025. Available at: https://www.ncbi.nlm.nih.gov/books/NBK563189/. Accessed September 18, 2026.
9. Lock G, Reng M, Messman H, et al. Inflation and positioning of the gastric balloon of a Sengstaken-Blakemore tube under ultrasonographic control. *Gastrointest Endosc*. 1997;45(6):538.