

# UC San Diego

## UC San Diego Previously Published Works

### Title

Disc Hemorrhages Are Associated With the Presence and Progression of Glaucomatous Central Visual Field Defects.

### Permalink

<https://escholarship.org/uc/item/2f18t5mv>

### Journal

Journal of Glaucoma, 29(6)

### Authors

Shukla, Aakriti

Sirinek, Portia

De Moraes, C

et al.

### Publication Date

2020-06-01

### DOI

10.1097/IJG.0000000000001487

Peer reviewed



Published in final edited form as:

*J Glaucoma*. 2020 June ; 29(6): 429–434. doi:10.1097/IJG.0000000000001487.

## Disc Hemorrhages Are Associated With The Presence And Progression Of Glaucomatous Central Visual Field Defects

Aakriti Garg Shukla, MD<sup>1</sup>, Portia E. Sirinek, MD<sup>1</sup>, C. Gustavo De Moraes, MD, PhD, MPH<sup>1</sup>, Dana M. Blumberg, MD, MPH<sup>1</sup>, George A. Cioffi, MD<sup>1</sup>, Alon Skaat, MD<sup>2</sup>, Christopher Girkin, MD, MSPH<sup>3</sup>, Robert N. Weinreb, MD<sup>4</sup>, Linda M. Zangwill, PhD<sup>4</sup>, Donald C. Hood, PhD<sup>5</sup>, Jeffrey M. Liebmann, MD<sup>1</sup>

<sup>1</sup>Bernard and Shirlee Brown Glaucoma Research Laboratory, Columbia University Medical Center, Edward S. Harkness Eye Institute, New York, NY.

<sup>2</sup>Goldschleger Eye Institute, Sheba Medical Center, Sackler Faculty of Medicine, Tel Aviv University, Tel Aviv, Israel.

<sup>3</sup>School of Medicine, University of Alabama, Birmingham, AL.

<sup>4</sup>Hamilton Glaucoma Center, Shiley Eye Institute, Viterbi Family Department of Ophthalmology, University of California, San Diego, CA.

<sup>5</sup>Departments of Psychology and Ophthalmology, Columbia University, New York, NY.

### Abstract

**Purpose:** To study the relationship between disc hemorrhage (DH) and the presence and progression of glaucomatous central visual field (VF) damage.

**Methods:** Cross-sectional and longitudinal analyses were performed on data from the African Descent and Glaucoma Evaluation Study (ADAGES) cohort. Two masked investigators reviewed disc photographs for the presence and location of DH. 24–2 central VF damage was based on the number of test locations within the central 10 degrees of the 24–2 field pattern deviation (PD) and their mean total deviation (MTD). 10–2 central VF damage was based on PD and MTD. Main outcome measures were the association between DH and presence of central VF damage and between DH and worsening of VF.

**Results:** DH was detected in 21 of 335 eyes (6.2%). In the cross-sectional analysis, DH was significantly associated with more severe central damage on 24–2 (incidence rate ratios, IRR= 1.47; 95% CI= 1.02 to 2.12; P= 0.035) and 10–2 VFs (IRR= 1.81; 95% CI= 1.26 to 2.60; P= 0.001). In the longitudinal analysis, DH eyes progressed faster than non-DH eyes based on 24–2 global MTD rates (difference in slopes,  $\beta$ = -0.06; 95% CI= -0.11 to -0.01; P= 0.009) and 10–2 MTD rates ( $\beta$ = -0.10; 95% CI= -0.14 to -0.06; P< 0.001), but not 24–2 central MTD rates ( $\beta$ = -0.02; 95% CI= -0.078 to 0.026; P=0.338).

**Corresponding author:** C. Gustavo De Moraes, M.D., Ph.D., M.P.H, Edward S. Harkness Eye Institute, 635 West 165th Street, Box 69, New York, NY 10032, cvd2109@cumc.columbia.edu, Phone: (212) 342-0630.

**Trial Registration:** [clinicaltrials.gov](https://clinicaltrials.gov) Identifier: NCT00221923

**Conclusion:** DH was associated with the presence and progression of central VF defects. DH identification should prompt intensive central VF monitoring and surveillance with 10–2 fields to detect progression.

## PRECIS

In this prospective cohort study, disc hemorrhages were associated with more severe central damage on 24–2 and 10–2 visual fields, and faster progression globally on 24–2 visual fields and centrally on 10–2 visual fields.

## Keywords

central visual field damage; disc hemorrhage; risk factors; glaucoma; progression

---

## INTRODUCTION

Optic disc hemorrhage (DH) is a relatively specific diagnostic feature for glaucoma, occurring at rates of 4.0 to 5.7% in glaucoma patients compared with 0.2% in normal eyes.<sup>1,2</sup> DH typically occurs in, or adjacent to, regions of localized retinal nerve fiber layer (RNFL) defects, neuroretinal rim notching, and parapapillary atrophy.<sup>2,3</sup> Many studies have demonstrated that DH is a significant risk factor for development of glaucoma, as well as structural and functional progression.<sup>4–7</sup> In RNFL and visual field regions corresponding to DH locations, there are faster rates of progression before and after the detection of DH.<sup>4,8</sup> In fact, the rate of visual field progression in eyes with DH can be as much as twice the rate of progression in eyes without DH.<sup>4,9</sup>

There is substantial evidence that glaucoma may affect the central visual field, even in early stages of disease.<sup>10–15</sup> Regarding visual field progression, Wu et al have recently reported that, for a similar frequency of testing, duration of follow-up, and specificity, the 10–2 visual field pattern had greater power than the central points of the 24–2 to detect statistically significant change.<sup>16</sup> Furthermore, Park et al found a significantly higher incidence of DH in patients with functional damage detected only within 10 degrees of fixation, providing additional evidence for a relationship between DH and early damage to the central visual field.<sup>17</sup>

We aimed to assess the relationship between DH and the presence and progression of central visual field damage. We tested this hypothesis in cross-sectional (detection) and longitudinal (progression) analyses. In the former, we hypothesized that DH eyes are more likely to have central visual field damage than non-DH eyes. For the latter, we tested whether DH eyes experience more rapid global and central visual field loss than non-DH eyes as measured with the entire 24–2 VF, central points of the 24–2 VF, and 10–2 VF test patterns.

## METHODS

The multi-site African Descent and Glaucoma Evaluation Study (ADAGES) collaboration ([clinicaltrials.gov](https://clinicaltrials.gov) Identifier: [NCT00221923](https://clinicaltrials.gov/ct2/show/study/NCT00221923)) includes the Hamilton Glaucoma Center at the Department of Ophthalmology, University of California-San Diego (UCSD) (data

coordinating center), Edward S. Harkness Eye Institute at the Columbia University Medical Center, and the Department of Ophthalmology, University of Alabama-Birmingham (UAB). The institutional review boards at all sites approved the study methodology, which adheres to the tenets of the Declaration of Helsinki and to the Health Insurance Portability and Accountability Act. All participants gave written informed consent. Participants of both African and European ancestry were included in this longitudinal cohort study of individuals with healthy eyes, glaucoma suspects, and established glaucoma. Methodological details have been described previously.<sup>18</sup>

### **Inclusion criteria at baseline**

All participants had open angles, best-corrected visual acuity (BCVA) 20/40, and refractive error <5.0 diopters sphere and 3.0 diopters cylinder. At baseline, we required at least one good-quality stereophotograph and two reliable standard automated perimetry Humphrey Field Analyzer SITA standard 24–2 field test results, defined as <15% false positives, <33% false negatives, and <20% fixation losses and without artifacts as assessed by the Visual Field Assessment Center (VISFact) at the University of California, San Diego. Both eyes were included, except in cases where only one eye met the study criteria. All participants were older than 18 years. Diabetic participants without evidence of retinopathy were included.

For the present study, only eyes who had glaucomatous optic neuropathy or were suspected to have glaucomatous optic neuropathy were included. Glaucomatous optic neuropathy was defined as excavation, neuroretinal rim thinning or notching, localized or diffuse RNFL defect, or vertical cup-disc ratio (VCDR) asymmetry > 0.2 between eyes by at least two independent graders.

### **Exclusion criteria**

Participants were excluded if they had a history of intraocular surgery (except for uncomplicated cataract surgery), secondary causes of glaucoma (e.g., iridocyclitis, trauma), other systemic or ocular diseases known to affect the visual field (e.g., pituitary lesions, demyelinating diseases, retinal disease, etc.), significant cognitive impairment, history of stroke, Alzheimer disease or dementia, problems other than glaucoma affecting color vision, an inability to perform visual field examinations reliably, or a life-threatening disease that precluded retention in the study.

For the cross-sectional analysis, eyes were excluded if they did not have 24–2 visual fields from at least two dates. For the longitudinal analysis, eyes were excluded if they did not have at least five 24–2 and 10–2 visual field tests on five visits.

### **Evaluation of the optic nerve complex**

Stereoscopic disc photos were taken annually for up to 13 years. Disc photos were reviewed for the presence of DH by two independent glaucoma specialists (CGDM and AS), who were masked to participant diagnosis, race, and all other identifying characteristics. Cases of disagreement were adjudicated by a third, experienced grader (JML).

DH was defined as a splinter or flame-shaped hemorrhage on or within the RNFL or neuroretinal rim with a proximal edge no further than ½ disc diameter from the disc margin, or hemorrhages within the cup area.<sup>2</sup> The location of the DH was recorded as nasal, superonasal, superotemporal, temporal, inferotemporal, or inferonasal based upon the Garway-Heath structure-function map.<sup>19</sup>

### Evaluation of the visual field

All participants underwent visual field testing every six months using the 24–2 strategy on the Humphrey Field Analyzer II with the Swedish Interactive Thresholding Algorithm (SITA) standard, 33 version 4.1 (Carl Zeiss Meditec, Inc, Dublin, California). Starting in 2013, given growing evidence of the importance of early macular damage in glaucoma, all participants were also tested with the 10–2 pattern at the same frequency as 24–2 tests, that is, every six months.<sup>10</sup> Any unreliable test (as defined above) was excluded. Only 24–2 and 10–2 tests done on the same day were included in the analyses; therefore, all eyes had the same number of 24–2 and 10–2 tests, all equally spaced, and during the same time period. Testing order (administration of the 24–2 or 10–2 test first) was randomized at the patient level.

The number of abnormal test locations within the central 10 degrees of the 24–2 and in the 10–2 patterns were assessed. For the central 10 degrees of the 24–2 (i.e., the 12 central-most test locations), abnormality was defined at  $P < 5\%$  of the pattern deviation (PD) plot, as this area matches the macular region tested with the 10–2.<sup>10</sup> For the 10–2, abnormal locations were also defined at  $P < 5\%$  of the PD plot. Visual field progression was quantified for three different outcome variables, (i) 24–2 mean total deviation (MTD), which is the average of total deviation (TD) values of all 52 locations (54 minus the points above and below the blind spot); (ii) 24–2 central MTD, which is the average of TD values of the 12 central-most locations, and (iii) 10–2 MTD, which is the average of total deviation (TD) of all 68 locations. The 12 central points included in the 24–2 central MTD analysis are demonstrated in Figure 1.

Because 10–2 tests were included as part of ADAGES protocol after 2013, only the 24–2 tests performed thereafter were included in the present study. Had we included the 24–2 tests done before (without accompanying 10–2), the number of tests would not be balanced, potentially biasing the comparison between the two test patterns. Given the progressive nature of glaucomatous visual field damage, to optimize the detection of visual field abnormalities the cross-sectional analysis was based on the last (most recent) follow-up visit, when both 24–2 and 10–2 were performed. For the longitudinal analysis, we included eyes with at least five visits with both test patterns and included a similar number of 10–2 and 24–2 visual field tests for each eye.

### Statistical analyses

Categorical variables were described by their percentages and compared using Fisher's exact test. Continuous variables were described by their means and standard deviations (SD) and compared with Mann–Whitney two-sample statistic. For the cross-sectional analysis, Poisson mixed effects regression models were used to calculate the incident rate ratio (IRR)

of central visual field damage where the predictor was the presence of DH and the outcome the number of abnormal test locations as defined above. In the longitudinal analysis, linear mixed effects models were used to test the difference in rates of abnormal test locations over time and MTD change over time (dB/year), respectively, between DH and non-DH eyes. This type of model adjusts for inter-eye correlation as well as the correlation between residuals in longitudinal data. Computerized statistical analyses were performed using commercially available software (STATA, version 14.0; StataCorp LP, College Station, TX). Statistical significance was defined at  $P < 0.05$ .

## RESULTS

### Cross-sectional analysis

335 eyes of 215 participants were included in the cross-sectional analysis. 145 (43.2%, 95% binomial confidence interval: 37.9% to 48.7%) were of African descent, and their mean (95% confidence interval of the mean) age was 68.8 (67.6 to 70.0) years. Baseline demographic characteristics of the study population are detailed in Table 1. Mean 24–2 and 10–2 MTD at the last visit were  $-5.0$  ( $-5.7$  to  $-4.3$ ) and  $-4.5$  ( $-5.1$  to  $-3.8$ ) dB, respectively. DH was detected in 21/335 eyes (6.2%; 3.9 to 9.4%) and was more common in eyes of participants of European descent (17/190, 8.9%; 5.3 to 13.9%) than African descent (4/145, 2.7%; 0.7 to 6.9%;  $P = 0.023$ , Fisher's exact test). 17 of the 21 (81%; 58.0 to 94.5%) eyes with DH had an inferotemporal DH, 2 DHs were inferonasal, 1 nasal, and 4 superotemporal (note: 3 eyes had concurrent superotemporal and inferotemporal DH).

DH eyes had more abnormal test points within the central 10 degrees of 24–2 visual fields from the last follow-up visit than non-DH eyes (Poisson's incidence rate ratio, IRR= 1.42;  $P = 0.032$ ). A similar relationship was seen when looking at the matching 10–2 fields (IRR= 1.67; 95% CI= 1.42 to 1.98;  $P < 0.001$ ).

### Longitudinal analysis

In the longitudinal analysis, 20/306 eyes (6.5%; 4.0 to 9.9%) had at least one DH, 16 of which were observed in the inferotemporal sector. Their mean (SD) age was 59.8 (58.6 to 61.1) years and mean 24–2 and 10–2 MTD at the baseline visit were  $-4.5$  ( $-5.2$  to  $-3.8$ ) and  $-3.8$  ( $-4.5$  to  $-3.2$ ) dB, respectively.

Over the follow-up period [mean of 7 (6.9 to 7.2) visits spanning 9 (8.9 to 9.1) years], DH eyes experienced more rapid global 24–2 progression than non-DH eyes (difference in slopes,  $\beta = -0.06$ ;  $P = 0.009$ ). However, a significant difference was not seen on the 24–2 central MTD (difference in slopes,  $\beta = -0.02$ ;  $P = 0.338$ ). With the 10–2, DH eyes experienced more rapid MTD progression than non-DH eyes (difference in slopes,  $\beta = -0.10$ ;  $P < 0.001$ ). Tables 2–4 detail the linear mixed effects models describing the relationship between disc hemorrhage and rates of progression of 24–2 MTD, 24–2 central MTD, and 10–2 central MTD, respectively.

Figure 2 shows the distribution of mean TD values at baseline from 24–2 (upper panel) and 10–2 (lower panel) fields of all eyes with detected DH. Note that in both tests, areas in the superior arcuate region had worse sensitivities, which match the location of most detected

DH (inferotemporal). Interestingly, while severe damage was noted within 10 degrees of fixation, damage did not clearly affect fixation.

## DISCUSSION

The current study was undertaken to better understand the relationship between DH and central visual field damage in eyes with glaucomatous optic neuropathy. We found that DH was significantly associated with the presence and progression of central visual field damage. Because macular damage is associated with poorer vision-related quality of life,<sup>20–22</sup> our study underscores the importance of monitoring the central field in DH eyes.

Based on data simulation, Wu et al<sup>16</sup> recently suggested that 10–2 visual fields could detect significant progression 6 months sooner than the 24–2 central MTD in eyes progressing at an average rate of –0.5 dB/year (which includes the majority of glaucomatous eyes<sup>23</sup>). Our findings in a real-world population are consistent with their simulations given that – for a matched follow-up time and number of tests – 10–2 fields detected differences in rates of progression between DH and non-DH. This difference in progression rate among DH and non-DH eyes was not reflected in central 24–2 MTD but was seen in the global 24–2 VF.

Little is known about the pathogenic mechanisms of DH. Vascular dysregulation seen in primary open-angle glaucoma,<sup>24,25</sup> and a vascular event such as ischemia to the optic nerve head or damage to the blood-retinal barrier may lead to an arterial or venous spasm or occlusion.<sup>26</sup> In accordance with this, Kwon et al found that non-physiologic drops in nocturnal blood pressure were a significant risk factor for the development of DH.<sup>25</sup> In another study, Kwon et al reported that eyes with parapapillary deep-layer microvasculature dropout detected by OCT angiography – which is correlated with DH presence<sup>27</sup> – had a significantly more rapid rate of visual field progression than eyes without dropout<sup>28</sup>. Additionally, a study by Chou et al found that fundus densitometry profiles of DH resemble microaneurysms rather than retinal venous occlusions, suggesting that DH have an arterial origin. Deeper vasculature may be relevant to the development of DH, as regional microvasculature dropout in the deep parapapillary layer of the choroid around the optic nerve head has been more frequently found in eyes with recurrent DH at the same site as previous DH.<sup>29</sup>

A mechanical theory proposes that DH may be a result of changes in the morphology of the lamina cribrosa resulting in shearing of laminar capillaries and retinal ganglion cell axons as a result of structural loss.<sup>4,30</sup> The matrix of collagenous beams that forms the lamina cribrosa acts as the load-bearing structural support for the optic nerve head and is hypothesized to be the primary site of retinal ganglion cell axonal glaucomatous damage.<sup>31–33</sup> Mechanical alteration of the lamina cribrosa at its scleral insertion point occurs with changes in intraocular pressure or translaminal pressure gradients and may cause damage indicated by DH.<sup>34–36</sup> Visualization of lamina cribrosa defects by swept source optical coherence tomography demonstrates a significant association with DH.<sup>37</sup> Finally, in agreement with the present report, Sharpe et al found that most DH and laminar disinsertion were located in the inferotemporal and superotemporal sectors.<sup>38</sup> More recently, Moghimi et al reported that lamina cribrosa defects are an independent risk factor for structural

progression, which was spatially-consistent with the defect location<sup>39</sup> and confirmed the findings of a previous retrospective study.<sup>40</sup> Disc hemorrhages,<sup>4,6</sup> microvascular dropout,<sup>28,29</sup> and lamina cribrosa defects<sup>39,40</sup> tend to occur in the same location (inferotemporal peripapillary region) and could, therefore, represent different clinical manifestations of the same underlying mechanism associated with rapid, local glaucomatous progression.

Glaucomatous damage to the macula may occur in both early and late stages of disease<sup>10–16,17</sup>. Thus, it appears that the presence of central visual field damage, irrespective of severity of the global visual field damage, may have significant implications on disease staging.<sup>41</sup> In addition, our previous work has demonstrated that the presence of central visual field damage is predictive of global visual field progression independent of baseline 24–2 mean deviation.<sup>42</sup> Importantly, central visual field damage has been associated with poor vision-related quality of life outcomes even in early glaucoma.<sup>43</sup> Our study confirms numerous previous reports that showed more rapid 24–2 progression in DH vs non-DH eyes. The inferotemporal optic nerve region receives axons from the macular vulnerability zone<sup>10</sup> as well as areas outside the macular region;<sup>19</sup> typically, damage to these fibers leads to paracentral visual field defects or nasal steps.<sup>10</sup> Therefore, the 24–2 grid can detect damage outside the central 10 degrees, which would be missed with the 10–2. Nonetheless, the 12 central-most points of the 24–2 do not sample the macular region as densely as the 10–2 (with 68 points for the same area) which may explain why the central MTD failed to reveal a significant association with progression in our sample. Similar knowledge has long been used to justify the use of 10–2 fields to track progression in eyes with severe damage on the 24–2 in clinical practice. As shown in Figure 2, the 12 central-most points were significantly depressed at baseline, thus making it more difficult to measure progressive changes beyond that level. With more tested locations within the same area (10–2 grid), progressive changes may be more easily identified.

Strengths of the present report include its large number of participants and prospective design. Potential limitations of our study are related to the availability of photographs. For instance, optic disc stereophotographs were taken annually and therefore, the number of DHs identified in this study is likely lower than the true number of DH that occurred in the study population, as DH may have occurred in the time between photos. Notably, in the Early Manifest Glaucoma Trial (EMGT), stereophotographs were taken every three months<sup>6</sup> and in the Collaborative Normal Tension Glaucoma Study (CNTGS) optic nerves were photographed every three to six months.<sup>44,45</sup> These studies found a significantly higher incidence of DH than other studies with less frequent photos.<sup>3,44,45</sup> Because of the relatively small number of DH detected in this study (~6% of the eyes), we were unable to perform sub-analyses based on the location of hemorrhages (e.g.: inferotemporal versus other regions) due to small sample sizes in each group, which decreased the statistical power of our analyses. Future studies with larger number of DH in each optic disc sector should investigate their relationship with central field damage. Finally, since this was not a randomized controlled trial, the observation of a DH may have led to the addition of further IOP-lowering therapy. This may have potentially prevented further VF progression. As such, the impact of DH on progression rates may be larger than detected in this study.



Considering the increased prevalence of central as well as peripheral visual field damage in patients with DH, clinicians should carefully scrutinize the central visual field in any patient with DH, preferably with testing such as 10–2 fields. Heightened awareness of the implications of DH will allow for risk stratification of patients who may require escalation of treatment to prevent rapid central visual field progression.

## Acknowledgments

### a. Funding / Support:

Funding for this work was contributed by the National Eye Institute Grants U10EY14267 (LMZ), EY08208 (LMZ), EY11008 (LMZ), EY019869 (LMZ), EY027510 (LMZ), EY13959 (CAG), EY025253 (CGDM), Bethesda, MD; Eyesight Foundation of Alabama, Birmingham, AL; Alcon Laboratories Inc., Fort Worth, TX; Allergan Inc., Dublin, Ireland; Pfizer Inc., New York, NY; Merck Inc., Rahway, NJ; Santen Inc., Osaka, Japan; unrestricted departmental grant from Research to Prevent Blindness, New York, NY (Department of Ophthalmology, Columbia University Medical Center and Department of Ophthalmology, University of California San Diego), Edith C. Blum Foundation, New York, NY.

### b. Financial disclosures:

**A.G.S.:** No financial disclosures.

**C.G.D.M.:** No financial disclosures.

**D.M.B.:** No financial disclosures.

**G.A.C.:** No financial disclosures.

**A.S.:** No financial disclosures.

**C.A.G.:** Research support: Heidelberg Engineering GmbH, Heidelberg, Germany.

**R.N.W.:** Financial support: Carl Zeiss Meditec Inc., Jena, Germany; Heidelberg Engineering GmbH, Heidelberg, Germany; Optovue Inc., Fremont, CA; Topcon Medical Systems, Tokyo, Japan. Grants: Quark Pharmaceuticals, Inc., Ness Ziona, Israel; Genentech - San Francisco, CA. Consultant: Aerie Pharmaceuticals, Pittsburgh, PA; Alcon Laboratories Inc., Fort Worth, TX; Allergan Inc, Dublin, Ireland; Bausch & Lomb, Garden City, NY.

**L.M.Z.:** Research support: Carl Zeiss Meditec Inc., Jena, Germany; Heidelberg Engineering GmbH, Heidelberg, Germany; Optovue Inc., Fremont, CA; Topcon Medical Systems Inc., Tokyo, Japan

**D.C.H.:** Financial support: Topcon, Inc., Tokyo, Japan; Heidelberg Engineering GmbH, Heidelberg, Germany. Consultant: Topcon, Inc., Tokyo, Japan; Heidelberg Engineering GmbH, Heidelberg, Germany.

**J.M.L.:** Consultant: Sensimed, Inc., Lausanne, Switzerland; Carl Zeiss Meditec, Jena, Germany, Inc.; Alcon Laboratories, Fort Worth, TX; Topcon, Inc., Tokyo, Japan; Heidelberg Engineering GmbH, Heidelberg, Germany; Allergan, Inc., Dublin, Ireland; Bausch & Lomb, Inc, Garden City, NY; Aerie Pharmaceuticals, Inc., Pittsburgh, PA; Quark Pharmaceuticals, Inc., Ness Ziona, Israel.

### c. Other acknowledgments: None.

## REFERENCES

1. Healey PR, Mitchell P, Smith W, Wang JJ. Optic disc hemorrhages in a population with and without signs of glaucoma. *Ophthalmology*. 1998;105(2):216–223. [PubMed: 9479278]
2. Jonas JB, Xu L. Optic disk hemorrhages in glaucoma. *Am J Ophthalmol*. 1994;118(1):1–8. [PubMed: 8023857]
3. Bengtsson B, Leske MC, Yang Z, Heijl A, Group E. Disc hemorrhages and treatment in the early manifest glaucoma trial. *Ophthalmology*. 2008;115(11):2044–2048. [PubMed: 18692244]
4. De Moraes CG, Prata TS, Liebmann CA, Tello C, Ritch R, Liebmann JM. Spatially consistent, localized visual field loss before and after disc hemorrhage. *Invest Ophthalmol Vis Sci*. 2009;50(10):4727–4733. [PubMed: 19458330]

5. Siegner SW, Netland PA. Optic disc hemorrhages and progression of glaucoma. *Ophthalmology*. 1996;103(7):1014–1024. [PubMed: 8684789]
6. Diehl DL, Quigley HA, Miller NR, Sommer A, Burney EN. Prevalence and significance of optic disc hemorrhage in a longitudinal study of glaucoma. *Arch Ophthalmol*. 1990;108(4):545–550. [PubMed: 2322157]
7. Uhler TA, Piltz-Seymour J. Optic disc hemorrhages in glaucoma and ocular hypertension: implications and recommendations. *Curr Opin Ophthalmol*. 2008;19(2):89–94. [PubMed: 18301280]
8. Chung E, Demetriades AM, Christos PJ, Radcliffe NM. Structural glaucomatous progression before and after occurrence of an optic disc haemorrhage. *Br J Ophthalmol*. 2015;99(1):21–25. [PubMed: 25057184]
9. Kim JM, Kyung H, Azarbod P, Lee JM, Caprioli J. Disc haemorrhage is associated with the fast component, but not the slow component, of visual field decay rate in glaucoma. *Br J Ophthalmol*. 2014;98(11):1555–1559. [PubMed: 24990873]
10. Hood DC, Raza AS, de Moraes CG, Liebmann JM, Ritch R. Glaucomatous damage of the macula. *Prog Retin Eye Res*. 2013;32:1–21. [PubMed: 22995953]
11. Hood DC, Slobodnick A, Raza AS, de Moraes CG, Teng CC, Ritch R. Early glaucoma involves both deep local, and shallow widespread, retinal nerve fiber damage of the macular region. *Invest Ophthalmol Vis Sci*. 2014;55(2):632–649. [PubMed: 24370831]
12. Hood DC, Raza AS, de Moraes CG, et al. Initial arcuate defects within the central 10 degrees in glaucoma. *Invest Ophthalmol Vis Sci*. 2011;52(2):940–946. [PubMed: 20881293]
13. Sullivan-Mee M, Karin Tran MT, Pensyl D, Tsan G, Katiyar S. Prevalence, Features, and Severity of Glaucomatous Visual Field Loss Measured With the 10–2 Achromatic Threshold Visual Field Test. *Am J Ophthalmol*. 2016;168:40–51. [PubMed: 27173372]
14. Park HY, Hwang BE, Shin HY, Park CK. Clinical Clues to Predict the Presence of Parafoveal Scotoma on Humphrey 10–2 Visual Field Using a Humphrey 24–2 Visual Field. *Am J Ophthalmol*. 2016;161:150–159. [PubMed: 26476213]
15. Roberti G, Manni G, Riva I, et al. Detection of central visual field defects in early glaucomatous eyes: Comparison of Humphrey and Octopus perimetry. *PLoS one*. 2017;12(10):e0186793. [PubMed: 29077730]
16. Wu Z, Medeiros FA, Weinreb RN, Girkin CA, Zangwill LM. Comparing 10–2 and 24–2 Visual Fields for Detecting Progressive Central Visual Loss in Glaucoma Eyes with Early Central Abnormalities. *Ophthalmology Glaucoma*. 2019.
17. Park SC, De Moraes CG, Teng CC, Tello C, Liebmann JM, Ritch R. Initial parafoveal versus peripheral scotomas in glaucoma: risk factors and visual field characteristics. *Ophthalmology*. 2011;118(9):1782–1789. [PubMed: 21665283]
18. Sample PA, Girkin CA, Zangwill LM, et al. The African Descent and Glaucoma Evaluation Study (ADAGES): design and baseline data. *Arch Ophthalmol*. 2009;127(9):1136–1145. [PubMed: 19752422]
19. Garway-Heath DF, Poinosawmy D, Fitzke FW, Hitchings RA. Mapping the visual field to the optic disc in normal tension glaucoma eyes. *Ophthalmology*. 2000;107(10):1809–1815. [PubMed: 11013178]
20. Garg A, Hood DC, Pensec N, Liebmann JM, Blumberg DM. Macular Damage, as Determined by Structure-Function Staging, Is Associated With Worse Vision-related Quality of Life in Early Glaucoma. *Am J Ophthalmol*. 2018;194:88–94. [PubMed: 30053467]
21. Blumberg DM, De Moraes CG, Prager AJ, et al. Association Between Undetected 10–2 Visual Field Damage and Vision-Related Quality of Life in Patients With Glaucoma. *JAMA Ophthalmol*. 2017;135(7):742–747. [PubMed: 28542692]
22. Abe RY, Diniz-Filho A, Costa VP, Gracitelli CP, Baig S, Medeiros FA. The Impact of Location of Progressive Visual Field Loss on Longitudinal Changes in Quality of Life of Patients with Glaucoma. *Ophthalmology*. 2016;123(3):552–557. [PubMed: 26704883]
23. Anderson AJ. Comparison of Three Parametric Models for Glaucomatous Visual Field Progression Rate Distributions. *Translational vision science & technology*. 2015;4(4):2.

24. Kwon J, Lee J, Choi J, Jeong D, Kook MS. Association Between Nocturnal Blood Pressure Dips and Optic Disc Hemorrhage in Patients With Normal-Tension Glaucoma. *Am J Ophthalmol.* 2017;176:87–101. [PubMed: 28088510]
25. Chou JC, Cousins CC, Miller JB, et al. Fundus Densitometry Findings Suggest Optic Disc Hemorrhages in Primary Open-Angle Glaucoma Have an Arterial Origin. *Am J Ophthalmol.* 2018;187:108–116. [PubMed: 29330062]
26. Grieshaber MC, Terhorst T, Flammer J. The pathogenesis of optic disc splinter haemorrhages: a new hypothesis. *Acta Ophthalmol Scand.* 2006;84(1):62–68. [PubMed: 16445441]
27. Rao HL, Sreenivasaiiah S, Dixit S, et al. Choroidal Microvascular Dropout in Primary Open-angle Glaucoma Eyes with Disc Hemorrhage. *Journal of glaucoma.* 2018.
28. Kwon JM, Suh MH, Weinreb RN, Zangwill LM. Parapapillary Deep-Layer Microvasculature Dropout and Visual Field Progression in Glaucoma. *Am J Ophthalmol.* 2018.
29. Park HL, Kim JW, Park CK. Choroidal Microvasculature Dropout Is Associated with Progressive Retinal Nerve Fiber Layer Thinning in Glaucoma with Disc Hemorrhage. *Ophthalmology.* 2018;125(7):1003–1013. [PubMed: 29486903]
30. Lee EJ, Han JC, Kee C. A novel hypothesis for the pathogenesis of glaucomatous disc hemorrhage. *Prog Retin Eye Res.* 2017;60:20–43. [PubMed: 28864288]
31. Quigley HA, Addicks EM, Green WR. Optic nerve damage in human glaucoma. III. Quantitative correlation of nerve fiber loss and visual field defect in glaucoma, ischemic neuropathy, papilledema, and toxic neuropathy. *Arch Ophthalmol.* 1982;100(1):135–146. [PubMed: 7055464]
32. Anderson DR, Hendrickson A. Effect of intraocular pressure on rapid axoplasmic transport in monkey optic nerve. *Invest Ophthalmol.* 1974;13(10):771–783. [PubMed: 4137635]
33. Downs JC. Optic nerve head biomechanics in aging and disease. *Exp Eye Res.* 2015;133:19–29. [PubMed: 25819451]
34. Quigley H, Arora K, Idrees S, et al. Biomechanical Responses of Lamina Cribrosa to Intraocular Pressure Change Assessed by Optical Coherence Tomography in Glaucoma Eyes. *Invest Ophthalmol Vis Sci.* 2017;58(5):2566–2577. [PubMed: 28494490]
35. Burgoyne CF. A biomechanical paradigm for axonal insult within the optic nerve head in aging and glaucoma. *Exp Eye Res.* 2011;93(2):120–132. [PubMed: 20849846]
36. Burgoyne CF, Downs JC, Bellezza AJ, Suh JK, Hart RT. The optic nerve head as a biomechanical structure: a new paradigm for understanding the role of IOP-related stress and strain in the pathophysiology of glaucomatous optic nerve head damage. *Prog Retin Eye Res.* 2005;24(1):39–73. [PubMed: 1555526]
37. Takayama K, Hangai M, Kimura Y, et al. Three-dimensional imaging of lamina cribrosa defects in glaucoma using swept-source optical coherence tomography. *Invest Ophthalmol Vis Sci.* 2013;54(7):4798–4807. [PubMed: 23778878]
38. Sharpe GP, Danthurebandara VM, Vianna JR, et al. Optic Disc Hemorrhages and Lamellar Disinsertions in Glaucoma. *Ophthalmology.* 2016;123(9):1949–1956. [PubMed: 27432205]
39. Moghimi S, Zangwill LM, Manalastas PIC, et al. Association Between Lamina Cribrosa Defects and Progressive Retinal Nerve Fiber Layer Loss in Glaucoma. *JAMA Ophthalmol.* 2019.
40. Faridi OS, Park SC, Kabadi R, et al. Effect of focal lamina cribrosa defect on glaucomatous visual field progression. *Ophthalmology.* 2014;121(8):1524–1530. [PubMed: 24697910]
41. De Moraes CG, Sun A, Jarukasetphon R, et al. Association of Macular Visual Field Measurements With Glaucoma Staging Systems. *JAMA Ophthalmol.* 2018.
42. Garg A, De Moraes CG, Cioffi GA, et al. Baseline 24–2 Central Visual Field Damage Is Predictive of Global Progressive Field Loss. *Am J Ophthalmol.* 2018;187:92–98. [PubMed: 29317211]
43. Garg A, Hood DC, Pensec N, Liebmann JM, Blumberg DM. Macular Damage, as Determined by Structure-Function Staging, is Associated with Worse Vision-Related Quality of Life in Early Glaucoma. *Am J Ophthalmol.* 2018.
44. Drance S, Anderson DR, Schulzer M, Collaborative Normal-Tension Glaucoma Study G. Risk factors for progression of visual field abnormalities in normal-tension glaucoma. *Am J Ophthalmol.* 2001;131(6):699–708. [PubMed: 11384564]

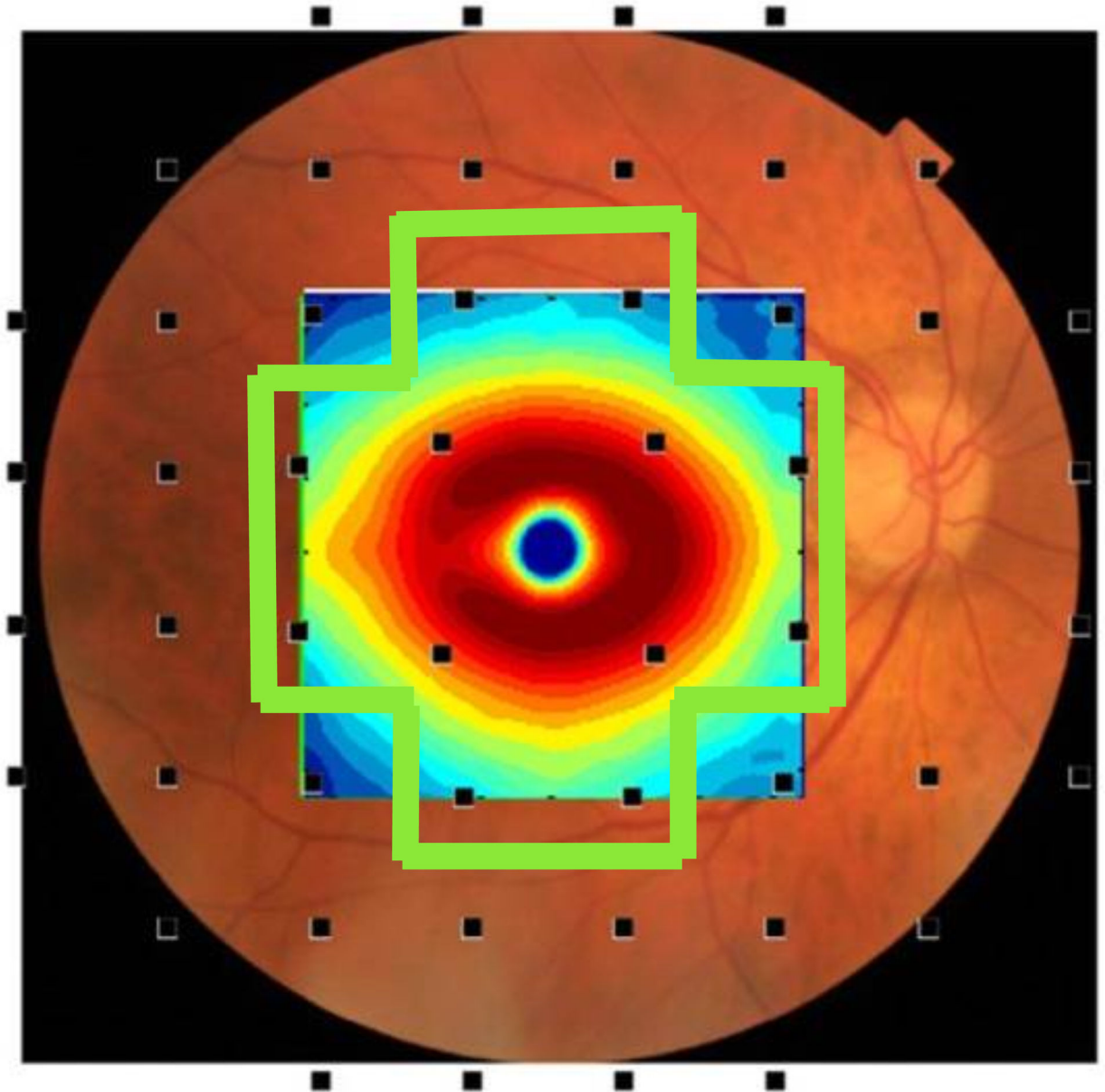
45. Comparison of glaucomatous progression between untreated patients with normal-tension glaucoma and patients with therapeutically reduced intraocular pressures. Collaborative Normal-Tension Glaucoma Study Group. *Am J Ophthalmol.* 1998;126(4):487–497. [PubMed: 9780093]

Author Manuscript

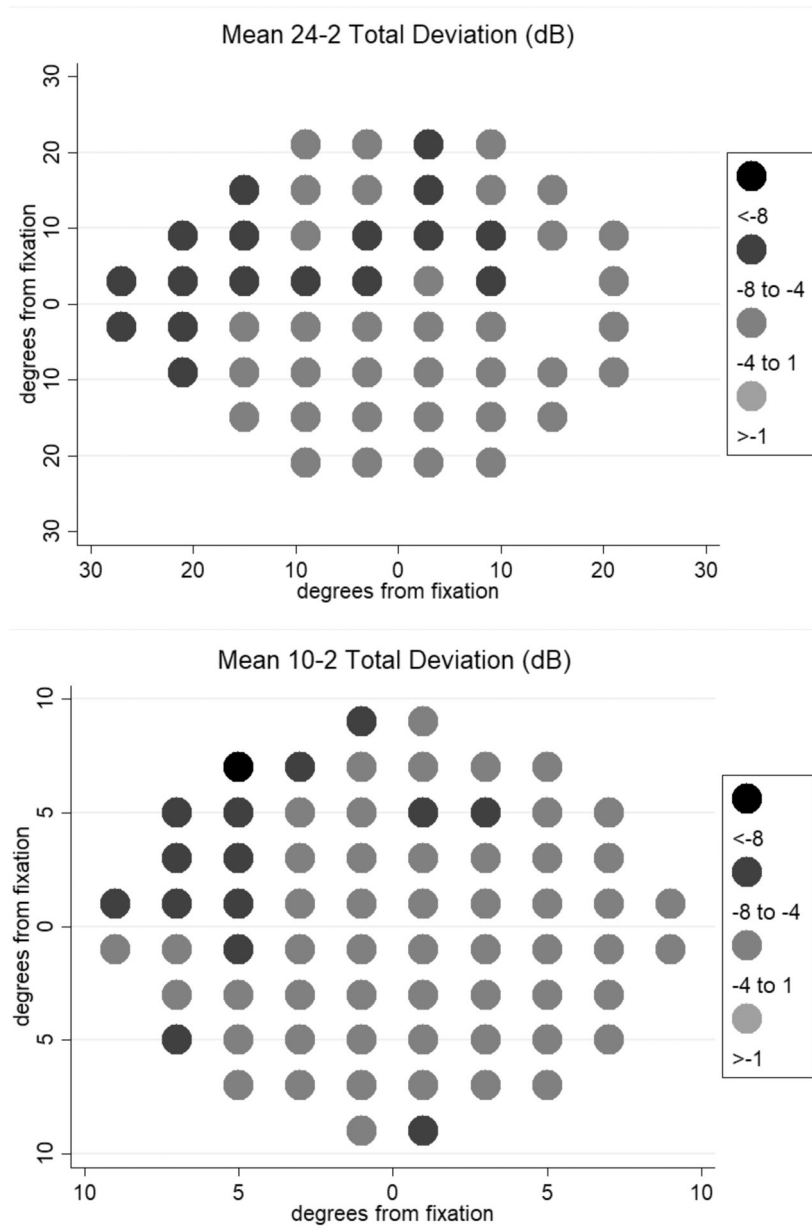
Author Manuscript

Author Manuscript

Author Manuscript



**Figure 1:** Map of the 24–2 test points and their spatial relationship to corresponding points on the retina. The points in the green box were included in the 24–2 central mean sensitivity deviation analysis. Modified from Hood et al.<sup>10</sup>



**Figure 2:** Mean baseline total deviation values (in dB) on the 24–2 and 10–2 of eyes experiencing disc hemorrhage. Upper panel 24–2; lower panel 10–2. Projections are in right eye view.

**Table 1.**

Demographic characteristics of the larger study population (N=335 eyes).

	<b>DH (n=21)</b>	<b>Non-DH (n=314)</b>	<b>P-value</b>
<b>Age (years)</b>	75.5 (9.3)	68.4 (11.2)	0.002
<b>Sex (Female/Male)</b>	10/11	176/138	0.501
<b>Race (African/European)</b>	4/17	141/173	0.023
<b>Spherical equivalent (D)</b>	-0.00 (1.5)	-0.58 (1.8)	0.382
<b>CCT (microns)</b>	531.2 (48.4)	541.4 (37.5)	0.170
<b>IOP (mmHg)</b>	14.6 (2.1)	15.3 (3.3)	0.186
<b>24-2 MD (dB)</b>	-5.7 (5.4)	-4.9 (6.2)	0.155
<b>10-2 MD (dB)</b>	-7.0 (6.3)	-4.3 (5.7)	0.032

Abbreviations: DH= disc hemorrhage; D= diopters; CCT= central corneal thickness; IOP= intraocular pressure; MD= mean deviation; dB= decibels

**Table 2.**

Linear mixed effects model testing the relationship between disc hemorrhage and rates of 24–2 mean sensitivity deviation progression.

24–2 MTD (dB)	Coef.	95% Conf. Interval		P-value
<b>DH (yes)</b>	–0.445	–3.021	2.129	0.734
<b>Time (years)</b>	–0.029	–0.0426	–0.017	<0.001
<b>DH X Time</b>	–0.063	–0.111	–0.015	0.009

Abbreviations: DH= disc hemorrhage; MTD= mean total deviation

Author Manuscript

Author Manuscript

Author Manuscript

Author Manuscript



**Table 3.**

Linear mixed effects model testing the relationship between disc hemorrhage and rates of 24–2 central mean sensitivity deviation progression.

24–2 Central MTD (dB)	Coef.	95% Conf. Interval	P-value
DH (yes)	-1.531	-3.958 0.895	0.216
Time (years)	-0.027	-0.0416 -0.0137	<0.001
DH X Time	-0.025	-0.078 0.026	0.338

Abbreviations: DH= disc hemorrhage; MTD= mean total deviation

Author Manuscript

Author Manuscript

Author Manuscript

Author Manuscript

**Table 4.**

Linear mixed effects model testing the relationship between disc hemorrhage and rates of 10–2 central mean sensitivity deviation progression.

10–2 MTD (dB)	Coef.	95% Conf. Interval	P-value
<b>DH (yes)</b>	–2.033	–4.345 0.278	0.085
<b>Time (years)</b>	–0.036	–0.055 –0.018	<0.001
<b>DH X Time</b>	–0.105	–0.170 –0.040	0.001

Abbreviations: DH= disc hemorrhage; MTD= mean sensitivity deviation

Author Manuscript

Author Manuscript

Author Manuscript

Author Manuscript