

# Diagnostic Ability of Optical Coherence Tomography Angiography Macula Vessel Density for the Diagnosis of Glaucoma Using Difference Scan Sizes

Rafaella C. Penteadó, MD,\*† Christopher Bowd, PhD,\*  
James A. Proudfoot, MSc,\* Sasan Moghimi, MD,\*  
Patricia I.C. Manalastas, MD,\* Elham Ghahari, MD,\*  
Huiyuan Hou, MD, PhD,\* Takuhei Shoji, MD, PhD,\*‡  
Linda M. Zangwill, PhD,\* and Robert N. Weinreb, MD\*

**Précis:** There is diagnostic information in the outer region of optical coherence tomography angiography (OCT-A) macula scans not available in the inner region, and this information is especially useful in the early stages of glaucoma.

**Purpose:** The aim of this study was to evaluate the diagnostic accuracy of 3×3 and 6×6 mm<sup>2</sup> macula OCT-A scans for classifying healthy, mild glaucoma, and moderate to severe glaucoma eyes.

**Methods:** Participants enrolled in the Diagnostic Innovations in Glaucoma Study (DIGS) with good quality 3×3 and 6×6 mm<sup>2</sup> OCT-A images of the macula acquired on the same day were included in this cross-sectional study. The area under the receiver operating characteristic (AUC) curves were calculated to assess the diagnostic accuracy of vessel density (VD) of both scan sizes for differentiating between 3 diagnostic groups.

**Results:** Two hundred seventy-nine eyes (89 healthy, 127 with mild glaucoma, and 63 with moderate to severe glaucoma) from 190 subjects were included in this study. The VD of the outer area of the 6×6 mm<sup>2</sup> scan size had higher diagnostic accuracy compared with the VD of the inner area of the 3×3 mm<sup>2</sup> scan when differentiating between healthy and mild glaucoma (3×3 mm<sup>2</sup> AUC=0.71 and 6×6 mm<sup>2</sup> AUC=0.79,  $P=0.032$ ). The VD of the outer area of the 6×6 mm<sup>2</sup> scans had only similar diagnostic accuracy compared with the inner area of the 3×3 mm<sup>2</sup>

scan when differentiating between healthy and moderate to severe glaucoma eyes (AUC=0.90 for 3×3 mm<sup>2</sup> and 0.92 for 6×6 mm<sup>2</sup>,  $P=0.279$ ). The VD of the inner area of the 6×6 mm<sup>2</sup> scan size had similar diagnostic accuracy to the corresponding area of the 3×3 mm<sup>2</sup> scan in both diagnostic categories.

**Conclusion:** The diagnostic accuracy of VD using the 6×6 mm<sup>2</sup> macula OCT-A scan was better than the 3×3 mm<sup>2</sup> scan when differentiating between healthy and mild glaucoma eyes, and similar to the 3×3 mm<sup>2</sup> scan when differentiating between healthy and moderate to severe glaucoma eyes.

**Key Words:** optical coherence tomography angiography, glaucoma, macula, vessel density, scan size

(*J Glaucoma* 2020;29:245–251)

Glaucoma is characterized by progressive degeneration of retinal ganglion cells and their axons, leading to structural damage to the optic nerve head and inner retina that is accompanied by the irreversible loss of vision.<sup>1</sup> Approximately half of these retinal ganglion cells are located within 4.5 mm of the center of the fovea. This area, particularly the inferior region known as the macula vulnerability zone, is susceptible to damage beginning in early disease.<sup>2–10</sup> Although the pathogenesis of glaucoma remains unclear, it has been suggested that changes in the ocular microcirculation, either primarily or secondarily due to increased intraocular pressure (IOP), contribute to disease development and progression.<sup>11–13</sup>

Optical coherence tomography angiography (OCT-A) is an imaging modality that provides noninvasive visualization of the retinal vascular network.<sup>14</sup> This technology has been used to investigate the diagnostic ability of vessel density (VD) measurements in glaucoma. It has been reported that optic nerve head VD and retinal nerve fiber layer (RNFL) thickness measurements perform similarly at classifying healthy and glaucoma eyes.<sup>15</sup> Another study suggested that peripapillary VD was superior to the macula and inside disc vessel densities at classifying healthy and glaucomatous eyes.<sup>16</sup> The latter study used 3×3 mm<sup>2</sup> macula scans and we hypothesize that a larger macula scan could improve classification performance because it may detect VD differences in the macula vulnerability zone, an area susceptible to early glaucoma damage, that is located > 5 degrees away from the center of the fovea.<sup>4</sup>

The goal of the current study was to compare the diagnostic accuracy of 3×3 and 6×6 mm<sup>2</sup> macula OCT-A scans in healthy and glaucoma eyes to determine if the

Received for publication September 4, 2019; accepted January 1, 2020.

From the \*Viterbi Family Department of Ophthalmology, Hamilton Glaucoma Center, Shiley Eye Institute, University of California San Diego, La Jolla, CA; †Department of Ophthalmology, University of Sao Paulo, Sao Paulo, Brazil; and ‡Department of Ophthalmology, Saitama Medical University, Saitama, Japan.

National Institutes of Health/National Eye Institute Grants R01EY029058, R01EY011008, R01 EY14267, and R01 EY027510, Core Grant P30EY022589, an unrestricted grant from Research to Prevent Blindness (New York, NY), and grants for participants' glaucoma medications from Alcon, Allergan, Pfizer, Merck, and Santen.

Disclosure: T.S.: Recipient: Pfizer, Senju, Alcon, Santen, Kowa, Otsuka. L.M.Z.: Financial Support: National Eye Institute, Carl Zeiss Meditec Inc., Heidelberg Engineering GmbH, Optovue Inc., Topcon Medical Systems Inc. Recipient: Heidelberg Engineering. R.N.W.: Consultant: Aerie Pharmaceuticals, Allergan, Eyeovia, Implantdata; Financial Support: Heidelberg Engineering, Carl Zeiss Meditec, Konan, Optovue, Centervue, Bausch&Lomb; Patent: Toromedes, Carl Zeiss Meditec. The remaining authors declare no conflict of interest.

Reprints: Robert N. Weinreb, MD, Viterbi Family Department of Ophthalmology, Hamilton Glaucoma Center, Shiley Eye Institute, University of California San Diego, 9415 Campus Point Drive La Jolla, CA 92037 (e-mail: rweinreb@health.ucsd.edu).

Supplemental Digital Content is available for this article. Direct URL citations appear in the printed text and are provided in the HTML and PDF versions of this article on the journal's website, www.glaucomajournal.com.

Copyright © 2020 Wolters Kluwer Health, Inc. All rights reserved.

DOI: 10.1097/JG.0000000000001447

larger scan size improves on the smaller scan size for differentiating healthy eyes from mild and moderate to severe glaucomatous eyes.

## METHODS

Participants enrolled in the Diagnostic Innovations in Glaucoma Study (DIGS<sup>17</sup>) who underwent both 3×3 and 6×6 mm<sup>2</sup> macula OCT-A (Angiovue; Optovue Inc., Fremont, CA) imaging at the same visit were included in this cross-sectional study. All research adhered to the tenets of the Declaration of Helsinki was approved by the Institutional Review Board at the University of California San Diego and was the Health Insurance Portability and Accountability Act (HIPAA) compliant. Written informed consent was obtained from all participants.

### Participants

Participants' eyes were classified as healthy, mild glaucoma or moderate to severe glaucoma groups. Healthy subjects were defined as having an IOP of 21 mm Hg or lower without history of elevated IOP; normal-appearing optic discs, neuroretinal rims, and retinal nerve fiber layer; and normal Humphrey Field Analyzer SITA standard 24-2 visual field test results, defined as pattern standard deviation within the 95% confidence limits and Glaucoma Hemifield Test results within normal limits in both eyes.

Glaucoma was defined as the presence of at least 2 repeatable and reliable ( $\leq 33\%$  fixation losses and false-negatives, and  $\leq 15\%$  false-positives) abnormal visual field results with Glaucoma Hemifield Test outside normal limits or pattern standard deviation outside 95% normal limits. Glaucoma eyes were stratified into 2 categories based on the severity of their 24-2 visual field damage. Eyes with mean deviation (MD)  $> -6.0$  dB were classified as mild glaucoma, and eyes with MD  $\leq -6.0$  were classified as moderate to severe glaucoma.<sup>18</sup> The quality of visual field tests was reviewed by the Visual Field Assessment Center (VisFACT) and eyes with identifiable testing artifacts (eg, rim artifacts) were excluded.

Participants with a history of intraocular surgery (except for uncomplicated cataract or uncomplicated glaucoma surgery), coexisting retinal pathologies, nonglaucomatous optic neuropathy, uveitis, ocular trauma, spherical equivalent  $< -6$  D or axial length  $> 26.5$  mm were not included in the study. Systemic blood pressure (BP) was measured in a seated position using the Omron Automatic (Model BP791IT; Omron Healthcare Inc., Lake Forest, IL) BP monitor. Baseline OCT RNFL thickness was measured Spectralis (Heidelberg Engineering, Heidelberg, Germany). IOP and BP measurements taken within a year of OCT-A scan were included in this study for descriptive purposes. Mean arterial pressure was calculated as one third of the systolic BP plus two thirds of the diastolic BP. Mean ocular perfusion pressure (MOPP) was defined as the difference between two thirds of the mean arterial pressure and the IOP.

### OCT-A

The Avanti Angiovue system (Optovue Inc.), consisting of a combined OCT-A and spectral-domain optical coherence tomography system, provides noninvasive visualization of the retinal vascular network by using a motion-contrast technique optimized for the split-spectrum amplitude-decorrelation angiography (SSADA) algorithm described previously.<sup>19</sup> The OCT-A Angiovue analysis software automatically calculates VD as the percentage of measured area occupied by flowing

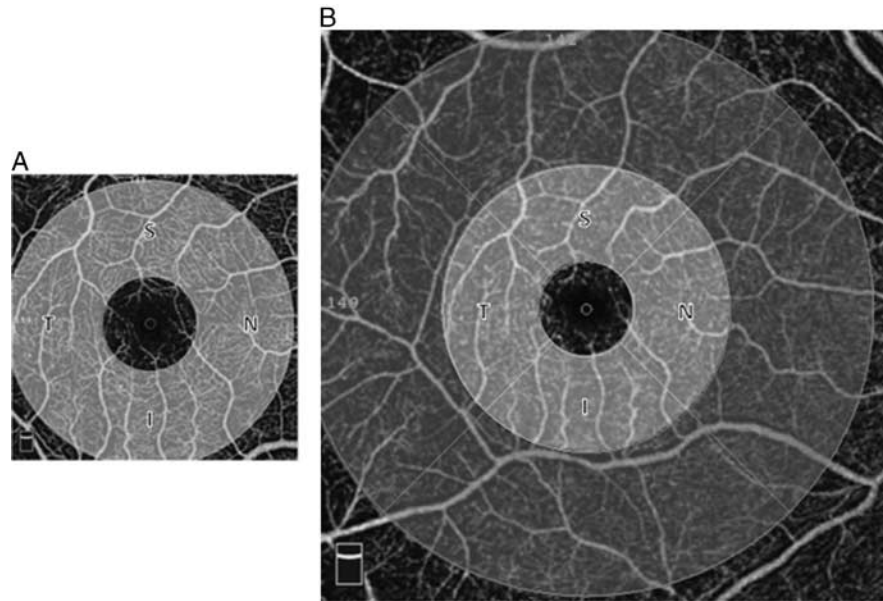
blood vessels defined as pixels having decorrelation values above the threshold level. Macula VD measurements were calculated from 3×3 to 6×6 mm<sup>2</sup> scans centered on the fovea. The macula OCT-A scanning protocol for both scan sizes consists of merged Fast-X volume of 304 horizontal B-scans of 304 A-scans per B-scan and Fast-Y volume of 304 vertical B-scans of 304 A-scans per B-scan.

Each scan was automatically segmented by the Angiovue software (version 2017.1.0.151) to visualize the superficial capillary plexus, measured from the internal limiting membrane to 10  $\mu$ m below the inner plexiform layer (IPL). VD of the inner ring was measured in an annular region with an inner diameter of 1 mm and an outer diameter of 3 mm centered on the fovea for both 3×3 and 6×6 mm<sup>2</sup> scan sizes. VD of the outer ring was measured in an annular region with an inner diameter of 3 mm and an outer diameter of 6 mm for the larger scan (Fig. 1). These measurements can be automatically exported from the instrument. A weighted mean of the inner and outer ring vessel densities of the 6×6 mm<sup>2</sup> scan was calculated and included in the analysis, corresponding to an annular region with an inner diameter of 1 mm and an outer diameter of 6 mm centered on the fovea. Ganglion cell complex (GCC) thickness measurements derived from the same scans were also included in the analysis.

OCT-A image quality review was performed by trained observers following a standard protocol established by the University of California, San Diego Imaging Data Evaluation and Analysis (IDEA) Reading Center.<sup>15</sup> Scans with poor quality, as defined by the following criteria, were not included: (1) a Quality Index  $< 3$  (where 1 = minimum, 10 = maximum), (2) poor clarity, (3) residual motion artifacts visible as an irregular vessel pattern on the en-face angiogram, (4) local weak signal, and (5) off-centered fovea. Segmentation errors were corrected when possible. Of 434 eyes initially eligible for this study, 44 (10.1%) were excluded due to poor quality 3×3 mm<sup>2</sup> scan, 16 (3.7%) were excluded due to poor quality 6×6 mm<sup>2</sup> scan and 59 (13.6%) were excluded due to both scan sizes having poor quality. In sum, 20.5% of scans had poor quality, leading to exclusion of 27.4% of initially eligible eyes. This is consistent with a previous study from our center that reported ~25% of scans having poor quality,<sup>20</sup> and with the reported high prevalence of severe artifacts in OCT-A images (56.8% of 3×3 mm<sup>2</sup> and 50.7% of 6×6 mm<sup>2</sup> scans presented severe image artifacts).<sup>21</sup>

### Statistical Analysis

Continuous and categorical data are reported as mean [95% confidence interval (CI)] and count (percentage) throughout. Statistical significance of subject-level characteristics was determined across groups using analysis of variance for continuous variables (with 2-sample *t* tests for pairwise comparisons) and Fisher exact test for categorical variables. Eye-level characteristics were compared between groups using linear mixed-effects models, with a random intercept to account for within-subject correlation. Comparisons of GCC thickness and VD parameters between groups were made with similar linear mixed-effects models, with the addition of fixed effects for age and scan quality. Diagnostic accuracy for differentiating between healthy and glaucoma eyes (in addition to the diagnostic accuracy in subsets of both mild and moderate to severe glaucoma eyes) was evaluated by calculating the age and scan-quality adjusted<sup>22</sup> area under the receiver operating characteristic (AUC) curves for each scan size, with confidence limits and



**FIGURE 1.** Macula OCT-A scans of the right eye of an 87-year-old female mild glaucoma patient (MD = -0.92 dB). A, 3×3 mm<sup>2</sup> scan, Quality Index = 8/10. B, 6×6 mm<sup>2</sup> scan, Quality Index = 8/10. Light gray: Inner ring with an inner diameter of 1 mm and an outer diameter of 3 mm. Dark gray: Outer ring with an inner diameter of 3 mm and an outer diameter of 6 mm. I indicates inferior; MD, mean deviation; N, nasal; OCT-A, optical coherence tomography angiography; S, superior; T, temporal.

hypothesis tests conducted via a clustered bootstrap with 1000 resamples by patient. All analyses were performed using the R statistical software (version 3.5.2). *P*-values of <0.05 were considered statistically significant.

**RESULTS**

Two hundred seventy-nine eyes from 190 study participants were included (Table 1). The 51 healthy control subjects were significantly younger (*P* < 0.001) than the 91

**TABLE 1.** Patient and Eye Characteristics

	Healthy (N = 51) (89 Eyes)	Mild Glaucoma (N = 91) (127 Eyes)	Moderate/Severe Glaucoma (N = 48) (63 Eyes)	<i>P</i>
Age (y)	58.5 (55.2, 61.8)	72.4 (70.3, 74.5)	72.6 (69.6, 75.6)	< 0.001*†
Sex (female/male)	36 (70.6)/15 (29.4)	45 (49.5)/46 (50.5)	22 (45.8)/26 (54.2)	0.020*†
Race				
African descent	16 (31.4)	23 (25.3)	9 (18.8)	0.210
European descent	31 (60.8)	63 (69.2)	30 (62.5)	
Other	4 (7.8)	5 (5.5)	9 (18.8)	
Systemic hypertension				
No	24 (47.1)	34 (37.4)	23 (47.9)	0.198
Yes	19 (37.3)	52 (57.1)	24 (50.0)	
Unknown/not reported	8 (15.7)	5 (5.5)	1 (2.1)	
Diabetes				
No	41 (80.4)	69 (75.8)	38 (79.2)	0.053*
Yes	2 (3.9)	17 (18.7)	9 (18.8)	
Unknown/not reported	8 (15.7)	5 (5.5)	1 (2.1)	
Visual field 24-2 MD (dB)	-0.05 (-0.91 to 0.80)	-2.77 (-3.41 to -2.13)	-11.67 (-12.52 to -10.82)	< 0.001*†‡
Visual field 24-2 PSD (dB)	1.67 (1.14, 2.19)	4.00 (3.60, 4.40)	9.82 (9.29, 10.35)	< 0.001*†‡
IOP (mm Hg) <sup>1</sup>	14.9 (13.0, 16.8)	14.6 (13.6, 15.6)	15.2 (14.0, 16.3)	0.608
Axial length (mm) <sup>2</sup>	23.7 (23.4, 24.0)	24.3 (24.1, 24.5)	24.1 (23.9, 24.3)	0.003*†
Central corneal thickness (μm) <sup>3</sup>	549.0 (538.5, 559.5)	542.6 (535.8, 549.4)	539.5 (531.8, 547.2)	0.315
MOPP (mm Hg) <sup>4</sup>	49.6 (45.9, 53.2)	49.3 (47.4, 51.2)	48.2 (46.1, 50.2)	0.339
Spectralis global RNFL (μm) <sup>5</sup>	97.7 (94.3, 101.1)	75.4 (73.0, 77.8)	63.0 (59.8, 66.2)	< 0.001*†‡

Continuous and categorical data is presented as mean (95% CI) and count (%), respectively. Significance of patient characteristics is determined by ANOVA (*t* test for pairwise comparisons) and Fisher exact test. Significance of eye characteristics is determined by linear mixed effects models.

Bold values indicate *P* < 0.05.

Significant pairwise comparisons: \*Healthy versus mild glaucoma; †Healthy versus moderate/severe glaucoma; ‡Mild versus moderate/severe glaucoma.

Missing 77<sup>1,4</sup>, 6<sup>2</sup>, 8<sup>3</sup>, and 17<sup>5</sup> values.

ANOVA indicates analysis of variance; CI, confidence interval; IOP, intraocular pressure; MD, mean deviation; MOPP, mean ocular perfusion pressure; PSD, pattern standard deviation; RNFL, retinal nerve fiber layer.

patients with mild glaucoma and 48 patients with moderate to severe glaucoma (Table 1). (Both eyes of healthy participants were not always included because some of these individuals did not have images of both scans sizes obtained on the same day.) Mean visual field MD and RNFL global thickness were significantly different among diagnostic groups in all pairwise comparisons, with values higher in healthy eyes and lower in moderate to severe glaucoma eyes. The prevalence of diabetes was significantly lower in the healthy group compared with mild glaucoma patients. Axial length was significantly shorter in healthy eyes compared with mild glaucoma and moderate to severe glaucoma eyes (average 0.6 and 0.4 mm lower, respectively). Race, history of hypertension, IOP, CCT, and MOPP did not differ among the 3 diagnostic groups (Table 1).

Mean (95% CI) 3×3 mm<sup>2</sup> scans inner ring VD was significantly greater in healthy eyes (50.4%, 95% CI: 49.2, 51.7) compared with mild glaucoma (45.8%, 95% CI: 44.9, 46.7) and moderate to severe glaucoma (41.0%, 95% CI: 39.8, 42.1) (*P* < 0.05 for all pairwise comparisons). The weighted mean of inner and outer rings vessel densities of the 6×6 mm<sup>2</sup> scan was also significantly greater in healthy eyes (50.1%, 95% CI: 48.9, 51.4) compared with mild glaucoma (43.5%, 95% CI: 42.6, 44.4) and moderate to severe glaucoma (39.3%, 95% CI: 38.1, 40.4) (*P* < 0.05 for all pairwise comparisons; Table 2).

VD obtained from the outer ring of the 6×6 mm<sup>2</sup> scan performed marginally better than VD obtained from the inner ring of the 3×3 mm<sup>2</sup> image (AUC = 0.82 and 0.77, respectively; *P* = 0.049) for differentiating between healthy and glaucoma eyes, while the combined VD obtained from both inner and outer rings of the 6×6 mm<sup>2</sup> image (AUC = 0.82) did not perform significantly better than VD obtained from the inner ring of either scan size. Similarly, only the VD obtained from the outer ring of the larger scan performed better when compared with vessel densities obtained from the inner rings of both scan sizes when differentiating between healthy and mild glaucoma. When differentiating between healthy and moderate to severe glaucoma eyes, vessel densities obtained from the inner ring of the 6×6 mm<sup>2</sup> image performed worse than vessel densities obtained from the 3×3 mm<sup>2</sup> scan (AUC = 0.85 and 0.90, respectively; *P* = 0.059), and this was significant for the temporal sector (*P* = 0.022; Supplementary Table 2, <http://links.lww.com/IJG/A358>, Supplementary Fig. 2, <http://links.lww.com/IJG/A356>). For both scan sizes, the highest sensitivity at 90%

specificity occurred when differentiating between healthy and moderate to severe glaucoma (0.86 in the temporal sector of the 3×3 mm<sup>2</sup> scan, and 0.84 and 0.83 in the nasal outer sector and the entire outer ring of the 6×6 mm<sup>2</sup> scan).

Mean inner ring GCC thickness obtained from the 3×3 mm<sup>2</sup> scans was significantly greater in healthy eyes (110.0 μm, 95% CI: 106.8, 113.2) than in mild glaucoma eyes (93.8 μm, 95% CI: 91.5, 96.1) and moderate to severe glaucoma eyes (81.6 μm, 95% CI: 78.6, 84.5) (*P* < 0.05 for all pairwise comparisons). The inner and outer ring weighted mean GCC thickness obtained from the 6×6 mm<sup>2</sup> scans (1 to 6 mm) was significantly greater in healthy eyes (100.1 μm, 95% CI: 97.6, 102.7) than in mild glaucoma eyes (83.5 μm, 95% CI: 81.7, 85.3) and moderate to severe glaucoma eyes (74.4 μm, 95% CI: 72.1, 76.6) (*P* < 0.05 for all pairwise comparisons; Table 2).

Inner ring GCC thickness from the 3×3 mm<sup>2</sup> scan performed similarly to the 6×6 mm<sup>2</sup> scan for differentiating between healthy and glaucomatous eyes (AUC = 0.80 for 3×3 mm<sup>2</sup> and AUC = 0.81 for 6×6 mm<sup>2</sup>, *P* = 0.815). In contrast, the outer ring GCC thickness from the 6×6 mm<sup>2</sup> scan performed better (AUC = 0.87, *P* = 0.018) than the inner ring of the 3×3 mm<sup>2</sup> scan, and so did the weighted mean of inner and outer rings GCC thickness (AUC = 0.87, *P* = 0.013). The outer ring and inner and outer rings of the 6×6 mm<sup>2</sup> scan combined also outperformed the inner ring of both scan sizes when differentiating between healthy and mild glaucoma (*P* = 0.019 and 0.016, respectively; driven primarily by the temporal, superior and inferior sectors). In addition, the combined inner and outer ring of the 6×6 mm<sup>2</sup> scan GCC thickness outperformed the inner ring of the 3×3 mm<sup>2</sup> scan when differentiating between healthy and moderate to severe glaucoma (*P* = 0.037; driven primarily by the nasal sector) (Table 3, Fig. 2; Supplementary Table 2, <http://links.lww.com/IJG/A358>, Supplementary Fig. 1, <http://links.lww.com/IJG/A356>).

Same sector GCC thickness and VD from both scan sizes showed similar diagnostic accuracy when differentiating between healthy and glaucoma, healthy and mild glaucoma, or healthy and moderate to severe glaucoma (*P* > 0.05 for all comparisons).

### DISCUSSION

The present study evaluated VD and GGC thickness derived from 2 different macula OCT-A scan sizes and compared their ability for differentiating between healthy eyes,

**TABLE 2.** Mean (95% CI) of Each Thickness and Vessel Density Parameter by Group and Scan Size

Scan Size	Area	Healthy	Mild Glaucoma	Moderate/Severe Glaucoma	<i>P</i>
GCC thickness (μm)					
3 mm	1-3 mm	110.0 (106.8, 113.2)	93.8 (91.5, 96.1)	81.6 (78.6, 84.5)	< 0.001
6 mm	1-3 mm	106.8 (103.7, 110.0)	90.7 (88.5, 93.0)	78.7 (75.9, 81.6)	< 0.001
	3-6 mm	98.2 (95.6, 100.7)	81.4 (79.6, 83.2)	73.1 (70.9, 75.3)	< 0.001
	1-6 mm	100.1 (97.6, 102.7)	83.5 (81.7, 85.3)	74.4 (72.1, 76.6)	< 0.001
Vessel density (%)					
3 mm	1-3 mm	50.4 (49.2, 51.7)	45.8 (44.9, 46.7)	41.0 (39.8, 42.1)	< 0.001
6 mm	1-3 mm	52.3 (50.9, 53.6)	46.7 (45.7, 47.7)	43.1 (41.8, 44.4)	< 0.001
	3-6 mm	49.5 (48.3, 50.7)	42.6 (41.7, 43.4)	38.2 (37.0, 39.3)	< 0.001
	1-6 mm	50.1 (48.9, 51.4)	43.5 (42.6, 44.4)	39.3 (38.1, 40.4)	< 0.001

Bold values indicate *P* < 0.05.

Significance is determined by a linear mixed effects model, with covariate adjustment for age and scan quality. All pairwise comparisons were statistically significant.

1-3: inner ring; 3-6: outer ring; 1-6: inner and outer rings combined.

CI indicates confidence interval; GCC, ganglion cell complex.

**TABLE 3.** Age and Quality Adjusted AUC (95% CI) of Each Thickness and Vessel Density Parameter by Group and Scan Size, With Sensitivity CIs Computed Via a Clustered Bootstrap

Scan Size	Area	Healthy vs. Glaucoma	Healthy vs. Mild Glaucoma	Healthy vs. Moderate/Severe Glaucoma
GCC thickness AUC				
3 mm	1-3 mm	0.80 (0.70, 0.88)	0.75 (0.63, 0.85)	0.91 (0.82, 0.96)
6 mm	1-3 mm	0.81 (0.70, 0.89)	0.75 (0.63, 0.85)	0.92 (0.83, 0.97)
	3-6 mm	0.87 (0.78, 0.93)	0.84 (0.73, 0.91)	0.95 (0.88, 0.98)
	1-6 mm	0.87 (0.77, 0.93)	0.83 (0.72, 0.91)	0.95 (0.88, 0.98)
Vessel density AUC				
3 mm	1-3 mm	0.77 (0.66, 0.87)	0.71 (0.58, 0.82)	0.90 (0.82, 0.96)
6 mm	1-3 mm	0.74 (0.66, 0.83)	0.69 (0.60, 0.79)	0.85 (0.77, 0.92)
	3-6 mm	0.84 (0.76, 0.90)	0.79 (0.71, 0.87)	0.92 (0.86, 0.97)
	1-6 mm	0.82 (0.74, 0.89)	0.78 (0.69, 0.86)	0.91 (0.84, 0.96)

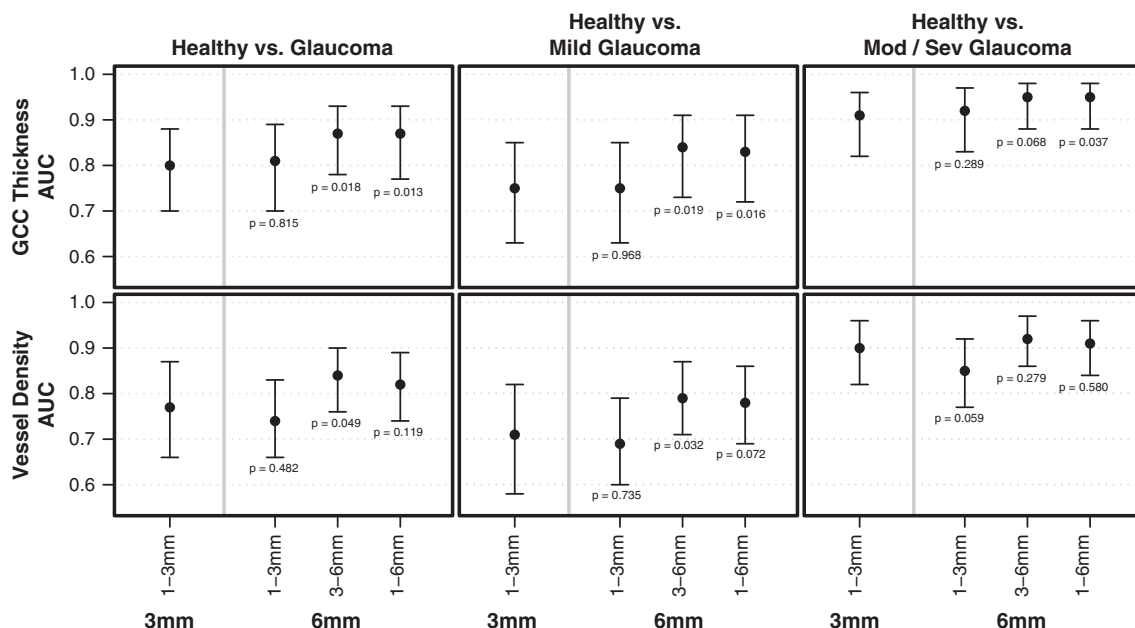
1-3: inner ring; 3-6: outer ring; 1-6: inner and outer rings combined.

AUC indicates area under the receiver operating characteristic; CI, confidence interval; GCC, ganglion cell complex.

mild glaucoma eyes and moderate to severe glaucoma eyes. In general, the diagnostic ability of VD and GCC thickness of the outer region of the 6×6 mm<sup>2</sup> macula OCT-A scans were similar or better than the inner region of the 6×6 mm<sup>2</sup> scans and the corresponding area of the 3×3 mm<sup>2</sup> scan.

The diagnostic ability of the 3×3 mm<sup>2</sup> macula scan VD was higher in the temporal sector than in other sectors when differentiating between healthy and glaucoma, healthy and mild glaucoma, and healthy and moderate to severe glaucoma (Supplementary Materials, <http://links.lww.com/IJG/A356>, <http://links.lww.com/IJG/A357>, <http://links.lww.com/IJG/A358>, <http://links.lww.com/IJG/A359>). In contrast, when evaluating sectors from the 6×6 mm<sup>2</sup> macula scan, VD from the superior sector of the outer ring performed better than other sectors for differentiating between healthy and glaucoma, healthy and mild glaucoma, and healthy and moderate to severe glaucoma. In the only other study (to our knowledge) comparing

different scan sizes in healthy and glaucoma eyes, Rao et al<sup>23</sup> compared optical microangiography (OMAG) measurements from Cirrus HD-OCT (Carl Zeiss Meditec Inc., Dublin, CA) between 3×3 and 6×6 mm<sup>2</sup> macula OCT-A scan sizes. Results were similar to those reported in the current study, with vessel densities measured from the temporal sector of the 3×3 mm<sup>2</sup> scan showing the best diagnostic accuracy. However, some of the results from Rao and colleagues contradict our results as OMAG density measurement obtained from the superior sector of the outer ring of the larger scan size outperformed other sectors, and they reported that measurements from the inferior sector were best at the classification task. The same study found the VD from the inner region of the 6×6 mm<sup>2</sup> scan of primary open angle glaucoma (POAG) patients was similar to VD in the control group, and the authors suggested this area might not be important for the diagnosis of POAG.<sup>23</sup> In contrast, our study shows that VD obtained from the inner ring of the larger scan size is



**FIGURE 2.** Age and quality-adjusted AUC and 95% CI of each GCC thickness and vessel density parameter in discriminating each glaucoma group from healthy subjects. A  $P < 0.05$  beneath the lower bound of the 95% CI indicates that the bootstrap hypothesis test between the 6 and 3 mm scan size parameter is significant. 1-3: inner ring; 3-6: outer ring; 1-6: inner and outer rings combined. AUC indicates area under the receiver operating characteristic; CI, confidence interval; GCC, ganglion cell complex.

significantly lower in glaucoma patients compared with healthy controls. The differences could be due to differences in scan density, instrumentation and strategies for identifying VD between the SSADA and OMAG algorithms. In addition, the study by Rao et al<sup>23</sup> included a population of glaucoma patients with mean visual field MD of  $-6.3$  dB (SD  $-12.5, -3.5$ ). The authors did not stratify glaucoma patients into different severity categories. The severity of the disease should be considered when comparing studies because AUCs tend to be higher when differentiating between healthy eyes and eyes from patients with severe disease, as shown in the current study (and is expected).

VD AUCs were observed to be lower than the corresponding structural measurements in earlier studies using the same OCT-A instrument as used in the current study.<sup>20,24</sup> However, the current study showed that GCC thickness AUC values were not significantly different from VD values. This difference may be explained by GCC thickness being measured from a separate larger scan type in those studies, whereas the current study uses GCC thickness derived from the same, but smaller, OCT-A scans. As we report in the current study, the  $6\times 6$  mm<sup>2</sup> scan covers a larger area and has better diagnostic accuracy when differentiating between healthy and glaucoma eyes. We hypothesize that an even larger area could provide higher AUC values.

Both scan protocols included in the current study consist of  $304\times 304$  B-scans, regardless of the scan area, meaning that the  $3\times 3$  mm<sup>2</sup> scan is a higher density scan compared with the  $6\times 6$  mm<sup>2</sup> scan (Fig. 1). The higher scan density has proved useful when evaluating the clarity of the fovea avascular zone, which is better delineated in the  $3\times 3$  mm<sup>2</sup> Angiovue OCT-A macula scan compared with the  $6\times 6$  mm<sup>2</sup> scan.<sup>25</sup> In the current study, measurements from the parafoveal superior and inferior quadrants, as well as the entire parafoveal region of the larger scan sizes, performed significantly worse for differentiating between healthy and mild glaucoma than measurements from the smaller, more dense scan. As described by Hood and colleagues, the spatial pattern of the greater vulnerability of the inferior macula region in glaucoma can be affected early in the disease.<sup>2-10</sup> Damage to this inferior vulnerability zone in early glaucoma is usually observed 5 or more degrees away from the center of the fovea<sup>4</sup> and, therefore, not assessed by the  $3\times 3$  mm<sup>2</sup> scan. Thus, it may not identify early glaucomatous damage and differentiate between healthy and mild glaucoma eyes. As the disease progresses, ganglion cell-inner plexiform layer (GCIPL) thinning occurs. In POAG eyes with an average visual field MD of  $<-6$  dB, the most common pattern of progressive GCIPL thinning is widening of the GCIPL defect, especially in the inferotemporal region  $\sim 2.0$  mm from the fovea.<sup>26</sup> Considering that GCIPL thickness and macula VD both are correlated with disease severity,<sup>20,27,28</sup> we hypothesize that the smaller scan size has marginally better diagnostic accuracy than the corresponding area of the larger scan size for differentiating between mild and moderate to severe glaucoma in this study because the higher scan density is able to more effectively detect the VD drop out that occurs within the scanned area.

One limitation of this study is the analysis software used to calculate VD in the  $6\times 6$  mm<sup>2</sup> scan was an early software release consisting of  $304\times 304$  B-scans that is not commercially available. It was provided by the manufacturer only for research purposes. The Avanti Angiovue system offers a "High Density (HD) Angio Retina"  $6\times 6$  mm<sup>2</sup> scan protocol that consists of  $400\times 400$  B-scans. Although the HD scan is less dense than the  $3\times 3$  mm<sup>2</sup> scan used in the current study, it is

possible that it will have better diagnostic accuracy due to both a higher density and a larger area when compared with the  $6\times 6$  and  $3\times 3$  mm<sup>2</sup> scans consisting of  $304\times 304$  B-scans included in this study. The "HD Angio Retina"  $6\times 6$  mm<sup>2</sup> scan is relatively new and will be the subject of another report when there is a sufficient sample size. In addition, the diagnostic groups used in this study presented differences in axial length measures and prevalence of diabetes. Our statistical analysis adjusted for age and quality index because they are known to have an effect on GCC thickness and VD.<sup>20,29,30</sup> Although it has been reported that there is no correlation between axial length and superficial VD in healthy eyes,<sup>31,32</sup> superficial VD within 1.5 mm of the fovea of diabetic patients without diabetic retinopathy has been reported to be decreased when compared with healthy controls.<sup>33</sup> These studies, however, did not include glaucoma patients and analyzed only VD from smaller scans ( $3\times 3$  mm<sup>2</sup>), therefore it is unknown whether these covariates could have any effect on our results.

In summary, GCC thickness and the VD of the outer area of the  $6\times 6$  mm<sup>2</sup> Angiovue OCT-A macula scan performed better than the inner areas of either scan size when differentiating between healthy and glaucoma, and between healthy and mild glaucoma. The GCC thickness and VD derived from the outer sectors of the  $6\times 6$  mm<sup>2</sup> scan had higher diagnostic ability than GCC thickness from the  $3\times 3$  mm<sup>2</sup> scan for differentiating between healthy eyes and eyes with glaucoma, and healthy and mild glaucoma eyes. This difference was not seen when differentiating between healthy and moderate to severe glaucoma. It is possible that there is less of a difference between outer and inner sector AUCs in moderate/severe cases because the central macula is more likely to be damaged in advanced disease. VD measurements from the smaller denser scan performed only marginally better ( $P=0.059$ ) than the corresponding area of the larger scan when differentiating between healthy and moderate to severe glaucoma. These results suggest that the use of a larger macula scan of  $6\times 6$  mm<sup>2</sup> is preferable for differentiating between healthy eyes and eyes with mild glaucoma, and either scan size will perform well when differentiating between healthy eyes and eyes with moderate to severe glaucoma.

## REFERENCES

- Weinreb RN, Aung T, Medeiros FA. The pathophysiology and treatment of glaucoma: a review. *JAMA*. 2014;311:1901-1911.
- Curcio CA, Allen KA. Topography of ganglion cells in human retina. *J Comp Neurol*. 1990;300:5-25.
- Hood DC, Raza AS, de Moraes CG, et al. Glaucomatous damage of the macula. *Prog Retin Eye Res*. 2013;32:1-21.
- Hood DC. Improving our understanding, and detection, of glaucomatous damage: an approach based upon optical coherence tomography (OCT). *Prog Retin Eye Res*. 2017;57:46-75.
- Alhadeff PA, De Moraes CG, Chen M, et al. The association between clinical features seen on fundus photographs and glaucomatous damage detected on visual fields and optical coherence tomography scans. *J Glaucoma*. 2017;26:498-504.
- Kim KE, Kim SH, Oh S, et al. Additive diagnostic role of imaging in glaucoma: optical coherence tomography and retinal nerve fiber layer photography. *Invest Ophthalmol Vis Sci*. 2014;55:8024-8030.
- Khachatryan V, Sirunyan AM, Tumasyan A, et al. Search for new physics in same-sign dilepton events in proton-proton collisions at [Formula: see text]. *Eur Phys J C Part Fields*. 2016;76:439.
- Seo JH, Kim TW, Weinreb RN, et al. Detection of localized retinal nerve fiber layer defects with posterior pole asymmetry

- analysis of spectral domain optical coherence tomography. *Invest Ophthalmol Vis Sci.* 2012;53:4347–4353.
9. Na JH, Kook MS, Lee Y, et al. Detection of macular and circumpapillary structural loss in normal hemifield areas of glaucomatous eyes with localized visual field defects using spectral-domain optical coherence tomography. *Graefes Arch Clin Exp Ophthalmol.* 2012;250:595–602.
  10. Zhang C, Tatham AJ, Abe RY, et al. Macular ganglion cell inner plexiform layer thickness in glaucomatous eyes with localized retinal nerve fiber layer defects. *PLoS One.* 2016;11:e0160549.
  11. Weinreb RN, Harris A. *Ocular Blood Flow in Glaucoma [Vol 6]*. Amsterdam, The Netherlands: Kugler Publications; 2009.
  12. Flammer J, Orgul S, Costa VP, et al. The impact of ocular blood flow in glaucoma. *Prog Retin Eye Res.* 2002;21:359–393.
  13. Schmidl D, Garhofer G, Schmetterer L. The complex interaction between ocular perfusion pressure and ocular blood flow—relevance for glaucoma. *Exp Eye Res.* 2011;93:141–155.
  14. Shahlaee A, Samara WA, Hsu J, et al. In vivo assessment of macular vascular density in healthy human eyes using optical coherence tomography angiography. *Am J Ophthalmol.* 2016;165:39–46.
  15. Yarmohammadi A, Zangwill LM, Diniz-Filho A, et al. Optical coherence tomography angiography vessel density in healthy, glaucoma suspect, and glaucoma eyes. *Invest Ophthalmol Vis Sci.* 2016;57:OCT451–OCT459.
  16. Rao HL, Pradhan ZS, Weinreb RN, et al. Regional comparisons of optical coherence tomography angiography vessel density in primary open-angle glaucoma. *Am J Ophthalmol.* 2016;171:75–83.
  17. Sample PA, Girkin CA, Zangwill LM, et al. The African Descent and Glaucoma Evaluation Study (ADAGES): design and baseline data. *Arch Ophthalmol.* 2009;127:1136–1145.
  18. Hodapp E, Parrish R, Anderson D. *Clinical Decisions in Glaucoma*. St. Louis, MO: CV Mosby Company; 1993:52–61.
  19. Jia Y, Tan O, Tokayer J, et al. Split-spectrum amplitude-decorrelation angiography with optical coherence tomography. *Opt Express.* 2012;20:4710–4725.
  20. Penteado RC, Zangwill LM, Daga FB, et al. Optical coherence tomography angiography macular vascular density measurements and the central 10-2 visual field in glaucoma. *J Glaucoma.* 2018;27:481–489.
  21. Holmen IC, Konda MS, Pak JW, et al. Prevalence and severity of artifacts in optical coherence tomographic angiograms. *JAMA Ophthalmol.* 2019. [Epub ahead of print].
  22. Pepe M, Longton G, Janes H. Estimation and comparison of receiver operating characteristic curves. *Stata J.* 2009;9:1.
  23. Rao HL, Riyazuddin M, Dasari S, et al. Diagnostic abilities of the optical microangiography parameters of the 3×3 mm and 6×6 mm macular scans in glaucoma. *J Glaucoma.* 2018;27:496–503.
  24. Rao HL, Pradhan ZS, Weinreb RN, et al. A comparison of the diagnostic ability of vessel density and structural measurements of optical coherence tomography in primary open angle glaucoma. *PLoS One.* 2017;12:e0173930.
  25. Ho J, Dans K, You Q, et al. Comparison of 3 mm×3 mm versus 6 mm×6 mm optical coherence tomography angiography scan sizes in the evaluation of non-proliferative diabetic retinopathy. *Retina.* 2019;39:259–264.
  26. Shin JW, Sung KR, Park SW. Patterns of progressive ganglion cell-inner plexiform layer thinning in glaucoma detected by OCT. *Ophthalmology.* 2018;125:1515–1525.
  27. Hou H, Moghimi S, Zangwill LM, et al. Macula vessel density and thickness in early primary open-angle glaucoma. *Am J Ophthalmol.* 2019;199:120–132.
  28. Ghahari E, Bowd C, Zangwill LM, et al. Association of macular and circumpapillary microvasculature with visual field sensitivity in advanced glaucoma. *Am J Ophthalmol.* 2019;204:51–61.
  29. Zhang X, Francis BA, Dastiridou A, et al. Longitudinal and cross-sectional analyses of age effects on retinal nerve fiber layer and ganglion cell complex thickness by fourier-domain OCT. *Transl Vis Sci Technol.* 2016;5:1.
  30. Leung CKS, Ye C, Weinreb RN, et al. Impact of age-related change of retinal nerve fiber layer and macular thicknesses on evaluation of glaucoma progression. *Ophthalmology.* 2013;120:2485–2492.
  31. Hashmani N, Hashmani S, Murad A, et al. Macular vascular density at the superficial capillary plexus using the optical coherence tomography angiography. *Clin Ophthalmol.* 2019;13:295–302.
  32. Wang Q, Chan S, Yang JY, et al. Vascular density in retina and choriocapillaris as measured by optical coherence tomography angiography. *Am J Ophthalmol.* 2016;168:95–109.
  33. Dimitrova G, Chihara E, Takahashi H, et al. Quantitative retinal optical coherence tomography angiography in patients with diabetes without diabetic retinopathy. *Invest Ophthalmol Vis Sci.* 2017;58:190–196.