

## Case Presentation

### Cryptococcal cellulitis on the shin of an immunosuppressed patient

Tian Hao Zhu, Paola G. Rodriguez, James W Behan, Brittney Declerck, Gene H Kim

Dermatology Online Journal 22 (6): 4

Departments of Dermatology University of Southern California Keck School of Medicine, Los Angeles, California

#### Correspondence:

Gene H. Kim MD  
1441 Eastlake Avenue  
Topping Tower, Suite 3405  
Los Angeles, CA 90033  
Tel (323) 442-9617, Fax (323) 442-9993  
Email: genekim@usc.edu

---

## Abstract

*Cryptococcus neoformans* is a common fungus found throughout the environment that causes opportunistic disease in immunocompromised individuals. Infection of humans with *C neoformans* usually manifests as lung disease through inhalation of spores or meningoencephalitis by involvement of the central nervous system. Rarely, dissemination in the form of cutaneous lesions can occur in individuals with long term immunosuppression. We present a patient with *C. neoformans* manifesting as cellulitis with focal segmental glomerulosclerosis treated with corticosteroids. Because of the mortality associated with disseminated cryptococcosis, early identification, especially of atypical cutaneous presentations is critical from a dermatological perspective.

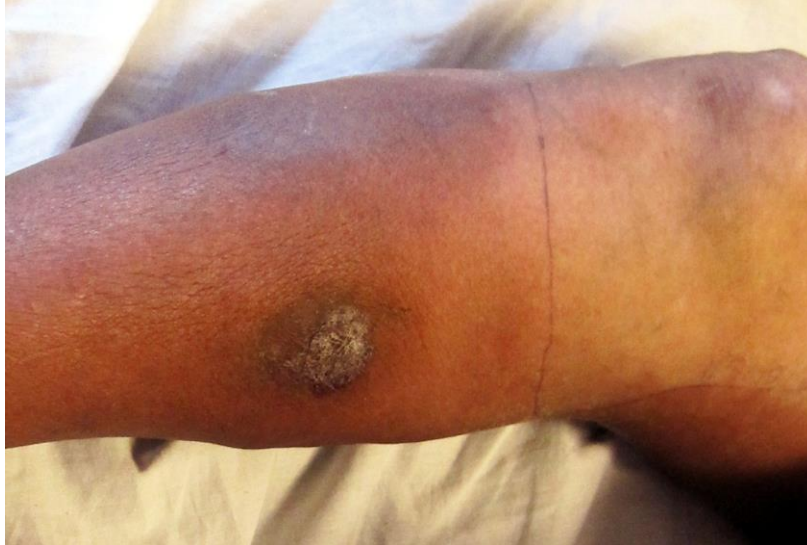**Keywords:** cryptococcal cellulitis, immunosuppression, antifungal therapy

## Introduction

*Cryptococcus neoformans* is an encapsulated yeast commonly found in soil, pigeon droppings, and decaying wood, fruits, and vegetables [1]. *C. neoformans* can be subclassified as variety *grubii* (serotype A), variety *gatii* (serotype B and C), and variety *neoformans* (serotype D) [2]. Although *C neoformans* var. *gatii* causes disease in immunocompetent individuals, *C neoformans* var. *neoformans* is a clinically important cause of opportunistic infection in immunocompromised hosts [2,3]. The major route of entry of infection is thought to be the respiratory tract through inhalation of aerosolized basidiospores [2]. However, hematogenous spread following aspiration can lead to disseminated cryptococcosis with cutaneous involvement in 10-20% of individuals [2]. Dermatologic features of cutaneous cryptococcosis can include papules, plaques, abscesses, nodules, pustules, and acneiform lesions [4]. Cellulitis caused by *C neoformans* is relatively rare with cases previously reported thus far in individuals on immunosuppressive therapy for solid organ transplants [5], rheumatoid arthritis [6], myelodysplastic syndrome [7], systemic erythematous lupus [8], and severe asthma [9]. We present here an additional case of Cryptococcal cellulitis in an individual who received long term corticosteroid therapy for nephrotic syndrome with emphasis on prompt diagnosis and appropriate treatment guidelines.

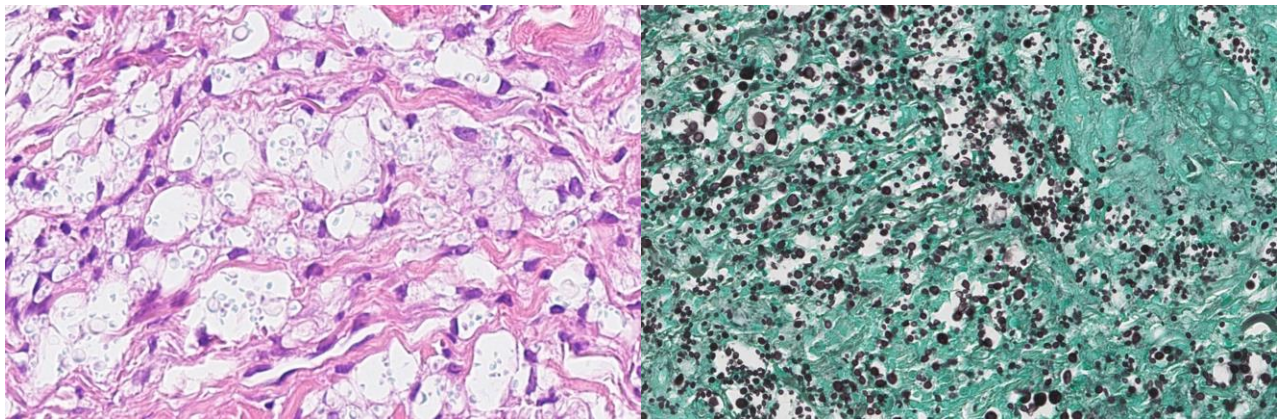
## Case synopsis

A 59-year-old man with focal segmental glomerulosclerosis, treated with prednisone and cyclosporine, was admitted for a cellulitis of the right lower leg that was refractory to treatment with oral clindamycin. His past medical history was also significant for deep venous thrombosis (DVT), treated with coumadin, and a prior episode of cellulitis several years earlier in the same leg that responded to antibiotics. He was admitted to the hospital and started on vancomycin. Initially, there was clinical improvement, but he continued to experience moderate to severe pain after eight days of treatment. On physical exam, the leg had a hyperpigmented, verrucous plaque over the shin with peau d'orange changes over the calf and lateral lower leg (Figure 1). Two punch biopsies were performed and sent for culture and histopathologic examination.



**Figure1.** An indurated verrucous plaque over the shin. Note the dusky erythema and surrounding edema from ankle to thigh with sparing of the anterior knee.

The biopsy showed a mucoid dermal infiltrate (Figure 2) with numerous yeast forms highlighted Gomori's methamine silver (Figure 3). Tissue cultures confirmed the diagnosis of *C neoformans*. The cryptococcal serum antigen titer was 1:2048. Upon further questioning, after his diagnosis was established, the patient endorsed exposure to pigeons at a nearby park. However, the patient had no respiratory symptoms and a chest radiograph on admission was normal. A subsequent lumbar puncture did not suggest central nervous system involvement.



**Figure2.** Skin biopsy demonstrated numerous pale spherules surrounded by a capsule with limited tissue reaction on hematoxylin-eosin stained section. **Figure 3.** The spherules were highlighted by Gomori's methamine silver stain.

Therapy for his cryptococcal cellulitis was initiated with an induction of intravenous amphotericin B 0.7 mg/kg/day and oral flucytosine 100 mg/kg/day divided between four doses. His immunosuppressant medication was held after blood cultures grew *C neoformans*. After one week, the patient reported a dramatic decrease in leg pain. However, owing to the nephrotoxicity of amphotericin B, his induction therapy was shortened after eight days. He was transitioned to maintenance treatment with oral fluconazole 800 mg and flucytosine 2500 mg daily and was discharged with follow up at an outside infectious disease clinic.

A month later, he was readmitted for shortness of breath, acute onset of right leg pain, and erythema of his right lower extremity. Because of an unchanged cryptococcal serum antigen titer and the shortened induction treatment, the patient was restarted on

amphotericin B (liposomal formulation) and flucytosine for two weeks. He was found to have a pulmonary embolism and his leg began to ulcerate despite antifungal therapy. His status deteriorated over the next month and he was eventually transferred to the intensive care unit. He developed septicemia with gram-negative rods and *Acinetobacter* and expired.

## Discussion

*Cryptococcal neoformans* is an encapsulated yeast that predominantly causes self-limited pulmonary and central nervous system (CNS) disease. Skin involvement, although uncommon, does occur either by direct inoculation without systemic involvement, referred to as primary cutaneous cryptococcosis (PCC) or through hematogenous spread, referred to as secondary cutaneous cryptococcosis [1]. Most cases of cutaneous cryptococcosis are thought to be caused by disseminated disease as PCC is relatively rare and confined to local areas of skin injury without extracutaneous manifestations [1,2, 9]. Although not completely confirmed, our patient likely developed secondary cutaneous cryptococcosis from respiratory tract involvement. Although the lungs may be the port of entry, some patients with disseminated cryptococcosis may not have clinical signs of pneumonia at the time of presentation.

To date, characteristic skin lesions observed for secondary cutaneous cryptococcosis have included ulcers, abscesses, papules, nodules, vesicles, and granulomas [4]. Our patient, however, exhibited a rare presentation of cryptococcosis in the form of cellulitis with a superimposed verrucous plaque. The morphological features of cryptococcal cellulitis were first emphasized in the literature by Schupbach et al, in 1976 [10]. They described a series of five immunosuppressed patients who presented with warmth, erythema, and tenderness and were initially diagnosed with a bacterial cellulitis. Tissue biopsy, culture, or Tzanck smears confirmed the diagnosis of cryptococcosis [10]

Recently, reports of cryptococcal cellulitis have increased in frequency owing to individuals receiving chronic immunosuppressive therapy for solid organ transplants, lupus, asthma, rheumatoid arthritis, and other autoimmune disease such as bullous pemphigoid and myasthenia gravis [6-9,12,13]. In the literature, patients with cryptococcal cellulitis have been iatrogenically immunosuppressed with tacrolimus, prednisone, cyclosporine, azathioprine, cyclophosphamide, and mycophenolate mofetil [4-11]. In addition cellulitis has been observed in patients with impaired cellular immunity such as AIDS and congenital lymphedema [14]. The patient we examined had been treated with prednisone and cyclosporine for nephrotic syndrome, causing immune suppression and likely permitting intravascular dissemination of *C neoformans* to distant sites such as the skin. Since cryptococcal cellulitis can be easily mistaken for bacterial cellulitis clinicians should consider a fungal etiology in an immunocompromised patient if the cellulitis does not initially improve on appropriate antibiotic therapy.

Methods of diagnosis can include Tzanck cytologic smear of vesicles or India ink stain of aspirations showing the saprophytic fungus. In addition, skin biopsy stained with Gomori's methamine silver, periodic acid-Schiff, hematoxylin-and-eosin, or mucicarmine can help to demonstrate the characteristic spherical budding yeasts with surrounding zone of clear capsule. Culture of blood, urine, or cerebrospinal fluid on Sabouraud dextros agar will reveal translucent cream-colored, mucoid colonies [15]. Obtaining cryptococcal antigen titers is another critical consideration in the initial evaluation because baseline titer levels aid in diagnosis and provide an estimate of disease severity. The presence of a high cryptococcal antigen titer in serum would suggest active dissemination with greater fungal load that may require more extensive treatment [16]. However the utility of cryptococcal titers in managing response to treatment is less clear as cryptococcal antigen can persist despite resolution of disease [16].

Prognosis of disseminated cryptococcosis can be favorable if early signs of cellulitis alert clinicians to the right diagnosis with prompt and aggressive antifungal therapy. Distinguishing between primary cutaneous inoculation of cryptococcus and secondary cryptococcal infection is critical in determining the appropriate treatment. The management guidelines, as of January 2010, from the Infectious Disease Society of America for non-meningeal, non-pulmonary involvement is fluconazole 400 mg or 6 mg/kg for 6 to 12 months [16]. This recommendation applies to primary cutaneous cryptococcosis with infection restricted to a single site. However, if there is evidence of cryptococemia or more than 1 site of infection, the patient should be treated similarly to those with CNS infection with amphotericin B (0.7–1.0 mg/kg per day IV) plus flucytosine (100 mg/kg per day orally) for a minimum of 2 weeks for induction and fluconazole 400 mg (6 mg/kg per day orally) for a minimum of 8 weeks for consolidation (grade B/Level III evidence) [16]. Nevertheless, certain antifungal medications may require dose or class adjustments owing to their nephrotoxic side effects toward individuals with worsening kidney function. Since our patient demonstrated renal compromise, appropriate substitution with liposomal amphotericin was made during his second hospital stay. According to Infectious Disease Society of America, patients with kidney disease can be started with flucytosine and lipid formulations of amphotericin B (3-4 mg/kg/day IV) for initial induction (B-II) [16].

## Conclusion

Cryptococcal cellulitis is an uncommon cutaneous manifestation of disseminated cryptococcosis, which is often mistaken for bacterial cellulitis, especially in the immunocompromised. Initial resistance to treatment with antibiotics should lead to search for an opportunistic fungal species. Because of the mortality associated with disseminated cryptococcosis, *C neoformans* is an important organism to consider in the setting of an immunosuppressed individual presenting initially with cellulitis. Skin biopsy, tissue culture, and cryptococcal antigen titers can be utilized to help establish an early diagnosis with improved outcome.

## References

1. Neville S, Dromer F, Morin O, et al. Primary cutaneous cryptococcosis: a distinct clinical entity. *Clin Infect Dis*. 2003;36(2):337-347. [PMID: 12539076]
2. Pau M, Lallai C, Aste N, Aste N, Atzori L. Primary cutaneous cryptococcosis in an immunocompetent host. *Mycoses*. 2010;53(3):256-8. [PMID: 19389063]
3. Dora JM, Kelbert S, Deutschendorf C, et al. Cutaneous cryptococcosis due to *Cryptococcus gattii* in immunocompetent hosts: case report and review. *Mycopathologia*. 2006;161(4):235-8. [PMID:16552487]
4. Hall JC, Brewer JH, Crouch TT, Watson KR. Cryptococcal cellulitis with multiple sites of involvement. *J Am Acad Dermatol*. 1987;17(2 Pt 2):329-32. [PMID: 3305608]
5. Sun HY, Alexander BD, Lortholary O, et al. Cutaneous cryptococcosis in solid organ transplant recipients. *Med Mycol*. 2010;48(6):785-91. [PMID: 20100136]
6. Probst C, Pongratz G, Capellino S, et al. Cryptococcosis mimicking cutaneous cellulitis in a patient suffering from rheumatoid arthritis: a case report. *BMC Infect Dis*. 2010;10:239. [PMID: 20699010]
7. Inoue Y, Onoda M, Aihara M, Koiwa K, Yamane Y, Ikezawa Z. Cryptococcal cellulitis in a patient with myelodysplastic syndrome. *Acta Derm Venereol*. 2011;91(2):199-200. [PMID: 21103838]
8. Ramos L, López C, Gómez C, Mathurín S, Mateo A. Case report. Cutaneous cryptococcosis in a patient with systemic erythematous lupus. *Mycoses*. 2001;44(9-10):419-21. [PMID: 11766110]
9. Hafner C, Linde HJ, Vogt T, et al. Primary cutaneous cryptococcosis and secondary antigenemia in a patient with long-term corticosteroid therapy. *Infection*. 2005;33(2):86-9. [PMID: 15827877]
10. Schupbach CW, Wheeler CE, Briggaman RA, Warner NA, Kanof EP. Cutaneous manifestations of disseminated cryptococcosis. *Arch Dermatol*. 1976;112(12):1734-1740. [PMID: 1008564]
11. Anderson DJ, Schmidt C, Goodman J, et al. Cryptococcal disease presenting as cellulitis. *Clin Infect Dis*. 1992;14(3):666-672. [PMID: 1562658]
12. Sugiura K, Sugiura N, Yagi T, et al. Cryptococcal cellulitis in a patient with bullous pemphigoid. *Acta Derm Venereol*. 2013;93(2):187-8. [PMID: 22688836]
13. Lafleur L, Beaty S, Colome-grimmer MI, Laforte RA, Dotson AD. Cryptococcal cellulitis in a patient on prednisone monotherapy for myasthenia gravis. *Cutis*. 2004;74(3):165-70. [PMID: 15499758]
14. Krywonis N, Kaye VN, Lynch PJ. Cryptococcal cellulitis in congenital lymphedema. *Int J Dermatol*. 1990;29(1):41-4. [PMID: 2184141]
15. Gupta RK, Khan ZU, Nampoory MR, Mikhail MM, Johny KV. Cutaneous cryptococcosis in a diabetic renal transplant recipient. *J Med Microbiol*. 2004;53(Pt 5):445-9. [PMID: 15096556]
16. Perfect JR, Dismukes WE, Dromer F, et al. Clinical practice guidelines for the management of cryptococcal disease: 2010 update by the infectious diseases society of America. *Clinical Infectious Diseases*. 2010;50(2):291-322. [PMID: 20047480]