

UC San Diego

UC San Diego Previously Published Works

Title

Bilateral abducens nerve palsy due to septic thrombophlebitis

Permalink

<https://escholarship.org/uc/item/2j36j03m>

Authors

Vu, Vincent N
Savino, Peter J
Robbins, Shira L

Publication Date

2019-12-01

DOI

10.1016/j.ajoc.2019.100566


Peer reviewed



ELSEVIER

Contents lists available at ScienceDirect

American Journal of Ophthalmology Case Reports

journal homepage: www.elsevier.com/locate/ajoc

Case report

Bilateral abducens nerve palsy due to septic thrombophlebitis

Vincent N. Vu^{a,*}, Peter J. Savino^{a,b}, Shira L. Robbins^a^a *Ratner Children's Eye Center at the University of California San Diego, 9415 Campus Point Drive, La Jolla, CA, USA*^b *The Neuro-ophthalmology Service, The Shiley Eye Institute, University of California, 9415 Campus Point Drive, La Jolla, CA, USA*

ARTICLE INFO

Keywords:

Lemierre syndrome
Septic thrombophlebitis
Abducens nerve
Sixth cranial nerve

ABSTRACT

Purpose: To report a case of septic thrombophlebitis producing bilateral abducens nerve palsy.**Observation:** A 65 year-old woman with recent sinus surgery experienced the onset of horizontal diplopia during treatment for bacteremia. Computer tomography of head and a neck ultrasonography showed right internal jugular vein occlusion. Ophthalmology examination was consistent with bilateral abducens nerve palsy. She was treated with systemic antibiotics and antiplatelet therapy with resolution of the internal jugular vein occlusion. The diplopia improved over a six-months.**Conclusion and importance:** Our patient had Lemierre syndrome with an unusual presentation. The patient was treated for septic thrombophlebitis with a resolution of her ocular symptoms.

1. Introduction

Lemierre syndrome is septic thrombophlebitis of the internal jugular vein. The most common presentation is sore throat, neck mass, and neck pain. Ocular and neuro-ophthalmological presentations of Lemierre are rare.¹ We are reporting the clinical presentation and management of bilateral abducens nerve palsy in Lemierre syndrome.

2. Case report

A 65-year-old woman was referred to University of California, San Diego, Neuro-ophthalmology for evaluation of horizontal and vertical diplopia after having undergone multiple sinus procedures for recurrent sinusitis of the sphenoid sinus. She was admitted twice within a week for complications of streptococcus intermedius bacteremia. Because of fever and neck/jaw stiffness, she was evaluated with computer tomography of head and a neck ultrasonography (U/S) which showed a filling defect of the right jugular vein (Figs. 1 and 2). Lumbar puncture showed a cerebrospinal fluid (CSF) with an elevated white blood cell count of 369mm³ (reference range: 0–10mm³) that was consistent with meningitis. CSF cell count and differential showed 87% neutrophils, 4% lymphocytes, and 9% macrophages. Meningitis and encephalitis nucleic acid detection test of the CSF was negative for any pathogen. However, no opening pressure was documented. She was treated with multiple systemic antibiotics (ceftriaxone, ampicillin, vancomycin, zosyn, and ertapenem), oral anticoagulation (rivaroxaban) and sinus debridement. Her diplopia developed prior to her first admissions for treatment of

streptococcus intermedius bacteremia.

Visual acuity was 20/20 in each eye. She denied any symptoms of headache, transient vision loss, pulsatile tinnitus, nausea or vomiting. She had no relative afferent pupillary defect, normal intraocular pressures and normal color vision by Ishihara color testing. Optic nerve examination showed no current papilledema, pallor, and no signs of old papilledema. Extraocular muscle movements showed a minor limitation of abduction in both eyes. Prism cover test showed an esotropia at distance of 20–25 prism diopters (PD) and a right hypertropia of 2PD. Prism cover test at near measured 14PD. The esotropia increased to 35PD on right and left gaze and decreased at near, which is consistent with bilateral abducens nerve palsies. She was treated for her diplopia with temporary press-on prism (25PD base out left eye and 2PD base down right eye). During her follow up visits, she required less temporary press-on prisms to relieve her symptoms of diplopia.

Repeat U/S at 3 months showed normal flow in the internal jugular vein (Fig. 3). Rivaroxaban was discontinued after 3 months. Her final deviation 6 months after initial presentation was an esophoria of 2PD at distance and orthophoria on near gaze.

3. Discussion

In 1936, Andre Lemierre published 20 cases of anaerobic septicemia and septic thrombophlebitis that lead to the death of 18 patients. Lemierre syndrome is diagnosed with a history of oropharyngeal infection, radiological evidence of internal jugular vein thrombosis, and isolated anaerobic pathogens. The most common anaerobic pathogen is

* Corresponding author. 9415 Campus Point Drive, La Jolla, CA 92093, USA.
E-mail address: vnu1984@gmail.com (V.N. Vu).

<https://doi.org/10.1016/j.ajoc.2019.100566>

Received 27 June 2018; Received in revised form 3 October 2019; Accepted 27 October 2019

Available online 31 October 2019

2451-9936/© 2019 The Authors. Published by Elsevier Inc. This is an open access article under the CC BY-NC-ND license (<http://creativecommons.org/licenses/by-nc-nd/4.0/>).

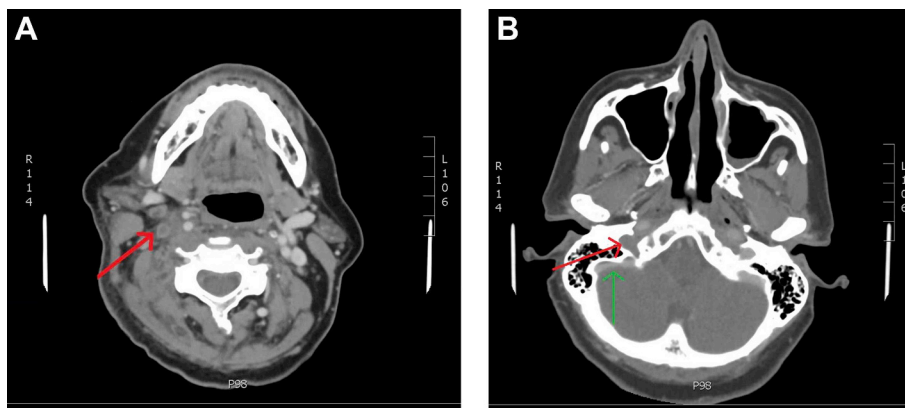


Fig. 1. Sagittal CT scan A. Filling defect of right internal jugular vein (red arrow). B. Filling defect extending to right transverse (red arrow) and sigmoid sinuses (green arrows). (For interpretation of the references to color in this figure legend, the reader is referred to the Web version of this article.)

Fusobacterium necrophorum.² Lemierre syndrome also has been caused by *Streptococcus* or *Staphylococcus*.³

The most common presentation of Lemierre syndrome is sore throat followed by neck pain and a neck mass. We could find only 4 cases with diplopia reported in the literature.^{4,6–8} Uveitis, vitreous hemorrhage, and sigmoidal sinus thrombosis leading to superior ophthalmic vein elongation have all been reported associations of Lemierre syndrome.⁵

Our patient displays an uncommon cause of abducens palsies. She meets the diagnostic criteria for Lemierre syndrome which includes positive blood cultures for *Streptococcus intermedius* and imaging evidence of internal jugular venous thrombophlebitis.

Paralysis of the abducens nerve is the most common palsy to affect extraocular movements. The most common reported etiology is vascular disease. Other causes include mass affect from neoplasm, viral infections, elevated intracranial pressure, brain stem lesions, meningitis, carotid cavernous fistula, and hydrocephalus.⁵

Gradenigo Syndrome typically presents as otitis media, ipsilateral abducens nerve palsy, and facial pain.⁹ Inflammation of the temporal bone with transverse sinus involvement can lead to elevated intracranial pressure and thus abducens involvement. This condition is almost always unilateral. Given the patient did not have symptoms of otitis media, did not report facial pain during the course of the disease and had bilateral abducens palsies Gradenigo Syndrome is unlikely.

The exact mechanism of our patient's bilateral abducens nerve palsy is unclear. The patient had internal jugular venous thrombophlebitis on the right side that extended to the right cavernous sinus. During examination it appeared the cranial nerve VI on the right side was more affected than the left. Unfortunately, there was no opening pressure documented and magnetic resonance imaging was performed.

Management for Lemierre disease is typically aggressive antibiotic and antiplatelet therapy.¹⁰ Diplopia management due to abducens nerve palsy should be conservative as there may be marked improvement with medical treatment. Our patient was managed with

temporary press-on prisms with decreasing power as needed.

4. Conclusion

This case report details bilateral abducens nerve palsy, an unusual presentation of Lemierre syndrome. The palsy resolved after a multidisciplinary approach to treatment of the underlying cause through antibiotics, surgical management of sinus disease, and antiplatelet therapy. The diplopia was conservatively managed with temporary press-on prisms. After a few months, the patient's diplopia improved. Aside from the mild prism spectacles when driving, the patient resumed her usual active lifestyle with no other symptoms.

Patient consent

Consent to publish this case report has been obtained from the patient(s) in writing.

Funding

SLR and PJS were supported in part by an unrestricted grant from Research to Prevent Blindness, New York, N.Y.

Authorship

All authors attest that they meet the current ICMJE criteria for Authorship.

Declaration of competing interest

The following authors have no financial disclosures: VNV, PJS, SLR.

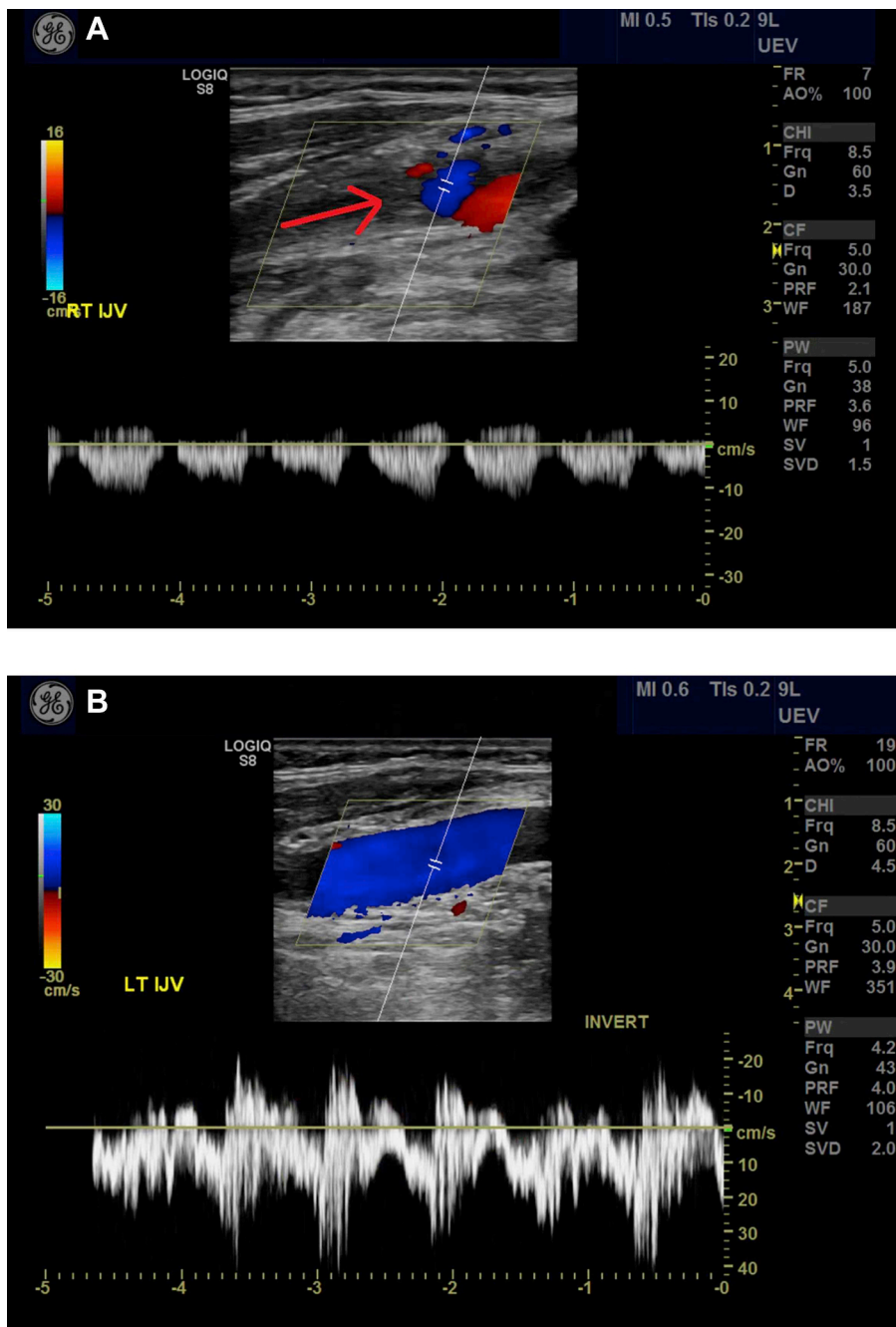


Fig. 2. Neck Ultrasound A. Right internal jugular vein with near-occlusion (red arrow). B. Left internal jugular vein with normal flow. (For interpretation of the references to color in this figure legend, the reader is referred to the Web version of this article.)

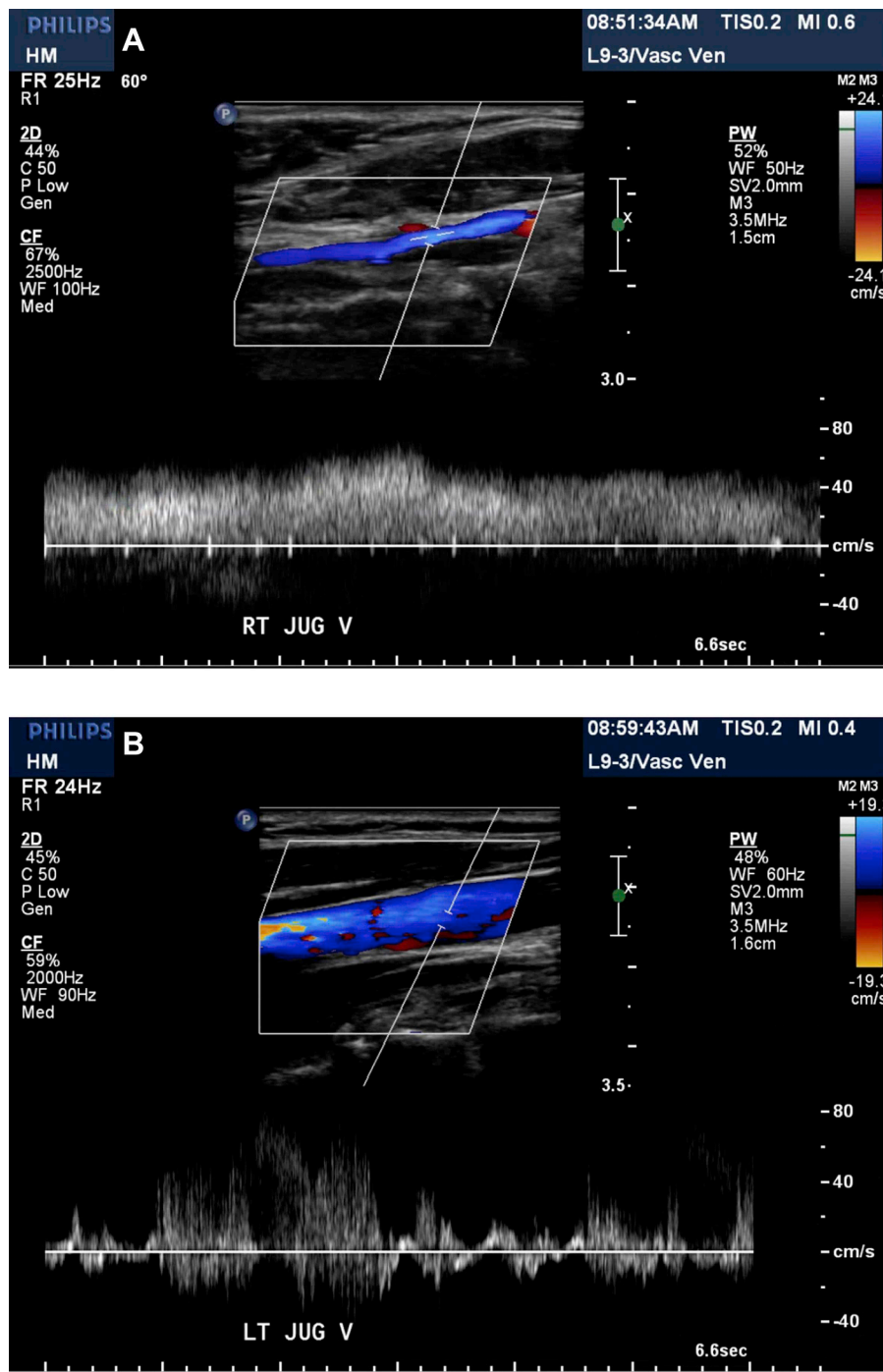


Fig. 3. Neck Ultrasound A. Right internal jugular vein with normal flow. B. Left internal jugular vein with normal flow.

Acknowledgements

None.

Appendix A. Supplementary data

Supplementary data to this article can be found online at <https://doi.org/10.1016/j.ajoc.2019.100566>.

References

1. Karkos PD, Asrani S, Karkos CS, et al. Lemierre's syndrome: a systematic review. *The Laryngoscope*. 2009;119(8):1552–1559.
2. Lemierre A. On certain septicemias due to anaerobic organisms. *Lancet*. 1936;1:701–703.
3. Martel A. Septic thrombosis of cavernous sinus extended to the ipsilateral internal jugular vein and transversal sinus with favorable outcome: clinical and radiological features of a Lemierre syndrome. *Orbit*. 2018;37(2):94–96.
4. Olson KR, Johnson JM, Branda JA. Case 36-2014: an 18-year-old woman with fever, pharyngitis, and double vision. *N Engl J Med*. 2014;20(21):2018–2027 371.

5. Rush JA, Younge BR. Paralysis of cranial nerves III, IV, and VI: cause and prognosis in 1,000 cases. *Arch Ophthalmol*. 1981;99(1):76–79.
6. Takahashi S, Ito S, Tagashira S, Yasui K, Watanabe Y, Nakajima K. A case of corticosteroid-response Lemierre Syndrome with clivus osteomyelitis and a mass in the cavernous sinus-supraseallar region. *Rinsho Shinkeigaku*. 2015;55(5):327–332.
7. Shibuya K, Igarashi S, Sata T, Shinbo J, Sato A, Yamazaki M. Case of Lemierre syndrome associated with infectious cavernous sinus thrombosis and septic meningitis. *Rinsho Shinkeigaku*. 2012;52(10):782–785.
8. Krishna K, Diwan AG, Gupt A. Lemierre's syndrome—the syndrome quite forgotten. *J Assoc Phys India*. 2012;60:60–63.
9. Valles JM, Fekete R. Gradenigo syndrome: unusual consequence of otitis media. *Case Rep Neurol*. 2014;6(2):197–201.
10. Johannesen KM, Bodtger U. Lemierre's syndrome: current perspective on diagnosis and management. *Infect Drug Resist*. 2016;9:221–227.