UC Davis
UC Davis Previously Published Works

Title

Society of Family Planning Committee Statement: Management and removal of deep and nonpalpable contraceptive implants

Permalink

https://escholarship.org/uc/item/2ns0691h

Journal

Contraception

ISSN

0010-7824

Authors

Castaño, Paula M
Creinin, Mitchell D
Eisenberg, David L
et al.

Publication Date

2026-08-01

DOI

10.1016/j.contraception.2026.111567

Peer reviewed

eScholarship.org Powered by the California Digital Library
University of California

ARTICLE IN PRESS

Contraception xxx (xxxx) xxx

Contents lists available at ScienceDirect

Contraception

journal homepage: www.elsevier.com/locate/contraception

Society of Family Planning Committee Statement: Management and removal of deep and nonpalpable contraceptive implants☆,☆☆

Paula M. Castaño [a,*], Mitchell D. Creinin [b], David L. Eisenberg [c], Mark Hathaway [d], Lisa G. Hofler [e], Neena Qasba [f], Sarita Sonalkar [g], Rachel Steward [h], on behalf of the Clinical Affairs Committee

[a] Columbia University Irving Medical Center, 622 W 168th St., PH 16-69, New York, NY 10032, United States
[b] University of California, Davis, Sacramento, CA, United States
[c] Washington University in St. Louis School of Medicine, Mailstop, St. Louis, MO, United States
[d] Carafem, Washington, DC, United States
[e] University of New Mexico Department of Obstetrics and Gynecology, New Mexico, NM, United States
[f] University of Connecticut School of Medicine, Farmington, CT, United States
[g] University of Pennsylvania, Penn Medicine, University City, Philadelphia, PA, United States
[h] FPA Women's Health, Los Angeles, CA, United States

ARTICLE INFO

Article history:
Received 28 December 2025
Received in revised form 13 July 2026
Accepted 21 July 2026

Keywords:
Contraceptive implant
Deep
Nonpalpable
Referral
Ultrasonography

ABSTRACT

This Committee Statement provides evidence-informed, person-centered guidance to optimize the identification, evaluation, management, and removal of deep and nonpalpable contraceptive implants. This guidance applies to clinicians removing the implants themselves or facilitating timely referral for removal. Appropriate referral includes a Center of Experience in the U.S. or similar tertiary experts outside the U.S. We discuss preventing the need for deep and nonpalpable implant removal by following proper subdermal placement techniques. When approaching removal of deep and nonpalpable implants, we recommend following a standardized protocol that addresses localization, positioning, marking the contraceptive implant location and measuring the depth, the necessary instruments, and removal techniques. When removing multi-rod contraceptive implants, we recommend that clinicians confirm both the number and location of the rods and adjust their removal approach accordingly. Finally, we discuss using the most appropriate diagnostic and procedural codes for deep or nonpalpable contraceptive implant removal services.

© 2026 Elsevier Inc. All rights are reserved, including those for text and data mining, AI training, and similar technologies.

☆ Conflicts of interest: Paula M. Castaño, MD, MPH reports receiving contraceptive research funding from Bayer Pharmaceuticals, Organon, and the Eunice Kennedy Shriver National Institute of Child Health and Human Development (NIH/NICHD). She has served as a consultant for Bayer Pharmaceuticals and as an instructor for the Organon CTP. Mitchell D. Creinin, MD has received speaking honoraria from Gedeon Richter and Mayne; served on Advisory Boards for Estetra SRL; holds stock options with Femasys, and has consulted for Bayer Pharmaceuticals, Gedeon Richter, Mayne, Medicines360, and Merck Sharp & Dohme. The Department of Obstetrics and Gynecology at the University of California, Davis, receives contraceptive research funding for Dr. Creinin from Femasys, Organon, Sebela, Sumitomo Pharma, the Society of Family Planning, and NIH/NICHD. David L. Eisenberg, MD, MPH has served as a consultant and on advisory boards for Medicines360, Merck & Co, Organon, Sebela, and Femasys. He has received honoraria from Omnia Education. His university department receives contraceptive research funding from Merck & Co., Sumitomo Pharma, the Society of Family Planning, and NIH/NICHD. Mark Hathaway, MD, MPH has received speaking honoraria from Bayer Pharmaceuticals and serves as an instructor for the Organon CTP. Lisa G. Hofler, MD, MPH, MBA serves as an instructor for the Organon CTP. Neena Qasba, MD, MPH reports no disclosures. Sarita Sonalkar, MD, MPH has received research funding from Sumitomo Pharma and is a consultant for the World Health Organization. Rachel Stewart, MD, MSc reports serving as a consultant for Bayer Pharmaceuticals and as an instructor for the Organon CTP.

☆☆ Funding: The Society receives no direct support from pharmaceutical companies or other industries to produce Committee Statements. This research did not receive any specific grant from funding agencies in the public, commercial, or not-for-profit sectors.

Disclaimer: This publication is designed as a resource to assist clinicians in providing family planning care. It should not be considered inclusive of all proper treatments or serve as the standard of care. It is not intended to substitute for the independent professional judgment of the treating clinician. Variations, taking into account individual circumstances, may be appropriate. This publication reflects the best available evidence at the time of publication, recognizing that continued research or major changes in the practice environment may impact future recommendations and should be evaluated for incorporation into care. Clinical guidance, grounded in evidence-based research, is distinct from legal requirements and restrictions governing family planning care. Medical recommendations do not vary based on practice location. However, abortion is not legal in all states and circumstances, and this document is not intended to aid in unlawful care. Any updates to this document can be found at https://societyfp.org/clinical/clinical-guidance-library/. The Society and its contributors provide the information contained in this publication "as is" and without any representations or warranties, express or implied, of any kind, whether of accuracy, reliability, or otherwise.

* Corresponding author.
E-mail address: pc2137@cumc.columbia.edu (P.M. Castaño).

https://doi.org/10.1016/j.contraception.2026.111567
0010-7824/© 2026 Elsevier Inc. All rights are reserved, including those for text and data mining, AI training, and similar technologies.

Please cite this article as: P.M. Castaño, M.D. Creinin, D.L. Eisenberg et al., Society of Family Planning Committee Statement: Management and removal of deep and nonpalpable contraceptive implants, Contraception, https://doi.org/10.1016/j.contraception.2026.111567

1. Background

The contraceptive implant is a progestin-only, long-acting reversible implant primarily used to prevent pregnancy, although it also benefits persons with gynecologic conditions [1,2]. It is available globally with differing characteristics (Table 1). The only US Food and Drug Administration (FDA) approved and marketed contraceptive implant is the etonogestrel (ENG) 68 mg Nexplanon®, which is approved for five years of pregnancy prevention [3]. Globally, the ENG 68 mg contraceptive implant is also known as Implanon NXT®; two-rod levonorgestrel (LNG) 150 mg contraceptive implants (Jadelle® and Sino-implant II™/Levoplant™) are also available. The ENG 68 mg contraceptive implant is a radiopaque, cylindrical rod-shaped implant typically placed subdermally in the inner aspect of the non-dominant upper arm. The implant consists of an ethylene vinyl acetate copolymer containing 68 mg of ENG and 15 mg of barium sulfate for radiographic identification. LNG contraceptive implants consist of similarly-sized silicone tubes containing crystalline LNG cores.

FDA approval of the ENG 68 mg contraceptive implant required a mandatory clinical training program (CTP) to order the implant. The manufacturer-run training session reviews the prescribing information, trains proper placement and removal techniques, and requires participants to place and remove the contraceptive implant in a model arm [4]. In 2026, this requirement was elevated through a Risk Evaluation and Mitigation Strategy due to the risk of complications from improper insertion and removal [3]. Most contraceptive implants can be removed using standard removal techniques demonstrated during the CTP and honed with experience.

If a contraceptive implant is placed more deeply than recommended or in an incorrect location, or has migrated significantly, it may not be fully palpable, and localization and removal can be challenging. Removals of deep and nonpalpable contraceptive implants require care from a clinician experienced in this type of removal. To this end, the US pharmaceutical manufacturer established a Centers of Experience (COE) program to facilitate referrals to clinicians who specialize in locating and removing deep or nonpalpable contraceptive implants. The Society of Family Planning (the Society) developed standards and qualifications that clinicians must meet to be listed as COE and hosts the publicly searchable directory [5].

1.1. Epidemiology

Among 15- to 49-year-olds who used contraception in the U.S. from 2022 to 2023, 4.5% used the contraceptive implant [6]. In adolescents aged 15–19 years, from 2015 to 2019, ever use of the contraceptive implant was 13% [7]. Worldwide, the United Nations Population Division estimates that 2.6% of 15- to 49-year-olds (25 million people capable of pregnancy) used a contraceptive implant in 2021. Global contraceptive implant use varies greatly. It is the predominant method in five sub-Saharan African countries, where 33%–47% of 15- to 49-year-olds use it [8].

The true incidence of deep or nonpalpable contraceptive implants is unknown, but cohort studies suggest it is rare. Reports (n = 20,497) from 4294 clinicians who completed the CTP from 2006 to 2011, describe deep adipose or intramuscular placement occurring at a rate of 1.56 per 1000 placements [9]. The Nexplanon Observational Risk Assessment cohort study followed 7364 placements from 2011 to 2017 and found deep placement – defined as nonpalpable contraceptive implants, intrafascial or intramuscular contraceptive implants, or injury to nerves or vessels – to be uncommon (n = 65, 8.8 per 1000 placements; 95% CI, 6.8–11.2) [10].

Factors associated with difficult removals include a nonpalpable contraceptive implant immediately after placement, weight gain since placement, and longer duration of use [11–13]. Nonpalpable contraceptive implants are more likely to be subfascial in persons with a body mass index (BMI) of less than 30 kg/m^2 (71%) compared with those with a BMI of 30 kg/m^2 or greater (8%) and placement during a removal–replacement procedure through the same incision [14].

1.2. Access

Facilitating access to timely removal of contraceptive implants whenever requested is a matter of health equity and person-centered care, regardless of personal biases or preferences. Clinicians should reassure individuals requesting removal that this service will be provided or promptly facilitated and that it is not dependent on additional contraceptive counseling or method selection. Factors contributing to wishes for contraceptive discontinuation may not be fully apparent and requests should be respected and honored without pressure or bias [15]. This practice must be grounded in the history and discourse surrounding coerced permanent contraception and contraceptive implants. Coercive contraceptive practices have disproportionately affected people of color, with disabilities, experiencing socioeconomic marginalization, involved in the legal or carceral systems, and in immigrant communities [16–18]. The legacy of legislative attempts to incentivize or mandate contraceptive implant use [19] has contributed to a collective and generational erosion of trust in contraceptive implants. To promote reproductive justice and personal autonomy, equitable access to timely removal by skilled clinicians with the needed resources is critical [15,20,21].

The spectrum of clinical skill, equipment, and resources across the US and globally potentially affects equitable access to deep or nonpalpable contraceptive implant removal. While most removals can occur in an outpatient setting, people in low-resource areas may face multiple referrals before locating a clinician skilled in removal of deep or nonpalpable contraceptive implants [12,22]. Clinicians referring to a COE [5], similar tertiary expert outside the U.S., or a subspecialist should be aware of and attempt to mitigate barriers that can impede timely removal:

- Insurance coverage:
  - o Referral to higher-level care facilities may be cost-prohibitive.

Table 1
Characteristics of progestin-only contraceptive implants that clinicians may encounter [37,58]

Name	Formulation	# of rods	Rod dimensions	Approved duration of use (years)	Worldwide availability	Radiopaque on X-ray
Nexplanon®/Implanon NXT®	ENG 68 mg	1	4 cm x 2 mm	3–5	2010-present (US and outside the US)	Yes
Jadelle®	LNG 150 mg (75 mg/rod)	2	4.3 cm x 2.5 mm	5	1996-present (US, never marketed) 2007-present (outside the US)	Yes
Sino-implant II™/ Levoplant™	LNG 150 mg (75 mg/rod)	2	4.4 cm x 2.4 mm	3–4	2017-present (outside the US)	Yes
Implanon®	ENG 68 mg	1	4 cm x 2 mm	3	Off-market: 2006–2012 (US) 1998–2012 (outside the US)	No
Norplant®	LNG 216 mg (36 mg/rod)	6	3.4 cm x 2.4 mm	5	Off-market: 1990–2002 (US) 1983–2008 (outside the US)	No

ENG, etonogestrel; LNG, levonorgestrel; US, United States.

- o People relying on postpartum Medicaid may experience coverage lapses after a certain period, leaving them uninsured for higher-level contraceptive care.
- Logistical hurdles: transportation, time away from work, childcare
- Adolescent-specific: Adolescents frequently rely on health care coverage under their parents. Higher-level care could disclose confidential contraceptive use to the guarantor. Adolescents are also particularly vulnerable to any additional costs, whether time or financial.

1.3. Counseling

When counseling a person seeking deep or nonpalpable implant removal, clinicians should facilitate informed decision-making by (1) determining the duration of use and evaluating whether the contraceptive implant is effectively preventing pregnancy, noting that a deep or nonpalpable location is not expected to affect contraceptive efficacy; (2) reviewing pregnancy risk and offering additional contraceptive methods, if indicated and desired; (3) counseling about potential risks and outcomes of the removal procedure; and (4) counseling about a replacement procedure, if desired, including options for synchronous and sequential procedures.

A trauma-informed care approach should be applied during counseling and procedural care for contraceptive implant removal [23]. Clinicians should not underestimate the pain patients experience and allow autonomy in the management of pain and anxiety [24].

2. Committee statements

2.1. Clinicians can minimize the need for deep and nonpalpable implant removal by following proper subdermal placement techniques

Training, mentorship, and experience with proper subdermal contraceptive implant placement are associated with easier removals and fewer cases requiring deep or nonpalpable removal [11,12,25]. Ideal contraceptive implant location is immediately subdermal, between the dermis and subcutaneous tissue. Proper placement is accomplished by visualizing the inserter needle movement under the skin [3]. Proper technique minimizes risk of neurovascular complications and intramuscular placement, which can lead to injury or migration. After a 2018 change in ENG implant insertion site to overlie the triceps muscle, and mandatory retraining of clinicians, reports of implant migrations to the pharmaceutical global pharmacovigilance database, subject to reporting bias, decreased by 74% from 2018 to 2024 [26].

Given the association between subfascial implant location and either implant replacement or BMI of less than 30 kg/m^2 (likely a proxy for low adipose tissue), clinicians should be particularly attentive to achieving immediately subdermal contraceptive implant placement between the dermis and subcutaneous tissue in people with lower BMI and during contraceptive implant exchange [12,24]. However, overcompensation with too-superficial placement in the epidermis can cause discomfort to sensory nerve fibers.

2.2. Clinicians who remove contraceptive implants should be aware of the anatomy of the upper arm

Clinicians should consider the variation and complexity of arm anatomy before attempting removal, particularly the proximity of the brachial artery, ulnar and median nerves, medial antebrachial cutaneous nerve, other nerve branches, and basilic vein. Contraceptive implants placed in the US before the 2018 placement location change or located near the sulcus between the biceps and triceps are more likely to be close to neurovascular structures. Despite the change in recommended placement location, the potential for neurovascular injury exists when the contraceptive implant is placed too deep or during a removal attempt. Nerve damage during contraceptive implant removal could lead to temporary or prolonged sensory loss, neuroma formation, and chronic neuropathic pain (see Section 2.8) [27].

2.3. Clinicians should attempt to determine the type of contraceptive implant the person seeking removal has in place

Clinicians should ask the person seeking removal about the type of contraceptive implant, the number of rods placed, and the placement date. This information guides appropriate localization and removal techniques and confirms all rods are removed. Characteristics from Table 1 can narrow the possible options.

2.4. Clinicians considering deep or nonpalpable contraceptive implant removal should conduct a review of previous removal attempts to guide the removal strategy

A review includes noting the techniques used, the outcomes of those attempts, any complications experienced, and the time elapsed since the last removal attempt. After prior unsuccessful removal attempts, clinicians may need to delay the next attempt at least 2 weeks until inflammation and edema have resolved, use specialized techniques, or refer to a COE [5]. Understanding these factors will help mitigate any potential for injuring neurovascular structures or creating unnecessarily large scars [27,28].

2.5. Clinicians considering deep or nonpalpable contraceptive implant removal should follow a standardized protocol that addresses localization, positioning, marking the contraceptive implant location and measuring the depth, and necessary instruments and removal techniques

2.5.1. Localization

2.5.1.1. Clinicians should first evaluate the contraceptive implant location via palpation and confirm they feel comfortable attempting standard removal. If not, they should promptly seek supervision by a clinician experienced in deep or nonpalpable implant removal or refer to an experienced clinician, such as a COE. To evaluate the contraceptive implant location, ask the person seeking removal whether they can palpate the implant and to demonstrate its suspected location. Reviewing medical records related to placement, visual inspection, and palpation of both arms may further aid in locating the implant. Palpation typically characterizes implant location. If the contraceptive implant is subdermal and the entire length, including both ends, is mobile and palpable, removal can proceed using standard techniques. Even contraceptive implants encased in fibrous tissue can be dissected to allow for successful removal with a standard approach.

Deep implants may be partially localized by palpation or may be completely nonpalpable. Experienced clinicians may feel comfortable proceeding with standard removal when they can palpate only one end of the implant with certainty. Clinicians inexperienced in more advanced implant removal techniques should not attempt to remove deep or nonpalpable contraceptive implants without localization and direct supervision by an experienced clinician. Referral to a clinician experienced in deep or nonpalpable contraceptive implant removals is also reasonable.

Early referral to either a COE [5] or specialist with deep or nonpalpable contraceptive implant removal experience is essential to facilitate person-centered care. Attempting removal may risk failure and delay timely removal under the care of an experienced clinician. Case reports and series demonstrate that one-quarter to one-half of persons referred for deep or nonpalpable contraceptive implant

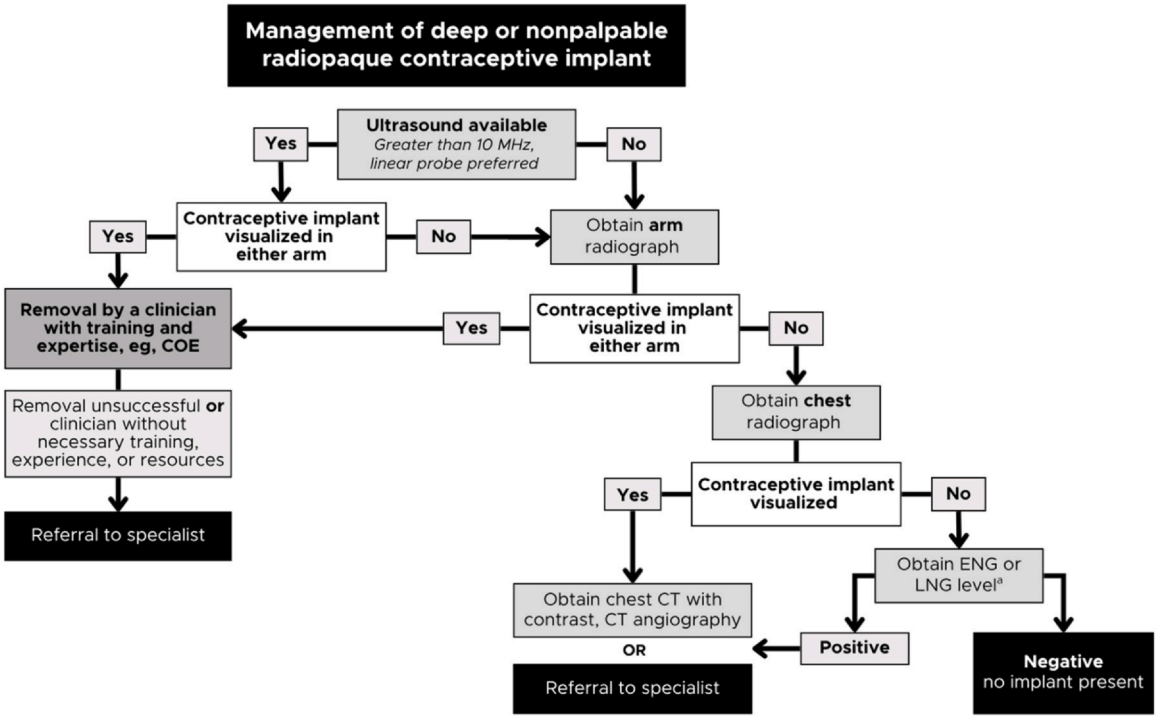

Fig. 1. Algorithm for localization of radiopaque contraceptive implant. COE, Center of Experience; CT, computerized tomography; ENG, etonogestrel; Implant, contraceptive implant; LNG, levonorgestrel; US, ultrasonography. [a]Use of related hormonal contraceptives must be excluded.

removal have prior failed removal attempts [14,29,30], sometimes creating disfiguring scars located far from the actual contraceptive implant location [28]. Clinicians who attempt removal of deep or nonpalpable contraceptive implants without the necessary resources and training delay care, risk the safety of the person seeking removal, and contribute to mistrust of the health care system.

Rarely, even COE clinicians cannot localize or remove a contraceptive implant, either because of a location distant from placement (eg, pulmonary) or proximity to neurovascular structures. Infrequent scenarios (eg, active infection) may make outpatient removal too risky, even for experts in deep and nonpalpable implant removals. COE clinicians should be able to refer to radiology practices for imaging support [31]; surgeons experienced in upper extremity procedures for removals near neurovascular structures [27,31,32]; neurologists or neurosurgeons for suspected nerve injury before, during, or after removal (see Section 2.8); and thoracic interventional radiologists or surgeons for suspected migration to pulmonary structures [31].

2.5.1.2. Whenever feasible, clinicians with expertise in localizing deep or nonpalpable contraceptive implants should assist surgeons in the operating room with contraceptive implant location to help mitigate additional risks. While outpatient removal has many advantages, sometimes persons request removal under sedation or clinicians prefer removal in an operating room. When clinicians refer to specialized surgeons for management, operating room procedures may include fluoroscopic localization and an incision which is larger than advised in an outpatient setting. Implant users that require operating room removals, especially for subfascial contraceptive implants, may face greater morbidity from anesthetic risk, larger incisions, and nerve injury [9,14,28–30,32–34].

2.5.1.3. Clinicians attempting to identify the location of a deep or nonpalpable contraceptive implant should be familiar with available radiologic equipment and understand how different imaging modalities can locate different types of contraceptive implants, even if not performing the localization themselves. If clinicians cannot palpate either end of the contraceptive implant in either arm with certainty, or the placement scar is not visible and an alternate placement location is excluded (see Section 2.5.1.4); they should perform or obtain imaging to confirm location prior to removal attempt. Appropriate radiologic evaluation can help determine the location of an implant that is only partially palpable or nonpalpable, as palpation alone cannot determine if an implant is subdermal, deeper within subcutaneous adipose tissue, or in suprafascial, intrafascial, or subfascial (intramuscular) locations. Radiologic evaluation ascertains whether nonpalpable implants are located adjacent to neurovascular structures or have migrated away from the initial placement area. Migration can be more substantial with subfascial placement due to muscle activity. Significant migration within the arm, described as more than 2 cm, is rare (1%) [35]. Once the contraceptive implant location is identified, the imaging information can help determine the ideal setting (eg, outpatient practice versus surgical setting) and appropriate clinicians with experience in such removals.

Knowledge of contraceptive implant type and whether it is radiopaque (Table 1) determines the most useful imaging. Fig. 1 presents an algorithm for the localization of a deep or nonpalpable contraceptive implant.

Ultrasonography. Ultrasonography is the first-line imaging modality for a deep or nonpalpable contraceptive implant because it is effective, low cost, and free of ionizing radiation. All types of contraceptive implants are visible with appropriate ultrasonography [36,37]. Successful ultrasonography requires a high-frequency linear array transducer (greater than 10 MHz), a technician or clinician with appropriate training in arm imaging to perform the scan, and a clinician with experience in contraceptive implant localization to interpret the images. High-frequency linear array transducers are not available on standard ultrasonography machines used for obstetrics and gynecology imaging. Multispecialty practices that provide thyroid or breast imaging may have access to the preferred transducers that optimize visualization of subdermal tissues. On

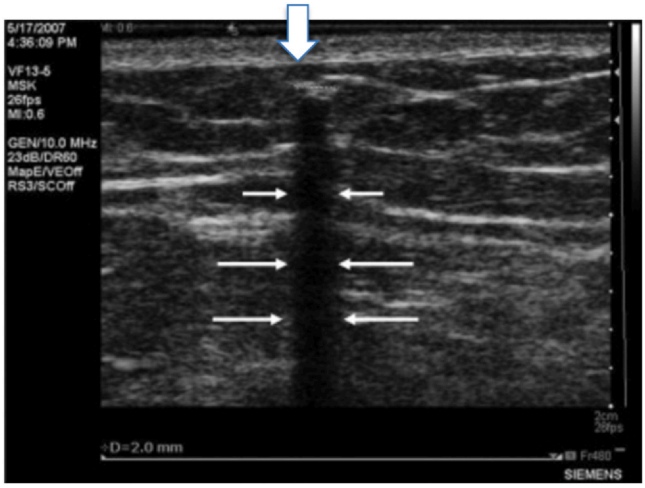

Fig. 2. Transverse ultrasonographic image through the implant. The implant appears as a hyperechoic structure (bold arrow) and is distinguished from surrounding anatomical structures by a sharp posterior acoustic shadow (narrow arrows) on the transverse scan [59]. Reprinted from Gurel, Kamil, Kaan Gideroglu, Ata Topcuoglu, Safiye Gurel, Ibrahim Saglam, and Sukru Yazar. 2012. "Detection and Localization of a Nonpalpable Subdermal Contraceptive Implant Using Ultrasonography: A Case Report." *Journal of Medical Ultrasound* 20 (1): 47–49. https://doi.org/10.1016/j.jmu.2012.01.005.

transverse ultrasonography, contraceptive implants appear as a hyperechoic structure with an acoustic shadow extending below (Fig. 2). Experienced clinicians may be able to locate contraceptive implants correctly placed between the dermis and subcutaneous tissue with lower frequency, curvilinear array, or even transvaginal transducers; scanning through a fluid-filled bag or glove or an ultrasound gel pad can enhance visibility with these transducers [38]. Higher frequency is required for deeper contraceptive implants.

The inner upper arm, or other contraceptive implant placement location (see Section 2.5.1.4), should be scanned in its entirety if the contraceptive implant is not found near the placement scar or suspected placement location, since a subfascial contraceptive implant can migrate during routine muscle movements. Ideally, ultrasonography should be performed with the probe placed transversely on the arm, moved systematically in overlapping sections, while looking for the posterior acoustic shadowing from the contraceptive implant (Fig. 2). Very deep contraceptive implants may not shadow, and only a bright echo may be visible. Viewing longitudinally (parallel with the contraceptive implant) can confirm implant visualization, but this is typically only possible with higher-frequency probes (15 MHz). Expertise in localizing deep and nonpalpable contraceptive implants ensures that the structure being visualized is the contraceptive implant and not hyperechoic lines from subcutaneous connective tissue (Fig. 3).

Unlike radiography, ultrasonography is able to demonstrate the depth from the epidermis and proximity to muscles. Arm extension and flexion during ultrasonography can make the contraceptive implant's proximity to muscles more evident. M-mode or color Doppler mode can identify nearby neurovascular structures affecting removal planning. When the contraceptive implant is located deeply, especially within muscle, clinicians should identify vessels along its length to assess the risk of significant bleeding during removal. If the implant is located deep to the fascial capsule of muscle, attempted removal may require a larger incision, more extensive dissection, and greater potential for bleeding and injury. Clinicians should assess their skill and experience and consider these factors when determining need for additional anesthesia, the most appropriate setting for removal, or referral to a COE or surgeon familiar with deep implant removals.

Radiograph. Radiography of one or both upper extremities only confirms the presence or absence of contraceptive implants that are radiopaque when ultrasonography is not readily available or is inconclusive.

Magnetic resonance imaging (MRI). If a contraceptive implant is not radiopaque, then ultrasonography or, as a last resort, MRI of the arm, should be used. Like ultrasonography, MRI can determine the contraceptive implant location, depth, and proximity to the surrounding structures. The MRI protocol should include T1 sequence in slices < =2 mm in sagittal and coronal planes to ensure adequate resolution and avoid fat suppression, which can make contraceptive implant identification difficult in subcutaneous fat or muscle [38].

Computed tomography (CT). CT imaging has limited utility compared with ultrasonography and MRI and exposes patients to ionizing radiation. Both MRI and CT can be difficult to obtain, costly, and require time and travel.

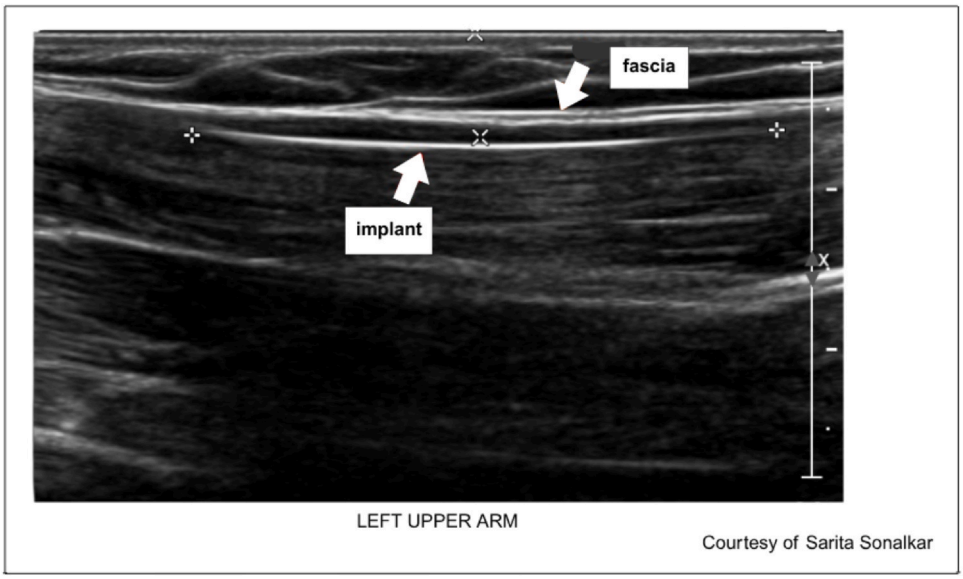

Fig. 3. Sagittal ultrasound of subfascial contraceptive implant. The distance between " + " symbols is the measured length of the contraceptive implant (approximately 4 cm). The distance between "x" symbols is the distance from the skin surface to the contraceptive implant (6 mm, in this example).

2.5.1.4. When a contraceptive implant is not localizable in either arm, clinicians should consider whether the contraceptive implant was placed in an alternate location, has migrated, or is absent. If imaging does not locate the implant in the arm, consider an alternate placement location. Best practice is to first examine the contralateral arm to rule out laterality error. Case reports suggest alternate locations for contraceptive implant placement: the scapula, inner thigh, and supraumbilical regions [39–41]. In cases of alternate placement location, clinicians should use clinical judgment and knowledge of relevant anatomy when confirming location and considering the ideal setting and appropriate experienced clinicians for such removals.

If a contraceptive implant is not identified in either arm by ultrasonography, arm radiograph, or MRI, consider the very rare instance of a pulmonary artery migration (1 in 100,000 placements) [42]. Chest radiograph may identify this. If no implant is seen on chest radiography, clinicians may order a hormonal serum assay to confirm contraceptive implant presence within the body, after ensuring the person with the contraceptive implant is not using another contraceptive with the same hormone. For ENG testing, this requires stopping desogestrel- or etonogestrel-containing contraceptives for at least one week, as etonogestrel is the active metabolite of desogestrel. Serum ENG and LNG testing is not commercially available. For ENG implants, the pharmaceutical company clinical liaisons provide instructions regarding sample collection, shipping, and receipt of results on a case-by-case basis [3]. Clinicians may encounter institutional barriers to sending out a serum sample and should counsel persons with implants about timing for receipt of results, as the assays are not run frequently. In the U.S., LNG assays are available for research laboratory use only. If the hormone level is undetectable, the contraceptive implant is assumed not to be present within the body.

If hormone levels are detectable, migration of the contraceptive implant to locations besides the arm should be considered. Reports of ENG contraceptive implant migration include the chest and areas proximal to the upper extremity, such as clavicle, shoulder, and neck [42–47]. Reported complications include arterial thrombosis, endothelialization of the contraceptive implant in the vascular wall, pulmonary embolism, and infarction. To evaluate for these rare complications, clinicians should obtain chest CT with contrast or CT angiography, or both. Depending on contraceptive implant location, the person seeking removal should be referred to a general surgeon, vascular surgeon, or interventional radiologist for removal [48]. Given the possible morbidity associated with removal of a migrated implant, an individual may decide against removal after shared decision-making incorporating their reproductive goals.

2.5.2. Positioning

Once a contraceptive implant is localized and the clinician determines removal is within their scope of practice, proper positioning is key to a successful removal. Position the person seeking removal to allow for localization by palpation or ultrasonography and a safe and comfortable removal attempt. In most cases, this means lying on their back with their arm flexed at the elbow and externally rotated in a position that optimizes access. Proper support promotes muscle relaxation. The clinician should note the relative amount of adipose in the upper arm, which can shift markings if the arm moves and is not returned to the same position. The position should be easily reproducible in case of movement and comfortable for an extended period of time.

2.5.3. Marking the contraceptive implant location and measuring the depth facilitate successful removal

Clinicians should identify and mark the distal and proximal ends of the contraceptive implant to aid removal. When marking each end with the ultrasonography probe perpendicular to the contraceptive implant, clinicians should center the underlying structures at the mid-point —not the end — of the probe. Marking at the midpoint of the probe on the long axis accurately identifies the contraceptive implant location. Marks at the distal and proximal ends of the contraceptive implant identify the 4 cm line of the contraceptive implant on the arm (Fig. 4). Other techniques to assist with identifying location after remote imaging include diagraming and marking distance from placement- or removal-attempt scars and cutaneous stigmata, such as moles and birthmarks [49].

Even when the full length of an implant is identified and marked with imaging, a clinician may refer to a COE or surgeon when the implant depth is beyond their experience or comfort level. With deep contraceptive implants, it is common for the contraceptive implant to be deeper at the proximal end, reflecting improper placement technique in which the needle was moved more deeply as it was advanced. To ensure accurate measurement of the depth of the contraceptive implant at each end, clinicians should use a stand-off or no compression technique. If the arm is compressed during sonographic visualization, the measured depth will also be compressed, providing a false underestimate of the true depth. To perform a stand-off measurement, clinicians apply adequate ultrasonography gel, visualize the implant at the midpoint of the probe, lift the probe upwards (remaining perpendicular to the contraceptive implant) until nearly off the arm, and freeze the image. A depth measurement from the top of the image to the contraceptive implant will still underestimate the true depth but will provide a more realistic approximation. This technique also minimizes compression of blood vessels [38]. This technique has been described for localization in a radiology department immediately before the person seeking removal is brought to an outpatient practice for repositioning and removal, as well as in an office with immediate removal [14,50].

2.5.4. The protocol used for difficult contraceptive implant removals determines the necessary instruments. Removal is commonly described using a modified vasectomy clamp, known as a U-clamp

The U-clamp was developed for the six-rod LNG contraceptive implant removal [51]. It has a ring diameter of 2.2 mm, based on the diameter of the contraceptive implant capsules, and is smaller than most vasectomy clamps with rings of at least 3.5 mm (Fig. 5A). The U-clamp is narrower at the tips, allowing easier grasp of fascia.

U-clamp technique. Most published experience for removal of deep and nonpalpable contraceptive implants in an outpatient setting involves the U-clamp technique, with or without direct ultrasonography guidance. The complexity of office removal of deep and nonpalpable contraceptive implants underscores the need for experience or direct supervision by an experienced clinician, as success rates are high when the procedure is performed by experienced clinicians. Relatively large case series with experienced clinicians reported successful outpatient removal of 98.1–100% suprafascial and 86.1–90.5% subfascial contraceptive implants [14,22,50].

Once the contraceptive implant is localized, experienced clinicians cleanse the surrounding skin with an antiseptic solution. Unlike standard removals, which proceed at the distal tip, experienced clinicians should plan an incision at a site overlying the axis, one-third to one-half the contraceptive implant's length proximal to the distal end. Grasping the contraceptive implant too close to an end may cause it to slip out of the clamp during removal. For local anesthetic administration (eg, lidocaine, ideally with epinephrine, when available, to minimize bleeding and increase duration of action), clinicians should first make a small wheal at the planned incision site and then slowly deliver anesthetic deeper along each side of the localized contraceptive implant. If the contraceptive implant is below the fascia, clinicians should administer the anesthetic both in the subcutaneous tissue to be dissected and subfascially around the contraceptive implant.

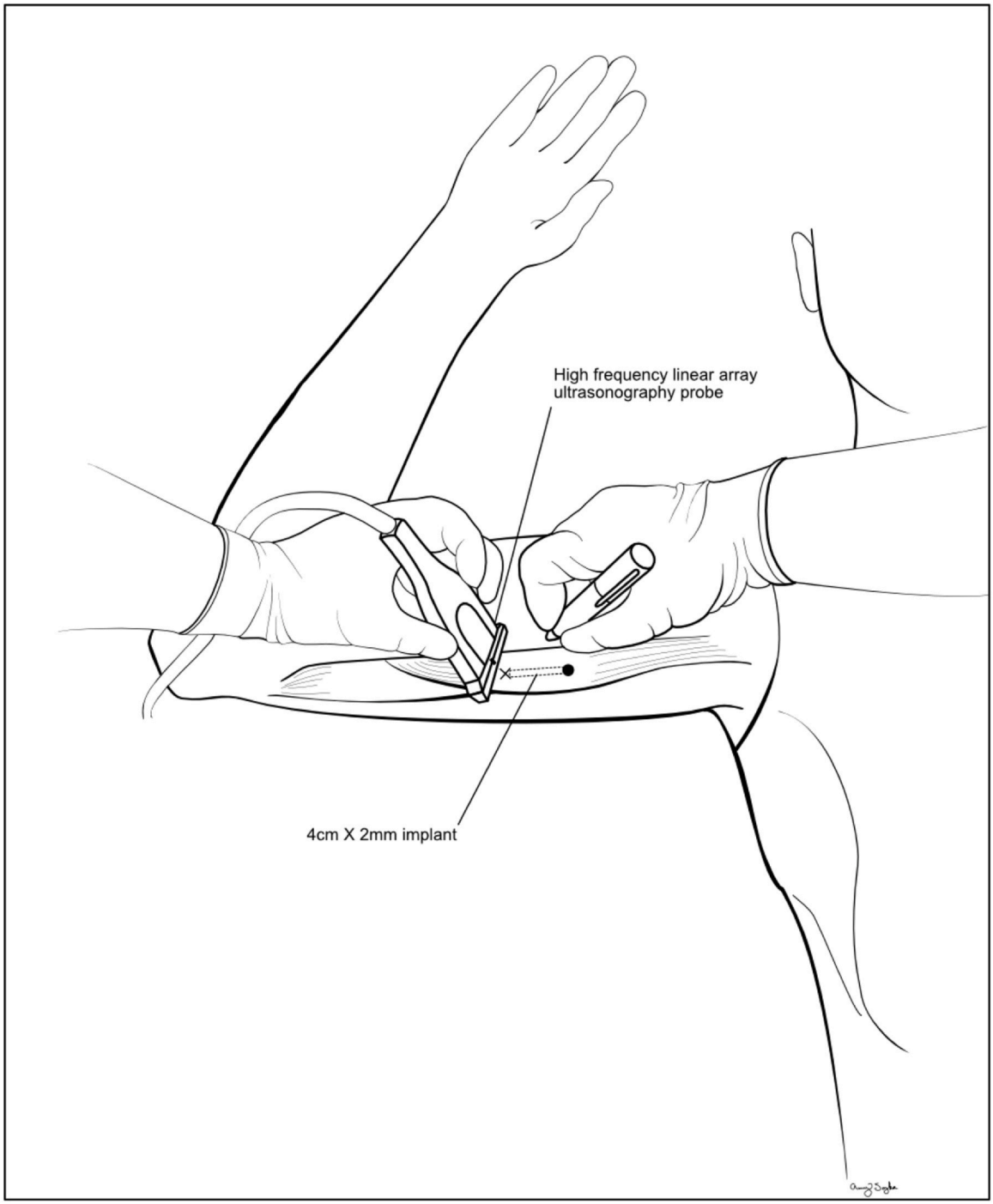

Fig. 4. Pre-procedure ultrasonography of the inner upper arm to localize and mark a contraceptive implant (dotted line) with high-frequency linear array probe (> 10 MHz). The probe is held perpendicular to the axis of the implant, ensuring the implant is centered, and the skin is marked at the midpoint of the probe to designate distal (x) and proximal (dot) implant ends.

Clinicians may cover the ultrasonography probe with a sterile sheath (or glove) and use real-time guidance throughout the removal. Ultrasonography guidance during anesthetic placement helps ensure the distance from epidermis to implant is not inadvertently increased. Clinicians should place a sterile drape near the arm to rest the sheathed ultrasound probe and instruments between uses, maintaining sterile technique throughout.

After ensuring adequate anesthesia, clinicians should use a #11 scalpel blade to make an incision of less than 5 mm along the contraceptive implant axis and use hemostats to dissect the subcutaneous tissue. Small retractors (eg, Ragnell or self-retaining lacrimal duct retractors) may aid in blunt dissection and visualization. For suprafascial contraceptive implants, advance the U-clamp through the incision, open it widely at the contraceptive implant depth, and close it completely. When the clamp is pulled up to the incision, the clinician should confirm that the contraceptive implant is securely grasped. The fibrous tissue encasing the implant can be cleared with gauze, a slightly opened hemostat, or sharply with dissecting forceps (Fig. 5B) or a scalpel, until the whiter implant surface is visible. If using a scalpel, use shallow scraping parallel to the contraceptive implant length to avoid transection [52]. Once cleared, clinicians should never completely release the contraceptive



Courtesy of Sarita Sonalkar
A

Courtesy of Paula M. Castaño
B

Fig. 5. A. A modified vasectomy or U-clamp (top) has a 2.2 mm ring diameter, smaller than most vasectomy clamps. B. A dissecting forceps can be useful for clearing the fibrous tissue encasing a contraceptive implant.

implant and instead should alternate holding the implant with clamps while moving toward one end until the tip is freed, then grasp and remove [52].

A larger incision (5 mm or more) likely allows less experienced clinicians to find contraceptive implants quickly and appears to result in fewer transient neuropathic complaints. However, larger incisions are also associated with increased scarring. Nevertheless, when removing a subfascial implant, a larger incision may be required to allow for more dissection and access to the fascia.

For subfascial contraceptive implants, experienced clinicians continue dissection to the fascia, which is then grasped with a hemostat or U-clamp, and cleared with gauze. Retractors may aid in visualization. The fascia is incised. If desired, clinicians may use a second hemostat to hold the opposite fascial edge. Place the U-clamp through the fascial opening to grasp the implant. Note that the contraceptive implant may be between muscle fibrils. If a grasped structure causes nerve pain or an electric sensation for the person undergoing removal, clinicians should promptly release it and avoid further manipulation, as a nerve may be involved. If localization is difficult, clinicians should check adjacent to the fascial incision, as contraceptive implants may adhere to the fascia underside. While maintaining sterile technique, clinicians may use a sterile gloved finger to palpate the contraceptive implant through the incision and brace it while grasping it with a clamp.

After confirming the contraceptive implant is intact, the clinicians should clean the skin of residual antiseptic and apply a sterile wound closure strip and a pressure dressing. If the incision made is greater than 5 mm, or the skin edges do not approximate well, clinicians can consider a subcuticular absorbable suture to improve the cosmetic outcome and healing and prescribe oral analgesics.

Other techniques. Promising novel techniques for the removal of deeply placed implants include passing a curved needle beneath the contraceptive implant or using hydrodissection with Hartmann grasping microforceps [28,53]. We present a summary of the existing literature and refer interested clinicians to the sources for detailed information on these non-standard techniques.

Curved needle approach. Three case series described placing a needle under the contraceptive implant for removal [28,54,55]. In a recent Swiss case series, following localization, the clinicians used a sterile 20-gauge 55 mm needle, bent slightly, to fixate the contraceptive implant followed by dissection, via an 8 mm to 2 cm skin incision along the axis of the rod. Of the 95 mostly nonpalpable ENG contraceptive implants, 27 (28%) were in the deep subcutaneous tissue, 16 (17%) were intrafascial, and 52 (55%) were subfascial. The authors reported removal of all contraceptive implants with an average removal time of 30 ± 7 min. Three participants experienced transient (< 48) hours dysesthesia in the fingers innervated by the median nerve [28].

Hydrodissection. A French single-center case series of 45 participants referred to interventional radiologists used hydrodissection under continuous ultrasonography guidance for removal of nonpalpable contraceptive implants with Hartmann grasping microforceps [53]. Clinicians localized the contraceptive implant with an 18 MHz transducer and performed all removals with the probe positioned perpendicular to the contraceptive implant. They injected lidocaine 1% using a 21-gauge 5-cm needle into all tissue layers up to the contraceptive implant, approaching from the medial side. They hydrodissected using sodium chloride through the same needle until the contraceptive implant was visible. They used a scalpel to make a small incision at the needle entry point and passed the microforceps to grasp the contraceptive implant. The study reported 21 participants with suprafascial and 24 with subfascial implants. The mean participant BMI was 24.2 ± 4.4 kg/m^2 and the average depth of the contraceptive implants in the subfascial group was 3.5 ± 1.8 mm. All contraceptive implants were successfully removed through an incision averaging 2.7 ± 0.5 mm. For suprafascial and subfascial contraceptive implants, mean removal duration was 5.0 ± 4.7 min and 10.0 ± 6.7 min, mean lidocaine volume was 3.9 ± 1.8 mL and 4.9 ± 1.9 mL, and mean saline volume for hydrodissection was 2.3 ± 2.3 mL and 8.7 ± 3.7, respectively. The study reported no significant complications.

2.6. If the person desires a new contraceptive implant immediately after deep or nonpalpable contraceptive implant removal, the clinician should consider anatomic distortions created during removal, placement in a more appropriate position in the same arm, or placement in the contralateral arm

Per prescribing instructions, if the contraceptive implant is removed from the correct anatomical location, a new implant can be placed without adjusting the location [3]. Contraceptive implant replacement immediately after deep or nonpalpable implant

removal should be approached carefully as the tissues above or, possibly, including the fascia, were distorted during the removal process, requiring additional care to remain immediately subdermal. One case series found an association between subfascial placement and placement during a removal–replacement procedure through the same incision [14]. Although case series include placement after deep and nonpalpable removal, long-term outcomes are not reported [14,29]. If deep or nonpalpable contraceptive implant removal is performed with an incision that is not over the triceps in the area where a contraceptive implant should be inserted, a new contraceptive implant can be placed in the same arm but in a correct location, ensuring superficial subdermal placement. As part of shared decision-making, clinicians can also discuss placement in the contralateral arm.

2.7. Management of bent or broken contraceptive implants depends on the type of contraceptive implant and the desires of the person seeking removal

The ENG 68 mg product label notes that the ENG release rate may increase in a bent or broken implant [3]. Based on expert opinion and knowledge of its copolymer structure, a bent or broken ENG contraceptive implant, whether from trauma or a manufacturing defect, will likely still maintain sufficient ENG levels to prevent pregnancy. A shared decision-making conversation with the person seeking removal can thus include a discussion of leaving bent or broken ENG 68 mg contraceptive implants in situ. By contrast, LNG contraceptive implants are composed of crystalline LNG encased within a silicone elastomeric tube. Damage to LNG implants may cause LNG crystal leakage, reducing efficacy or duration of use. Therefore, a bent or broken LNG implant should be removed and replaced if continued use is desired.

Bent or broken contraceptive implants are not more likely to migrate. If a fractured contraceptive implant is removed, clinicians should measure each piece to ensure the full 4-cm length is accounted for. If the entire contraceptive implant cannot be removed, clinicians should refer the person to a clinician skilled in fragmented implant removals. Documentation should include the size of the pieces retrieved so the receiving clinician is aware of the retained fragment.

2.8. Neuropathic symptoms after deep or nonpalpable contraceptive implant removal are uncommon and transient and usually respond to supportive care

Transient neuropathic symptoms can occur after deep or nonpalpable contraceptive implant removal. First-line approaches to management include application of ice and use of analgesics to decrease any contributory swelling. One series with experienced specialists reported postprocedure neuropathic complaints (finger tingling or ulnar nerve distribution numbness) after 1/21 (4.8%) suprafascial and 7/23 (30.4%) subfascial removal procedures, although most (6/8, 75.0%) resolved by one month postprocedure and all resolved by six months [14]. In the series of 95 removals via the curved needle approach, three participants (3.2%) reported median nerve paresthesia that resolved within 48 h [28]. In the series of 45 deep or nonpalpable removals via hydrodissection, two participants (4.4%) reported transient paresthesia in the region of the medial cutaneous nerve that resolved by the end of the procedure. No participant reported neuropathic pain at day seven, even though 19 (42.2%) contraceptive implants were located within 3 mm of a neurovascular structure on ultrasonography [53]. In a series of 28 participants with operating room removals, one participant (3.6%) developed ulnar nerve paresthesia that resolved within 72 h [30].

2.9. When removing multi-rod contraceptive implants, clinicians should confirm both the number and location of the rods and adjust their removal approach accordingly

Standard placement of any multi-rod system is in the inner upper arm, typically in a “V” or fan-shaped arrangement. Vascular migration is theoretically less likely with multi-rod systems because placement is nonparallel to the neurovascular bundle. All multi-rod implants, whether currently available or legacy, are LNG systems (Table 1). LNG rods are encased in silicone rather than ethylene vinyl acetate, which may result in more fibrotic encapsulation.

In a standard removal of palpable multi-rod implants, clinicians should make a small incision perpendicular to the axis of the contraceptive implants, near or slightly proximal to the tip of the “V,” allowing access for removal of all rods. Deep or nonpalpable multi-rod systems require localization with high-frequency ultrasonography to reveal multiple rods and their corresponding acoustic shadows before removal. In these removals by experienced clinicians, incisions overlying the axis of each rod may facilitate removal.

2.10. Clinicians should use the most appropriate diagnostic and procedural codes

Correct diagnostic and procedural coding depends on the documentation of deep or nonpalpable contraceptive implant removal, including the indication, technique, and procedure performed. Currently, the most appropriate diagnostic code is Z30.46 – *encounter for surveillance of implantable subdermal contraceptive*. Clinicians may also consider secondary diagnostic codes such as T85.628 – *displacement of other specified internal prosthetic devices, implants, and grafts*, or T85.698 – *other mechanical complication of other specified internal prosthetic devices, implants, and grafts*. Table 2 presents possible upper arm foreign body removal procedural codes and modifiers [56].

Payment may not reflect the specialized training, advanced techniques, and resources required for deep or nonpalpable contraceptive implant removal services. Concerns about inadequate payment can create barriers to offering deep or nonpalpable removals. Out-of-pocket costs can deter persons from seeking care or increase medical debt. Facilities can offset both concerns by establishing self-pay packages and financial assistance programs for services not covered by insurance.

2.11. Clinicians should familiarize themselves with the Resource Appendix available on the Society's landing page for this clinical guidance

Numerous print and online resources are available for clinicians managing deep or nonpalpable removals, including resources on services in low-resource settings. These include job aids and training videos on removal techniques [60].

3. Continued discussion

During the development of this document, we identified areas warranting further discussion, research, and consensus, and we invite further exploration:

- Accurate and up-to-date data on referral frequency to COE for deep and nonpalpable removals in real-world settings should be readily available.
- A repository of protocols used by different COE could allow for ongoing evaluation and dissemination of experience.
- Further experience with newer removal techniques (eg, curved needle fixation, hydrodissection) can clarify their potential benefits compared with the U-clamp technique.

Table 2
Possible Current Procedural Terminology (CPT®) codes and modifiers related to deep and nonpalpable contraceptive implant removal[a]

Possible code or modifier	*Descriptor*	*Notes*
11982	Removal, nonbiodegradable drug delivery implant	Typically describes a straightforward office-based procedure that requires only local anesthesia.
24200	Removal of foreign body, upper arm or elbow area; subcutaneous	When the device is accessed subcutaneously in a more challenging fashion but does not require more anesthesia or intraoperative ultrasonography guidance, CPT code 11982 and a −22 modifier may be more accurate.
20525	Removal of foreign body in muscle or tendon sheath; deep or complicated	Consider this code when the device cannot be located or accessed without more anesthesia, or intraoperative ultrasonography guidance is required.
24201	Removal of foreign body, upper arm or elbow area; deep (subfascial or intramuscular)	Consider this code when the device cannot be located or accessed without more anesthesia, or intraoperative ultrasonography guidance is required.
76998	Ultrasonic guidance, intraoperative	
−22	Increased procedural services	When the work required to provide a service is substantially greater than typically required, it may be identified by adding modifier −22 to the usual procedure code. Documentation must support the substantial additional work and the reason for the additional work (eg, increased intensity, time, and technical difficulty of procedure; severity of the condition of the person receiving care; physical and mental efforts required).
−51	Multiple procedures	When multiple procedures are performed at the same session by the same clinician, the primary procedure or service may be reported as listed. The additional procedure(s) or service(s) may be identified by adding modifier −51 to the additional procedure or service code(s).

CPT®, Current Procedural Terminology. CPT® is a registered trademark of the American Medical Association.
[a] States and payors may have their own policies that should be confirmed before submitting a claim. Proper coding may require analysis of statutes, regulations, or carrier policies. As a result, the appropriate code may vary from one payor to another. Not all payors recognize all procedure codes or modifiers.

- An evaluation of the training and comfort level of both radiologists who aid in localizing and surgeons who aid in removing deep or nonpalpable contraceptive implants could inform educational needs and optimize creation of referral networks.
- Increased access to ENG and LNG serum testing could shorten the interval to diagnosing an absent implant.
- Programs that expand access to appropriate ultrasonography probes and removal instruments could allow more clinicians to be mentored to competency in deep and nonpalpable removal, reducing barriers to these services.
- Long-term follow-up data are lacking for who selects new contraceptive implant placement after deep and nonpalpable removal.
- More published experience is needed on removals from nonstandard placement sites.
- Virtual peer-to-peer networks support clinicians managing challenging placement or removals of other long-acting reversible contraceptive methods [57]. A similar network could support clinicians caring for patients with deep or nonpalpable contraceptive implants.
- Reimbursement rates that reflect the complexity of deep and nonpalpable removals could encourage clinicians to develop and maintain the required skills and ensure financial hardship is not a barrier to access.
- Consideration should be given for additional diagnostic codes specific to deep or nonpalpable contraceptive implant removal.

4. Summary of statements

- Clinicians can minimize the need for deep and nonpalpable implant removal by following proper subdermal placement techniques.
- Clinicians who remove contraceptive implants should be aware of the anatomy of the upper arm.
- Clinicians should attempt to determine the type of contraceptive implant the person seeking removal has in place.
- Clinicians considering deep or nonpalpable contraceptive implant removal should conduct a review of previous removal attempts to guide the removal strategy.
- Clinicians considering deep or nonpalpable contraceptive implant removal should follow a standardized protocol that addresses localization, positioning, marking the contraceptive implant location and measuring the depth, and necessary instruments and removal techniques.
- Clinicians should first evaluate the contraceptive implant location via palpation and confirm they feel comfortable attempting standard removal. If not, they should promptly seek supervision by a clinician experienced in deep or nonpalpable implant removal or refer to an experienced clinician, such as a COE.
- Whenever feasible, clinicians with expertise in localizing deep or nonpalpable contraceptive implants should assist surgeons in the operating room with contraceptive implant location to help mitigate additional risks.
- Clinicians attempting to identify the location of a deep or nonpalpable contraceptive implant should be familiar with available radiologic equipment and understand how different imaging modalities can locate different types of contraceptive implants, even if not performing the localization themselves.
- When a contraceptive implant is not localizable in either arm, clinicians should consider whether the contraceptive implant was placed in an alternate location, has migrated, or is absent.
- Marking the contraceptive implant location and measuring the depth facilitate successful removal.
- The protocol used for difficult contraceptive implant removals determines the necessary instruments. Removal is commonly described using a modified vasectomy clamp, known as a U-clamp.
- If the person desires a new contraceptive implant immediately after deep or nonpalpable contraceptive implant removal, the clinician should consider anatomic distortions created during removal, placement in a more appropriate position in the same arm, or placement in the contralateral arm.
- Management of bent or broken contraceptive implants depends on the type of contraceptive implant and the desires of the person seeking removal.
- Neuropathic symptoms after deep or nonpalpable contraceptive implant removal are uncommon and transient and usually respond to supportive care.

- When removing multi-rod contraceptive implants, clinicians should confirm both the number and location of the rods and adjust their removal approach accordingly.
- Clinicians should use the most appropriate diagnostic and procedural codes.
- Clinicians should familiarize themselves with the Resource Appendix available on the Society's landing page for this clinical guidance.

5. Sources

The authors and representatives from the Society's Clinical Affairs Committee identified critical statement topics. The Cochrane Fertility Regulation Group searched Ovid MEDLINE and the Cochrane Central Register of Controlled Trials to identify relevant published articles (Appendix A). We also reviewed guidelines published by organizations such as the U.S. Centers for Disease Control and Prevention, the American College of Obstetricians and Gynecologists, and the Society, as well as relevant product labels. We located additional studies by reviewing the references of identified articles. We contacted representatives from the pharmaceutical company to inquire about ENG testing protocols and information on cases referred to the COE. We used consensus expert opinion from family planning clinicians when published research was unavailable.

6. Intended audience

This Committee Statement is intended for family planning and sexual and reproductive health clinicians removing deep or nonpalpable contraceptive implants or referring to a Center of Experience or similar tertiary expert for removal; Society members; family planning and reproductive health researchers; individuals receiving family planning care; and policymakers, regardless of geographic location. Although this document addresses other contraceptive implant types, the intended audience is clinicians involved in the management of deep or nonpalpable ENG 68 mg contraceptive implants.

Acknowledgments

We thank the Cochrane Fertility Regulation Group for assisting with the literature searches. The North American Society for Pediatric and Adolescent Gynecology and the Planned Parenthood Federation of America endorse this document.

Authorship

This Committee Statement was prepared by Paula M. Castaño, MD, MPH; Mitchell D. Creinin, MD; David L. Eisenberg, MD, MPH; Mark Hathaway, MD, MPH; Lisa G. Hofler, MD, MPH, MBA; Neena Qasba, MD, MPH; Sarita Sonalkar, MD, MPH; and Rachel Steward, MD, MSc. The Clinical Affairs Committee reviewed and approved the statement on behalf of the Society Board of Directors.

Appendix A. Supplementary material

Supplementary data associated with this article can be found in the online version at doi:10.1016/j.contraception.2026.111567.

References

[1] Dethier D, Qasba N, Kaneshiro B. Society of Family Planning Clinical Recommendation: Extended use of long-acting reversible contraception. Contraception 2022;113:13–8. https://doi.org/10.1016/j.contraception.2022.06.003
[2] Bahamondes L, Valeria Bahamondes M, Shulman LP. Non-contraceptive benefits of hormonal and intrauterine reversible contraceptive methods. Hum Reprod Update 2015;21:640–51. https://doi.org/10.1093/humupd/dmv023
[3] US Food and Drug Administration. Nexplanon® (etonogestrel implant). Nexplanon® (Etonogestrel Implant) 2026. https://www.accessdata.fda.gov/drugsatfda_docs/label/2026/021529s027lbl.pdf (accessed April 19, 2026).
[4] Organon. Clinical Training Program (CTP) for Nexplanon®. Clinical Training Program (CTP) for Nexplanon® 2024. https://nexplanontraining.com/request-clinical-training/ (accessed April 24, 2025).
[5] Society of Family Planning. Implant Removal Centers of Experience. Society of Family Planning; 2025https://societyfp.org/clinical/implant-removal-centers-of-experience/ (accessed August 5, 2025).
[6] Zolna MR, Chiu DW, Kavanaugh ML. Contraceptive use and unfulfilled preferences among women ages 15–49 years in the United States, 2022–2023. F S Rep 2026. https://doi.org/10.1016/j.xfre.2026.05.002
[7] Abma J, Martinez G. Teenagers in the United States: Sexual activity, contraceptive use, and childbearing, 2015-2019. National Center for Health Statistics (U.S.); 2023. https://doi.org/10.15620/cdc:134957
[8] World family planning 2022. meeting the changing needs for family planning: contraceptive use by age and method. New York: United Nations; 2022.
[9] Creinin MD, Kaunitz AM, Darney PD, et al. The US etonogestrel implant mandatory clinical training and active monitoring programs: 6-year experience. Contraception 2017;95:205–10. https://doi.org/10.1016/j.contraception.2016.07.012
[10] Reed S, Do Minh T, Lange JA, et al. Real world data on Nexplanon R procedure-related events: final results from the Nexplanon Observational Risk Assessment study (NORA). Contraception 2019;100:31–6. https://doi.org/10.1016/j.contraception.2019.03.052
[11] Chevreau J, Krief D, Abou Arab O, et al. Factors associated with removal difficulties of etonogestrel-containing contraceptive implants (Nexplanon R). Eur J Obstet Gynecol Reprod Biol 2018;224:81–4. https://doi.org/10.1016/j.ejogrb.2018.03.019
[12] Kendall PD, Bresnitz W, Huang J, et al. A retrospective analysis of factors associated with deep contraceptive implant removals compared to superficial removals. Contraception 2024;137:110486. https://doi.org/10.1016/j.contraception.2024.110486
[13] Chene G, Akl P, Gjorgjievska-Delov A, et al. Nonpalpable implant removals at centre of experience in France: a cohort study. Eur J Contracept Reprod Health Care 2024;29:163–70. https://doi.org/10.1080/13625187.2024.2349039
[14] Matulich MC, Chen MJ, Schimmoeller NR, et al. Referral center experience with nonpalpable contraceptive implant removals. Obstet Gynecol 2019;134:801–6. https://doi.org/10.1097/AOG.0000000000003457
[15] American College of Obstetricians and Gynecologists' Committee on Health Care for Underserved Women. Contraceptive Equity Expert Work Group, Committee on Ethics. Patient-centered contraceptive counseling: ACOG Committee Statement number 1. Obstet Gynecol 2022;139:350–3. https://doi.org/10.1097/AOG.0000000000003457
[16] Increasing access to intrauterine devices and contraceptive implants: ACOG Committee Statement No. 5. Obstet Gynecol 2023;141:866–72. https://doi.org/10.1097/AOG.0000000000005127
[17] Boydell V, Smith RD, Global LARC Collaborative (GLC). Hidden in plain sight: A systematic review of coercion and long-acting reversible contraceptive methods (LARC). PLOS Glob Public Health 2023;3:e0002131. https://doi.org/10.1371/journal.pgph.0002131
[18] Stern AM. STERILIZED in the name of public health: race, immigration, and reproductive control in modern California. Am J Public Health 2005;95:1128–38. https://doi.org/10.2105/AJPH.2004.041608
[19] Jekanowski E. Voluntarily, for the good of society: Norplant, coercive policy, and Reproductive Justice. Berkeley Public Policy J 2018.
[20] SisterSong. SisterSong. SisterSong; 2025https://www.sistersong.net/about-x2 (accessed April 25, 2025).
[21] American Public Health Association. Opposing coercion in contraceptive access and care to promote reproductive health equity. American Public Health Association; n.d. https://doi.org/10.1097/AOG.0000000000004659.
[22] Petro G, Spence T, Patel M, et al. Difficult etonogestrel implant removals in South Africa: a review of 74 referred cases. Contraception 2020;102:129–32. https://doi.org/10.1016/j.contraception.2020.04.013
[23] American College of Obstetricians and Gynecologists. Caring for patients who have experienced trauma: ACOG Committee Opinion number 825. Obstet Gynecol 2021;137:e94–9. https://doi.org/10.1097/AOG.0000000000004326
[24] American College of Obstetricians and Gynecologists. Pain Management for In-Office Uterine and Cervical Procedures: ACOG Clinical Consensus No. 9. Obstet Gynecol 2025;146:161–77. https://doi.org/10.1097/AOG.0000000000005911
[25] Katabi L, Stevens E, Ascha M, Arora K. Characteristics of patients requiring surgical removal of subdermal contraceptive implants: A case-control study. Open Access J Contracept 2022;13:111–9. https://doi.org/10.2147/OAJC.S368250
[26] Organon. Communication with Organon 2025.
[27] Odom EB, Eisenberg DL, Fox IK. Difficult removal of subdermal contraceptive implants: a multidisciplinary approach involving a peripheral nerve expert. Contraception 2017;96:89–95. https://doi.org/10.1016/j.contraception.2017.05.001
[28] El-Hadad S, Villars P, Kahr MK, Leeners B. Removal of nonpalpable etonogestrel implants after fixation with a curved needle-a case series. Contraception 2021;104:577–80. https://doi.org/10.1016/j.contraception.2021.07.001
[29] Jacques T, Henry S, Giraudet G, et al. Minimally-invasive fully ultrasound-guided removal of nonpalpable single-rod contraceptive implant: case report and technical description. Contraception 2020;101:338–41. https://doi.org/10.1016/j.contraception.2020.01.006
[30] Vidin E, Garbin O, Rodriguez B, et al. Removal of etonogestrel contraceptive implants in the operating theater: report on 28 cases. Contraception 2007;76:35–9. https://doi.org/10.1016/j.contraception.2007.03.012

[31] Society of Family Planning. Centers of Experience standards and qualifications. Soc Family Plan 2025https://societyfp.org/wp-content/uploads/2025/10/Centers-of-Experience-Standards-and-Qualifications-003-2025-07-03.pdf (accessed December 27, 2025).
[32] Hellwinkel JE, Konigsberg MW, Oviedo J, et al. Subfascial-located contraceptive devices requiring surgical removal. Contracept Reprod Med 2021;6:13. https://doi.org/10.1186/s40834-021-00158-5
[33] Wechselberger G, Wolfram D, Pulzl P, et al. Nerve injury caused by removal of an implantable hormonal contraceptive. Am J Obstet Gynecol 2006;195:323–6. https://doi.org/10.1016/j.ajog.2005.09.016
[34] Gillies R, Scougall P, Nicklin S. Etonogestrel implants - case studies of median nerve injury following removal. Aust Fam Physician 2011;40:799–800.
[35] Ismail H, Mansour D, Singh M. Migration of Implanon. J Fam Plann Reprod Health Care 2006;32:157–9. https://doi.org/10.1783/147118906777888413
[36] Herzog J, Walker L, Sutter C, et al. Ultrasound first for removal of nonpalpable contraceptive implants. J Ultrasound Med 2021;40:1479–83. https://doi.org/10.1002/jum.15539
[37] Soler-Perromat JC, Bartolome-Solanas A, Del Amo M, et al. Non-palpable contraceptive implants localization: review of imaging techniques and algorithm proposal. Quant Imaging Med Surg 2024;14:7862–71. https://doi.org/10.21037/qims-24-353
[38] Sium AF, Abdu AN, Grentzer JM, et al. Non-palpable contraceptive implant evaluation and removal: a protocol that can be adopted for practice in low-middle income countries. Public Health Chall 2025;4:e70086. https://doi.org/10.1002/puh2.70086
[39] Clure C, Sheeder J, Lazorwitz A. Pilot study of a novel, alternative subdermal scapular insertion site for the etonogestrel contraceptive implant. Contraception 2024;135:110442. https://doi.org/10.1016/j.contraception.2024.110442
[40] de Oliveira ECF, Rocha ALL. Inserting the etonorgestrel implant into the thigh: a case report. Contraception 2024;135:110472. https://doi.org/10.1016/j.contraception.2024.110472
[41] Stabile G, Foti C, Mordeglia D, et al. Alternative insertion site of Nexplanon: description of a case report and systematic review of the literature. J Clin Med 2022;11. https://doi.org/10.3390/jcm11113226
[42] Ohannessian A, Levy A, Jaillant N, et al. A French survey of contraceptive implant migration to the pulmonary artery. Contraception 2019;100:255–7. https://doi.org/10.1016/j.contraception.2019.05.016
[43] Kang S, Niak A, Gada N, et al. Etonogestrel implant migration to the vasculature, chest wall, and distant body sites: cases from a pharmacovigilance database. Contraception 2017;96:439–45. https://doi.org/10.1016/j.contraception.2017.08.009
[44] Hindy J-R, Souaid T, Larus CT, et al. Nexplanon migration into a subsegmental branch of the pulmonary artery: A case report and review of the literature. Medicine (Baltimore) 2020;99:e18881. https://doi.org/10.1097/MD.0000000000018881
[45] Choi JH, Kim H-Y, Lee SS, Cho S. Migration of a contraceptive subdermal device into the lung. Obstet Gynecol Sci 2017;60:314–7. https://doi.org/10.5468/ogs.2017.60.3.314
[46] Enabi J, Al-Ayyubi R, Amador P, et al. Migration of a contraceptive subdermal device into the lung. Cureus 2023;15:e48179. https://doi.org/10.7759/cureus.48179
[47] Diego D, Tappy E, Carugno J. Axillary migration of Nexplanon R: case report. Contraception 2017;95:218–20. https://doi.org/10.1016/j.contraception.2016.11.002
[48] Guilbert E, Arguin H, Belanger M. Migration of etonogestrel subcutaneous contraceptive implants: systematic review and recommendations for practice. Eur J Contracept Reprod Health Care 2024;29:115–30. https://doi.org/10.1080/13625187.2024.2342919
[49] Vollans SR, Grainger A, O'Connor P, Limb D. Hormone-releasing contraceptive implants: our experience of complex removals using preoperative ultrasound. Contraception 2015;92:81–3. https://doi.org/10.1016/j.contraception.2015.03.015
[50] Mastey N, Matulich MC, Uhm S, et al. US referral center experience removing nonpalpable and difficult contraceptive implants with in-office ultrasonography: a case series. Contraception 2021;103:428–30. https://doi.org/10.1016/j.contraception.2021.01.018
[51] Praptohardjo U, Wibowo S. The "U" technique: a new method for Norplant® implants removal. Contraception 1993;48:526–36. https://doi.org/10.1016/0010-7824(93)90115-N
[52] Chen MJ, Creinin MD. Removal of a nonpalpable etonogestrel implant with preprocedure ultrasonography and modified vasectomy clamp. Obstet Gynecol 2015;126:935–8. https://doi.org/10.1097/AOG.0000000000001082
[53] Jacques T, Brienne C, Henry S, et al. Minimally invasive removal of deep contraceptive implants under continuous ultrasound guidance is effective, quick, and safe. Eur Radiol 2022;32:1718–25. https://doi.org/10.1007/s00330-021-08263-4
[54] Shihata AA, Salzetti RG, Schnepper FW, Deutsch G. Innovative technique for Norplant® implants removal. Contraception 1995;51:83–5. https://doi.org/10.1016/0010-7824(94)00012-L
[55] Taneepanichskul S, Intaraprasert S, Chaturachinda K. Modified needle elevation technique for misplaced Norplant® implants removal. Contraception 1996;54:87–9. https://doi.org/10.1016/0010-7824(96)00139-4
[56] American Medical Association. CPT Professional 2025. 1st ed. Newburyport: American Medical Association; 2024.
[57] Bayer. Medical support for Bayer IUDs. Bayer 2022https://veeva-vault.prod.cdp.int.bayer.com/7817c6a6-b094-4028-ac98-fef34b85ba42/82937745-ac2c-4305-9e87-5bd09f84585d/82937745-ac2c-4305-9e87-5bd09f84585d_source__v.pdf (accessed December 27, 2025).
[58] Reproductive Health Access Project. A history: the progestin implant. Reprod Health Access Project 2013https://www.reproductiveaccess.org/2013/01/a-history-the-progestin-implant/ accessed February 17, 2025.
[59] Gurel K, Gideroglu K, Topcuoglu A, et al. Detection and localization of a non-palpable subdermal contraceptive implant using ultrasonography: A case report. J Med Ultrasound 2012;20:47–9. https://doi.org/10.1016/j.jmu.2012.01.005
[60] Society of Family Planning. Resource Appendix: Management and Removal of Deep and Nonpalpable Contraceptive Implants. Society of Family Planning; 2026https://societyfp.org/clinical_guidances/management-and-removal-of-non-palpable-contraceptive-implants (accessed July 7, 2026).