

**Elisabeth H. Winterhalter (1856-1952): The Pioneer and her Eponymous Ovarian
Ganglion**

Richard P. Tucker

Department of Cell Biology and Human Anatomy, University of California, Davis, California

Davis, CA 95616-8643, USA

Short Running Head: Elisabeth H. Winterhalter (1856-1952)

Telephone: 530 752 0238

E-mail: rptucker@ucdavis.edu

Abstract

Elisabeth Winterhalter was a German neuroanatomist, physician, feminist and promoter of the arts. After earning her medical degree and completing post-graduate work in surgery and gynecology she was denied the opportunity to take the medical licensing exam in her native Germany. In 1896, while working part time in Frankfurt as an assistant to two physicians, she used Golgi staining to identify neurons in human ovaries. Others, including one of the period's leading researchers of reproductive biology, were unable to find "Winterhalter's ganglia" in their preparations and concluded that Winterhalter had observed non-neuronal cells. Almost a century later researchers using histochemical techniques rediscovered autonomic neurons in primate ovaries, vindicating Winterhalter and supporting parts of her "nervous influence theory" of ovarian function.

Key words: ovary; neuron; Golgi staining; Winterhalter's ganglion; neuroanatomy

Introduction

One of the many remarkable revelations found in Dobson's (1962) collection of anatomical eponyms is the almost total absence of structures named after women. In fact, only three of the nearly 800 short biographies describe female anatomists. The first belongs to Raissa Nitabuch [b. 1859], a Russian exile studying at the University of Bern who described "Nitabuch's stria" (also known as "Nitabuch's layer" or "Nitabuch's membrane") of the placenta in her dissertation, which was to be her only publication (Nitabuch, 1887; see also Pijnenborg & Vercruysse, 2008). The second belongs to Seraphima Schachowa [b. 1854] of "the spiral tubule of Schachowa", and the third to Elisabeth H. Winterhalter [1856-1952], the discoverer of "Winterhalter's ganglion" of the ovary. Like Nitabuch, Schachowa was a Russian studying at the University of Bern; she returned to her native Russia to practice medicine after describing novel aspects of the collecting ducts of the kidney in her dissertation (Schachowa, 1876). In contrast to Nitabuch and Schachowa, the life and work of Winterhalter is relatively well documented (Klausman, 1997; Rök, 1999). These references, as well as information provided through the Institut für Geschichte der Medizin at the Free University of Berlin ("Dokumentation: Ärztinnen im Kaiserreich" at <http://userpage.fu-berlin.de/~elehmus/index.html>), reveal a portrait of a remarkable neuroanatomist, physician and cultural pioneer.

Early Life and Education

Elisabeth Harmine Winterhalter (Fig. 1) was born to Georg and Elisabeth (née von Garr) Winterhalter on December 17, 1856, in München. She was the youngest of 13 children. Her father,

grandfather and great-grandfather were physicians, but her mother (her father died when Elisabeth was 11 years old) opposed a career in medicine for her daughter and insisted that she become a primary school teacher instead. After attending a convent school in Beuerberg bei Wolfratshausen, young Elisabeth followed her mother's wish and trained to be an elementary school teacher at the Bayerisches Lehrerinnenseminar, from which she graduated in 1874. For a while she put her training to use by teaching at an elementary school in Schwabing, a district in Munich known for its Bohemian traditions during the early years of the German Empire. But Elisabeth lacked passion for teaching and continued to argue with her mother that she should study medicine instead. Eventually Elisabeth's persistence paid off and in 1884, at the age of 28, she enrolled at the University of Zürich. Studying in both Zürich and Bern, she earned her medical degree in 1889. Thus, all three of the female anatomists mentioned by Dobson (1962) were educated, at least in part, at the progressive University of Bern.

The Discovery

After graduation Winterhalter studied surgery and gynecology in Paris, Stockholm and Munich. However, she was denied the opportunity to take the board exam to practice medicine in Germany because she was a woman. Not one to be discouraged by this, she moved to Frankfurt in 1891 and worked as an unlicensed assistant with two male colleagues who were sympathetic to her plight and who valued her skills. Just a few years later, in 1895, she became the first surgeon in Germany to perform a laparotomy.

During her early years in Frankfurt work as an unlicensed physician was sparse, so Winterhalter took advantage of her free time to conduct research in neuroanatomy at the nearby

Senckenberg Institute. Working with Professor Carl Weigert [1845-1904], Winterhalter set out to answer a deceptively simple problem: do human ovaries have neurons? Neuroanatomists had recently learned that the ovary had autonomic nerve fibers that entered the gonad by following the ovarian artery in the suspensory ligament (e.g., Riese, 1891). Most appeared to terminate in blood vessels, but some researchers, including the formidable Professor Otto von Herff [1856-1916], soon to become the director of the Frauenspital at the University of Basel, observed fibrils extending into the follicles (von Herff, 1892). Winterhalter set out to determine if any of these fibers were associated with neurons found in the ovaries themselves. Her paper (Winterhalter, 1896) is succinct. She confirmed the presence of a perivascular nerve net in her sections of Golgi-impregnated human ovaries and, more importantly, she found loose collections of neuronal cell bodies associated with the ovarian vasculature and in interstitial spaces near the ovarian hilum (Fig. 2). She describes these ganglia as “consisting of darkly impregnated cells with sharp contours, some of which are round, and some of which are polygonal.” The number of neurons found in the ganglia were different in different preparations, but in this regard she claimed they resembled the neurons found elsewhere in autonomic ganglia. Though she failed to confirm von Herff’s observations of nerve fibers near follicles, she writes, “It is by no means unlikely that as the blood vessels penetrate the follicular layer, the course of which I could see, that the fibers penetrate the follicular layer as well.” In her discussion she boldly concludes, “The presence of ovarian ganglia associated with the vessels of the follicular layer suggests a role for these cells in follicular maturation, ovulation and menstruation” (Winterhalter, 1896). Others came to call this the “nervous influence theory of Winterhalter” (Andrews, 1904).

Winterhalter’s paper made a splash on both sides of the Atlantic as is evidenced by laudatory summaries in the English *Medical Chronicle* (Young, 1896), the *Boston Medical and*

Surgical Journal (Reynolds, 1896) and the *St. Louis Medical Review* (“Notes and Items”, 1896).

The latter includes an interesting error, as it refers to Winterhalter as “he” (similar assumptions were made about Schachowa of spiral tubule fame), even though her full name is used on the title page of her paper. Her paper also inspired a prompt and lengthy rebuttal by Professor von Herff (1896). He agreed that the cells observed by Winterhalter resembled neurons, but paradoxically he remained uncommitted as to whether or not the ovary contained autonomic ganglia:

Given the results of Winterhalter, I reviewed my not yet published drawings in order to add to this subject. I found the same cells, which were concentrated at the branch points of vessels. They appear to be the same cells described by Ramon y Cajal in sympathetic perivascular nets. I found these entities exclusively along the surface of vessels. I was inclined to regard them as ganglion cells, but now I quietly have my doubts, as I have seen similar Golgi stained entities in other regions (von Herff, 1896).

Ultimately, this seed of doubt planted by the influential professor contributed significantly to the widespread dismissal of Winterhalter’s observations in following years.

A Pioneer of Medicine and Culture

Winterhalter’s research paper describing the neurons of the ovaries was to be her first—and her last. Her research brought her an eponym and an entry in Dobson’s (1962) book, but it was her future career as a physician and her role as a leader of the feminist movement in Germany that brought her more widespread fame. While conducting research she also made the time to found a women’s health clinic in Frankfurt and her practice started to thrive, despite her lack of a German medical license. At the turn of the century she also organized and participated in a

Congress on the treatment and prevention of venereal diseases, and she became a leader in the local Patriotic Women's Association. Finally, in 1904, 13 years after she started to practice medicine in Frankfurt, German authorities allowed Winterhalter to take the state medical exam and earn her licensure.

Not one to shy from controversy, Winterhalter lived openly in Frankfurt with her life partner Otilie Roederstein [1859-1937], a renowned painter whom she met while studying in Zürich. With Roederstein she championed the cause of women's education and co-founded a high school for girls. Failing health led Winterhalter to retire from medical practice in 1911, when she moved with Roederstein to a country home in Hofheim am Taunus, about 20 km west of Frankfurt. There she continued to be active in promoting women's rights and the arts. She died in Hofheim am Taunus on February 13, 1952.

Controversy and Validation

"Winterhalter's ganglia" quickly became controversial. In fact, during the first two decades of the twentieth century many researchers were unable to repeat Winterhalter's results (reviewed by Kuntz, 1919). An influential textbook on reproduction by Marshall (1922) was one of the last publications to refer to "Winterhalter's ganglia", only to conclude that "von Herff discredited her description, which, so far, has received no confirmation." Half a century later, Neilson et al. (1970) claimed that Winterhalter's ovarian "neurons" were most likely artifacts of non-specific labeling of non-neuronal cells, possibly fibroblasts—basically a restatement of von Herff's unsubstantiated remarks. Her "nervous influence theory" was also turned into a straw man shortly after her paper was published, as Knauer (1896) was able to show that ovaries

transplanted into the abdominal musculature of a rabbit, far from the influence of their natural innervation, were at least partially functional.

More recently, researchers using modern methods of immunohistochemistry to identify neurons vindicated Winterhalter (Dees et al., 1995; Anesetti et al., 2001; reviewed in D'Albora et al., 2002), and we now know that the proper innervation of mammalian gonads is important for their normal development and function. For example, vagotomy is known to alter the estrous cycle, reduce the secretion of steroids, delay the onset of puberty and reduce the number of shed oocytes (reviewed in Gerendai et al., 2005). Modern micrographs of Golgi staining and histochemical preparations of mammalian ovaries using neuron-specific markers are remarkably similar to the drawings published more than a century earlier by Winterhalter (Fig. 3). So why were researchers unable to reproduce her observations for almost a century? One explanation is that there are relatively few ovarian neurons, so only the most dedicated (or lucky) neuroanatomists are likely to find them. Also contributing to the negative results is the fact that the number of neurons diminishes significantly with age—researchers looking at ovaries from middle-aged or post-menopausal women would be much less likely to encounter neurons than a researcher studying the ovaries of a young woman. Finally, species-to-species variation in neuron number complicated confirmation of Winterhalter's results in common animal models.

One of the many reasons why the use of eponyms during anatomy education should be discouraged (e.g., see O'Rahilly, 1989) is the fact that they can reflect the gender and cultural biases of an earlier age. But sometimes there are important lessons about these very issues to be gleaned from their appearance in the literature. In the case of “Winterhalter's ganglia” and the resulting “nervous influence theory” we learn that the careful observations of a young, female researcher working outside the scientific power centers of her day should not have been so

readily dismissed by her male colleagues: her observations, and some aspects of her theory, survived the test of time.

Acknowledgments

The author would like to thank C. Peterson (University of the Pacific) for reviewing the manuscript and offering suggestions for clarification.

References

- Andrews HR (1904): The internal secretion of the ovary. *Journal of Obstetrics and Gynecology* 5:448-465.
- Anesetti G, Lombide P, D'Albora H, Ojeda SR (2001): Intrinsic neurons in the human ovary. *Cell and Tissue Research* 306:231-237.
- D'Albora H, Anesetti G, Lombide P, Dees WL, Ojeda SR (2002): Intrinsic neurons in the mammalian ovary. *Microscopy Research and Technique* 59:484-489.
- D'Albora H, Barcia JJ. (1996): Intrinsic neuronal cell bodies in the rat ovary. *Neuroscience Letters* 205:65-67.
- Dees WL, Hiney JK, Schulte TD, Mayerhofer A, Danilchik M, Dissen GA, Ojeda SR (1995): The primate ovary contains a population of catecholaminergic neuron-like cells expressing nerve growth factor receptors. *Endocrinology* 136:5760-5768.
- Dobson J (1962): *Anatomical Eponyms*, 2nd Ed, London: Livingstone. p. 1-236.
- Gerendai I, Banczerowski P, Halász B (2005): Functional significance of the innervation of the gonads. *Endocrine* 28:309-318.
- Klausmann C (1997): *Politik und Kultur der Frauenbewegung im Kaiserreich*, Frankfurt a.M.: Campus Verlag. p. 1-404.
- Knauer E (1896): *Einige Versuche von Ovarientransplantation am Kaninchen*. *Centralblatt für Gynäkologie* 20:524-528.
- Kuntz A (1919): The innervation of the gonads in the dog. *Anatomical Record* 17:203-219.
- Marshall FHA (1922): *The Physiology of Reproduction*, London: Longmans, Green and Company. p. 1-770.

- Neilson D, Jones GS, Woodruff JD, Goldberg B (1970): The innervation of the ovary. *Obstetrical and Gynecological Survey* 25:889-904.
- Nitabuch R (1887): *Beiträge zur Kenntniss der menschlichen Placenta*, Medical thesis dissertation. Berne, Switzerland.
- Notes and Items (1896): *The St. Louis Medical Review*, 33:380.
- O’Rahilly R (1989): Anatomical terminology, then and now. *Acta Anatomica* 134:291-300.
- Pijnenborg R, Vercruyssen L (2008): Shifting Concepts of the Fetal–Maternal Interface: A Historical Perspective. *Placenta* 29S:20-25.
- Reynolds E (1896): Progress in gynecology. *The Boston Medical and Surgical Journal* 135:310-312.
- Riese H (1891): *Die feinsten Nervenfasern und ihre Endigungen im Ovarium der Säugethiere und des Menschen*. *Anatomischer Anzeiger* 6:400-420.
- Rök B (1999): *Ottilie W. Roederstein (1859-1937): Eine Künstlerin zwischen Tradition und Moderne*, Marburg: Jonas.
- Schachowa S (1876): *Untersuchungen über die Niere*, Medical thesis dissertation. Berne, Switzerland.
- von Herff O (1892): *Ueber den feineren Verlauf der Nerven im Eierstocke des Menschen*. *Zeitschrift für Geburtshilfe und Gynäkologie* 24:289-308.
- von Herff O (1896): *Giebt es ein sympathisches Ganglion im menschlichen Ovarium?* *Archiv für Gynäkologie* 51:374-388.
- Winterhalter EH (1896): *Ein sympathisches Ganglion im menschlichen Ovarium*. *Archiv für Gynäkologie* 51:49-56.
- Young AH (1896): Anatomy. *Medical Chronicle* 5:228-234.

Figure Legends



Fig. 1. Elisabeth H. Winterhalter as a medical student in 1886. Reproduced from Rök (1999).

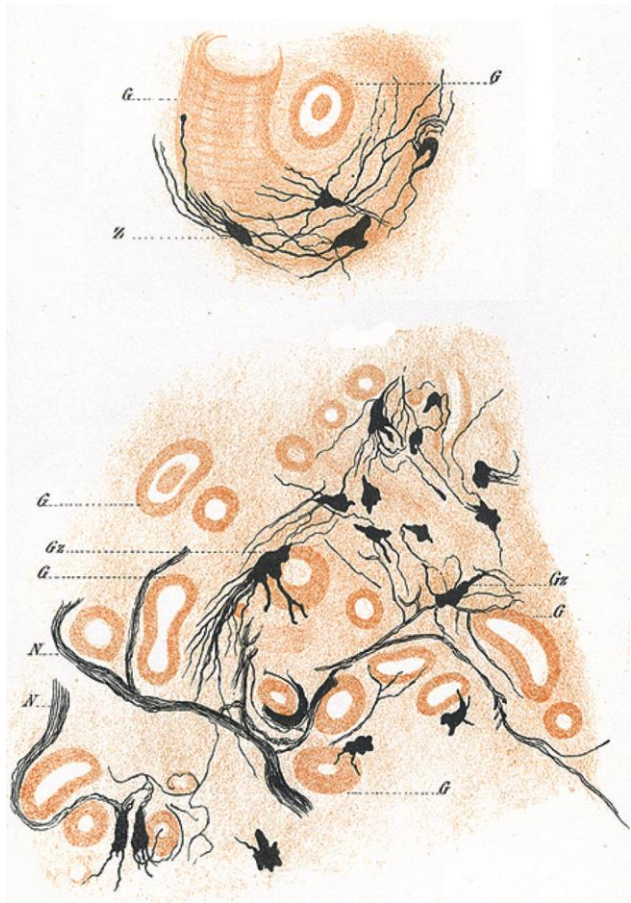


Fig. 2. Perivascular Golgi-impregnated neurons in the human ovary (top) and similarly stained neurons in the inner zona vasculosa (bottom). From Winterhalter (1896).

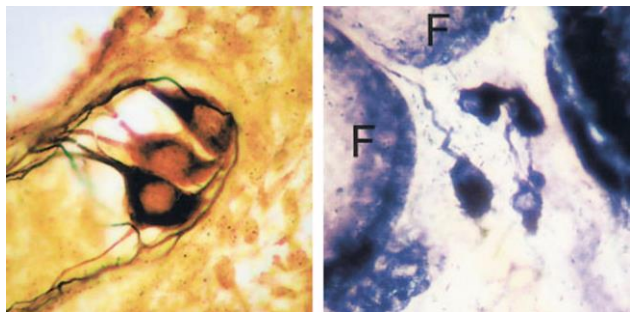


Fig. 3. Golgi-stained neurons near a blood vessel in the rat ovary (left) and neurons near follicles (F) in the rat ovary that are labeled with a histochemical procedure for identifying NADPH diaphorase, a neuron-specific marker (right). Reprinted from D'Albora and Barcia (1996) with permission from Elsevier.