

UC Davis

Dermatology Online Journal

Title

Generalized retiform purpura as a presenting sign of diffuse dermal angiomatosis

Permalink

<https://escholarship.org/uc/item/2pw4682s>

Journal

Dermatology Online Journal, 24(5)

Authors

Bhattacharya, Tanya
Sluzevich, Jason

Publication Date

2018

DOI

10.5070/D3245040104

Copyright Information

Copyright 2018 by the author(s). This work is made available under the terms of a Creative Commons Attribution-NonCommercial-NoDerivatives License, available at <https://creativecommons.org/licenses/by-nc-nd/4.0/>

Peer reviewed

Generalized retiform purpura as a presenting sign of diffuse dermal angiomatosis

Tanya Bhattacharya MD, Jason Sluzevich MD

Affiliations: Mayo Clinic, Jacksonville, Florida, USA

Corresponding Author: Tanya Bhattacharya, M.D., 4500 San Pablo Road, Jacksonville, FL 32224, Email: bhattacharya.tanya@mayo.edu

Abstract

A 49-year-old man presented with progressive, painful, ulcerative, retiform purpuric patches on the torso and extremities. Multiple skin biopsies revealed a prominent pan-dermal vascular proliferation but no occlusive vasculopathy or cutaneous vasculitis. Diffuse dermal angiomatosis should be considered in the differential diagnosis of retiform purpura, especially in patients with atherosclerotic disease or underlying hypercoagulable states.

Keywords: diffuse dermal angiomatosis, retiform, stellate, purpura

Introduction

Retiform purpura is a distinct cutaneous morphology characterized by branched and stellate violaceous patches. Common etiologies include acquired and inherited forms of occlusive vasculopathy as well as small and medium vessel cutaneous vasculitis, especially when the purpura predominates on the lower extremities. Generalized retiform purpura with ulceration is uncommon and has been most frequently described as a feature of calciphylaxis.

We describe a 49-year-old man who presented with generalized retiform purpura as a sign of diffuse dermal angiomatosis (DDA) in the setting of advanced atherosclerosis.

Case Synopsis

A 49-year-old man presented with progressive

multiple painful retiform purpuric patches on the trunk and extremities for 12 weeks (**Figure 1**). Prior treatment with oral prednisone and chronic anti-coagulation with apixaban resulted in no improvement. Anti-nuclear antibody (ANA), extractable nuclear antigen (ENA) panel, rheumatoid factor, and anti-neutrophil cytoplasmic antibody (ANCA) panel were negative. Serum protein electrophoresis with immunofixation revealed a monoclonal IgG lambda gammopathy but serum cryoglobulins were negative and the serum kappa/lambda light chain ratio was normal. A hypercoagulable panel was also found to be unremarkable. Multiple punch biopsies were obtained on the torso and extremities and revealed a diffuse dermal vascular proliferation of larger ectatic vessels admixed with tightly clustered small caliber vascular proliferations as confirmed by CD34 staining (**Figure 2**). The specimens did not demonstrate evidence of active vasculopathy or vasculitis. Angiography demonstrated a distal right radial artery occlusion and atherosclerotic stenosis of the bilateral lower extremities.

Case Discussion

Diffuse dermal angiomatosis is a rare form of cutaneous reactive angiomatosis presenting as purpuric retiform and stellate patches with variable degrees of epidermal ulceration. The histology of DDA is characterized by a benign diffuse proliferation of small caliber blood vessels in the dermis without histologic evidence of vasculitis or vascular occlusion. The vascular proliferation is posited to be secondary to chronic tissue hypoxia

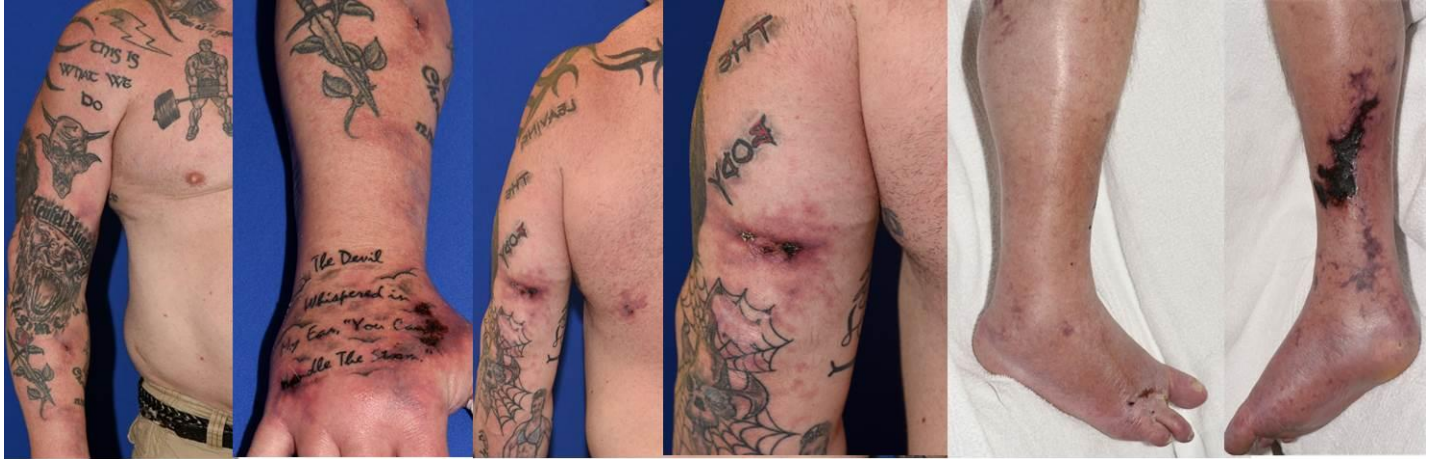

Figure 1. Multiple, reddish-purple to dusky violaceous, stellate patches with variable central ulcerations on the right upper extremity, left upper extremity, left back, and lower extremities.

triggering increased vascular endothelial growth factor (VEGF) production from endothelial and dermal fibroblasts [1]. Accordingly, DDA has been described in association with smoking, peripheral vascular disease, and hypercoagulable states leading to impaired vascular perfusion such as is seen in antiphospholipid syndrome, monoclonal gammopathy, or calciphylaxis [1].

Classic presentations of DDA are usually unilateral [2]. Common locations include the thighs, buttocks, and lower extremities of elderly men and the breasts of middle-aged women who smoke or have macromastia [3]. Rarely, DDA can be more generalized owing to the presence and severity of multiple risk factors for DDA [2]. In this case, the

patient had evidence of advanced peripheral vascular disease as confirmed with angiography. He was an active smoker and also had an underlying monoclonal gammopathy, which could predispose to vascular sludging and micro-vascular occlusion. Generalized presentations of DDA most closely mimic the clinical features of calciphylaxis, but biopsies are generally discriminatory. Vasculopathy and vasculitis are often also leading clinical considerations; multiple biopsies of early and late lesions can minimize the possibility of sampling error and help to establish angiomasia as the principal histologic finding. The treatment of DDA focuses on improving tissue hypoxia. Revascularization procedures are beneficial in the setting of advanced peripheral vascular disease [4]. Anti-coagulation and

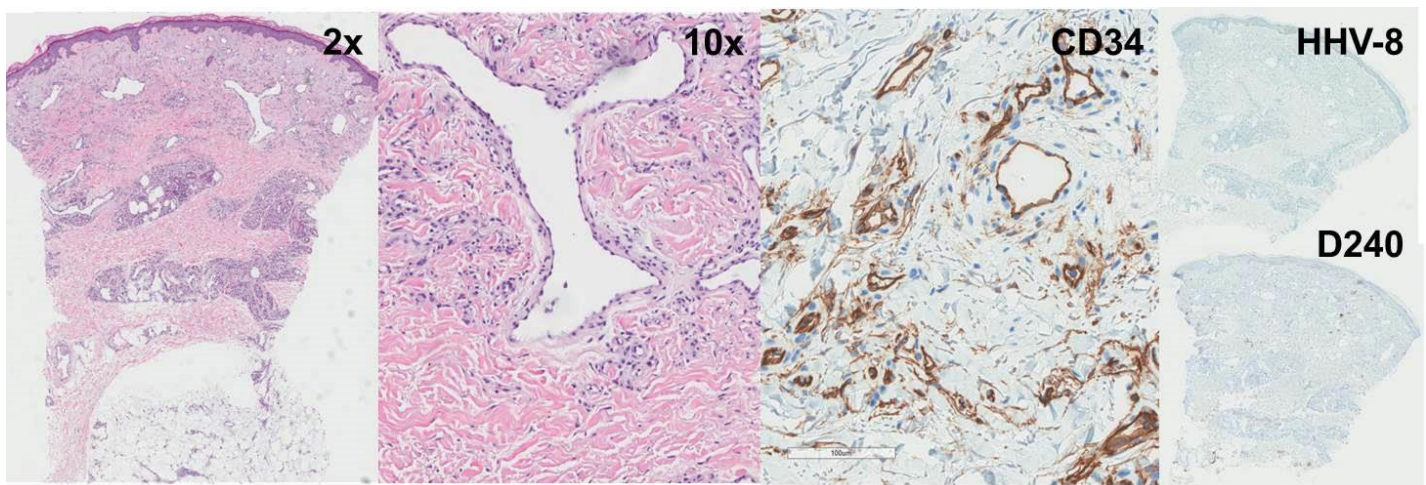


Figure 2. Punch biopsies demonstrated numerous variably ectatic dermal blood vessels lined with bland, plump endothelial cells (torso) admixed with a diffuse dermal proliferation of smaller caliber vessels (upper arm). CD34 immunostain was positive. HHV-8 and D240 immunostains were negative. No vasculitis or occlusive vasculopathy was identified.

systemic corticosteroid therapy have been reported to be helpful in some presentations [4]. Smoking cessation is strongly advised.

Conclusion

DDA should be considered in a patient with painful, progressive, ulcerated retiform purpura in the following settings: (1) localized lesions on the proximal lower extremities in elderly men with

peripheral arterial disease; (2) localized lesions on the breasts in women with smoking history and pendulous breasts; (3) generalized or localized lesions in patients with peripheral arterial disease, monoclonal gammopathy, and/or hypercoagulable states. The histopathologic findings are characteristic and help to exclude more common inflammatory or occlusive etiologies of retiform purpura.

References

1. Ferrel C, Atzori L, Pinna AL, Pau M, Aste N, Ricotti C, Rongioletti F. Diffuse dermal angiomas: a clinical mimicker of vasculitis associated with calciphylaxis and monoclonal gammopathy. *G Ital Dermatol Venereol*. 2015;150(1):115-121. [PMID:25502367].
2. Crickx E, Saussine A, Vignon-Pennamen MD, Cordoliani F, Mouly F, Bagot M, Rybojad M. Diffuse dermal angiomas associated with severe atherosclerosis: two cases and review of the literature. *Clin Exp Dermatol*. July 2015;40(5):521-524. Available from: EBSCO MegaFILE, Ipswich, MA. [PMID:25639294].
3. Reusche R, Winocour S, Degnim A, Lemaine V. Diffuse dermal angiomas of the breast: a series of 22 cases from a single institution. *Gland Surg*. Dec 2015;4(6):554-560. [PMID:26645009].
4. García-Colmenero L, Martín-Ezquerro G, Gómez-Martín I, Joan MM, Barranco C, Albero-González R, Villar-García J, Pujol R. Persistent cutaneous abdominal ulcerations secondary to diffuse dermal angiomas: an underestimated sign for severe atherosclerosis. *Medicine (Baltimore)*. 2016;95(29):e4212. [PMID:27442644].