

## **UC Irvine**

### **Journal of Education and Teaching in Emergency Medicine**

#### **Title**

Ultrasonographic Findings of Acute Achilles Tendon Rupture

#### **Permalink**

<https://escholarship.org/uc/item/2qg6n340>

#### **Journal**

Journal of Education and Teaching in Emergency Medicine, 4(4)

#### **Authors**

Rudy, Charles Craig  
Thompson, John A  
Bengtzen, Rachel R

#### **Publication Date**

2019

#### **DOI**

10.5070/M544045613

#### **Copyright Information**

Copyright 2019 by the author(s). This work is made available under the terms of a Creative Commons Attribution License, available at <https://creativecommons.org/licenses/by/4.0/>

Peer reviewed

## Ultrasonographic Findings of Acute Achilles Tendon Rupture

Charles Craig Rudy, MD<sup>\*^</sup>, John A Thompson, MD<sup>\*</sup> and Rachel R Bengtzen, MD<sup>\*^</sup>

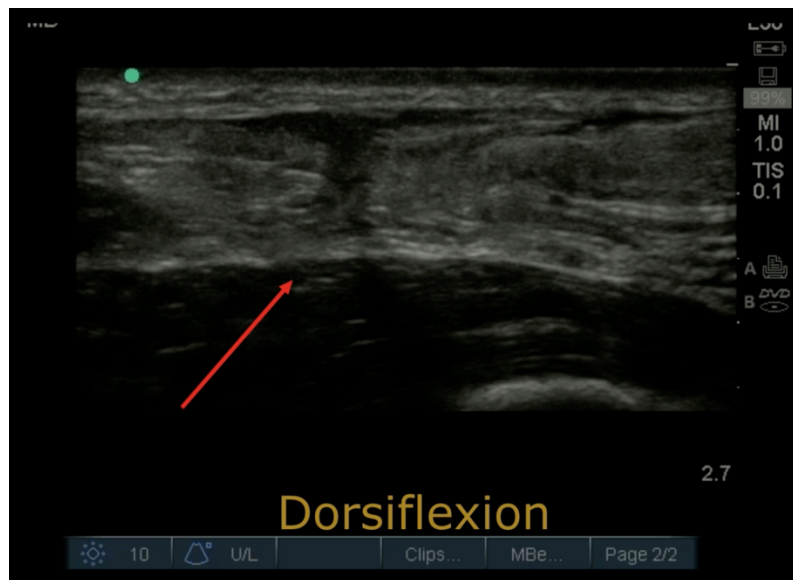
<sup>\*</sup> Oregon Health & Sciences University, Department of Emergency Medicine, Portland, OR

<sup>^</sup> Oregon Health & Sciences University, Department of Family Medicine (Sports Medicine), Portland, OR

Correspondence should be addressed to Charles Craig Rudy, MD at [rudy@ohsu.edu](mailto:rudy@ohsu.edu)

Submitted: March 10, 2019; Accepted: May 26, 2019; Electronically Published: October 15, 2019; <https://doi.org/10.21980/J8063S>

Copyright: © 2019 Rudy, et al. This is an open access article distributed in accordance with the terms of the Creative Commons Attribution (CC BY 4.0) License. See: <http://creativecommons.org/licenses/by/4.0/>



Annotated Video Link: [https://youtu.be/KQUjk3dW\\_IM](https://youtu.be/KQUjk3dW_IM)

Long Axis Video Link: <https://youtu.be/XiQMJFdfROW>

Short Axis Video Link: <https://youtu.be/VKD0LVfqoOw>

Distal to Proximal Video Link: <https://youtu.be/rRDLp0fR2qM>

Dynamic Rupture Video Link: <https://youtu.be/M6MILjqoADY>

**History of present illness:** A 47-year-old male presents with acute right Achilles tendon (AT) pain. When he was vaulting off a diving board, he felt a snapping sensation in his right lower extremity, with a sudden onset pain and associated swelling.

**Significant findings:** The ultrasound video clip shows a longitudinal view of the AT during a dynamic exam.

While the patient's foot is gently passively dorsi/plantar flexed, the video demonstrates first a normal Achilles tendon (from the unaffected extremity) without disruption (highlighted by a yellow bracket on screen left). Then it shows an abnormal tendon (the patient's affected side) with disruption of the typical linear tendon fibers (red arrow identifies area of rupture). Dynamic testing shows the movement of the distal stump of the AT is evident adjacent to hypoechoic fluid that is reactive edema or blood from the acute rupture.

**Discussion:** Achilles tendon rupture identified in the emergency department is often made by history and physical exam alone; however, up to 20% of ruptures are missed during the hyperacute phase.<sup>1</sup> Delayed diagnosis and subsequent treatment delay can lead to a permanently discontinuous or lengthened tendon; patients experience poorer functional performance and strength.<sup>2</sup> Additionally, surgical repair is more complicated with a higher risk of complications.<sup>2,3</sup>

Accurate identification and referral can prevent significant functional morbidity. To facilitate diagnosis, point of care ultrasound (POCUS) is a helpful adjunctive tool to confirm the suspected diagnosis.<sup>4,5</sup> Ultrasound has been found to be 79%-100% sensitive for this injury.<sup>5</sup> Evaluate the AT systematically in two planes: a superior-inferior direction (longitudinal) and medial-lateral (axial) through the full length and width of the tendon through the myotendinous junction. In a healthy tendon, the fibers are oriented in a fibrillar linear and regular pattern. In the disrupted tendon, the fibers may appear thickened, wavy, or as an abrupt edge of a completely disrupted tendon stump with/without retraction. Secondary signs of AT tear include hypoechoic areas within or deep to the tendon.<sup>1,6</sup> A common pitfall in the evaluation of a tendon is to mistake anisotropy for AT tearing or rupture. Anisotropy is the natural tendency for a structure to have apparent changing density as the angle of sound waves directed at the tissue changes.<sup>7</sup> The tendon will appear to change from a hyperechoic to hypoechoic structure as the ultrasound transducer is fanned.<sup>7,8</sup> This can lead to the common pitfall that a hypoechoic structure appears torn. Fanning and toeing the probe to evaluate for anisotropy and looking for secondary signs of rupture can help distinguish between a ruptured tendon and a normal healthy tendon.<sup>8</sup> Additionally, gentle dynamic active or passive movement placing the tendon under slight tension can help distinguish the presence of tear or rupture. A subtle tear can be exaggerated with gentle dorsiflexion of the foot as the tendon is stretched to length.<sup>6</sup> If a full thickness tear is present, the distal stump will move across the screen as seen in the associated video.

The patient was diagnosed with a full thickness AT rupture. The patient's foot was braced in an equine position, and the patient was given close outpatient orthopedic follow-up. Surgical therapy was selected and the patient is recovering well.

**Topics:** Musculoskeletal ultrasound, Achilles tendon, tendon rupture, orthopedic injuries.

#### References:

1. Hartgerink P, Fessell D, Jacobson J, van Holsbeeck M. Full- versus partial-thickness achilles tendon tears: sonographic accuracy and characterization in 26 cases with surgical correlation. *Radiology*. 2001;220(2):406-412.

2. Steginsky BD, Van Dyke B, Berlet GC. The missed achilles tear: now what? *Foot Ankle Clin.* 2017;22(4):715-734. doi: 10.1016/j.fcl.2017.07.004.
3. Singh D. Acute Achilles tendon rupture. *BMJ.* 2015;351:h4722. doi: 10.1136/bmj.h4722.
4. Robinson P. Sonography of common tendon injuries. *Am J Roentgenol.* 2009;193(3):607-618. doi: 10.2214/AJR.09.2808.
5. Dams OC, Reininga IH, Gielen JL, van den Akker-Scheek I, Zwerver J. Imaging modalities in the diagnosis and monitoring of Achilles tendon ruptures: a systematic review. *Injury.* 2017;48(11):2383-2399. doi: 10.1016/j.injury.2017.09.013.
6. Adhikari S, Marx J, Crum T. Point-of-care ultrasound diagnosis of acute Achilles tendon rupture in the ED. *Am J Emerg Med.* 2012;30(4):634 e633-634. doi: 10.1016/j.ajem.2011.01.029.
7. Garcia T, Hornof WJ, Insana MF. On the ultrasonic properties of tendon. *Ultrasound Med Biol.* 2003;29(12):1787-1797.
8. Alves T, Dong Q, Jacobson J, Yablon C, Gandikota G. Normal and injured ankle ligaments on ultrasonography with magnetic resonance imaging correlation. *J Ultrasound Med.* 2019;38(2):513-528. doi: 10.1002/jum.14716